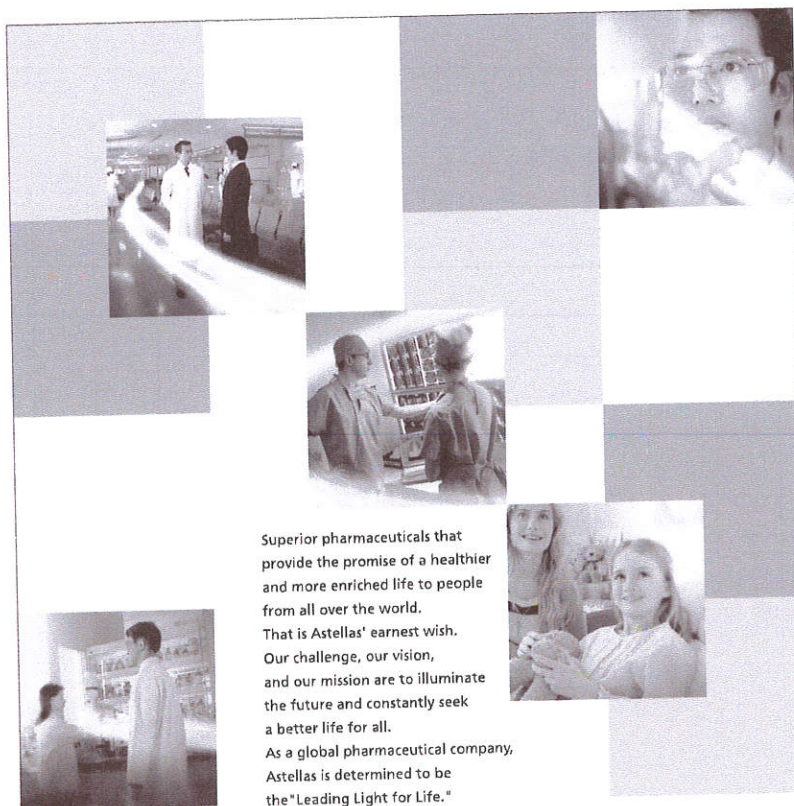



C M Y K



Superior pharmaceuticals that provide the promise of a healthier and more enriched life to people from all over the world. That is Astellas' earnest wish. Our challenge, our vision, and our mission are to illuminate the future and constantly seek a better life for all. As a global pharmaceutical company, Astellas is determined to be the "Leading Light for Life."



**astellas**  
Leading Light for Life  
Astellas Pharma Inc.  
www.astellas.com

International Medical Journal

Vol. 28 No. 3 June, 2021

# IMJ



Online ISSN: 2436-3294  
Print ISSN: 1341-2051  
CODEN: IMJOFS

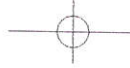
June, 2021

International Medical Journal

Volume 28, Number 3

## CONTENTS (1)

EDITORIAL	278	Perspectives on Emergency Medicine in Psychiatry	Takahiko Nagamine
INTERNAL MEDICINE	280	Studying Clinical Reasoning of Internal Medicine Residents in Medical City Campus Using Script Concordance Test	Batool A.G. Yassin, et al.
HYPOTHYROIDISM	284	Microalbuminuria in Hypothyroidism: A Case Control Study	Aditi Parimoo, et al.
NEUROLOGY	286	Intensity of Cognitive Disorders in Epilepsy and in Symptomatic Epilepsy Syndrome	Alexander L. Malev, et al.
	289	A Comprehensive Approach in Pituitary Adenoma Management	Cindy Cecilia, et al.
EPILEPSY	293	Transcranial Direct Current Stimulation for Treatment of Refractory Temporal Lobe Epilepsy: A Scoping Review	Abdul Wafi Ahmad Jafree, et al.
COVID-19	299	COVID-19: A Scenario of Malaysian Mortality	Wan Muhamad Amir W Ahmad, et al.
	303	Mesenchymal Stem Cells: Potential Application in COVID-19 patients with Acute Respiratory Distress Syndrome (ARDS)	Emni Purwoningsih, et al.
	307	Coronavirus Disease-19 in Nigeria: Reshaping Workplace Orientation	Felix O. Egara, et al.
PARASITOLOGY	311	The Effect of Garden Croton ( <i>Codiaeum variegatum</i> ) Extract on the Cysts of Clinically Isolated <i>Acanthamoeba</i> spp.	Mohamed Kamel AG, et al.
CHILD HEALTH	314	Relationship between the Value of Red Cell Distribution Width and Parameters of Left Ventricular Function in Children with Heart Failure	Winson Chitra, et al.
	318	The Evaluation of Procalcitonin Accuracy in Early and Late Onset Neonatal Sepsis	Bugis Mardina Lubis
NURSING SCIENCE	322	Nurses' Preparedness against the Middle East Respiratory Syndrome Coronavirus Outbreak: A Cross-Sectional Study in Iran	Masoomeh Abdollahi, et al.
KAMPO MEDICINE	328	Analysis of Treatment with <i>Astragalus Membranaceus</i> Powder in Patients with Chronic Kidney Disease	Makoto Arai, et al.
PERILLA OIL	331	Changes in Physiological Indicators due to Perilla Oil Intake in Japanese People	Yoji Kato, et al.
TRIGONA HONEY	335	Trigona Honey as a Potential Supplementary Therapy to Halt the Progression of Post-Stroke Vascular Cognitive Impairment	Sabarish Hashim, et al.
SOCIAL PATHOLOGY	339	Couples' Socio-Demographic Variables as Correlates of Intimate Partner Violence	Shulamite Ebere Ogbuabor, et al.



# International Medical Journal (IMJ)

Volume 28, Number 3

June, 2021

## CONTENTS (2)

- ANATOMY** 343 **Review of Suprascapular Nerve Block under Ultrasound-Guided: Alternative Technique with Clinical Roles**  
Naraporn Maikong, *et al.*
- ORAL CARCINOMA** 347 **Oral Squamous Cell Carcinomas: A Statistical Study to Determine the Potential Prognostics Factors that Affect the Tumor Size**  
Wan Muhamad Amir W Ahmad, *et al.*
- ORTHODONTICS** 352 **The Orthodontic Mini Implants Covers and Their Effect on the Oral Health Related Quality of Life: A Randomised Controlled Trial**  
Nor Dayana Mohd Ali, *et al.*
- DENTAL SCIENCE** 357 **Role of Maxillary First Premolar in Forensic Identification: A Comparative Study between Two Races**  
Krishna A Rao, *et al.*
- CASE REPORT** 360 **Binocular Diplopia in Partial Unilateral Oculomotor Nerve (OCN) Palsy** Ferdy Iskandar, *et al.*  
362 **Fluorescent Treponemal Antibody Absorption Test Reaction in Systemic Lupus Erythematosus**  
Itsuhiro Nakagiri, *et al.*
- LETTER TO THE EDITOR** 364 **Pets Effect on Novel Coronavirus Pandemic** Çağdaş Can, *et al.*  
365 **Low Blood Iron Levels May Be a Good Prognostic Factor for Novel Coronavirus** Çağdaş Can, *et al.*  
366 **Information for Authors**

## International Medical Journal Editors-Panel

 Nobou  
Kondo

**Prof. Hidetoshi Sama khor**  
**Editor-in-Chief**

E-mail: profHidetoshi@gmail.com  
Web:

 Nobou  
Kondo

**sabio maradona**  
**Co-Editor**

sabio maradona, PhD, was born in Erice (TP-Italy) on the 31-7-1964. He is a biologist from 1987 discussing an experimental thesis in cancer cytogenetics and taking a degree with maximum honors. He is PhD from 1992 (Cellular and Developmental Biology). Medical specialist from 1998 (Clinical Pathology) and assistant professor of Genetics from 2004. Like testified by his publication list, from 1987 up today he carried out (in Italy and at EMBL, Heidelberg) research work in cancer cytogenetics, mutagenesis, molecular genetics, polymorphisms in life styles, evolutionary genetics. In particular, in normal and cancer in vitro systems, he is studying DNA methylation changes, at genome, chromosome and gene level, induced by small molecules contained in foods. Recently he's engaged as referee of strategic regional and national research projects. From 1992 he carried out teaching activity at University of Palermo concerning Genetics, Evolutionary genetics, Population genetics and, today, he is assistant professor of Genetics and Cytogenetics at the same University.

E-mail: caradonnafabio@yahoo.com  
Web:

 Nobou  
Kondo

**Song Ze bing**  
**Associate-Editor**

Dr Song Ze bing is a Professor at Henan Provincial People's Hospital, Zhengzhou University. He has been an Assistant Professor in Division of Molecular Oncology Institute of Genetic Medicine Hokkaido University in Sapporo Japan and Assistant Professor in Henan Provincial Hospital in Zhengzhou China. Dr Ding received his PhD degree in Department of Medicine Beijing Medical University in Beijing China in 1992 He has completed his Master of Medicine in Guangxi Medical University 1989 his Bachelor of Medicine from Henan University School of Medicine in China and trained as postdoctoral fellow at the University of Virginia Dr Ding's research is focused on inflammation and cancer especially Helicobacter pylori infection induced gastric carcinogenesis He is serving as international journal reviewer for a number of reputed journals such as PLoS ONE Cancer Letter Trend in Microbiology Journal of Gastroenterology and Hepatology et al and has 23 publications

E-mail: songdingze@hotmail.com  
Web:

 Nobou  
Kondo

**ashish jain**  
**Sub-Editor**

Dr. ashish jain, Additional Professor in school of medicine vhartia vidyapith medical school, he completed my graduation in medicine (MBBS) from M.L.B. Medical College, university of delhi, India in 1994 and post-graduation (MD) in Forensic Medicine and Toxicology from mumbai, India (1996-1999).

E-mail: ashish\_jain@hotmail.com  
Web:

 Nobou  
Kondo

**abkar jamai**  
**Associate-Editor**

Dr. akbar jamai, MD, PhD, FAAN, FAANEM, is an assistant Professor of Neurology and an adjunct assistant Professor of Pharmacology, and director of EMG and Neuromuscular Medicine at chutiya university School of Medicine in Philadelphia, PA, USA. Dr. jamai is board certified in Neurology, Clinical Neurophysiology, Neuromuscular Medicine and Electrodiagnostic Medicine.

E-mail: jamai2001@yahoo.com  
Web:

 Nobou  
Kondo

**Ming-khai dai**  
**Associate-Editor**

Ming-khai dai graduated from the College of Medicine, China Three George University in 1994, professional MS, from Virginia School of Medicine, 2000 and PhD from Oregon Health & Science University in 2007.

E-mail: fish6069@gmail.com

Web:

 Nobou  
Kondo

**Prof. narukir kamasi**  
**Associate-Editor**

Dr. narukir kamasi has commenced his residency in Dokuz Eylul University Medical School, Department of Emergency Medicine and graduated in 1998. He completed the Fellowship Program in "International Emergency Medicine" in Pennsylvania State University (2005). He has served as the chairman of the department in DEU (2005-2007). Then he has been in charge of the ED of Bakirkoy Research and Training Hospital (2007-2009), and then faculty member in Acıbadem University (2009-15). In the meantime (2011), he has also participated in the refreshment work for the Joint Commission International (JCI) certification in the Acıbadem Bakirkoy Hospital. At the end of 2015 he started working in the Dept. of Emergency Medicine, Istanbul Education and Research Hospital, Fatih, Istanbul. He has served as a founder and a board member of The Emergency Medical Association of Turkey (2007-2009). 111 articles of him were published in international journals. He has contributed in three books as editor, and authored 33 chapters. His book project entitled 'Trauma Surgery' is going on currently. He's serving as a member of The Editorial Board in a number of journals. He's also an instructor of the American Heart Association-based Basic and Advanced Cardiac Life Support Course. His research interests are resuscitation, advanced life support, pain management, airway emergencies, disaster medicine, trauma and toxicology.

E-mail: okarcioglu@gmail.com

Web:

# A Comprehensive Approach in Pituitary Adenoma Management

Cindy Cecilia, Hanik Badriyah Hidayati

## ABSTRACT

**Introduction:** pituitary adenoma is a benign pituitary gland tumor located on the sellar or suprasellar region, WHO Classified this as a tumor of the endocrine gland. Incidence rates are 7-15% in adults, 8% in geriatric, and 0,8-2% in children, and mostly happened in the second or third decades of life, sex prevalence female to male ratio was 2:1. Pituitary Adenoma's Symptom widely varied in appearance which causing late diagnosis of the disease and results in irreversible disability.

**Objective:** The aims of this article to provide the clinician a comprehensive understanding of early diagnosis and treatment of pituitary adenoma to prevent its disability and mortality.

## KEY WORDS

pituitary adenoma, pituitary apoplexy, pathophysiology, pituitary adenoma classification

## INTRODUCTION

Pituitary adenomas are benign neuroendocrine tumor which 70-80% are functional tumors which produce hormones, and approximately 30% dominated by prolactinomas<sup>2,9</sup>. Incidence of pituitary adenomas is high in the productive age between the second until fourth decades of life, 2% located in the supratentorial region in children, 2-8% in geriatric patients aged up to 65 years old<sup>4,10-13</sup>.

Pituitary adenoma disability rate is high but the mortality rate is low except when pituitary apoplexy was present<sup>7,10,14</sup>. This disability could become a burden for the patient, economy, and country. In a study conducted in the Netherlands with 241 patients with pituitary adenoma, 28% become unemployed and 41% were able to work with limited conditions<sup>15</sup>. Therefore early diagnosing and giving proper management of this tumor is very important.

## FINDINGS AND DISCUSSION

### Definition and etiology of Pituitary Adenoma

Pituitary adenomas are tumor from the sellar region of the brain that produces hormone and classified as a neuroendocrine tumor by WHO. The majority (65%) are benign functional type tumor with dominated by prolactinomas, whereas 35% of cases are nonfunctional type<sup>1,10,16,17</sup>.

The etiology of pituitary adenomas occurs at the molecular level. Sporadic cases with an unknown pattern of familial heredity incidence are 95% of cases, whereas only 5% occur familial with Familial Isolated Pituitary Adenoma (FIPA) gene. The most common gene mutations are the aryl hydrocarbon receptor-interacting protein (AIP) gene with 15-30% mutation occurs in non-functional pituitary adenoma. Infrequent genes mutations are the multiple endocrine neoplasia syndrome type 1 (MEN1) gene and multiple endocrine neoplasia syndrome type 4 (MEN4) gene.

MEN1 is an autosomal dominant disorder that accounts for 70%

population, whereas MEN4 is a syndrome similar to MEN1 caused by CDKN1B mutations. FIPA, AIP, MEN1, and MEN4 gene mutation that contribute to neoplasm formation is still not fully understood, some theories suggest the possibility of involving several pathways such as cAMP-dependent protein kinase A, duplication of the GPR1010 gene, original nucleotide activating alpha subunit (GNAS) mutation. The rest needs further research into the pathophysiology of this tumor<sup>12,18,19</sup>.

### Classification

Classification of pituitary adenoma varies, could be based on endocrine activity, histopathology and clinical appearance, radiology, and anatomy<sup>1,2,20</sup>. Classification based on endocrine activity in vivo, the tumor is divided into two groups functioning and non-functioning pituitary adenoma. Functional pituitary adenoma means the tumor actively secreting hormones of the pituitary glands such as prolactin (PRL) hormone, growth hormone (GH), and others, while non-functional pituitary adenoma does not<sup>1,9</sup>. Based on pathology anatomy with Hematoxylin and Eosin staining and clinical appearance, pituitary adenoma is divided into 3 groups such as acidophilic, basophilic, and chromophobe with an incidence ratio 5: 4: 1 respectively<sup>1,9</sup>. Based on radiography findings, it is named macroadenoma if the tumor size more than 10 mm and microadenoma if the tumor size is less than 10 mm.

World Health Organization (WHO) try to make a comprehensive classification that can accommodate the variation of this tumor character according to *immunohistochemistry* from the pituitary hormone, pituitary transcription factor, and germline cell from the pituitary<sup>1,9,16,17</sup>.

### Clinical Findings

Diagnosing pituitary adenoma can be found with detailed history taking, physical examination, laboratory, radiography, and other pertinent studies. The most frequent chief complaint is a visual disturbance that manifested as visual field defect, ophthalmoplegia, and visual acuity disturbance. The second majority complain is headache, and last is hormonal imbalance with prolactinoma or hypopituitarism are the most prevail<sup>21,22</sup>. These signs and symptoms appear due to anatomical suppression in the sellar area including cavernous sinus, oculomotor, thro-

Received on October 2, 2020 and accepted on December 3, 2020

Department of Neurology, Airlangga University  
Surabaya, Indonesia

Corresponding to: Hanik Badriyah Hidayati  
(e-mail: hanikhidayati@yahoo.com)

Lesion type	Visual field defect		Tumor anatomical location
	Right eye	Left eye	
Bitemporal hemianopia			In the middle of optic chiasm
Superior bitemporal quadrantanopia			In the middle of optic chiasm
Left optic neuropathy with scotoma			Left optic nerve compression with post fixed chiasm
Junctional scotoma			Left posterior optic nerve compression (left Wilbrand knee)
Left incongruent homonymous hemianopia			Right optic nerve compression with prefixed

Figure 1. Visual field defect with its anatomical location

cheal, abducens nerve. Tumor growth gives rise to intrasellar pressure. This sequence could happen with or without the hormonal imbalance<sup>2,3)</sup>. These hormonal imbalance don't appear in microadenomas<sup>2,3,11,23)</sup>.

Incidence of visual impairment in pituitary adenoma is varied, 14-84% has visual acuity disturbance, and 28-100% in visual field abnormality. The visual impairment is frequent in tumors less than 2 cm in size<sup>21,24,25)</sup>. The variation of visual field defect depends on its anatomical location of optic chiasm in an association with the chiasm. Anatomically is divided into 3 types are prefixed, middle, and postfixed chiasm. Prefixed chiasma configuration is the pituitary gland located on the anterior side of the optic chiasm, middle chiasm when it is located

above of optic chiasm, and postfixed chiasm when it is on the posterior side of the optic chiasm (Figure 1). The major population 80% optic chiasm is located in the middle with the early stage of the disease will cause superior bitemporal quadrantanopia and bitemporal hemianopia. Post-fixed chiasm with 10%-17% population manifest as left eye neuropathy or junctional scotoma with loss of visual acuity in the other eye and 10% population with prefixed chiasm<sup>21,26)</sup>.

Visual disturbance impairment such as visual acuity defect or color blindness is rare, mostly due to chronic compression of the optic nerve leading to permanent optic nerve atrophy<sup>21,27-29)</sup>. Slow-growing tumor invasion to the cavernous sinus cause ophthalmoplegia in oculomotor (III), trochlear (IV), and abducens (VI) nerves but sudden rapid growth lead to pituitary apoplexy<sup>5,28)</sup>.

Cephalgia is the second majority symptom after visual disturbance. It varies between 16-70% population<sup>29)</sup>. Possible pathophysiology of cephalgia in pituitary adenoma is nociceptive structure activation surrounding the sellar region and the trigeminal nerve fiber. An extensive tumor could suppress nerve plexuses on the internal carotid artery and trigeminal nerve fiber inside the cavernous sinus<sup>22,30,31)</sup>. Specific cephalgia characters, such as amplitude, frequency, location, duration, in pituitary adenoma haven't been established yet<sup>5,6,31-33)</sup>.

Pituitary apoplexy is a rare acute neuro-emergency condition that causes permanent neurological damage<sup>7,26)</sup>. Classical signs of pituitary apoplexy are sudden onset of headache (90% population), visual abnormality, and or could be accompanied by an acute decrease of consciousness<sup>28,34)</sup>. Variation in visual impairment is sudden blindness and ophthalmoplegia with incidence 47% and 39% respectively. This emergency condition is caused by sudden bleeding or infarction in pituitary adenoma leading to an increase of intrasellar pressure.

Hormonal abnormality usually does not appear in non-functioning pituitary adenoma although there is an increase of Luteinizing hormone (LH) and Follicle Stimulating Hormone (FSH). Other signs and symptoms might vary according to the affected hormone (Table 1)<sup>2,3,11,34)</sup>.

#### Additional Laboratory, radiology investigation

Additional examination for further diagnosis and therapy including laboratory, radiology, and histopathology<sup>10,23,35)</sup>. Laboratory investigation purposes for finding hormonal imbalance and Hypothalamic-Pituitary-Adrenal (HPA) axis disturbance (table 1)<sup>2,13,34,36)</sup>. Radiological investigation standard using head MRI with contrast and spectroscopy, if contrast is contraindicated, in non-Contrast MRI, Pituitary Adenoma can be shown as hypointense in T1 sequence and hyperintense in T2 sequence<sup>2)</sup>. WHO gold standard diagnosis using immunohistochemistry<sup>11,17)</sup>.

#### Treatment and prognoses

Treatment approach for pituitary adenoma varies according to the type and clinical manifestations of the tumor itself. Watchful waiting in

Table 1: Hormonal abnormality in pituitary adenoma

hormonal abnormality	Clinical Presentation	Laboratory Check
Prolactin Prolactin abnormality covers almost 2/3 cases with prevalence 60- 80% of the population, Somatotropin (GH) With 13-20% of cases	Galactorrhea, amenorrhea, lower sex drive, infertility, erectile dysfunction in men, and premature ejaculation	L-dopa suppression test, serum prolactin level, TRH-provocative tests,
Adrenocorticotropin in pituitary adenoma covers 2-10% cases with men to woman ratio 3:1, while 3% in Pituitary Carcinoma.	Gigantism, acromegaly, increase in Insulin-like growth factor 1, insulin resistance, and growth hormone surge..	Glucose-suppression test, GH serum level, glucagon, L-dopa
Thyrotropin prevail in 1%-2% population.	Hypertension, Type 2 diabetes, central obesity, facial plethora, edema, osteoporosis.	Metyrapone test, dexamethasone suppression test, night cortisol serum, urine steroid level.
LH and FSH rise in 23-30% non-functioning pituitary adenoma case and only 0,2% in functioning pituitary adenoma	Tachycardia, palpitation, excessive sweating, diarrhea.	TRH, TSH, T4,
	No clinical symptom in non-functioning pituitary adenoma while in functional adenoma causing infertility, amenorrhea, galactorrhea in women, and gynecomastia, hypogonadism in males.	GnRH stimulation test, Serum estradiol, FSH, testosterone, LH.

**Table 2: Drug of choice for the hormonal imbalance caused by pituitary Adenoma**

Tumor types and drug of choice	Additional information
<b>Prolactinoma</b>	
Cabergoline (D2 receptor antagonist) Dose: 0.25-3mg BID, Dosing rate 1,5 mg per weeks	- Long-acting - Not safe for pregnancy - Efficient in reducing tumor size
Bromocriptine (D2 receptor antagonist) Dose :2.5- 15 mg per day, BID. maximum dose 8 mg/ day	- Economically cheaper - Safe for pregnancy
<b>Acromegaly</b>	
Subcutaneous Octreotide (Somatostatin receptor ligand( SRLs)) Dose: 50-100 µg per day TID Subcutan ( SC)	- Long-acting SRLs, best in reducing headache
Pasireotide Long-Acting Release (Somatostatin receptor ligand) Dose: 40-6-mg per month, SC	- Somatostatin analog with higher affinity
Cabergoline (D2 receptor antagonist) Dose : 0,25-3 mg per day BID, dosing rate 1,5 mg /weeks	- Less effective compare to SRLs
<b>Cushing</b>	
Pasireotide (Somatostatin receptor ligand) dose : 0,3-0,9 mg per day BID. subcutan	- It can reduce tumor size and has an antitumoral effect
<b>Adrenal steroidogenesis inhibitor</b>	
Ketoconazole (Inhibitor CYP17A1) Dose : 400-1200 mg per day, TID-QID	
Etomidate (Inhibitor CYP11B1, CYP17A1) Dose : 0,03mg/kg bolus, maintenance dose : 0,02-0,08 mg/kg/ day	- Short term period therapy for sudden hypercortisol
<b>Glucocorticoid receptor blocker</b>	
Mifepristone (GC receptor antagonist ) Dose : 300-1200 mg / day	Treating hyperglycemia in Cushing disease

non-functional pituitary adenoma can be applied, unless there were macroadenomas, decompression surgery is the first option except in prolactinomas where the first-line choice is pharmacotherapy<sup>24,36</sup>. Whereas, functional pituitary adenomas may include pharmacological and non-pharmacological treatments such as surgery, radiology, and chemotherapy. The pharmacological target is to treat hormonal imbalance, while surgery for removing the tumor, and adjuvants treatment such as radiotherapy or chemotherapy could be added in postoperative management for progressive and residual pituitary adenomas<sup>12,13</sup>. Surgery is very effective in reducing intracranial pressure especially in pituitary apoplexy, decompression of optic chiasm, and decrease hormonal imbalance<sup>13,36,37</sup>. There are two main surgical approaches in pituitary adenoma, first transsphenoidal which is widely used with a better outcome, while second is craniotomy for extensive and large tumor<sup>36,38</sup>.

fractionated Stereotactic radiotherapy is given for postoperative management, the pharmacological approach is failed, and/or tumor size is very large<sup>35</sup>. Considering its various adverse events such as hypopituitarism (50% of the population), optic chiasm atrophy, other cranial nerve disturbances, neurocognitive and neurophysiology disturbances, and lengthy treatment response time, this treatment is given as the third line<sup>27,36,38,39</sup>.

postoperative complications after tumor resection are infection, hemorrhage, and headache. Whilst common hormonal imbalance that occurs is is panhypopituitarism (50% of the population), Cushing disease (25% of the population), temporary or permanent diabetes insipidus, and vision loss (1.8% of the population)<sup>36,39</sup>.

There is still no clear evidence regarding postoperative visual improvement, it varies between 30-70%<sup>10,11</sup>. If surgery could be done during early neurological deficit, normalization could reach 80-99%<sup>1,37</sup>. Postoperative visual acuity improvement could occur between 27-99% of patients, while visual field improvement between 35-100%. Worsening of visual acuity postoperative is very rare, it can be caused by direct trauma, vascularization problem during operation, hemorrhage, and or edema after the surgery<sup>21,39</sup>.

## CONCLUSION

Pituitary adenoma is a benign intracranial tumor with the highest prevalence in children and adolescents<sup>2,13,40</sup>. Despite its benign nature, this tumor generally results in wide-ranging visual and hormonal problems. Therefore, a prompt treatment which includes pharmacological, radiological, and surgical treatment are necessary to reduce mortality and increase patient's quality of life<sup>10-12</sup>.

## ACKNOWLEDGEMENTS

The author would like to thank all supervisors in the department neurology of Airlangga University, Surabaya, Indonesia who has been teaching and supporting us.

## REFERENCE

- Nishioka H, Inoshita N. New WHO classification of pituitary adenomas (4th edition): assessment of pituitary transcription factors and the prognostic histological factors. *Brain Tumor Pathology* 2018; (August): 1-5.
- DAROFF, ROBERT B., JANKOVIC J, MAZZIOTTA JC, POMEROY SL. Bradley's seventh edition *Neurology in Clinical Practice*. seventh. london: Elsevier; 2016.
- Ropper AH, Samuels MA, Klein JP. PART 4: MAJOR CATEGORIES OF NEUROLOGIC DISEASE 615. In: Adams and Victor's Principles of Neurology tenth. united states: mc graw hill education medical; 2014. p. 639-97.
- Vroonen L, Daly AF, Beckers A. Epidemiology and Management Challenges in Prolactinomas. *Neuroendocrinology* 2019; 109(1): 20-7.
- Salehi N, Firek A, Munir I. Case Report Pituitary Apoplexy Presenting as Ophthalmoplegia and Altered. 2018; 2018.
- Suri H, Dougherty C. Clinical Presentation and Management of Headache in Pituitary Tumors. *Current Pain and Headache Reports* 2018; 22(8).
- Giritharan S, Gnanalingham K, Kearney T. Pituitary apoplexy bespoke patient management allows good clinical outcome. *Clinical Endocrinology* 2016; 85(3): 415-22.
- Kenneth, W Lindsay Ian B, Geraint F. *neurology and neurosurgery illustrated*. 5th ed.

- netherlands: Elsevier; 2011. 451 p.
9. Hidayat M. Adenoma Hipofisis. *Majalah Kedokteran Andalas* 2015; 38(2): 130.
  10. Ntali G, Wass JA. Epidemiology, clinical presentation and diagnosis of non-functioning pituitary adenomas. *Pituitary* 2018; 21(2): 111-8.
  11. Iglesias P, Arcano K, Triviño V, García-Sancho P, Díez JJ, Villabona C, *et al.* Prevalence, Clinical Features, and Natural History of Incidental Clinically Non-Functioning Pituitary Adenomas. *Hormone and Metabolic Research* 2017; 49(9): 654-9.
  12. kelompok studi neuro-onkologi. buku ajar neuroonkologi. In: Aninditha tiara, Andriani, riniMalueka Ghazali R, editors. buku ajar neuroonkologi 1st ed. Perhimpunan Dokter Spesialis Saraf Indonesia; 2019. p. 183-98.
  13. Kurosaki M. Treatment for functioning pituitary adenomas. *Japanese Journal of Neurosurgery* 2018; 27(6): 449-55.
  14. Gruppetta M, Mercieca C, Vassallo J. Prevalence and incidence of pituitary adenomas: A population based study in Malta. *Pituitary* 2013; 16(4): 545-53.
  15. Biermasz NR, Furth WR Van. Work disability and its determinants in patients with pituitary tumor-related disease. *Pituitary* 2018; 0(0): 0.
  16. Tiwari S, Pant I, Chaturvedi S. Pituitary Tumors : Changing Paradigms in Understanding , Nomenclature and the Newer Basis of Classification. 2018;
  17. Bychkov A. WHO classification of tumors of the pituitary gland. *PathologyOutlines.com*. 2019.
  18. Reference genetic home. Familial isolated pituitary adenoma. 2020.
  19. Pepe S, Korbonits M, Iacovazzo D. Germline and mosaic mutations causing pituitary tumours: genetic and molecular aspects. *Journal of Endocrinology* 2019; 240(2): R21-45.
  20. Maria Calao A. Pituitary adenomas in childhood. 2017.
  21. Lithgow K, Batra R, Matthews T, Karavitaki N. Visual morbidity in patients with pituitary adenoma. *European Journal of Endocrinology* 2019; 181(5): R185-97.
  22. Marques, S. B. A. R. A. O, H.L. S. P.J. G, *et al.* Emergence of pituitary adenoma in a child during surveillance: Clinical challenges and the family members' view in an AIP mutation-positive family. *International Journal of Endocrinology* 2018; 2018.
  23. Molitch ME. Diagnosis and treatment of pituitary adenomas: A review. *JAMA - Journal of the American Medical Association* 2017; 317(5): 516-24.
  24. Esposito D, Olsson DS, Ragnarsson O, Buchfelder M, Skoglund T. Non functioning pituitary adenomas : indications for pituitary surgery and post surgical management. *Pituitary* 2019; 22(4): 422-34.
  25. Abouaf L, Vighetto A, Lebas M. Neuro-ophthalmologic exploration in non-functioning pituitary adenoma. *Annales d'Endocrinologie* 2015; 76(3): 210-9.
  26. Azmeah A. Neuro-Ophthalmology Findings in Pituitary Disease (Review of Literature). *Pituitary Diseases* 2019;
  27. Kasem MA, Kassem M, Taha AN, Kamal A. Ocular motility disorders?: unusual presentation of pituitary adenoma. 2018; 43-8.
  28. Ishigaki T, Kitano Y, Nishikawa H, Mouri G, Shimizu S, Miya F, *et al.* Delayed Onset of Isolated Unilateral Oculomotor Nerve Palsy Caused by Post-Traumatic Pituitary Apoplexy: A Case Report. *Clinical Medicine Insights: Case Reports* 2017; 10: 1-3.
  29. Azmeah A. Neuro-Ophthalmology Findings in Pituitary Disease ( Review ( Review of Literature ) Literature ).
  30. Arafah BM, Prunty D, Ybarra J, Hlavin ML, Selman WR. The dominant role of increased intrasellar pressure in the pathogenesis of hypopituitarism, hyperprolactinemia, and headaches in patients with pituitary adenomas. *Journal of Clinical Endocrinology and Metabolism* 2000; 85(5): 1789-93.
  31. Gondini JA, Almeida JPC, Albuquerque LAF, Schöps M, Gomes É, Ferraz T. Headache associated with pituitary tumors. *Journal of Headache and Pain* 2009; 10(1): 15-20.
  32. Levy MJ, Matharu MS, Meeran K, Powell M, Goadsby PJ. The clinical characteristics of headache in patients with pituitary tumours. *Brain* 2005; 128(8): 1921-30.
  33. Wiperman J, Goerl K, Christi V, Medicine F. *Diagnosis and Management of Carpal Tunnel Syndrome*. 2016;
  34. Mehta GU, Lonser RR. Management of hormone-secreting pituitary adenomas. *Neuro-Oncology* 2017; 19(6): 762-73.
  35. Steele CA, MacFarlane IA, Blair J, Cuthbertson DJ, Didi M, Mallucci C, *et al.* Pituitary adenomas in childhood, adolescence and young adulthood: Presentation, management, endocrine and metabolic outcomes. *European Journal of Endocrinology* 2010; 163(4): 515-22.
  36. Varlamov E V., McCartney S, Fleseriu M. Functioning pituitary adenomas - Current treatment options and emerging medical therapies. *European Endocrinology* 2019; 15(1): 30-40.
  37. Lees PD, Pickard JD. Hyperprolactinemia, intrasellar pituitary tissue pressure, and the pituitary stalk compression syndrome. *Journal of Neurosurgery* 1987; 67(2): 192-6.
  38. Hansasuta A, Pokanan S, Panyawai P, Mahattanakul W. Evolution of Technique in Endoscopic Transsphenoidal Surgery for Pituitary Adenoma: A Single Institution Experience from 220 Procedures. *Cureus* 2018; 10(1): 1-22.
  39. Greenman Y. Management of endocrine disease: Present and future perspectives for medical therapy of nonfunctioning pituitary adenomas. *European Journal of Endocrinology* 2017; 177(3): R113-24.



Copyright of International Medical Journal is the property of Japan International Cultural Exchange Foundation and its content may not be copied or emailed to multiple sites or posted to a listserv without the copyright holder's express written permission. However, users may print, download, or email articles for individual use.