

Microvascular Activity from the Wound Healing Process in Wistar Rats Due to Administration of Anredera Cordifolia (Ten.) Steenis

by Christian Khoswanto

Submission date: 07-Mar-2022 09:30AM (UTC+0000)

Submission ID: 1778427880

File name: cular_activity_from_the_wound_healing_process_in_wistar_rats.pdf (1.87M)

Word count: 3400

Character count: 18636

26
**Microvascular Activity from the Wound Healing Process in Wistar Rats
Due to Administration of *Anredera Cordifolia* (Ten.) Steenis**

Christian Khoswanto^{1*}

1. Department of Oral Biology Faculty of Dentistry, Airlangga University, Surabaya – Indonesia.

Abstract

Post-tooth extraction can cause complications that can occur several days or even weeks after tooth extraction, dry socket and infection bleeding are some of the complications that can occur after tooth extraction. For this reason, a drug is needed that can accelerate healing of wounds without causing complications. The aim of this study was to investigate Microvascular activity from the wound healing process in wistar rats due to administration of *Anredera cordifolia* (Ten.) Steenis.

This study is an experimental laboratory research using The Post-Test Only Control Group Design. 40 male Wistar Rats weigh between 150-200 grams, 3 months of age are being used. All animal procedures were approved by the University of Airlangga Surabaya Animal Care and Use Committee. The 40 rats are divided into two groups. In the first group, after the extraction is done, *Anredera cordifolia* (Ten.) Steenis 10% is applied on the extraction wound. In the second group, bone graft is applied to the extraction wound as control group.

The result on the 3rd and 7th day examined via a light beam that is transmitted through the tissue using image magnified 200 times shows that the expression of VEGF-A and amount of microvascular on the group which is given *Anredera cordifolia* (Ten.) Steenis Gel is much more than the control group. The result shows there is significant difference in each group treatment $p < 0.05$ ($p = 0.001$).

The application of 10% *Anredera cordifolia* (Ten.) Steenis gel can accelerating microvascular activity from the wound healing process in Wistar Rats.

Experimental article (J Int Dent Med Res 2021; 14(4): 1351-1356)

Keywords: VEGF-A, Microvascular and *Anredera cordifolia* (Ten.) Steenis gel.

Received date: 18 June 2021.

Accept date: 05 August 2021

Introduction

Wounds to the body basically involve soft tissues, hard tissues and even involving both. Wounds to tooth extraction involve soft and hard tissue. Tooth decay of the Indonesian population in the age group who have undergone permanent tooth changes over the age of 12 years, according to recent research in shows that on average 4 teeth per person have been revoked.¹ Tooth extraction is an action that is often experienced by patients who experience tooth decay that cannot be maintained by a dentist. Post-tooth extraction can cause

complications that can occur several days or even weeks after tooth extraction. Post-extraction, dry socket and infection bleeding are some of the complications that can occur after tooth extraction.² For this reason, a drug is needed that can accelerate healing of wounds without causing complications. Experimental animals that are often used to examine wound healing are mice, because these animals are able to survive after being given treatment.³⁻⁴ Until now, humans have relied heavily on the surrounding environment to meet their needs, knowledge of medicinal plants based on experience and skills that have been passed down from generation to generation. Plants produce various kinds of active compounds that provide pharmacological effects. This metabolite has long been known as an effective and important source of medical therapy, for example as an anti-bacterial and anti-cancer drug. This compound continues to be the main source of various important efficacious drugs. In the practice of traditional medicine,

***Corresponding author:**

Christian Khoswanto,
Department of Oral Biology Faculty of Dentistry,
Airlangga University, Jln. Mayjend.
Prof. Dr. Moestopo No. 47 Surabaya 60132, Indonesia.
E-mail : christiankhoswanto@hotmail.com

people have used active compounds from various plants in the form of medicinal herbs, to cure diseases. Active compounds in plants have become a source of inspiration for the treatment of diseases that are difficult or expensive for treatment.⁵

Traditional medicine using plants has always been used by the Indonesian people, one of which is binahong or *Anredera cordifolia* (Ten.) Steenis. Research on ethanol extract of *Anredera cordifolia* (Ten.) Steenis leaves which have been carried out previously showed the results that a 10% concentration can increase the expression of HIF 1 α in tooth extraction wound.⁶ The flavanoid content of quercetin and other substances is found in the leaves of *Anredera cordifolia* (Ten.) Steenis.⁷ Quercetin is an active compound that can increase the expression of HIF-1 α and VEGF-A. VEGF-A expression is one of the mediators of ossification in the body.⁸

Research on the use of ethanol extract of the leaves of *Anredera cordifolia* (Ten.) Steenis as an alternative wound healing in the oral cavity, especially in wound healing after tooth extraction until the stage of protein expression around the alveolar bone after tooth extraction has never been done. The process of wound healing in animals and humans is the same, namely through the phase of hemostasis, inflammation, proliferation, and maturation.

Materials and methods

This study is an experimental laboratory research using The Post-Test Only Control Group Design. 40 male Wistar Rats weigh between 150-200 grams, 3 months of age are being used. Have well condition, food and drink water given ad libitum. All animal procedures were approved by the University of Airlangga Surabaya Animal Care and Use Committee. This kind of animal is used because tooth extraction on Wistar Rats is easier with sufficiently wide socket extraction wound for applying *Anredera cordifolia* (Ten.) Steenis Gel. Tooth extraction is being done on lower left incisor. The choosing of lower incisor is based on the structure and anatomical form of Rat's teeth which enable extraction to be done. The 40 rats are divided into two groups. In the first group, after the extraction is done, *Anredera cordifolia* (Ten.) Steenis 10% is applied on the extraction wound. In the second group, bone graft is applied to the

extraction wound as control group.

Anredera cordifolia (Ten.) Steenis leaf which is made into gel form will be easier to be put into the extraction wound socket because of its solid, soft and elastic characteristics. This gel forms makes the substance durable in extraction wound socket, so that it helps the body in wound recovery process. The making of *Anredera cordifolia* (Ten.) Steenis Gel is uses the mixture of HPMC and distillation of *Anredera cordifolia* (Ten.) Steenis leaf. The characteristics of HPMC are for thickening, stabilizer, gel maker and in some things as emulsifiers. In hydrocolloid emulsion system it doesn't function as emulsifiers, but more as substance which gives stabilization. This HPMC is easily soluble in hot or cold water, so it is easy to use. It is used as stabilizer because it's easily obtainable and also reasonably priced.^{6,9}

Animal's mandible were decapitated at intervals of 3 and 7 days after extraction by median-sagittal cut, samples that had been detached from the body then fixated, Buffered isotonic solution of 10% formaldehyde was used for fixatives. 96% ethanol was used to extracted the water from the fragment. The ethanol then replaced with a solvent miscible with the embedding medium. In paraffin embedding, the solvent used is xylene. Once the tissue is impregnated with the solvent, it is placed in melted paraffin in the oven at 58-60°C. The heat causes the solvent to evaporate, and the space within the tissue become filled with paraffin. The tissue together within its impregnating paraffin hardens taken out of the oven. Tissues embedded with plastic resin dehydrated in ethanol. The hard blocks containing the tissues are then taken to a microtome, and sliced into thin sections 4-5 μ m. The sections are floated on water and transferred to glass slide to be stained. Staining tissue with Hematoksillin-Eosin and an anti-VEGF-A antibody (Novusbio, USA) was done to make the various tissue component conspicuous. Under the light microscope (Olympus, JAPAN) tissue are examined via a light beam that is transmitted through the tissue using image magnified 400 times.⁶

Results

The mean and standard deviation of the expression of VEGF-A and number of microvascular post extraction in Wistar Rats is

shown in the table 1 and table 2. A Kolmogorof Smirnov test was carried out on the data to determine the normality of distribution. The result of every tested group showed $p > 0.05$, therefore all the data had a normal distribution.

Group	X±SD Day 3	X±SD Day 7
10% K	17.30 ^a ±2.75	14.50 ^a ±2.99
K	8.10 ^b ±3.34	8.60 ^b ±2.36

Table 1. Mean expression of VEGF-A in treatment group and control group.

Note : different superscript showed significance difference ($\alpha < 0.05$).

Group	X±SD Day 3	X±SD Day 7
10% K	22.30 ^a ±3.36	19.30 ^a ±3.09
K	12.80 ^b ±2.14	12.10 ^b ±2.60

Table 2. Mean number of microvascular in treatment group and control group.

Note : different superscript showed significant difference ($\alpha < 0.05$).

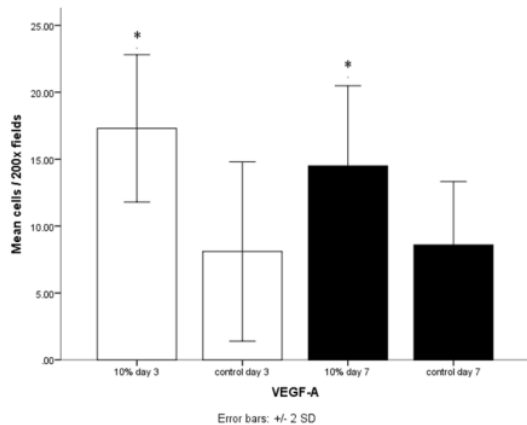


Figure 1. Data showing the expression of VEGF-A per 200 field in treated for 3 & 7 days. *show significant different between control & treatment group ($P < 0.05$).

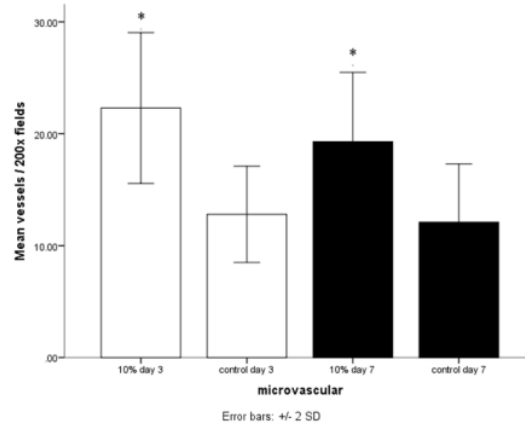


Figure 2. Data showing the number of microvascular vessels per 200 field in treated for 3 & 7 days. *show significant different between control & treatment group ($P < 0.05$).

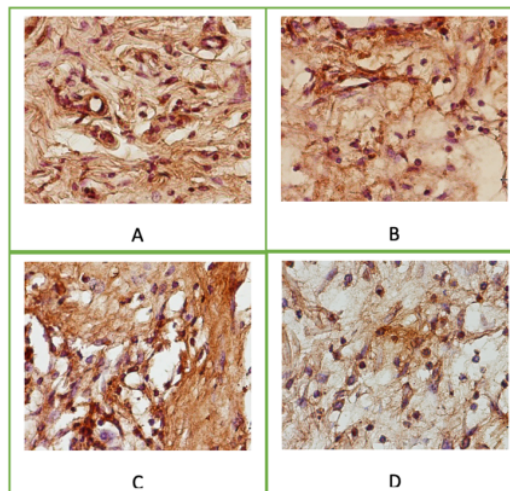


Figure 3. Expression of VEGF-A in socket after tooth extraction on day 3 & 7 with 200x magnification light microscope. (A). ethanol extract of Anredera cordifolia (Ten.) Steenis 10% day 3 (B). control group day 3. (C). ethanol extract of Anredera cordifolia (Ten.) Steenis 10% day 7 (D) control group day 7.

Therefore, they were analyzed using independent sample t-test, considering $p < 0.05$ as significant. The result on the 3rd and 7th day examined via a light beam that is transmitted through the tissue using image magnified 200 times shows that the expression of VEGF-A and

amount of microvascular on the group which is given Anredera cordifolia (Ten.) Steenis Gel is much more than the control group (Figure 1,2,3 & 4). The result shows there is significant difference in each group treatment $p < 0.05$ ($p = 0.001$).

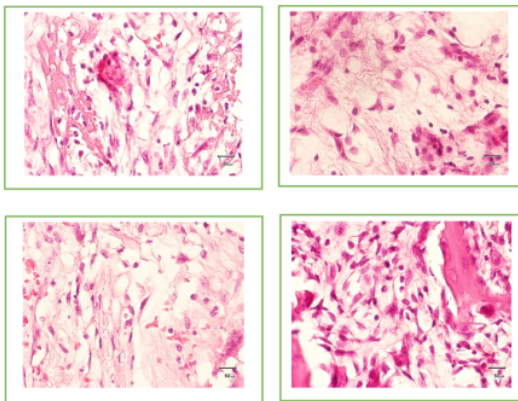


Figure 4. Microvascular number in socket after tooth extraction on day 3 & 7 with 200x magnification light microscope. (A). ethanol extract of Anredera cordifolia (Ten.) Steenis 10% day 3 (B). control group day 3. (C). ethanol extract of Anredera cordifolia (Ten.) Steenis 10% day 7 (D) control group day 7.

Discussion

Wounds to the body is a common occurrence, both soft and hard tissue injuries. Injuries involving soft and hard tissues such as wounds on tooth extraction need to be considered. Given this wound healing takes longer, so the incidence of complications is more likely to occur. The wound will go through several stages in achieving recovery, including: stages of hemostasis, inflammation, proliferation, and remodeling.¹⁰ Hemostasis occurs immediately after tooth extraction occurs, used socket after tooth extraction will be filled with blood and then blood clot is formed. The stage of inflammation is the body's response stage to clean the wound area from foreign objects, bacteria and dead cells to prepare for the start of the healing process. At the beginning of this phase the inflammatory response is characterized by the number of polymorphonuclear neutrophils, the leukocytes cells around inflammatory tissues and macrophages. This phase starts from day 1 to

day 3 after injury. The function of macrophages in addition to phagocytosis is collagen synthesis, granulation tissue formation together with fibroblasts, producing VEGF-A growth factors that contribute to the formation of new capillary vessels or angiogenesis. The process of angiogenesis is an important factor in wound healing.¹¹ The formation of new blood vessels or angiogenesis is stimulated by VEGF-A and synthesizes endothelial cell formation in the wound area. Angiogenesis is the initial process needed by osteogenesis. New bone formation is always associated with the availability of blood vessels.

The result of VEGF-A expression and the microvascular by the 3rd day increased significance because of the response of the wound area after tooth extraction experienced in the bone formation through the cellular mechanism of VEGF-A formation. Damaged blood vessels and formed platelets form the fibrin clot. Fibrin tissue and platelet assemblages are formed to cover damaged blood vessels and repair. Active platelets release many cytokines, including VEGF-A. which will accumulate in blood vessels and platelets will activate chemical mediators in inflammatory responses such as neutrophils, macrophages, endothelial cells and fibroblasts. Phagocytic cell infiltration in the injured area after tooth extraction requires an active metabolic process and results in increased oxygen demand, so that the oxygen supply is reduced in the wound, hypoxia will occur in the wound area. Active macrophages and platelets release angiogenic factors such as VEGF-A in the injured area. VEGF-A stimulates endothelial cells to form new blood vessels in injured areas that experience hypoxia.¹² VEGF-A is an important mediator in embryogenesis, angiogenesis, wound healing, soft and hard tissue remodeling. VEGF-A is produced by several cell types which have a role in wound healing, including: endothelial cells, fibroblasts, smooth muscle cells, platelets, neutrophils, macrophages, osteoblasts, osteoclasts and chondrocytes. VEGF-A release response in the wound healing process was also carried out by platelets which were the first vascular component in the wound area, followed by neutrophils and macrophages.¹³⁻¹⁴ VEGF-A expression and the number of microvascular that formed significantly compared to the control group showed the response of the wound area after tooth extraction

had improved and the formation of new blood vessels faster and towards the repair process so that the supply of oxygen and nutrients in the wound tissue became better. VEGF-A plays an important role in the healing process of tooth extraction wounds through stimulation of new blood vessel formation or angiogenesis, which includes several stages such as vasodilation, basement membrane degradation, endothelial cell migration and proliferation.^{13,15} VEGF-A increases vascularization of new blood vessels, also stimulates mesenchymal cells in the connective tissue. VEGF-A is a potent stimulator in the process of angiogenesis. Its formation is stimulated by growth factors and the main thing that plays an important role is stimulation by hypoxia and HIF-1 α . This protein stimulates several processes, such as: proliferation, capillary formation and endothelial cell migration to the chemotactic area.¹⁵ Several factors involved in the wound healing process bind to several receptors such as VEGFR1, VEGFR2 and VEGFR3 which are expressed on the surface of endothelial cells. The relationship of receptors and ligands activates cells and stimulates the formation of new capillaries.^{6,16-17}

VEGF-A expression and the number of microvascular in the 7th day alveolar socket after administration of ethanol extract of the leaves of *Anredera cordifolia* (Ten.) Steenis with a dose of 10% showed a higher VEGF-A expression and the number of microvascular than the control group, this was related to the formation of new blood vessels that still took place in Day 7 for a healing response in the alveolar bone that takes longer than healing in soft tissue.¹⁸ The development of new blood vessel responses has three phases: the non-proliferation phase in the formation of new blood vessels, the proliferation phase with the formation of new blood vessels to achieve maximum and decreased phase growth in blood vessel density due to the completion of new blood vessel formation. VEGF-A expression can stimulate bone regeneration not only through the process of angiogenesis, but also through osteogenic differentiation by mesenchymal stem cells.^{12,19-22}

Conclusions

The application of 10% *Anredera cordifolia* (Ten.) Steenis gel can accelerating microvascular activity such as expression of

VEGF-A and angiogenesis from the wound healing process in Wistar Rats.

Authors Contribution

Khoswanto C carried out the main research works and the main data in the experiments and approved the final manuscript.

Acknowledgments

The authors are very thankful to Faculty of dentistry Airlangga University and Faculty of Veterinary medicine Airlangga University for providing all the type of facilities to conduct this research.

Declaration of Interest

This research did not receive any specific grant from funding agencies in the public, commercial, or not-for-profit sectors.

References

1. Laporan Riset Kesehatan Dasar (RISKESDAS). DEPKES RI. 2013; pp. 110-119.
2. Wray D, Stenhouse D, Lee D & Clark AJE. *Textbook of General and Oral Surgery*, Elsevier Churchill Livingstone, 2003:208-211.
3. Balqis U, Darmawi, Iskandar CD, Salim MN. Angiogenesis activity of *Jatropha curcas* L. latex in cream formulation on wound healing in mice, *Veterinary World*, 2018;11(7):939-943.
4. Yuniarti WM, Lukiswanto BS. Effects of herbal ointment containing the leaf extracts of Madeira vine (*Anredera cordifolia* (Ten.) Steenis) for bum wound healing process on albino rats, *Veterinary World*, 2017;10(7): 808-813.
5. Oktora L, Pemanfaatan Obat Tradisional dengan Pertimbangan Manfaat dan Keamanannya, *Majalah Ilmu Kefarmasian*, 2006;3(1):1-7.
6. Khoswanto C, Soehardjo I, The effect of Binahong Gel (*Anredera cordifolia* (Ten.) Steenis) in accelerating the escalation expression of HIF-1 α and FGF-2, *Journal of International Dental and Medical Research*, 2018;11(1):303-307.
7. Yang RY, Lin B & Kuo G. Content and distribution of flavonoids among 91 edible plant species, *Asia Pac J Clin Nutr*, 2008;17: 275-9.
8. Jeon H, Kim H, Choi D, Kim D, Park SY, Kim YJ, Kim YM & Jung Y. Quercetin Activates an Angiogenic Pathway, Hypoxia Inducible Factor (HIF)-1-vascular endothelial growth factor, by inhibiting HIF-Prolyl Hydroxylase: a structural analysis of quercetin for Inhibiting HIF-Prolyl Hydroxylase, *Mol Pharmacol*, 2007;71: 1676-84.
9. Astuti SM, Mimi SAM, Retno ABM, & Awalludin R. Determination of Saponin Compound from *Anredera cordifolia* (Ten.) Steenis (*Binahong*) to potential treatment for several diseases, *Journal of Agricultural Science*, 2011; 3(4): 224-32.
10. Olczyk P, Mencner L & Vassev KK. The Role of the Extracellular Matrix Components in Cutaneous Wound Healing, *BioMed Research International*, 2014;1: 1-8.
11. Tortora GJ. *Principles of Anatomy and Physiology*, 14th ed. Wiley, 2013;pp.85-86.
12. Nanci A. *Oral Histology : Development, Structure and Function*. 8th ed. Mosby, Missoun, 2012;pp.50-60.

13. Bao P, Arber KA, Canic MT, Golinko MS, Ehrlich HP & Brem H. The Role of Vascular Endothelial Growth Factor in Wound Healing, *J Surg Res*, 2009;153(2):347-58.
14. Waris V, Sillat T, Waris E, Virkki L, Mandelin J, Takagi M & Kontinen YT. Role and Regulation of VEGF and Its Receptors 1 and 2 in the Aseptic Loosening of Total Hip Implants, *Journal Of Orthopaedic Research*, 2012;30(11):1830-6.
15. Vieira,AE, Repeke CE, Junior SBF, Colavite PM, Bigueti CC, Oliveira RC, Assis GF, Taga R, Trombone APV & Garlet GP. Intramembranous Bone Healing Process Subsequent to Tooth Extraction in Mice: Micro-Computed Tomography, Histomorphometric and Molecular Characterization, *Plos One*, 2015;10(5):371-89.
16. Rafiei M, Sadeghian S, Nakisa Torabinia N, Hajhashemi V. Systemic effects of fluoxetine on the amount of tooth movement, root resorption, and alveolar bone remodeling during orthodontic force application in rat. *Dental Research Journal*, 2015;12(5): 482-487.
17. Rezvani HR, Ali N, Nissen LJ, Harfouche G, Verneuil HD, Tai'eb A & Mazurier F. HIF-1a in Epidermis: Oxygen Sensing, Cutaneous Angiogenesis, Cancer, and Non-Cancer Disorders, *Journal of Investigative Dermatology*, 2011;131: 1793-1805.
18. Khoswanto C. A new technique for research on wound healing through extraction of mandibular lower incisors in Wistar rats. *European journal of dentistry*. 2019; 13 (02): 235-237.
19. Behr B, Tang C, Germann G, Longaker MT, Quarto N. Locally applied vascular endothelial growth factor-A increases the osteogenic healing capacity of human adipose-derived stem cells by promoting osteogenic and endothelial differentiation, *Stem Cells*, 2011;29: 286-296.
20. Ezoddini-Ardakani F, Navabazam A, Fatehi F, Danesh-Ardekani M, Khadem S, Rouhi G. Histologic evaluation of chitosan as an accelerator of bone regeneration in microdrilled rat tibias, *Dental Research Journal*, 2012; 9(6) :694-699.
21. Bedeloglu E, Ersanlı S, Arisan V. Vascular endothelial growth factor and biphasic calcium phosphate in the endosseous healing of femoral defects: An experimental rat study, *Lournal of Dental Science*, 2017;12: 7-13.
22. Sun R, Li L, Yao H, Chen Y, Li P, Sun J, Qin Y, Wang X, Wang Q. Association between body constitution type and vascular endothelial dysfunction: A cross-sectional study in an adult obese/ overweight population. *Journal of Traditional Chinese Medical Science*, 2018, 5: 94-99.

Microvascular Activity from the Wound Healing Process in Wistar Rats Due to Administration of Anredera Cordifolia (Ten.) Steenis

ORIGINALITY REPORT

22%
SIMILARITY INDEX

18%
INTERNET SOURCES

13%
PUBLICATIONS

6%
STUDENT PAPERS

PRIMARY SOURCES

1 www.medlabscience.blogfa.com **4%**
Internet Source

2 ejurnal.stikes-bth.ac.id **3%**
Internet Source

3 www.thieme-connect.com **1%**
Internet Source

4 G C T Manurung, Y Hasanah, C Hanum, L Mawarni. " The role of bamboo shoot and shallot extracts combination as natural plant growth regulator on the growth of binahong ((Ten.) Steenis.) in Medan ", IOP Conference Series: Earth and Environmental Science, 2020 **1%**
Publication

5 Submitted to Koforidua Technical University **1%**
Student Paper

6 innovareacademics.in **1%**
Internet Source

7	Internet Source	1 %
8	id.scribd.com Internet Source	1 %
9	jurnal.pdgi.or.id Internet Source	1 %
10	jurnal.unsyiah.ac.id Internet Source	1 %
11	worldwidescience.org Internet Source	1 %
12	www.ncbi.nlm.nih.gov Internet Source	1 %
13	Hamid R Rezvani. "HIF-1 α in Epidermis: Oxygen Sensing, Cutaneous Angiogenesis, Cancer, and Non-Cancer Disorders", Journal of Investigative Dermatology, 09/2011 Publication	1 %
14	Lucía Fátima Souza, Ingrid Bergman Inchausti de Barros, Emilia Mancini, Laura De Martino, Elia Scandolera, Vincenzo De Feo. " Chemical Composition and Biological Activities of the Essential Oil from Grown in Brazil ", Natural Product Communications, 2014 Publication	1 %

15	Internet Source	1 %
16	Submitted to University of Sydney Student Paper	<1 %
17	armaghanj.yums.ac.ir Internet Source	<1 %
18	dehistology.blogspot.com Internet Source	<1 %
19	assets.researchsquare.com Internet Source	<1 %
20	www.nature.com Internet Source	<1 %
21	D. N. Streblow, J. Dumortier, A. V. Moses, S. L. Orloff, J. A. Nelson. "Chapter 22 Mechanisms of Cytomegalovirus-Accelerated Vascular Disease: Induction of Paracrine Factors That Promote Angiogenesis and Wound Healing", Springer Science and Business Media LLC, 2008 Publication	<1 %
22	eprints.keele.ac.uk Internet Source	<1 %
23	Edible Medicinal and Non Medicinal Plants, 2014. Publication	<1 %

24 Ville Waris. "Role and regulation of VEGF and its receptors 1 and 2 in the aseptic loosening of total hip implants", Journal of Orthopaedic Research, 2012
Publication <1 %

25 ejomr.org
Internet Source <1 %

26 eprints.rums.ac.ir
Internet Source <1 %

27 f1000research.com
Internet Source <1 %

28 www.thieme-connect.de
Internet Source <1 %

29 Lauryn Samelko, Marco S. Caicedo, Seung-Jae Lim, Craig Della-Valle, Joshua Jacobs, Nadim J. Hallab. "Cobalt-Alloy Implant Debris Induce HIF-1 α Hypoxia Associated Responses: A Mechanism for Metal-Specific Orthopedic Implant Failure", PLoS ONE, 2013
Publication <1 %

30 Olivia Avriyanti Hanafiah, Diana Sofia Hanafiah, Gostry Aldica Dohude, Denny Satria et al. "Effects of 3% binahong (*Anredera cordifolia*) leaf extract gel on alveolar bone healing in post-extraction tooth socket wound <1 %

in Wistar rats (*Rattus norvegicus*)",
F1000Research, 2021

Publication

31

Nuryantini, Ade Yeti, Muhammad Miftahul
Munir, Annisa Rahma, Tri Suciati, and
Khairurrijal. "Poly(Vinyl Alcohol)/Chitosan
Nanofibrous Membrane Containing *Anredera
cordifolia* (Ten.) Steenis", *Advanced Materials
Research*, 2015.

<1 %

Publication

Exclude quotes Off

Exclude matches Off

Exclude bibliography On

Microvascular Activity from the Wound Healing Process in Wistar Rats Due to Administration of Anredera Cordifolia (Ten.) Steenis

GRADEMARK REPORT

FINAL GRADE

/0

GENERAL COMMENTS

Instructor

PAGE 1

PAGE 2

PAGE 3

PAGE 4

PAGE 5

PAGE 6
