

FOLIA MEDICA INDONESIANA

Vol. 55 No. 3 September 2019

COMPARISON OF THE EFFECTIVENESS OF TOMATO (*Lycopersicon commune*) AND RED MELON (*Cucumis melo* L.) JUICE IN INCREASING VAGINAL WALL THICKNESS OF MENOPAUSAL RATS MODEL
(Yheni Widjayanis, Arief Widya Prasetya)

COMPARISON OF PPT AND APTT IN PRE AND POST-HEMODIALYSIS PATIENTS AS THE HEPARIN-EXPOSED EFFECT
(Yetti Hermaningsih, Widodo, Koko Aprianto)

THE EFFECT OF VITAMIN E SUPPLEMENTATION ON MUSCULAR FATIGUE IN PROFESSIONAL MEN'S ATHLETICS
(Yusni, Aminuddin)

ACCELERATION OF BONE FRACTURE HEALING THROUGH THE USE OF NATURAL BOVINE HYDROXYAPATITE IMPLANT ON BONE DEFECT ANIMAL MODEL
(Junaidi Khoib, Cantika SC Lasandara, Samirah, Aniek S Budiati)

LEAF AND PETIOLE EXTRACT OF *Cantella asiatica* ARE POTENTIAL FOR ANTIFERTILITY AND ANTIMICROBIAL MATERIAL
(Susie Amilah, Sukarjati, Diaz P Rachmatin, Masruruh)

HUMAN SPERM MOTILITY, VIABILITY, AND MORPHOLOGY DECREASED AFTER CRYOPRESERVATION
(Ninik Darsini, Berliana Hamidah, Seso Sulijaya Suyono, Faisal Yusuf Ashari, R Hanjanto Aswin, Rina Yudiwati)

THE INFLUENCE OF PSYCHOCURATIVE ON CORTISOL LEVEL, ANXIETY, AND QUALITY OF LIFE IN ADVANCED STAGE CERVICAL CANCER PATIENTS
(Soetrisno, Sri Mulyani, Angesi Nugrahani, Haf Nurinesari, Erindra Budi)

EVALUATION OF KI-67, APOPTOSIS, AND HYALURONIC ACID IN GRADING RETINOBLASTOMA
(Hendrian D. Soetajaja, Nurwasis, Ugroseno Y. Bintoro, Sulman B. Soemirto)

EFFECT OF COMBINATION SOY BEAN OIL AND OLEIC ACID TO CHARACTERISTIC, PENETRATION, PHYSICAL STABILITY OF NANOSTRUCTURE LIPID CARRIER RESVERATROL
(Widji Soeratri, Rohmawati Hidayah, Noorma Rosita)

DETERMINANTS OF MATERNAL AND CHILD HEALTH HANDBOOK UTILIZATION IN SURABAYA, INDONESIA
(Invento, Ilham Hidar, Indah Luslya, Windu Purnomo)

THE INFLUENCE OF HEALTH EDUCATION ON DIABETES MELLITUS ON KNOWLEDGE IMPROVEMENT OF DIABETES MELLITUS CADRES IN THE WORKING AREA OF MEDOKAN AYU HEALTH CENTER, SURABAYA, INDONESIA
(Suziawati Andjani)

Case report:
DENTIGEROUS CYST AND CANINE IMPACTION AT THE ORBITAL FLOOR
(Ferdian Rizky Hutomo, Ellen Saaja Pratiwi, Viskesari P. Katarjati Andri Rizqianan)

Case report:
MANAGEMENT OF PROGRESSIVE LUNG CANCER PATIENTS AFTER FIRST-LINE EGFR TYROSINE KINASE INHIBITOR THERAPY
(Sahrul, Lekemi Wulandari)

International Online Distribution by ProQuest™
www.proquest.com

[Home](#) > [About the Journal](#) > [Editorial Team](#)

EDITORIAL TEAM

EDITOR-IN-CHIEF

[Kuntaman Kuntaman](#), Department of Clinical Microbiology, Universitas Airlangga, Surabaya, Indonesia; PAMKI (Perhimpunan Dokter Spesialis Mikrobiologi Klinik Indonesia), Indonesia

ASSOCIATE EDITORS

[Viskasari Pintoko Kalanjati](#), Department of Anatomy Histology and Pharmacology, Faculty of Medicine, Universitas Airlangga, Indonesia; International Federation of Associations of Anatomists (IFAA)

EDITORIAL BOARD

[Lucky Prasetiowati](#), PAAI, Indonesia

[Muhammad Miftahussurur](#), Universitas Airlangga, Indonesia; Baylor College Medicine, Houston, US

[Yoshio Yamaoka](#), Oita University, Japan

[Anucha Thatrimontrichai](#), Prince of Songkla University, Thailand Surasak Sangkhathat, Pediatric Surgery Unit, Department of Surgery, Prince of Songkla University, Songkhla, Thailand

[Purwo Sri Rejeki](#), Department of Physiology and Biochemistry, Faculty of Medicine, Universitas Airlangga, Surabaya, Indonesia

[Delvac Oceanady](#), Division of Cardiovascular Sciences, Faculty of Biology, Medicine, and Health, The University of Manchester, Manchester, United Kingdom

[Andrew Paul Smith](#), Centre for Occupational and Health Psychology, School of Psychology, Cardiff University, Cardiff, United Kingdom

[Franco Servadei](#), Department of Neurosurgery, Humanitas University, Italy

[Marten J Postma](#), Faculty of Science, Swammerdam Institute for Life Sciences, University of Amsterdam, Netherlands

[Aryati Aryati](#), PDS PATKLIN, Indonesia

[Dirk Jan Marie de Ridder](#), Department of Development and Regeneration, Katholieke Universiteit Leuven, Belgium

[Horie Shigeo](#), Department of Urology, Faculty of Medicine, Juntendo University, Japan

[Yusuke Suzuki](#), Department of Nephrology, Faculty of Medicine, Juntendo University, Japan

[Hiroaki Kimura](#), Department of Physical Medicine and Rehabilitation, Hiroshima University Hospital, Japan

[Bambang Purwanto](#), Master Program of Sport Medicine, Dr. Soetomo General Academic Hospital, Indonesia

[Arend Frederik Bos](#), Division Neonatology, Faculty of Medical Sciences, University of Groningen, Netherlands

[Azimatul Karimah](#), Dr. Soetomo General Academic Hospital, Surabaya, Indonesia

[Reny T'ishom](#), Department of Biomedical Sciences, Faculty of Medicine, Universitas Airlangga, Surabaya, Indonesia

[Christianto Lumenta](#), Bogenhausen Academic Teaching Hospital, Technical University, Munich, Germany

[Inwanto Irwanto](#), Department of Child Health, Universitas Airlangga, Indonesia

[Jitti Hanprasertpong](#), Division of Gynecologic Oncology, Department of Obstetrics and Gynecology, Faculty of Medicine, Prince of Songkla University, Hat Yai, Songkhla, Thailand

[Surasak Sangkhathat](#), Pediatric Surgery Unit, Department of Surgery, Prince of Songkla University, Songkhla, Thailand

[Brahmaputra Marjadi](#), Western Sydney University, Penrith, Australia

[Asra Al Fauzi](#), PERSPEBSI (Perhimpunan Spesialis Bedah Saraf Indonesia- INS), Indonesia; Surabaya Neuroscience Institute (SNeI), Indonesia

[Wihasto Suryaningtyas](#), PERSPEBSI, Indonesia; Dr. Soetomo General Academic Hospital, Indonesia

[Siti Khaerunnisa](#), Department of Physiology and Medical Biochemistry, Faculty of Medicine, Universitas Airlangga, Surabaya, Indonesia

ASSISTANT EDITORS

[Achmad Naufal Irsyadi](#), Unit Konsorsium Jurnal dan Folia Medica Indonesiana, Indonesia

[Alfiananda Dwi Oktora Nugraheni](#), Unit Konsorsium Jurnal dan Folia Medica Indonesiana, Indonesia

Indexed By



This work is licensed under a [Creative Commons Attribution-NonCommercial-ShareAlike 4.0 International License](#).

00233016 [View My Stats](#)

ISSN

Printed ISSN

Electronic ISSN

Instruction for Author

[How to Submit](#)

[Guidelines for Authors](#)

[Online Submission](#)

[Document Template](#)

[CTA & Author Statement](#)

Journal Policy

[Focus and Scope](#)

[Publication Ethics](#)

[Article Processing Charge](#)

[Editorial Team](#)

[Peer Reviewers](#)

[Peer Review Process](#)

[Peer Review Process Flowchart](#)

[Open Access Statement](#)

[Plagiarism Check](#)

[Archiving](#)

[Copyright](#)

[Repository Policy](#)

[Contact](#)

[Old Website](#)

Journal Standing

Scopus[®]

Reference Manager



Plagiarism Checker



External Links



In Collaboration with



Accreditation Certificate



OPEN JOURNAL SYSTEMS

Journal Help

USER

Username

Password

Remember me

NOTIFICATIONS

[View](#)

[Subscribe](#)

JOURNAL CONTENT

Search

Search Scope

All

Browse

[By Issue](#)

[By Author](#)

[By Title](#)

[Other Journals](#)

FONT SIZE

INFORMATION

[For Readers](#)

[For Authors](#)

[For Librarians](#)

Visitors

 ID 51,812	 PH 801
 US 6,977	 AU 724
 IN 1,731	 GB 656
 MY 971	 TH 571
 JP 849	 CA 484

Pageviews: 275,117



Pusat Pengembangan Jurnal dan Publikasi Ilmiah
Universitas Airlangga
copyright@2017 Template PPJPI

[Home](#) > [Archives](#) > **Vol 55, No 3 (2019)**

VOL 55, NO 3 (2019)

SEPTEMBER

TABLE OF CONTENTS

FRONT MATTER

Front Matter Vol. 55, No. 3 September (2019)

PDF

BACK MATTER

Back Matter Vol. 55, No. 3 September (2019)

PDF

ARTICLES

Comparison of the Effectiveness of Tomato (*Lycopersicum commune*) and Red Melon (*Cucumis melo* L.) Juice in Increasing Vaginal Wall Thickness of Menopausal Rats Model

PDF
159-165

 [10.20473/fmi.v55i3.15490](https://doi.org/10.20473/fmi.v55i3.15490)

Yhenti Widjayanti, Arief Widya Prasetya

Comparison of PPT and APTT in Pre and Post-Hemodialysis Patients as the Heparin-Exposed Effect

PDF
166-170

 [10.20473/fmi.v55i3.15491](https://doi.org/10.20473/fmi.v55i3.15491)

Yeti Hernaningsih, Widodo Widodo, Koko Aprianto

The Effect of Vitamin E Supplementation on Muscular Fatigue in Professional Men's Athletics

PDF
171-175

 [10.20473/fmi.v55i3.15493](https://doi.org/10.20473/fmi.v55i3.15493)

Yusni Yusni, Amiruddin Amiruddin

Acceleration of Bone Fracture Healing through the Use of Natural Bovine Hydroxyapatite Implant on Bone Defect Animal Model

PDF
176-187

 [10.20473/fmi.v55i3.15495](https://doi.org/10.20473/fmi.v55i3.15495)

Junaidi Khotib, Cantika SC Lasandara, Samirah Samirah, Aniek S Budiati

Leaf and Petiole Extract of *Centella Asiatica* are Potential for Antifertility and Antimicrobial Material

PDF
188-197

 [10.20473/fmi.v55i3.15498](https://doi.org/10.20473/fmi.v55i3.15498)

Susie Amilah, Sukarjati Sukarjati, Diaz P Rachmatin, Masruroh Masruroh

Human Sperm Motility, Viability, and Morphology Decreased after Cryopreservation

PDF
198-201

 [10.20473/fmi.v55i3.15501](https://doi.org/10.20473/fmi.v55i3.15501)

Ninik Darsini, Berliana Hamidah, Seso Sulijaya Suyono, Faisal Yusuf Ashari, R Haryanto Aswin, Rina Yudiwati

The Influence of Psychocurative on Cortisol Level, Anxiety, and Quality of Life in Advanced Stage Cervical Cancer Patients

PDF
202-205

 [10.20473/fmi.v55i3.15502](https://doi.org/10.20473/fmi.v55i3.15502)

Soetrisno Soetrisno, Sri Mulyani, Hafi Nurinasari, Hafi Nurinasari, Erindra Budi

Evaluation of KI-67, Apoptosis, and Hyaluronic Acid in Grading Retinoblastoma

PDF
206-212

 [10.20473/fmi.v55i3.15504](https://doi.org/10.20473/fmi.v55i3.15504)

Hendrian D Soebagjo, Nurwasis Nurwasis, Ugresone Y Bintoro, Sutiman B Soemitro

Effect of Combination Soy Bean Oil and Oleic Acid to Characteristic, Penetration, Physical Stability of Nanostructure Lipid Carrier Resveratrol

PDF
213-222

 [10.20473/fmi.v55i3.15505](https://doi.org/10.20473/fmi.v55i3.15505)

Widji Soeratri, Rohmawati Hidayah, Noorma Rosita

ISSN

Printed ISSN

Electronic ISSN

Instruction for Author

[How to Submit](#)

[Guidelines for Authors](#)

[Online Submission](#)

[Document Template](#)

[CTA & Author Statement](#)

Journal Policy

[Focus and Scope](#)

[Publication Ethics](#)

[Article Processing Charge](#)

[Editorial Team](#)

[Peer Reviewers](#)

[Peer Review Process](#)

[Peer Review Process Flowchart](#)

[Open Access Statement](#)

[Plagiarism Check](#)

[Archiving](#)

[Copyright](#)

[Repository Policy](#)

[Contact](#)

[Old Website](#)

Journal Standing

Scopus[®]

Reference Manager



Plagiarism Checker



External Links



In Collaboration with



Accreditation Certificate

Determinants of Maternal and Child Health Handbook Utilization in Surabaya, Indonesia

doi 10.20473/fmi.v55i3.15506

Irwanto Irwanto, Ilham Ikhtiar, Indah Lutfiya, Windhu Purnomo

PDF
223-
228

The Influence of Health Education on Diabetes Mellitus on Knowledge Improvement of Diabetes Mellitus Cadres in the Working Area of Medokan Ayu Health Center, Surabaya, Indonesia

doi 10.20473/fmi.v55i3.15507

Susilowati Andajani

PDF
229-
233

Case report: Dentigerous Cyst and Canine Impaction at the Orbital Floor

doi 10.20473/fmi.v55i3.15508

Ferdian rizky Hutomo, Ellen Satya Pratiwi, Viskasari P Kalanjati, Andra Rizqiawan

PDF
234-
238

Case report: Management of Progressive Lung Cancer Patients after First-Line EGFR Tyrosine Kinase Inhibitor Therapy

doi 10.20473/fmi.v55i3.15509

Sahrn Sahrn, Laksmi Wulandari

PDF
239-
245



OPEN JOURNAL SYSTEMS

Journal Help

USER

Username Password

Remember me

NOTIFICATIONS
View
Subscribe

JOURNAL CONTENT

Search

Search Scope

Browse
By Issue
By Author
By Title
Other Journals

FONT SIZE

INFORMATION

For Readers
For Authors
For Librarians

Visitors

	ID 51,812		PH 801
	US 6,977		AU 724
	IN 1,731		GB 656
	MY 971		TH 571
	JP 849		CA 484

Pageviews: 275,125

Indexed By



This work is licensed under a [Creative Commons Attribution-NonCommercial-ShareAlike 4.0 International License](https://creativecommons.org/licenses/by-nc-sa/4.0/).

00233033 [View My Stats](#)



Pusat Pengembangan Jurnal dan Publikasi Ilmiah
Universitas Airlangga
copyright@2017 Template PPJPI

Case Report:**MANAGEMENT OF PROGRESSIVE LUNG CANCER PATIENTS AFTER FIRST-LINE EGFR TYROSINE KINASE INHIBITOR THERAPY****Sahrin, Laksmi Wulandari**

Department of Pulmonology and Respiratory Medicine, Faculty of Medicine, Universitas Airlangga, Dr. Soetomo Hospital, Surabaya, Indonesia

ABSTRACT

Various tyrosine kinase inhibitor (TKI) drugs have been widely used as therapy for cancer that has EGFR mutations, or abnormal EGFR activation. However, patients who have a mutation in the gene that activates EGFR only benefit from EGFR-TKI therapy for less than one year, because after that resistance occurs. In the management of patients according to NCCN 2017, patients who experience progress after receiving TKI as the first-line therapy must undergo an examination to identify the presence of T790M mutation. If the T790M mutation is positive, the choice of therapy that needs to be provided is the third generation (Osimertinib). Many recent studies have proved the significance of the effectiveness and response of Osimertinib therapy in lung cancer with EGFR T790M mutation. We reported the management of a pulmonary adenocarcinoma patient with positive EGFR mutation who had received first-line EGFR TKI who had progressive disease and T790M mutation in Dr. Soetomo Hospital. The patient finally received Osimertinib through an Early Access Program with a therapeutic response that improved significantly.

Keywords: Tyrosine kinase inhibitor; TKI resistance; T790M mutation; progressive disease; osimertinib

ABSTRAK

Berbagai obat golongan tyrosine kinase inhibitor (TKI) telah banyak digunakan sebagai terapi kanker yang memiliki mutasi EGFR, atau aktivasi EGFR yang abnormal. Akan tetapi, pasien-pasien yang memiliki mutasi pada gen yang mengaktifasi EGFR hanya mendapat manfaat dari terapi EGFR-TKI selama kurang dari satu tahun, karena setelah itu terjadi resistensi. Dalam tatalaksana pasien menurut NCCN tahun 2017, pasien yang mengalami progress setelah pemberian TKI sebagai terapi lini pertama harus menjalani pemeriksaan untuk mengidentifikasi keberadaan mutasi T790M. Jika mutasi T790M didapatkan positif, pilihan terapi yang perlu diberikan adalah generasi ketiga (Osimertinib). Penelitian terbaru banyak yang membuktikan signifikansi efektivitas dan repons terapi Osimertinib pada kanker paru dengan mutasi EGFR T790M. Kami melaporkan tatalaksana seorang pasien adenokarsinoma paru dengan mutasi EGFR positif yang telah mendapatkan EGFR TKI lini pertama yang mengalami progressive disease dan mutasi T790M di Rumah Sakit Dr. Soetomo. Pasien akhirnya mendapatkan Osimertinib melalui Early Access Program dengan respon terapi yang membaik signifikan.

Kata kunci: Tyrosine kinase inhibitor; resistensi TKI; mutasi T790M; progressive disease; osimertinib

Correspondence: Laksmi Wulandari, Department of Pulmonology and Respiratory Medicine, Faculty of Medicine, Universitas Airlangga, Dr. Soetomo Hospital, Surabaya, Indonesia. E-mail:

pISSN:2355-8393 • eISSN: 2599-056x • doi: <http://dx.doi.org/10.20473/fmi.v55i3.15509>
• Fol Med Indones. 2019;55:239-245 • Received 21 Feb 2019 • Accepted 18 Jul 2019
• Open access under CC-BY-NC-SA license • Available at <https://e-journal.unair.ac.id/FMI/>

INTRODUCTION

Lung cancer is the highest cause of deaths due to cancer in the world, both in developed and developing countries (Jemal et al 2003). According to GLOBOCAN in 2008, lung cancer has also become the most diagnosed cancer case and the cause of death from cancer in ASEAN countries. This should be a special concern, because statistical data shows that lung cancer is a lethal disease with a low survival rate. Only 15% of

patients diagnosed with lung cancer survive in the next 5 years (Mok et al 2009). Treatment of pulmonary tumor types of NSCLC (Non-Small Cell Lung Cancer) depends on the stage at the time of finding. For advanced stage (IIIB-IV) the choice of therapy is radiotherapy, chemotherapy or a combination of both (Rosell et al 2009). Radiotherapy is given as palliative therapy or symptom prevention (Category 2A NCCN). In advanced NSCLC, chemotherapy can be provided for treatment purposes if the patient's general performance

is good (WHO Performance Score 0-2) (Sequist et al 2011).

First-line therapy is given to patients who have never received prior treatment. Second-line therapy is given to patients who have received first-line therapy, but did not respond after 3 cycles, or the cancer becomes progressive. According to the 2017 NCCN tumor therapy guidelines, cancers classified as adenocarcinoma, large cell, squamous cell carcinoma and other non-specific NSCLCs need to be subjected to molecular testing and determination of PD-L1 status to determine tumor genetic mutations. All patients who have been diagnosed with adenocarcinoma can be given first-line platinum-based chemotherapy from the start or after the results of the EGFR mutation are identified. Especially for adenocarcinoma, if the molecular test of EGFR mutation is found to be sensitive when the patient is undergoing chemotherapy, chemotherapy can still be continued to completion, or given as maintenance therapy, or target therapy can be directly provided. If the EGFR mutation has been identified from the beginning, then the EGFR TKI can immediately be the choice of first-line therapy. Conversely, if the EGFR mutation turns out to have a negative result, the choice of treatment is platinum-based chemotherapy. Furthermore, the progression of EGFR TKI is observed. If progress occurs due to T790M mutation, the next treatment option will be the administration of second-line EGFR TKI (Osimertinib) (Sequist et al 2011, Thomas et al 2004, WHO 2004).

There are several mechanisms for the occurrence of resistance to EGFR-TKI, such as secondary mutations (T790M), alternative path activation (c-Met, HGF, AXL), abnormalities at the end of the pathway (K-RAS mutation, loss of PTEN), EGFR-TKI-mediated disruption of apoptosis pathways (polymorphism in the form of BCL2-like 11/BIM gene deletions), histological changes, ATP binding cassette (ABC) transporter effusions, and others (Ettinger et al 2010, Parkin et al 2002).

Adenocarcinoma patients with EGFR mutation initially respond strongly to EGFR TKI therapy, but will subsequently experience secondary (acquired) resistance with a median Progression-Free Survival (PFS) of 9-14 months (Mok et al 2009, Sequist et al 2011). The AURA 3 trial, using cell-free DNA examination, found that around 51.2% of the patients had a positive T790M mutation. This is the reason of why 60% of patients who have received EGFR TKI eventually experience EGFR T790M mutation in exon 20, which has been investigated as being related to molecular change (Parkin et al 2002, Yang et al 2005). In this case report we discussed a pulmonary adenocarcinoma patient with a positive EGFR mutation who had received first-line

EGFR and experienced progressive disease and T790M mutation.

CASE REPORT

Mr. J, 54, worked as a handyman with a history of smoking 1 pack per day for 32 years, coming with complaints of coughing up blood. The complaint was also accompanied by coughing up thick white phlegm. The body was weak, appetite lost, and bodyweight decreases. Temperature was high, with intermittent short of breath.

CT-Scan Guiding FNAB in dextral pulmonary mass showed adenocarcinoma, and EGFR mutations examination revealed exon 19 positive. The patient began to receive targeted treatment therapy with Gefitinib 250 mg tablets once daily for 7 months. Initially, the patient responded well to Gefitinib therapy as evidenced by improved clinical conditions, coughing and shortness decreases, appetite and weight increased. In the first three months the results of RECIST-based CT scan showed partial response. After Gefitinib therapy entered the 7th month, the results of CT scan showed that the patient's condition was worsening with progressive disease. The patient then received second line therapy with Docetaxel for 4 series. Post three-cycle Docetaxel, thoracic CT-scan was evaluated and clinical progressive disease was deteriorated on RECIST, so that the patient was admitted to the hospital.

Physical examination showed that the mass in the right thoracic region was 8x15 cm, and collateral veins appeared. Edema was seen in both upper limbs and the one on the left was more severe. Subsequently, the patient underwent a liquid biopsy (CT-DNA) examination to assess the suspicion of secondary mutations due to exposure to first-line EGFR TKI. The results of EGFR CT-DNA examination showed positive mutations in exon 20 T790M.

The patient followed osimertinib early access program and start getting 80 mg osimertinib every 24 hours orally. Clinical evaluation was carried out 5 days after 80 mg osimertinib treatment, and significant improvement was found, coughing was reduced, congestion improved, appetite increased, and the edema of the limbs decreased considerably. Collateral venous ectasia started to decrease with a decrease in JVP. CXR evaluation showed a reduction in homogeneous opacity as much as 2/3 of the right lung. The pulmonary parenchyma started to appear clearly again, accompanied by a decrease in right and left pleural effusion. Laboratory evaluation also showed improvement.

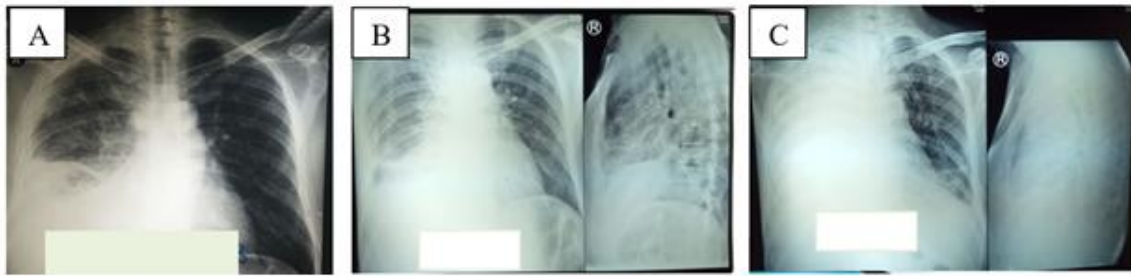


Fig. 1. (A) Chest X-ray of the patient at the beginning of a lung tumor diagnosis. The right costophrenic angle looks blunt. There is a homogeneous coating in 1/3 of the lower right lung. (B) Chest X-ray of the patient after receiving Gefitinib 250 mg target therapy for 3 months and experiencing a partial response. (C) The patient's chest X-ray at the time of admission to the emergency room, where homogeneous opacity appears to be wider and meet all right hemithorax.

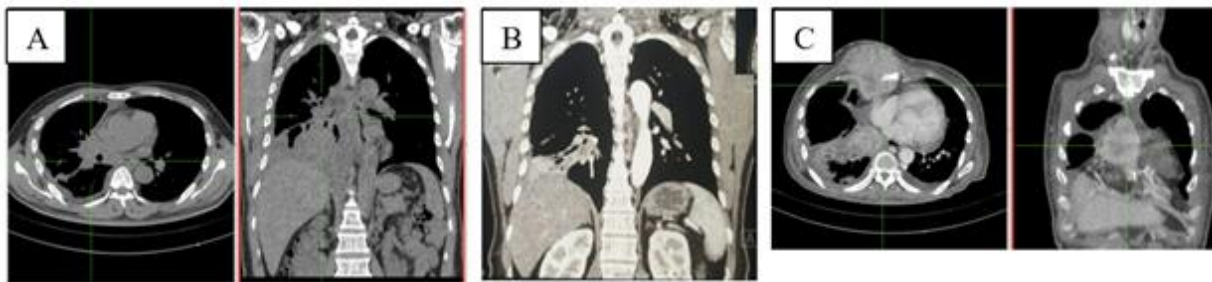


Fig. 2. (A) Initial CT-scan when the patient was diagnosed with a right lung tumor, there is a solid mass in the 8-9 segment measuring 3.56 x 3.61 x 5 cm. Dextral costa IV nodules sized 3.69 x 5.32 x 4 cm is visible. Dextral pleural effusion is also visible. (B) Evaluation of thoracic CT scans after the patient has received Gefitinib 250 mg target therapy for the first 3 months. The size of the mass is relatively small (> 30%). Right upper paratracheal lymph nodes, paraorta, lower paratracheal are detected. There is right pleural effusion, soft tissue mass bulging with corpus sternum destruction. RECIST criteria: Partial response. (C) The patient's thoracic CT scan at a follow-up evaluation when the patient experiences progression of the disease and finally is admitted to the hospital (indefinite lung mass border, irregular edges measuring 8.5 x 6, 5 x 9.9, cm on the right anterior hemithorax wall. The mass destroys the sternum and extending into the anterior mediastinum: It appears solid with a firm boundary, irregular edges measuring 2.3 x 3.7 x 4.0 cm posterior to the right hemithorax that erode the right posterior costa 2-4 and extends to the pleural cavity. The mass size of 2.5 x 2x6 x 3 cm is seen in the right upper abdominal wall at the level of the liver. Fluid density appears in the right and left pleural cavity, RECIST criteria: Progressive disease).

After a 20-day first visit to the Oncology Clinic, Dr. Soetomo Hospital, the patient's family contacted the doctor and found the patient died when he woke up on the morning of December 17, 2017. The patient was suspected of dying from a pulmonary embolism from Deep Vein Thrombosis (DVT).

DISCUSSION

According to the 2017 NCCN, adenocarcinoma patients should be explored to see the presence of mutations to determine target therapy. If the molecular test results show a positive EGFR mutation, then the target therapy must be started immediately and its progressivity observed. The median survival rate after getting an

EGFR for TKI is 9-14 months. If there is a progress with the secondary T790M mutation, the choice of therapy is the administration of second-line TKI EGFR (Osimertinib) (Sequist et al 2011, David et al 2017, Thomas et al 2004). In this case report, the results of anatomical pathology examination in pulmonary adenocarcinoma patients showed positive EGFR mutations in exon 19. Patients were given first-generation TKI therapy Gefitinib 125 mg daily orally for 7 months. Initially the patient experienced a fairly good treatment response with the results of the thoracic CT-scan evaluation with the RECIST partial response criteria. But in the seventh month the first-line EGFR TKI treatment patients progressed until finally the patient was hospitalized.

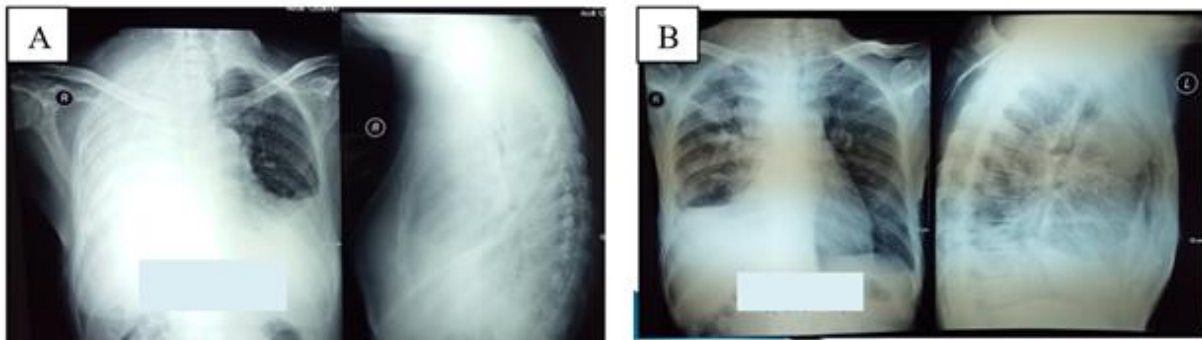


Fig. 3. (A) Chest X-ray of the patient at the beginning of admission before getting second-line radiotherapy and EGFR. Homogeneous opacity appears to fill the entire right lung field, obstructing the appearance of pulmonary parenchyma. The left costophrenic angle also looks blunt. (B) Chest X-ray of the patient after obtaining 13-series radiotherapy and the second line EGFR TKI (osimertinib). During the visit complaints of shortness of breath, coughing, and chest pain were not found. Left hand swelling diminishes.

Medicines belonging to the tyrosine kinase (TKI) inhibitor have been widely used as cancer therapies that have an EGFR mutation or abnormal EGFR activation. Gefitinib can inhibit TK domains from EGFR reversibly by competing with ATP competitively. TKIs also cause tumor cell death through BCL2-like 11 (BIM) mediated apoptosis. However, patients who have a mutation in the gene that activates EGFR only benefit from EGFR-TKI therapy for less than 1 year, because after that resistance occurs. The etiology of resistance to EGFR-TKI is very complex. Based on cell signal transduction pathways, the etiology of EGR-TKI resistance can be divided into several categories (Yun et al 2008).

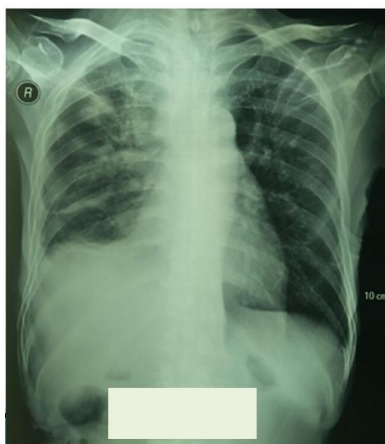


Fig. 4. Chest X-ray 21 days after osimertinib administration. The appearance of 2/3 of the right lung is increasingly clear and the right-left costophrenic angle is sharp.

Initially, adenocarcinoma patients with EGFR mutations greatly respond to EGFR TKI therapy, but will subsequently experience secondary (acquired) resistance with median progression-free survival (PFS) averaging 9-14 months, even with a dramatic initial response. This means that every time a patient receives TKI, within an average period of 9-14 months he will experience progress related to various mutation pathways used by the tumor. The most common secondary mutation is T790M. It is evident that 60% of patients who have received EGFR TKI eventually experience EGFR T790M mutations in exon 20 which is believed to be related to molecular changes (Shinagare et al 2011, Carson et al 1992). Patients who experience progression after the administration of TKI can be identified clinically and radiologically. Evaluation of therapeutic response to chemotherapy is performed by observing changes in tumor size after the 3rd chemotherapy administration (cycle) (Greene et al 2002).

In these patients clinical deteriorations were in the form of shortness of breath and heavy coughing, heat, nausea, vomiting, coughing up blood, decreased appetite, decreased body weight, and edema of the legs as a sign of VCSS due to tumor crushing. In addition, there were signs of massive pleural effusion, filling the entire right lung field. Whereas, treatment response assessed from tumor radiological profile resulted from thoracic CT scans, showed that tumor mass increased of >25% with RECIST criteria for of progressive disease.

Shortness of breath occurs because of the inflammatory process of the lower airways by infection and the

presence of blockage on the right heart which interfere with circulation and right heart oxygenation so that it appears as a symptom of hypoxemia. Hemoptysis can occur due to the process of necrosis and inflammation of blood vessels in tumor tissue. Invasion of tumors into pulmonary blood vessels is rare. Hemoptysis can occur in 7-10% of patients with bronchogenic carcinoma (Kosasih et al 2008).

Vena cava superior syndrome (VCSS) is a collection of symptoms due to widening of the veins that carry blood from upper body part to the heart. Inhibition of blood flow (occlusis) that passes through this vein can cause superior vena cava syndrome (VCSS) (Arief 2009). More than 95% of all VCSS cases involve upper thoracic cancer, and the case that mostly associated with VCSS syndrome is lung cancer, which is close to 80% of all cases of superior vena cava syndrome and lymphoma (Brzezniak et al 2017).

In non-small-cell lung cancer patients who initially respond to EGFR TKI, there is resistance to EGFR inhibitors, which then results in treatment failure related to its development. Most studies found that the EGFR mutation occurred in exon 20, resulting in substitution of methionine for threonine in codon 790 (T790M) (Huang, Fu 2015). The AURA 3 trial, using cell-free DNA examination, found that around 51.2% of patients had positive T790M mutation. This mutation causes tridimensional changes in tyrosine kinase domain structure and prevents the binding of erlotinib and gefitinib to EGFR (Ciardiello, Tortora 2008).

According to the NCCN in 2017, patients who experience progress after receiving TKI as first-line therapy must undergo EGFR T790M mutation examination. If the results of the EGFR T790M mutation are obtained positively, then the treatment choice is second-line TKI (osimertinib). Conversely, if the results of EGFR T790M mutation are negative, then the therapy given can be in the form of chemotherapy.

Many recent studies have proved the effectiveness and therapy response of osimertinib which is quite significant for lung cancer with T790M mutation. Based on the Aura Study II, the effectiveness of osimertinib in controlling adenocarcinoma with the T790M mutation reached 91% (95% CI, 88, 94) and overall response rate (ORR) was 66% (95% CI, 61, 71). Another study, the Apple Trial 2017, also revealed osimertinib's response to pulmonary adenocarcinoma with T790M mutation, which found a longer progression-free survival rate of up to 18 months until the end of treatment. The same study by TS Mok et al (2017) showed that in the third trial on osimertinib effects compared to platinum-pemetrexed on EGFR T790M showed that free survival

rate progression increased significantly to 10.1 months compared to platinum-pemetrexed which was only 4.4 months. In addition, ORR was also found to be quite significant at 71% (95% CI, 65-76) when compared to platinum-pemetrexed, which was only 31% (95% CI, 24-40) (Mok et al 2009, Ciardiello, Tortora 2008, Socinski et al 2016).

After CT-DNA examination, the patient was found to have a mutation in the T790M. The patients should have been given with second-line TKI (osimertinib), but because the drug has not yet been available in Indonesia, the patient was temporarily given with second-line chemotherapy docetaxel as many as 4 series. The patient underwent 4 cycles of docetaxel chemotherapy until October 2017. Post 3-cycle docetaxel evaluation of chest CT-scan was carried out in September 2017 and RECIST criteria of progressive disease was obtained. The patient then followed osimertinib's early access program with a significant therapeutic response manifested as clinical and radiological improvements. The patient, who was initially congested, coughed, weak and had difficulty moving, experienced improvement within 5 days after the administration of osimertinib. Hematological markers and signs of VCSS also appeared to be improving. CXR evaluation was very clearly showing significant reduction in tumor mass and effusion, so that in the end the patient could continue the therapy on an outpatient basis.

During outpatient therapy, the patient did not complain of shortness and coughing, had improved appetite and weight gain was reported to increase. Before the second visit to the clinic, the patient was found dead at the time he should have woken up, without any prior complaints of shortness and coughing or fever. It was suspected that the patient died from pulmonary embolism originating from deep vein thrombosis (DVT). It is known that the incidence of thromboembolism is basically quite low in general population, but its incidence increases 4-7 times higher in cancer patients, depending on the type and stage of the tumor (Nordstrom et al 1992, Falanga 2009). An estimated 20% of all Venous Thromboembolism (VTE) is caused by cancer (Lee 2005). Pulmonary embolism and DVT are manifestations of VTE. Lung cancer is the most malignant disease associated with VTE. A recent study of case-control populations found that blood malignancies, followed by pulmonary and gastrointestinal malignancies, are the major causes of VTE (Sorensen et al 2000, Blom et al 2005).

CONCLUSION

We have reported one case of a 54-year-old male patient with stage IV EGFR adenocarcinoma with exon 19 mutation and a secondary mutation in exon 20 T790M. Clinical manifestations in the patients are the presence of shortness, coughing, coughing up blood and signs of VCSS due to obstruction by tumor suppression on superior vena cava. The results of special examination on thoracic CT-scan showed a right lung tumor mass. Anatomic histopathology examination showed adenocarcinoma. Examination of EGFR mutations revealed exon 19 mutation, and CT-DNA examination showed a secondary mutation of T790M. Initially, the patient received EGFR-TKI gefitinib chemotherapy, showing partial response, then becoming progressive after 7 months. The patients then underwent second-line chemotherapy with docetaxel for 4 series, the response was poor and progressive. The patient finally received osimertinib with a significantly improved therapeutic response. Improvement evaluation, even after visit, again showed improvement in clinical and radiological conditions.

REFERENCES

- Arief N (2009). Kegawatdaruratan paru, departemen pulmonologi dan ilmu kedokteran respirasi FKUI RS PERSAHABATAN, Universitas Indonesia
- Blom JW, Doggen CJ, Osanto S, et al (2005). Malignancies, prothrombotic mutations, and the risk of venous thrombosis. *JAMA* 293, 715-722. Available at <https://www.ncbi.nlm.nih.gov/pubmed/157019> 13. Accessed September 13, 2018
- Brzezniak C, Oronsky B, Carter CA, et al (2017). Superior vena cava syndrome in a patient with small-cell lung cancer: A case report. *Case Rep Oncol* 10, p 252-257
- Carson JL, Kelley MA, Duff A, et al (1992). The clinical course of pulmonary embolism. *N Engl J Med* 326, p 1240-1245. Available at <https://www.ncbi.nlm.nih.gov/pubmed/1560799>. Accessed September 11, 2018
- Ciardiello F, Tortora G (2008). EGFR Antagonists in Cancer Treatment. *N Engl J Med* 358, 1160-1174
- David SE, Douglas EW, Dara LA, et al (2017). Non-Small Cell Lung Cancer, Version 5, Clinical Practice Guidelines in Oncology. *J National Comprehensive Cancer Network (NCCN)* 15, 504-535
- Ettinger DS, Akerley W, Bepler G, et al (2010). Non-small cell lung cancer clinical practice guidelines in oncology. *Natl Compr Cancer Netw* 8, 740-801
- Falanga A (2009). The incidence and risk of venous thromboembolism associated with cancer and nonsurgical cancer treatment. *Cancer Investig* 27, 105-115. Available at <https://www.ncbi.nlm.nih.gov/pubmed/19160098>. Accessed September 14, 2018
- Greene FL, Page DL, Fleming ID, et al (2002). Cancer Survival Analysis. In: *AJCC Cancer Staging handbook*, 6th Ed. New York, Springer, p 15-25
- Huang L, Fu L (2015). Mechanisms of resistance to EGFR tyrosine kinase inhibitors. *Acta Pharmaceutica Sinica B* 5, 390-401. Available at <https://core.ac.uk/download/pdf/82702660.pdf>. Accessed September 12, 2018
- Jemal A, Bray F, Center MM, et al (2003). Global cancer statistics. *A Cancer Journal Clinicians* 61, 69-90
- Kosasih, Alvin, Susanto AD, et al (2008). *Diagnosis Dan Tatalaksana Kegawatdaruratan Paru Dalam Praktek Sehari-hari*, Jakarta, Sagung Seto
- Lee AY (2005). Management of thrombosis in cancer: primary prevention and secondary prophylaxis. *Br J Haematol* 128, p 291-302. Available at <https://www.ncbi.nlm.nih.gov/pubmed/15667530>. Accessed 09 10, 2018
- Mok TS, Wu YL, Thongprasert S, et al (2009). Gefitinib or carboplatinpaclitaxel in pulmonary Adenokarsinoma. *N Engl J Med* 361, p 947-57
- Nordstrom M, Lindblad B, Bergqvist D, et al (1992). A prospective study of the incidence of deep-vein thrombosis within a defined urban population. *J Intern Med* 232(2), p 155-160. Available from <https://www.ncbi.nlm.nih.gov/pubmed/1506812>. Accessed 09 14, 2018
- Parkin DM, Bray F, Ferlay J, et al (2002). Global cancer statistics 2002. *A Cancer Journal Clinicians* 55(2), p 74-108
- Rosell R, Moran T, Queralt C, et al (2009). Screening for epidermal growth factor receptor mutations in lung cancer. *N Engl J Med* 361, 958-67
- Sequist LV, Waltman BA, Dias-Santagata D, et al (2011). Genotypic and histological evolution of lung cancers acquiring resistance to EGFR inhibitors. *Sci Transl Med* 3, 75ra26
- Shinagare AB, Guo M, Hatabu H, et al (2011). Incidence of pulmonary embolism in oncologic outpatients at a tertiary cancer center. *Cancer* 117, p 3860-6. Available at <https://www.ncbi.nlm.nih.gov/pmc/articles/PMC3131455/>. Accessed September 11, 2018
- Socinski MA, Villaruz LC, Ross J (2016). Understanding mechanisms of resistance in the epithelial growth factor receptor in non-small cell lung cancer and the role of biopsy at progression. *Oncologist* 21, 1-9
- Sorensen HT, Mellekjaer L, Olsen JH, et al (2000). Prognosis of cancers associated with venous thromboembolism. *N Engl J Med* 343, 1846-50. Available at <https://www.ncbi.nlm.nih.gov/pubmed/11117976>. Accessed September 13, 2018

- Thomas A, D'Amico MD, Malcolm M, et al (2004). EGF receptor gene mutation are common in lung cancer from "never smokers" and are associated with sensitivity of tumors to gefinitib and erlotinib. *Proceedings of the National Academy of Science* 101, 13306-11
- WHO (2004). Histological of the tumor of the lung. In: *Tumor of the lung-WHO classification*
- Yang P, Cerhan JR, Vierkan RA, et al (2002). Adenokarsinoma of the lung is strongly associated with cigarette smoking: further evidence from a prospective study of women. *American Journal of Epidemiology* 156, 1114-1122
- Yun C, Mengwasser KE, Toms A V, et al (2008). The T790M mutation in EGFR kinase causes drug resistance by increasing the affinity for ATP. *Proc Natl Acad Sci USA* 105, 2070-2075. Available at <https://www.ncbi.nlm.nih.gov/pubmed/18227510>. Accessed September 11, 2018

PEMERINTAH PROVINSI JAWA TIMUR
RUMAH SAKIT UMUM DAERAH Dr. SOETOMO
KOMITE ETIK PENELITIAN KESEHATAN
Jl. Prof. Dr. Moestopo No. 6-8, Telp. (031) 5501164
SURABAYA 60286

SURAT KETERANGAN
Nomor: 13 /113/Komitlitkes/ W /2022

Yang bertanda tangan dibawah ini:

Nama : Prof. Dr. Hendy Hendarto, dr.,Sp.OG(K)
NIP : 19610817 198802 1002
Jabatan : Ketua Komite Etik Penelitian RSUD Dr.Soetomo Surabaya

Dengan ini menerangkan bahwa artikel berikut:

Judul : Management of Progressive Lung Cancer Patients After First-Line EGFR Tyrosine Kinase Inhibitor Therapy
Penulis : Sahrun, Laksmi Wulandari
Penerbit : Folia Medica Indonesiana

Merupakan laporan dari kasus pasien seperti yang tersebut didalam artikel, yang dirawat di RSUD Dr. Soetomo Surabaya dengan dokter penanggung jawab pasien (DPJP) Dr. Laksmi Wulandari, dr., Sp.P (K) dan telah mendapatkan ijin dan persetujuan untuk menggunakan informasi rekam medis, sehingga dapat dipublikasikan sebagai salah satu bentuk tambahan dan pengembangan keilmuan.

Demikian Surat Keterangan ini dapat dipergunakan sebagaimana mestinya.

Surabaya, 26 APR 2022

Ketua Komite Etik Penelitian Kesehatan
RSUD Dr. Soetomo Surabaya


Prof. Dr. Hendy Hendarto, dr., Sp.OG (K)
Pembina Utama Madya
NIP. 196108 17198802 1 002

Journal Profile

Folia Medica Indonesiana

eISSN : 2599056X | pISSN : 23558393

Education

Universitas Airlangga



S2

Sinta Score

13

H-Index

10

H5-Index

883

Citations

601

5 Year Citations



Penerbit:

Fakultas Kedokteran Universitas Airlangga

[!\[\]\(feabb98897b440bc8695a03336a6e2df_img.jpg\) Website](#) | [!\[\]\(c7f935293d8062fa748ed86b74d28761_img.jpg\) Editor URL](#)

Address:

Jalan Mayjen Prof dr Moestopo 47
KOTA SURABAYA

Email:

fmi@journal.unair.ac.id

Phone:

0315020251 ext. 1199

Last Updated :

2021-12-04

2018

2020

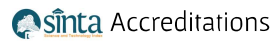2021

2022

2023

2024

2025



Search..



1

2

3

4

5



Page 1 of 43 | Total Records : 428

Publications

Citation

<u>The potency of piperine as antiinflammatory and analgesic in rats and mice</u> SA Sudjarwo Folia Medica Indonesiana 41 (3), 190-194	63
<u>Risk factors for birth asphyxia</u> MT Utomo Folia Medica Indonesiana 47 (4), 211	43
<u>Noise induced hearing loss in steel factory workers</u> S Harmadji, H Kabullah Folia Medica Indonesiana 40 (4), 171-174	42
<u>Button batteries: the worst case scenario in nasal foreign bodies</u> AK Guidera, S HR NZ Med J 123 (1313), 68-73	33
<u>Isolation of male antifertility compound in n-butanol fraction of Justicia gendarussa Burm. F. leaves</u> BEW Prajogo, D Guliet, FE Queiroz, JL Wolfender, NZ Cholies, H Aucky, ... Folia Medica Indonesiana 45 (1), 28	30
<u>Antimicrobial resistance and antibiotic use in low-income and developing countries</u> U Hadi, EP Kolopaking, W Gardjito, IC Gyssens, PJ Van den Broek Folia Medica Indonesiana 42 (3), 183-95	24
<u>Antibiotic usage and antimicrobial resistance in Indonesia</u> U Hadi Leiden University	22
<u>Green clover potentiates delaying the increment of imbalance bone remodeling process in postmenopausal women</u> H Laswati Folia Medica Indonesiana 47 (2), 112-117	21
<u>Staphylococcal scalded skin syndrome in a neonate</u> S Kadam. A Tagare. I Deodhar. Y Tawade. A Pandit	18

Spermatozoa Motility and Morphological Recovery Process in Mice (*Mus musculus*) after the Induction of 2-Methoxyethanol

16

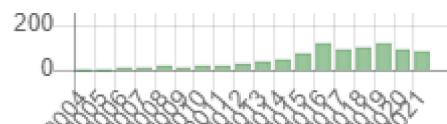
A Hayati, AD Rahmaninta, IBR Pidada

Folia Medica Indonesiana 41 (2), 90

Page 1 of 43 | Total Records : 428



Citation Statistics



Copyright © 2017
Kementerian Pendidikan, Kebudayaan, Riset, dan Teknologi
(The Ministry of Education, Culture, Research, and Technology)
All Rights Reserved.