

## Expression of Bmp-2 in the Alveolar Rats' Extraction Socket after High Sucrose Diet

Christian Khoswanto<sup>1\*</sup>

1. Department of Oral Biology Faculty of Dentistry, Airlangga University. Surabaya – Indonesia.

### Abstract

One of wound regeneration's important roles is in the presence of calcium minerals and compounds and mineralization for bone survival after the tooth extraction process. BMPs are bone proteins that are needed in the formation of new bone. BMP that plays a very important role is BMP-2. In the process of forming new bones, they also really need good minerals so that the bones can be perfectly formed. A high diet of sucrose can promote mineral bone loss, resorption of alveolar bone by osteoclast also can increase calcium urine, and plasma.

The purpose of this study is to explore the expression of BMP-2 in Wistar rats with tooth extraction after high sucrose diet. The results were statistically evaluated using a T-test. In comparison to the control group, there was a substantial difference in BMP-2 expression on days 7 and 15.

Experimental article (J Int Dent Med Res 2022; 15(2): 561-563)

**Keywords:** Tooth extraction, sucrose, BMP-2.

**Received date:** 25 March 2022

**Accept date:** 14 April 2022

### Introduction

Tooth extraction in the mandible and maxilla, because of the failing tooth caused by a variety of reasons, such as late periodontitis disease, cracked tooth, endodontic treatment failure, huge caries that cannot be maintained, and loose alveolar bone. The extraction would cause damage to mucous and alveolar sockets. Damaged to soft tissue and hard tissue will be through four stages in achieving normal recovery again, the stages including hemostasis in the socket, inflammation of soft and hard tissues, the proliferation of the cell and tissue remodeling.<sup>1,2</sup>

One of wound regeneration's important roles is in the presence of calcium minerals and compounds and mineralization for bone survival after the tooth extraction process. The process of intramembranous ossification is a type of ossification that occurs during tooth extraction, which is mesenchymal connective tissue the main role. The mandibulocraniofacial skeletal structure is bone complex and very dynamic

organ, presence of the inner and outer of the alveolar cortical layer is the pieces came off the bone that can be presence on the inner structure is the inner cancellous layer and the part of outer surface for skeletal strength also has a significant impact on the structure of bone metabolism. Mandibulocraniofacial consist of a high microvascularized which is good for remodeling. The bone homeostasis process was an important role to regulate the stability from damage and loss of minerals. The microvasculature of the bone also presence oxygen and nutrients and produces the molecular and progenitors cell whichever presence an important role in bone structure repair.<sup>3,4</sup>

The osteogenesis process is required from bone cells in the process that occurs through bone healing. Many cells such as muscle cells, bone cells, fibroblast, and cartilage cells came from mesenchymal cells in bone marrow, that have a special potential ability to differentiate into many specific cells. The microvascular pieces of bone and Bone's internal and external surfaces including osteoprogenitor cells can supply the nutritive of the bone, including in the marrow cavity which is endosteal cells, and periosteal cells from the outer and inner layer, Volkmann's canal, and Haversian canal structure.<sup>4,5</sup>

BMPs are bone proteins that are needed in the formation of new bone. BMP that has a

#### \*Corresponding author:

Christian Khoswanto,  
Department of Oral Biology Faculty of Dentistry,  
Airlangga University. Jln. Mayjend.  
Prof. Dr. Moestopo No. 47 Surabaya 60132, Indonesia.  
E-mail : christiankhoswanto@hotmail.com

vital function to perform is BMP-2. The process to forming new bones, they also really need good minerals so that the bones can be perfectly formed.<sup>6</sup>

A high diet of sucrose can promote mineral bone loss, resorption of alveolar bone by osteoclast also can increase calcium urine, and plasma. Many previous studies showed that high sucrose diet make a negative impact on the bone health, but There isn't any study that showed the effect of high sucrose on BMP2 protein expression following tooth extraction.<sup>7</sup> The aim of this study is to find out how the expression of BMP 2 in Wistar rats with tooth extraction after high sucrose diet.

### Materials and methods

In this study using PostTest Only Control Group Design, the sample was randomly assigned to the received intervention. This study used 28 female Wistar rats, weighing 130-140 grams, 100 days of age. All samples must have a good condition, drink, and food given for good nutrition as ad libitum. This study already has been approved for all steps in experimental procedures by Animal Care and committee Airlangga University. Wistar rats were used in this study for easier treatment and high survival in extraction tooth treatment. The lower incisor is visible to extraction with less complication such as bleeding and fracture alveolar bone.

All samples were randomized and divided into 4 groups (7 rats for each). Group 1 (40 % energy from sucrose 7 days), Group 2 (control Group 7 days), Group 3 (40 % energy from sucrose 15 days), Group 4 (control Group 15 days). Sucrose diet given for 7 and 15 days and then extraction done to the lower incisive of Wistar rats. The sample was decapitated with sagittal cutting, fixated using buffered formaldehyde 10%. The water of the samples fragment was extracted using 96% Ethanol.

The next stage is dehydration by using graded series of alcohol and clearing stage using xylene. Embedding tissue using paraffin and sectioning was done by 5 µm. mounting and staining for BMP2 done on next stage. After all histology specimens were done, all samples were examined under a light microscope magnified 400 times (OLYMPUS JAPAN).

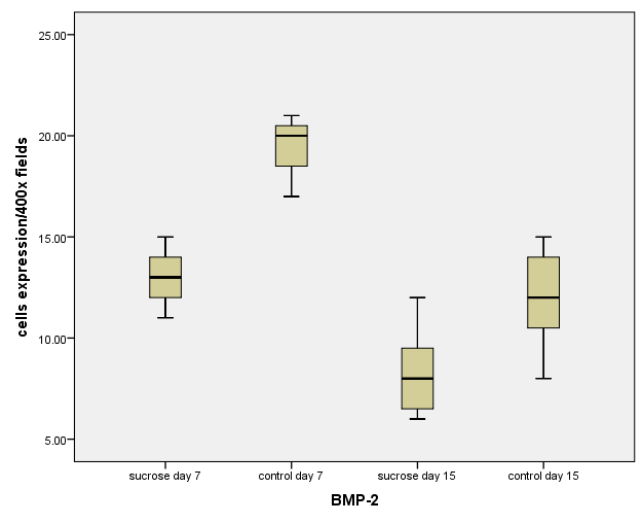
### Results

In this investigation, no difficulties and bleeding occurred during Wistar rat incisors were extracted, there were no deaths among the animals as a result of anesthesia or infection. Table 1. demonstrate the mean and standard deviation of BMP-2 expression after extraction lower incisive in Wistar Rats. To determine the normality of the distribution, the data were subjected to a Kolmogorof Smirnov test. All of the data had a normal distribution because each analyzed group's outcome was  $p > 0.05$ . Figure 1. Data showing the number of BMP-2 per 400 times in treated for 7 & 15 days.

Group	X±SD Day 7	X±SD Day 15
Sucrose 40%	13.00 <sup>a</sup> ±1.41	8.28 <sup>a</sup> ±2.36
K	19.42 <sup>b</sup> ±1.51	12.00 <sup>b</sup> ±2.51

**Table 1.** Shows the mean BMP-2 expression in the treatment and control groups.

Note that the varied superscripts revealed a significant difference (0.05).



**Figure 1.** Data showing the number of BMP-2 per 400 fields in treated for 7 & 15 days.

### Discussion

Bone healing can be aided or hindered by a variety of reasons. Tissue types, Wound site and condition, wound vasculature, pathogen infiltration, and topical and systemic variables are all factors to consider.<sup>8</sup>

The presence of HIF1 expression in the wound region indicates the formation of

vascularization after tooth extraction, the first step in the healing process, followed by the presence of BMP-2 expression to Osteoblast cells that are responsible for the development of alveolar bone.<sup>9,10</sup>

Osteoblast differentiation and proliferation are aided by the action of BMP-2, which encourages mesenchymal cells to proliferate and differentiate into active osteoblast cells, hence improving alveolar bone quality. Mononucleated cells called osteoblasts produce collagen and non-collagen matrix production. Osteoblasts are mesenchymal cells that produce osteoid or bone matrix, which is round, oval, or polyhedral and separate from the mineralized matrix. Osteoblasts play a role in the mineralization process by synthesizing and secreting regulating electrolyte changes in extracellular fluid and bone organic matrix. The endoplasmic reticulum, Golgi membrane, and mitochondria are all found in osteoblasts.<sup>11</sup>

Alveolar bone is a mineralized tissue with a collagen type I content of bone sialoprotein, osteocalcin, osteonectin, osteopontin, and proteoglycans varieties. The alveolar bone also contains a number of growth factors and serum proteins. Cortical and trabecular bones are the two forms of alveolar bones that are commonly recognized. On the outside, the bone cortex is a solid bone and the trabecular bone, which is structured like a sponge, is on the inside.<sup>5,11</sup>

In this study, a high-sugar diet resulted in a decrease in BMP-2 expression (Table 1 & Figure 1). Changes in plasma calcium levels in rats were measured, according to fed various doses of sucrose diet reveal that as indicated by high sucrose intake, plasma calcium levels rise. The loss of calcium in urine is one of the processes proposed for how a high-sugar diet affects serum calcium. Reduced tubular reabsorption is assumed to be the cause of sucrose's calciuric impact.<sup>12</sup>

Reduced calcium in the body causes BMP-2 expression to be disrupted, allowing barriers to bone production to mature. A high sucrose diet causes high glucose levels, which have a direct inhibitory effect on osteoblasts, as demonstrated by osteoblast cells exposed to high glucose levels. Glucose is thought to cause a reduction in putrescine, a result of ornithine decarboxylase (ODC). ODC is a critical enzyme for cell development.<sup>13</sup>

## Conclusions

In this study, a 40% sucrose diet reduced BMP-2 expression in the alveolar Wistar rats' extraction socket

## Declaration of Interest

There are no conflicts of interest reported by the author, and the article was not financed or supported by any research grant.

## References

1. Zhao R, Liang H, Clarke E, Jackson C, Xue M. Inflammation in chronic wounds. *Int. J. Mol. Sci.* 2016;17(12):2085.
2. Khoswanto C, Soehardjo I. The effect of Binahong Gel (*Anredera cordifolia* (Ten.) Steenis) in accelerating the escalation expression of HIF-1 $\alpha$  and FGF-2, *Journal of International Dental and Medical Research*, 2018;11(1):303-307.
3. Gonzalez ACO, Costa TF, Andrade ZA, Medrado ARAP. Wound healing - A literature review. *An Bras Dermatol.* 2016; 91(5):614-620.
4. Broughton G II, Janis JE, Attinger CE. Wound Healing: An Overview. *Plast. Reconst. Surg.* 2006; 117(7):1-32.
5. Young B and Heath, JW. *Functional Histology*, 6th ed, London: Churchill Livingstone; 2013:40-8.
6. Dewi RS, Gita F, Soekanto SA. BMP2 Concentration in Gingival Crevicular Fluid as an Osseointegration Biomarker in Dental Implant, *Journal of International Dental and Medical Research*, 2017;10:800-8.
7. Salau BA, Ajani EO, Adebayo OL, Atunnise AK, & Osilesi O. High sucrose diet modulates Calcium status in male albino rats: Possible implication on cardiovascular disease and dental caries. *Annals of Biological Sciences*, 2014;2(2):45-50.
8. Buser D. *Guided bone regeneration*. 2<sup>nd</sup> ed. Illinois: Quintessence; 2009:30-55.
9. Heun Y, Pogoda K, Anton M, Pircher J, Pfeifer A, et al. HIF-1 $\alpha$  Dependent Wound Healing Angiogenesis in Vivo Can Be Controlled by Site-Specific Lentiviral Magnetic Targeting of SHP- 2. *Molecular Therapy*. 2017; 25(7):1616-1627
10. Kim SY, Yang EG, Recent Advances in Developing Inhibitors for Hypoxia-Inducible Factor Prolyl Hydroxylases and Their Therapeutic Implications. *Molecules*, 2015; 20:20551–20568.
11. Nanci A. *Oral Histology : Development, Structure and Function*. 8<sup>th</sup> ed. Missouri: Mosby Co; 2012:12-60.
12. Ericsson Y, Angman-Månsson B & Flores M. Urinary mineral loss after sugar ingestion. *Bone and Mineral*, 1990;9:233-7.
13. Tejwani V and Qian Q, Calcium Regulation and Bone Mineral Metabolism in Elderly Patients with Chronic Kidney Disease, *Nutrients*, 2013;5(6):1913-36.