



Source details

International Journal of Surgery Case Reports

Scopus coverage years: from 2010 to Present

Publisher: Elsevier

ISSN: 2210-2612

Subject area: Medicine: Surgery

Source type: Journal

CiteScore 2021

0.9



SJR 2021

0.198



SNIP 2021

0.691



[View all documents >](#)

[Set document alert](#)

[Save to source list](#) [Source Homepage](#)

[CiteScore](#) [CiteScore rank & trend](#) [Scopus content coverage](#)

i Improved CiteScore methodology



CiteScore 2021 counts the citations received in 2018-2021 to articles, reviews, conference papers, book chapters and data papers published in 2018-2021, and divides this by the number of publications published in 2018-2021. [Learn more >](#)

CiteScore 2021 ▼

$$0.9 = \frac{3,130 \text{ Citations } 2018 - 2021}{3,573 \text{ Documents } 2018 - 2021}$$

Calculated on 05 May, 2022

CiteScoreTracker 2022 ⓘ

$$0.8 = \frac{3,124 \text{ Citations to date}}{3,887 \text{ Documents to date}}$$

Last updated on 05 October, 2022 • Updated monthly

CiteScore rank 2021 ⓘ

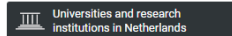
Category	Rank	Percentile
Medicine		
Surgery	#316/469	32nd

[View CiteScore methodology >](#) [CiteScore FAQ >](#) [Add CiteScore to your site](#)

International Journal of Surgery Case Reports

COUNTRY

Netherlands



SUBJECT AREA AND CATEGORY

Medicine
└ Surgery

PUBLISHER

Elsevier BV

H-INDEX

19

PUBLICATION TYPE

Journals

ISSN

22102612

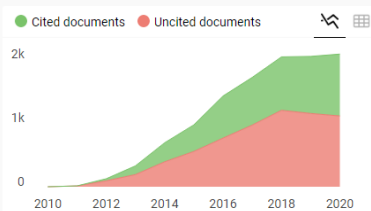
COVERAGE

2010-2020

Support - Scopus journal

Gak takut gangguan internet dengan

Telkomsel



International Journal of Surgery Case Reports

Q3

Surgery

best quartile

SJR 2020
0.23

powered by scimagojr.com

← Show this widget in your own website

Just copy the code below and paste within your html code:

```
<a href="https://www.scimagojr.com" data-bbox="625 511 729 522">
```



ISSN 2210-2612

INTERNATIONAL JOURNAL OF SURGERY CASE REPORTS

Advancing surgery through shared experience



ERUDITIO • DILIGENTIA • FIDES

EST. 2003

Actions for selected articles

Select all / Deselect all

 [Download PDFs](#)

 [Export citations](#)

[Show all article previews](#)

Contents

[Correspondence](#)

[Case Reports](#)

[Case Series](#)

[Corrigendum](#)

Case report • [Open access](#)

Secondary pleuropulmonary amoebiasis due to liver abscess rupture: A complication case report in low resource setting

Putri Mega Juwita, Resti Yudhawati
[Article 106231](#)

[Download PDF](#) [Article preview](#) ▾

Case report • [Open access](#)

Compartment syndrome following intramuscular self-injection of kerosene and rodenticide: A case report

Daniel Asiiimwe, Walufu Ivan Egesa, William Mugowa Waibi, Dickson Kajoba, Patrick Kumbowi Kumbakulu
[Article 106233](#)

[Download PDF](#) [Article preview](#) ▾

Case report • [Open access](#)

Primary left ovarian hydatid cyst presenting as an abdominal mass – Case report

Fareed Ahmad Nazari, Oais Muraveii, Ghulam Yahia Rasat



[FEEDBACK](#) 



ELSEVIER



International Journal of Surgery Case Reports

Editor-in-Chief

Professor David Rosin, Barbados, West Indies

Managing and Executive Editor

Dr Riaz Agha, London, UK

Assistant Managing Editor

Maliha Agha, London, UK

Senior Editors

Professor Hasan Alam, Michigan, USA
Professor Raafat Afifi, Cairo, Egypt
Dr Juan Barret, Barcelona, Spain
Mr Ben Challacombe, London, UK
Dr Xiaoping Chen, Wuhan, China

Dr Burcin Ekser, Indianapolis, USA
Professor Joseph W Y Lau, Shatin, Hong Kong
Dr Oliver Muensterer, New York, USA
Dr Selwyn Rogers, Galveston, Texas
Professor Jamsheer Talati, Karachi, Pakistan

Dr Mangesh Thorat, London, UK
Professor Fu Chan Wei, Tapei, Taiwan
Professor Rudy Leon De Wilde, Oldenburg, Germany

Associate Editors

Professor Roberto Coppola, Rome, Italy
Dr Veerappan Kasivisvanathan, London, UK
Dr Richard Keijzer, Winnipeg, Canada, USA
Dr Boris Kirshtein, Beer Sheva, Israel

Professor James McCaul, London, UK
Miss Emma McGlone, London, UK
Dr Dattatraya Muzumdar, Mumbai, India
Professor Andy Petroianu, Minas Gerais, Brazil

Mr Shahzad Raja, London, UK
Dr Kandiah Raveedran, Ipoh, Malaysia
Dr Daniel Yeh, Boston, USA

Assistant Editors

Dr Rafid Al-Mahfoudh, Oxford, UK
Dr Hussein Atta, Boston, USA
Dr Mohammad Bashashati, Texas, USA
Professor Somprakus Basu, Varanasi, India
Mr Andrew Beamish, Cardiff, UK
Dr Anthony Charles, North Carolina, USA
Dr Amitava Das, Hyderabad, India
Dr Brian Davis, Texas, USA
Dr Susana Adriana Esquivel, Córdoba, Mexico
Professor Sheng Feng, Shanghai, China

Dr Juan Gomez Rivas, Madrid, Spain
Dr Satoshi Ieiri, Kagoshima City, Japan
Dr Haytham Kaafarani, Massachusetts, USA
Dr Yogeesh Kamat, Karnataka, India
Mr Omar Khan, London, UK
Prof. Tsuyoshi Konishi, Osaka, Japan
Dr Vito A Mannacio, Naples, Italy
Dr Todd Manning, Oxford, UK
Dr Zubing Mei, Shanghai, China
Dr Umesh Metkar, Beth, Israel

Dr Indraneil Mukherjee, Staten Island, USA
Dr Enyi Ofo, Adelaide, South Australia
Dr Lena Perger, Albuquerque, USA
Professor Prathamesh S Pai, Mumbai, India
Dr Alfredas Smailys, Kaunas, Lithuania
Prof. Peter Hyunsuk Suh, Seoul, South Korea
Dr Dieter Weber, Perth, Australia
Dr John Wee, Boston, USA
Dr Honggyi Zhu, Shanghai, China

Statistical Editors

Dr Derek Cooper, London, UK
Professor Nora Donaldson, London, UK
Professor Mary W Gray, Washington DC, USA

Society Representative

Deniz Balci, Representative of the International Society of Liver Surgeons
Rhiannon Harries, President, Association of Surgeons in Training
Gene F. Coppa, President of the New York Surgical Society
Xiao-ping Chen, President of the Chinese Chapter of International Hepato-Pancreato-Biliary Association

Social Media Editor

Dr Riaz Agha, London, UK

Assistant Commissioning Editors

Ahmed Al-Jabir, London, UK
Zaid Alsafi, London, UK
Thomas Franchi, Sheffield, UK
Christos Iosifides, London, UK

Ahmed Kerwan, London, UK
Mehdi Khan, London, UK
Ginimol Matthew, London, UK
Maria Nicola, London, UK

Niamh O'Neill, London, UK
Catrin Sohrabi, London, UK

Executive Committee

Professor David Albala, New York, USA
Sir Graeme Catto, London, UK
Professor David Cooper, Pittsburgh, USA
Lord Ara Darzi, London, UK
Professor Harold Ellis, London, UK
Ather Enam, Karachi, Pakistan

Sir Barry Jackson, London, UK
Professor Arthur Li Kwok-Cheung, Wanchai, Hong Kong
Professor C H Leong, Central, Hong Kong
Lord Ian McColl, London, UK

John Norcini, Philadelphia, USA
Professor Susan Standing, London, UK
Lord Robert Winston, London, UK
Sir Magdi Yacoub, London, UK

Editorial Board

Raj Badwe
Mumbai, India
Michael Boscoe
Middlesex, UK
Rapheal Bueno
Boston, USA
Kris Chatamra
Bangkok, Thailand
Paul Coulthard
Manchester, UK
Anil d'Cruz
Mumbai, India
Mahesh Desai
Mumbai, India
Juan Gomez Rivas
Spain, Madrid

David W. Green
London, UK
Iraj Harirchi
Tehran, Iran
Doris Henne-Bruns
Ulm, Germany
Delawir Kahn
Cape Town, South Africa
Xiaoxi Lin
Shanghai, China
Ashok Mahapatra
New Delhi, India
Todd Manning
Melbourne, Australia
Indraneel Mittra
Mumbai, India

Vijay Naraynsingh
West Indies
Fabio Nicoli
London, UK
Anibal R. Núñez De Pierro
Buenos Aires, Argentina
Reuben Orda
Tel Aviv, Israel
Vladimir Semiglazov
St. Petersburg, Russia
Tejinder Singh
Ludhiana, India
Barbara L. Smith
Boston, USA
James Tatum
California, USA

Thehnton Udwardia
Mumbai, India
Martin R. Weiser
New York, USA
Yixin Zhang
Shanghai, China
Jun Zhong
Shanghai, China
Zhao-Fan Xia
Shanghai, China

Elsevier

Executive Publisher

Ash Allan, Oxford, UK
Administrative Editor
Josie Hutchins, Oxford, UK
Marketing Manager
Jayne Dawkins, Philadelphia, USA

Journal Manager

Tamsyn Hopkins, Exeter, UK
Senior Business Development Executive (Reprints)
Emma Steel, London, UK
Advertising Sales Manager
Robert Bayliss, London, UK

Account Manager (Supplements)

Evelina Euren, Amsterdam, the Netherlands
Project Manager Supplements & E-business
Mónica Hernández-Sesma, Amsterdam, the Netherlands



Case report

Secondary pleuropulmonary amoebiasis due to liver abscess rupture: A complication case report in low resource setting

Putri Mega Juwita, Resti Yudhawati*

Department of Pulmonology and Respiratory Medicine, Faculty of Medicine, Universitas Airlangga – Dr. Soetomo General Academic Hospital, Surabaya, Indonesia

ARTICLE INFO

Keywords:

Amoebiasis
Amoebic liver abscess
Empyema
Percutaneous aspiration drainage

ABSTRACT

Background: Pleuropulmonary amoebiasis caused by complications of amoebic liver abscess (ALA) is rare.

Case presentation: A 23 years old male, presented with shortness of breath, cough with yellowish phlegm, right chest pain, fever, bulging stomach, yellow eyes, and swelling of both legs. Abdominal ultrasound and CT scan thorax and abdomen revealed right fluidopneumothorax and liver abscess. Serological testing leads to *Entamoeba histolytica* infection, which was treated with metronidazole but no significant improvement on empyema and abscess liver size. Surgery was performed after percutaneous aspiration drainage failed to evacuate the abscess. HE and PAS staining from surgical tissue showed *Entamoeba histolytica* infection.

Discussion: Serological testing and radiological examination will be more useful in the early detection of cases of *Entamoeba histolytica* infection. Surgery may be considered when purulent drainage does not show improvement in the patient's condition.

Conclusion: ALA complication that causes pulmonary empyema can be surgically treated if the pus cannot be drained.

1. Introduction

Amoebiasis is an infection caused by the parasite *Entamoeba histolytica* with or without clinical manifestations [1,2]. Currently, it is estimated that 40–50 million people suffer from amoebiasis in developing countries and about 40,000 people died from amoebiasis [3]. The incidence of amoebiasis in Indonesia is quite high between 10 and 18%, with a Crude Fatality Rate (CFR) ranging from 1.9%–9.1%. *Entamoeba histolytica* can invade the intestinal mucosa and spread to other organs, especially the liver [1,4,5]. The incidence of amoebic liver abscess (ALA) varies between 3 and 9% of all amoebiasis cases [1,2,6].

Ruptured ALA can result in pleural infection [6], in which pleuropulmonary complications are estimated to occur in 7–20% of patients with ALA and can cause empyema that affects the lung parenchyma and triggers bacterial pneumonia [4,7]. Meanwhile, amoebiasis causing pulmonary empyema is reported as much as 1–2% [3]. Based on the description above, we are interested in reporting a case report of pleuropulmonary amoebiasis due to liver abscess based on the Surgical Case Report (SCARE) 2020 guideline [8].

2. Case presentation

A 23-years old Madurese male presented with a chief complaint of shortness of breath for 2 weeks, worsened 4 days before admission. The patient also complained of cough with yellowish phlegm and right chest pain, fever, bulging stomach, yellow eyes, and swelling of both legs. The patient had a bad habit of consuming water without cooking it first. The patient underwent treatment for 4 days which resulted in chest tube insertion in the right hemithorax and was given anti-tuberculosis drug first category plus empirical antibiotics but no improvement.

On physical examination, we found tachycardia, with Wong-Baker pain scale 3, anemic conjunctiva, sclera jaundice, dyspnea, and trachea being deviated to the left. Right hemithorax was diminished, a chest tube between 5th ribs in the right anterior axillary line of the right hemithorax, decreased palpation fremitus, dim percussion, and decreased vesicular breath sounds in the right hemithorax. The abdomen was distended, dim percussion in the right hypochondrial region, positive shifting dullness, tenderness in all quadrants, palpable liver enlarged 3 cm below the arch of the ribs, the flat surface is not humped. Pitting edema in both lower limbs. Laboratory results showed a

* Corresponding author at: Resti Yudhawati, Department of Pulmonology and Respiratory Medicine, Faculty of Medicine, Universitas Airlangga – Dr. Soetomo General Academic Hospital, Jl. Mayjend Prof. Dr. Moestopo No. 6-8, Airlangga, Gubeng, Surabaya, East Java 60286, Indonesia

E-mail addresses: poe3.mj@gmail.com (P.M. Juwita), resti.yudhawati2021@gmail.com (R. Yudhawati).

<https://doi.org/10.1016/j.ijscr.2021.106231>

Received 20 June 2021; Received in revised form 18 July 2021; Accepted 20 July 2021

Available online 21 July 2021

2210-2612/© 2021 The Authors. Published by Elsevier Ltd on behalf of IJS Publishing Group Ltd. This is an open access article under the CC BY-NC-ND license

(<http://creativecommons.org/licenses/by-nc-nd/4.0/>).

total leukocyte count of 12,190 cells/mm³, neutrophils of 88.4%, serum aspartate aminotransferase (AST) of 221 U/L, and serum alanine aminotransferase (ALT) of 54 U/L. A rapid molecular test of sputum and empyema was *Mycobacterium tuberculosis* not detected. We also checked anti amoeba serology test (ELISA) with a result of 37.8NTU (positive cut off >11NTU).

Chest X-ray showed right fluidopneumothorax and chest tube attached with the distal tip at the level of 4th thoracic vertebrae thoracic 4th and trachea deviated to the left. Abdominal ultrasound showed heterochronic lesions with partially defined borders and irregular edges in the right lobe of the liver which on CDUS examination showed minimal perihilar vascularization suggestive liver abscess. CT scan thorax and abdomen with contrast showed loculated right fluidopneumothorax with thickening parietal and visceral pleura and hepatomegaly accompanied by abscesses with gas-forming in segments VII and VIII of the right lobe of the liver which penetrated the subcapsular liver of the posterior VII-VIII segments with air density represent ruptured liver abscess (Fig. 1).

Reddish-brown pleural fluid was collected from the thorax drain. No protozoa were found from direct smear examination of pleural fluid. From the aerobic culture of pleural fluid, we found *Mycrococcus lylae*. The patient was treated with double antibiotics according to the result of pleural fluid culture and anti amoeba serology test, meropenem 1 g/8 h, and metronidazole 750 mg/8 h intravenous. The patient's condition was improved after 2 weeks of receiving antibiotics but chest X-ray and abdominal ultrasound evaluation showed no significant improvement of right lung and abscess liver size. We had already performed percutaneous aspiration drainage guiding ultrasound for the abscess but failed, so the patient underwent surgery.

The patient underwent surgical decortication and repair of hepato-pleural fistula by thoracic and cardiovascular surgery and drainage of liver abscess by digestive surgery. On exploration, the right sub-diaphragmatic cavity was found in segments VII and VIII of the liver, a thickened and torn diaphragm attached to the liver wall, and condensed pus. Adhesiolysis, diaphragm repair, and intra-cavity and thoracic drainage (Fig. 2). Microbiological examination of abscess did not show bacteria or fungi growth and histopathological examination showed extensive necrotic tissue with suppurative chronic inflammation. Hematoxylin-eosin (HE) and Periodic Acid Schiff (PAS) staining for this preparation showed *Entamoeba histolytica* in both abscesses obtained from the thorax cavity and liver (Fig. 3).

Post-surgery vital signs were stable, SpO₂ was 97%, chest X-ray showed controlled right fluidopneumothorax and abdominal ultrasound results showed Hypochoic lesion without internal moving echo accompanied by peripheral calcification in segment VII, size ±8.1 × 6.4 cm impressive healing process abscess (smaller size than before). The patient was given metronidazole 750 mg/8 h and albumin extract, the patient experienced clinical improvement.

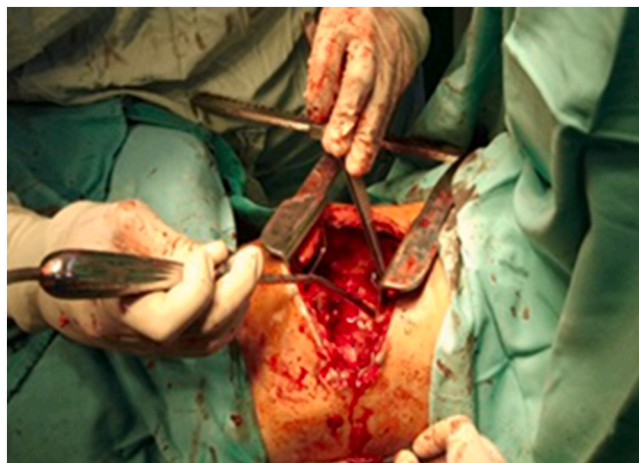

Fig. 2. Adhesiolysis procedure in which the right sub-diaphragmatic cavity and condensed pus were found.

3. Discussion

Liver abscess is the most common extraintestinal complication encountered due to amoebic invasion of the portal vein [1,6,9]. Abscesses are generally homogeneous, containing thick exudate, varying in color from creamy white to reddish brown (anchovies like) caused by digestion of liver tissue. This pus is almost always sterile except when secondary infection occurs due to pyogenic abscesses. Amoeba can be found at the edge of the lesion by microscopic examination but is rarely detected in the pus or in the abscess cavity itself [10,11]. The most important complication is abscess rupture into the peritoneal cavity, pleural cavity, or pericardial cavity depending on the location of the abscess in the liver. As much as 7–20% of ALA will rupture into the pleural cavity and cause empyema [4,7].

During hospitalization, the patient received intravenous metronidazole therapy at a dose of 750 mg/8 h. Most patients with metronidazole show response to treatment (decreased fever and abdominal pain) within 72–96 h [12,13]. Percutaneous needle aspiration is performed in cases of ALA with persistent clinical complaints, large right lobe liver abscess at risk of rupture, left lobe liver abscess, patients who are pregnant, amoebiasis with pleuropulmonary complications, and no clinical progress after administration of medical therapy [14,15]. But, in this case, percutaneous aspiration was failed because the pus was solidified so the patient underwent surgery. Surgical intervention is only performed in patients with multiple abscesses, percutaneous aspiration cannot be done, abscess size is large (> 5 cm), and with complications [1,14].

The high mortality of amoebiasis is caused by socioeconomic factors,

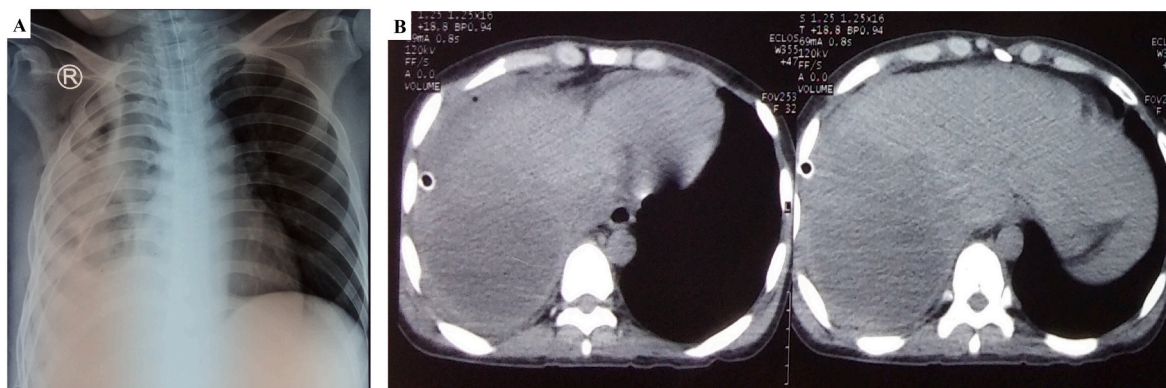


Fig. 1. A. Chest X-ray showed right fluidopneumothorax with chest tube insertion; B. CT scan showed right fluidopneumothorax.

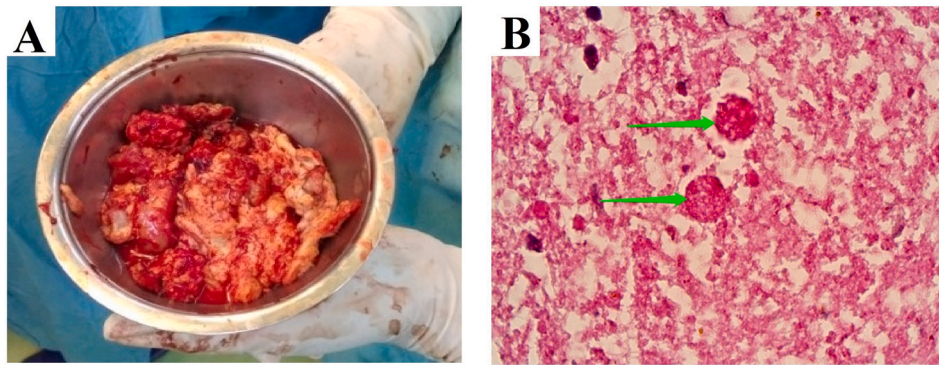


Fig. 3. A. Post-surgery tissue draining pus in the pleural cavity and liver abscess; C. *Entamoeba histolytica* (shown arrows) from HE and PAS staining of the evacuated abscess.

age, malnutrition, late diagnosis, and inadequate treatment [16]. The prognosis of patients with ALA can be easily identified through clinical evaluation, biochemical, and ultrasonographic criteria. Bilirubin levels >3.5 mg/dL, encephalopathy, abscess cavity volume, and hypoalbuminemia are independent risk factors that increase mortality. The duration of symptoms and the type of therapy given did not affect mortality [4,17].

4. Conclusion

A common complication of amoebiasis is a liver abscess, while amoebiasis empyema is very rare. Serological testing and radiological examination will be more useful in the early detection of cases of *Entamoeba histolytica* infection. The process of removing pus in the pleural cavity and liver abscess using a chest tube and percutaneous aspiration drainage guiding ultrasound for the abscess but failed. If the lung condition does not improve after thoracic drainage and the size of the liver abscess does not decrease, surgery may be selected. In this case, surgery and antibiotics have a good prognosis.

Author contribution

Putri Mega Juwita: collecting data, analysis, drafts, revisions, and supervision; Resti Yudhawati: methodology, analysis, drafting, review, submit, and revisions.

Consent

We have requested the patient's consent to publish this case report for educational purposes.

Funding

None.

Ethical approval

We have conducted an ethical approval base on the Declaration of Helsinki at Ethical Committee in Dr. Soetomo General Academic Hospital, Surabaya, Indonesia.

Guarantor

Resti Yudawati.

Research registration

Not applicable.

Provenance and peer review

Not commissioned, externally peer-reviewed.

Declaration of competing interest

The authors declare that they have no conflict of interest.

Acknowledgment

We would like to thank Fis Citra Ariyanto for helping us in the editing and proof process.

References

- [1] J. Blessmann, P. Van Linh, P.A. Nu, H.D. Thi, B. Muller-Myhsok, H. Buss, et al., Epidemiology of amebiasis in a region of high incidence of amebic liver abscess in Central Vietnam, *Am. J. Trop. Med. Hyg.* 66 (5) (2002) 578–583, <https://doi.org/10.4269/ajtmh.2002.66.578>.
- [2] C. Jiménez, P. Morán, L. Rojas, A. Valdez, A. Gómez, M. Ramiro, et al., Novelty on amoebiasis: a neglected tropical disease, *J. Global Infect. Dis.* 3 (2) (2011) 166–174, <https://doi.org/10.4103/0974-777X.81695>.
- [3] A. Zakaria, B. Al-Share, Asad K. Al, Primary pulmonary amebiasis complicated with multicystic empyema, *Case Rep. Pulmonol.* 2016 (2016) 8709347, <https://doi.org/10.1155/2016/8709347>.
- [4] D.N. Amarapurkar, N. Patel, A.D. Amarapurkar, Amoebic liver abscess, *J. Hepatol.* 39 (2) (2003) 291–292, [https://doi.org/10.1016/s0168-8278\(03\)00235-6](https://doi.org/10.1016/s0168-8278(03)00235-6).
- [5] A.H. Wardhana, D.H. Sawitri, F. Ekawasti, E. Martindah, D. Apritadewi, T. Shibahara, et al., Occurrence and genetic identifications of porcine entamoeba, *E. suis* and *E. polecki*, at Tangerang in West Java, Indonesia, *Parasitol. Res.* 119 (9) (2020) 2983–2990, <https://doi.org/10.1007/s00436-020-06806-0>.
- [6] S.L. Stanley Jr., Amoebiasis, *Lancet (London, England)*. 361 (9362) (2003) 1025–1034, [https://doi.org/10.1016/s0140-6736\(03\)12830-9](https://doi.org/10.1016/s0140-6736(03)12830-9).
- [7] S. Martínez, C.S. Restrepo, J.A. Carrillo, S.L. Betancourt, T. Franquet, C. Varón, et al., Thoracic manifestations of tropical parasitic infections: a pictorial review, *Radiographics* 25 (1) (2005) 135–155, <https://doi.org/10.1148/rg.251045043>.
- [8] R.A. Agha, T. Franchi, C. Sohrabi, G. Mathew, A. Kerwan, The SCARE 2020 guideline: updating consensus surgical CAse REport (SCARE) guidelines, *Int. J. Surg.* 84 (2020) 226–230, <https://doi.org/10.1016/j.ijsu.2020.10.034>.
- [9] M. Kantor, A. Abrantes, A. Estevez, A. Schiller, J. Torrent, J. Gascon, et al., *Entamoeba histolytica*: updates in clinical manifestation, pathogenesis, and vaccine development, *Can. J. Gastroenterol. Hepatol.* 2018 (2018) 4601420, <https://doi.org/10.1155/2018/4601420>.
- [10] J.M. Salles, L.A. Moraes, M.C. Salles, Hepatic amebiasis, *Braz. J. Infect. Dis.* 7 (2) (2003) 96–110, <https://doi.org/10.1590/s1413-86702003000200002>.
- [11] S. Saidin, N. Othman, R. Noordin, Update on laboratory diagnosis of amoebiasis, *Eur. J. Clin. Microbiol. Infect. Dis.* 38 (1) (2019) 15–38, <https://doi.org/10.1007/s10096-018-3379-3>.
- [12] M.H. Roshdy, N.M. Abd El-Kader, M. Ali-Tammam, I. Fuentes, M.M. Mohamed, N. A. El-Sheikh, et al., Molecular diagnosis of *Entamoeba* spp. versus microscopy in the great Cairo, *Acta Parasitol.* 62 (1) (2017) 188–191, <https://doi.org/10.1515/ap-2017-0022>.
- [13] G. Khim, S. Em, S. Mo, N. Townell, Liver abscess: diagnostic and management issues found in the low resource setting, *Br. Med. Bull.* 132 (1) (2019) 45–52, <https://doi.org/10.1093/bmb/ldz032>.
- [14] R.N. Priyadarshi, V. Prakash, U. Anand, P. Kumar, A.K. Jha, R. Kumar, Ultrasound-guided percutaneous catheter drainage of various types of ruptured amoebic liver abscess: a report of 117 cases from a highly endemic zone of India, *Abdom. Radiol.* 44 (3) (2019) 877–885, <https://doi.org/10.1007/s00261-018-1810-y>.

- [15] Y.L. Cai, X.Z. Xiong, J. Lu, Y. Cheng, C. Yang, Y.X. Lin, et al., Percutaneous needle aspiration versus catheter drainage in the management of liver abscess: a systematic review and meta-analysis, *HPB (Oxford)* 17 (3) (2015) 195–201, <https://doi.org/10.1111/hpb.12332>.
- [16] V.P. Shenoy, S. Vishwanath, B. Indira, G. Rodrigues, Hepato-pulmonary amebiasis: a case report, *Braz. J. Infect. Dis.* 14 (4) (2010) 372–373.
- [17] R. Neghina, A.A. Neghina, C. Merkle, I. Marincu, I. Iacobiciu, A case report of pulmonary amoebiasis with *Entamoeba histolytica* diagnosed in western Romania, *J. Infect. Dev. Countries* 2 (5) (2008) 400–402, <https://doi.org/10.3855/jidc.206>.



SURAT KETERANGAN

No : 495/301.10/TU/XI/2020

Yang bertanda tangan di bawah ini :

Nama : Isnin Anang Marhana, dr., SpP(K), FCCP, FISR
NIP : 19781107 200604 1 023
Pangkat / Golongan : Pembina / IV a
Jabatan : Ketua Departemen / KSM Pulmonologi & Ilmu Kedokteran
Respirasi FK. UNAIR - RSUD Dr. Soetomo Surabaya

MENGIZINKAN


Kepada: Peneliti Utama : Dr. Resti Yudhawati Meliana, dr.,Sp,P(K)
Peneliti Lain : Putri Mega Juwita
Judul Karya Ilmiah : Amoebiasis pleuropulmonal sekunder akibat ruptur abses hati:
Laporan kasus komplikasi dalam sumber daya terbatas

Untuk melakukan pengambilan data pasien yang dirawat di RSUD Dr. Soetomo dengan dokter penanggung jawab pasien (DPJP) Dr. Resti Yudhawati Meliana, dr.,Sp,P(K) dan telah mendapat persetujuan dan ijin menggunakan informasi rekam medis dengan ketentuan menjaga etika penelitian. Data tersebut dapat dipublikasikan dalam bentuk laporan kasus sebagai pengembangan keilmuan.

Demikian surat keterangan ini dapat dipergunakan sebagaimana mestinya.

Dikeluarkan di : Surabaya
Pada Tanggal : 26 November 2020

Ketua Departemen,


Isnin Anang Marhana, dr., Sp.P(K), FCCP, FISR
NIP. 19781107 200604 1 023

Lampiran :

1. Surat Permohonan Pengambilan Data

Hal : Persetujuan Pengambilan Data

Kepada Yth :
Ketua Departemen
Pulmonologi dan Ilmu Kedokteran Respirasi
RSUD Dr. Soetomo
di Surabaya

Dengan hormat,

Dalam rangka penyelesaian tugas ilmiah PPDS-1 Pulmonologi dan Ilmu Kedokteran Respirasi, peserta didik kami bernama:

Nama : Putri Mega Juwita
NIM : 011718096303
Judul Karya Ilmiah : Amoebiasis pleuropulmonal sekunder akibat ruptur abses hati: Laporan kasus komplikasi dalam sumber daya terbatas
Pembimbing : Dr. Resti Yudhawati Meliana, dr.,Sp.P(K)

Bersama ini kami memohon persetujuan dan perijinan untuk mengambil data rekam medis pasien RSUD Dr. Soetomo di Ruang Palem I dengan dokter penanggung jawab pasien (DPJP) Dr. Resti Yudhawati Meliana, dr.,Sp.P(K). Data tersebut akan kami publikasikan dalam bentuk laporan kasus, maka kami telah berkomitmen untuk menjaga dan menjamin kerahasiaan data pribadi pasien. Atas perhatian dan kerjasamanya kami sampaikan terima kasih.

Surabaya, 26 November 2020
Pemohon,

Dosen Pembimbing


Dr. Resti Yudhawati Meliana, dr.,Sp.P(K)
NIP. 19761206 200912 2 002