

Journal Profile

Folia Medica Indonesiana

eISSN : 2599056X | pISSN :

Education
Universitas Airlangga



S2
Sinta Score

Indexed by GARUDA

11
H-Index

9
H5-Index

778
Citations

502
5 Year Citations



2018



Accreditations

Search..

⏪ ⏩ 1 2 3 4 5 ⏪ ⏩

Page 1 of 47 | Total Records : 463

Publications	Citation
The potency of piperine as antiinflammatory and analgesic in rats and mice SA Sudjarwo Folia Medica Indonesiana 41 (3), 190-194	61
Risk factors for birth asphyxia MT Utarna	38

Citation Statistics

FOLIA MEDICA INDONESIANA

Vol. 56 No. 3 September 2020

QUANTITY OF ANTIBIOTIC USE AND RESISTANCE PATTERN OF GUT NORMAL FLORA *Escherichia coli* AT INTENSIVE CARE UNIT AND TROPIC INFECTION WARD, DR SOETOMO HOSPITAL, SURABAYA, INDONESIA

(Mohammad Akbaruddin Sholeh, Kuntaman, Usman Hadi)

EFFECT OF SIMVASTATIN IN SERUM INTERLEUKIN-6 LEVEL IN PATIENTS WITH ACUTE ISCHEMIC STROKE

(Maria Lettisia Meo, Abdulloh Machin, Didik Hasmono)

INFLUENCE OF ADMINISTERING WATERMELON RIND WATER EXTRACT (*Citrullus vulgaris* Schard) ON GLUCOSE LEVEL OF MALE WHITE RATS (*Rattus norvegicus*) INDUCED WITH STREPTOZOTOSIN

(Hasyim As'ari, Sugiyanta)

CORRELATIONS BETWEEN STAGING AND CHEMOTHERAPY RESPONSE WITH TESTICULAR CARCINOMA NON-SEMINOMA AT DR. SOETOMO HOSPITAL, SURABAYA, INDONESIA

(Achmad Nugroho, Johan Renaldo, Wahjoe Djatisoesanto)

EFFECTIVENESS OF PRE PRP INJECTION AND POST ELEVATION FLAP AT EXTENDED RANDOM FLAP RAT SKIN

(Thomas Eduardus Sudrajat Wahyu Nugroho, Sitti Rizaliyana, David S Perdanakusuma)

ACID PHOSPHATASE AND ZINC TESTS ARE EFFECTIVE FOR SEMEN EXAMINATION AND IDENTIFICATION TO PROVE INTERCOURSE

(Ahmad Yudianto, Ariyanto Wibowo, Indah Nuraini, Htet Htet Aung)

MEAN DIFFERENCES OF TOTAL CHOLESTEROL LEVELS AMONG VEGETARIANS AND NON-VEGETARIANS AT MAHA VIHARA MAITREYA DUTA PALEMBANG, INDONESIA

(Lathifah Nudhar, Subandrate, Susilawati, Liniyanti Oswari)

BLOOD TYPE AND BLOOD PRESSURE CORRELATIONS TO BODY MASS INDEX IN YOUNG ADULTS

(Bambang Edi Suwito, Viskasari P Kalanjati, Abdurachman)

EFFECTIVENESS OF ANTIDIARRHEAL UNRIPE WOODEN BANANA (*Musa paradisiaca* L.) IN MALE Balb-C/MICE INDUCED WITH *Escherichia coli*

(Arista Wahyu Ningsih, Maftuchah Rochmanti, Achmad Basori)

COCHLEAR DYSFUNCTION AFTER KANAMYCIN INJECTION IN MULTIDRUG RESISTANT TUBERCULOSIS PATIENTS

(Aditya Brahmono, Nyilo Purnami, Bakti Surarso)

EFFECT OF HIGH FAT DIET ON WEIGHT LOSS THROUGH THE EXPRESSION OF UNCOUPLE PROTEIN 1 IN MICE VISCERAL FAT

(Indira Syahraya, Hermina Novida, Lilik Herawati, Purwo Sri Rejeki)

IN VITRO CHARACTERIZATION OF POLY-GLYCOLIC LACTIC-CO ACID (PLGA) –COLLAGEN BASED ON RED SNAPPER FISH SCALES (*Lutjanus Sp.*) COATING CHITOSAN AS DURAMATER ARTIFICIAL CANDIDATE

(Hajria Jabbar, Prihartini Widiyanti, Adanti Wido Paramadini, Dina Kartika Putri, Andini Isfandiary)

Case Report:

SURVIVAL OF A CORONAVIRUS DISEASE-2019 (COVID-19) PATIENT WITH ACUTE RESPIRATORY DISTRESS SYNDROME (ARDS) IN DR. SOETOMO HOSPITAL, SURABAYA, INDONESIA

(Soedarsono, Bambang Pudjo Semedi, Rosy Setiawati, Resti Yudhawati Meliana, Tutik Kusmiati, Ariani Permatasari, Arief Bakhtiar, Irmu Syafa'ah, Dwi Wahyu Indrawanto)

**International Online Distribution by ProQuest™
www.proquest.com**

Folia Medica Indonesiana	Vol. 56	No. 2	Page 159-244	Surabaya June 2020	p-ISSN: 2355-8393 e-ISSN: 2599-056X
-----------------------------	---------	-------	--------------	-----------------------	--

FOLIA MEDICA INDONESIA

p-ISSN 2355-8393, e-ISSN 2599-056X

Vol. 56 no. 3 September 2020

Medical journal, published by Airlangga University School of Medicine, Surabaya, publishing original basic medical and clinical articles presented as research articles and review articles

EDITOR-IN CHIEF

Ni Made Mertaniasih, Department of Medical Microbiology, Faculty of Medicine,
Universitas Airlangga, Surabaya, Indonesia

DEPUTY EDITORS

Muhammad Miftahussurur, Department of Internal Medicine, Faculty of Medicine, Universitas Airlangga, Indonesia

EDITORIAL BOARD

Arend Frederik Bos, Division Neonatology, Faculty of Medical Sciences, University of Groningen, Netherlands

Hiroaki Kimura, Department of Physical Medicine and Rehabilitation, Hiroshima University Hospital, Japan

Jitti Hanprasertpong, Division of Gynecologic Oncology, Department of Obstetrics and Gynecology,
Faculty of Medicine, Prince of Songkla University, Hat Yai, Songkhla, Thailand

Anucha Thatrimontrichai, Prince of Songkla University, Thailand

Surasak Sangkhathat, Pediatric Surgery Unit, Department of Surgery, Prince of Songkla University,
Songkhla, Thailand

Aryati, Department of Clinical Pathology, Faculty of Medicine, Universitas Airlangga, Indonesia

Viskasari Pintoko Kalanjati, Department of Anatomy and Histology, Faculty of Medicine,
Universitas Airlangga, Surabaya, Indonesia

Irwanto, Department of Pediatrics, Faculty of Medicine, Universitas Airlangga, Indonesia

Wihasto Suryaningtyas, Department of Neurosurgery, Faculty of Medicine, Universitas Airlangga, Surabaya, Indonesia

Asra Al Fauzi, Department of Neurosurgery, Faculty of Medicine, Universitas Airlangga, Surabaya, Indonesia

Azimatul Karimah, Department of Psychiatry, Faculty of Medicine, Universitas Airlangga, Surabaya, Indonesia

Lucky Prasetiowati, Department of Anatomy & Histology, Faculty of Medicine, Universitas Airlangga, Surabaya, Indonesia

Bambang Purwanto, Department of Medical Physiology, Faculty of Medicine, Universitas Airlangga, Surabaya, Indonesia

MANAGING EDITOR

Ahmad Suryawan, Department of Pediatrics, Faculty of Medicine, Universitas Airlangga, Surabaya, Indonesia

PRODUCTION EDITORS

Moch. Zuhdy, Center for Medical Science Community, Faculty of Medicine, Universitas Airlangga, Surabaya, Indonesia

Athfiyatul Fatati, Center for Medical Science Community, Faculty of Medicine, Universitas Airlangga, Surabaya, Indonesia

Alviana Nur Afifah, Center for Medical Science Community, Faculty of Medicine, Universitas Airlangga, Surabaya, Indonesia

Published by : **GRAMIK (Graha Masyarakat Ilmiah Kedokteran)**
(Center for Medical Science Community)
Quarterly (March, June, September, and December)

Address : **Airlangga University School of Medicine**
Jl. Prof dr Moestopo 47 Surabaya 60131
Phone: 62-31-5013749, 5020251-3 ext. 135
Fax : 62-31-5013749, 62-31-5022472
E-mail: fmi@journal.unair.ac.id, foliamedica@gmail.com

Accredited no. 2/E/KPT/2015

FOLIA MEDICA INDONESIA

p-ISSN 2355-8393, e-ISSN 2599-056X

Vol. 56 no. 3 September 2020

CONTENTS

QUANTITY OF ANTIBIOTIC USE AND RESISTANCE PATTERN OF GUT NORMAL FLORA <i>Escherichia coli</i> AT INTENSIVE CARE UNIT AND TROPIC INFECTION WARD, DR SOETOMO HOSPITAL, SURABAYA, INDONESIA (Mohammad Akbaruddin Sholeh, Kuntaman, Usman Hadi)	159 – 164
EFFECT OF SIMVASTATIN IN SERUM INTERLEUKIN-6 LEVEL IN PATIENTS WITH ACUTE ISCHEMIC STROKE (Maria Lettisia Meo, Abdulloh Machin, Didik Hasmono)	165 – 173
INFLUENCE OF ADMINISTERING WATERMELON RIND WATER EXTRACT (<i>Citrullus vulgaris</i> Schard) ON GLUCOSE LEVEL OF MALE WHITE RATS (<i>Rattus norvegicus</i>) INDUCED WITH STREPTOZOTOSIN (Hasyim As'ari, Sugiyanta)	174 – 177
CORRELATIONS BETWEEN STAGING AND CHEMOTHERAPY RESPONSE WITH TESTICULAR CARCINOMA NON-SEMINOMA AT DR. SOETOMO HOSPITAL, SURABAYA, INDONESIA (Achmad Nugroho, Johan Renaldo, Wahjoe Djatisoesanto)	178 – 185
EFFECTIVENESS OF PRE PRP INJECTION AND POST ELEVATION FLAP AT EXTENDED RANDOM FLAP RAT SKIN (Thomas Eduardus Sudrajat Wahyu Nugroho, Sitti Rizaliyana, David S Perdanakusuma)	186 – 191
ACID PHOSPHATASE AND ZINC TESTS ARE EFFECTIVE FOR SEMEN EXAMINATION AND IDENTIFICATION TO PROVE INTERCOURSE (Ahmad Yudianto, Ariyanto Wibowo, Indah Nuraini, Htet Htet Aung)	192 – 196
MEAN DIFFERENCES OF TOTAL CHOLESTEROL LEVELS AMONG VEGETARIANS AND NON-VEGETARIANS AT MAHA VIHARA MAITREYA DUTA PALEMBANG, INDONESIA (Lathifah Nudhar, Subandrate, Susilawati, Liniyanti Oswari)	197 – 202
BLOOD TYPE AND BLOOD PRESSURE CORRELATIONS TO BODY MASS INDEX IN YOUNG ADULTS (Bambang Edi Suwito, Viskasari P Kalanjati, Abdurachman)	203 – 207
EFFECTIVENESS OF ANTIDIARRHEAL UNRIPE WOODEN BANANA (<i>Musa paradisiaca</i> L.) IN MALE BALB-C/MICE INDUCED WITH <i>Escherichia coli</i> (Arista Wahyu Ningsih, Maftuchah Rochmanti, Achmad Basori)	208 – 215
COCHLEAR DYSFUNCTION AFTER KANAMYCIN INJECTION IN MULTIDRUG RESISTANT TUBERCULOSIS PATIENTS (Aditya Brahmono, Nyilo Purnami, Bakti Surarso)	216 – 222
EFFECT OF HIGH FAT DIET ON WEIGHT LOSS THROUGH THE EXPRESSION OF UNCOUPLE PROTEIN 1 IN MICE VISCERAL FAT (Indira Syahraya, Hermina Novida, Lilik Herawati, Purwo Sri Rejeki)	223 – 228
IN VITRO CHARACTERIZATION OF POLY-GLYCOLIC LACTIC-CO ACID (PLGA) –COLLAGEN BASED ON RED SNAPPER FISH SCALES (<i>Lutjanus Sp.</i>) COATING CHITOSAN AS DURAMATER ARTIFICIAL CANDIDATE (Hajria Jabbar, Prihartini Widiyanti, Adanti Wido Paramadini, Dina Kartika Putri, Andini Isfandiary)	229 – 234
Case Report: SURVIVAL OF A CORONAVIRUS DISEASE-2019 (COVID-19) PATIENT WITH ACUTE RESPIRATORY DISTRESS SYNDROME (ARDS) IN DR. SOETOMO HOSPITAL, SURABAYA, INDONESIA (Soedarsono, Bambang Pudjo Semedi, Rosy Setiawati, Resti Yudhawati Meliana, Tutik Kusmiati, Ariani Permatasari, Arief Bakhtiar, Irmis Syafa'ah, Dwi Wahyu Indrawanto)	234 – 244

Case Report:**SURVIVAL OF A CORONAVIRUS DISEASE-2019 (COVID-19) PATIENT WITH ACUTE RESPIRATORY DISTRESS SYNDROME (ARDS) IN DR. SOETOMO HOSPITAL, SURABAYA, INDONESIA**

Soedarsono^{1,4}, Bambang Pudjo Semedi^{2,4}, Rosy Setiawati^{3,4}, Resti Yudhawati Meliana^{1,4}, Tutik Kusmiati^{1,4}, Ariani Permatasari^{1,4}, Arief Bakhtiar^{1,4}, Irmu Syafa'ah^{1,4}, Dwi Wahyu Indrawanto^{1,4}

¹Department of Pulmonology and Respiratory Medicine, ²Department of Anesthesiology and Reanimation, ³Department of Radiology, Faculty of Medicine, Universitas Airlangga, ⁴Dr. Soetomo Hospital, Surabaya, Indonesia

ABSTRACT

*An outbreak of coronavirus disease 2019 (COVID-19) caused by severe acute respiratory syndrome coronavirus 2 (SARS-CoV-2) that began in Wuhan, China has spread rapidly in multiple countries of the world and has become a pandemic. Currently, there is no vaccine or specific antiviral for COVID-19. A study reported 7.3% of critical patients admitted to ICU, 71% of them required mechanical ventilation, and 38.5% of them were survived. Herein, we reported a 54-year-old man with Acute Respiratory Distress Syndrome (ARDS) of COVID-19 who survived the disease. Real-time reverse transcriptase-polymerase chain reaction (RT-PCR) assay of nasopharyngeal and oropharyngeal swabs were positive for SARS-CoV-2. Diagnosis of ARDS was also according to clinical symptoms, laboratory, chest radiograph, and chest CT scan. *Alcaligenes faecalis* and *Candida albicans* were also identified from sputum culture. Treatment for this patient was causal and supportive therapy, including antibiotic, antiviral, and antifungal therapy according to the culture results, fluid resuscitation, and oxygen supply from the mechanical ventilator. This patient was survived and discharged on hospital day-29. A fibrosis in parenchyma pulmonary and sensory peripheral neuropathy occurred after survived from ARDS. Monitoring of clinical, laboratory, and chest radiograph were continued after the patient discharged from the hospital. This case highlights the importance of early diagnosis and effective treatment to the care of COVID-19 patient.*

Keywords: COVID-19; Acute Respiratory Distress Syndrome

ABSTRAK

*Wabah penyakit coronavirus 2019 (COVID-19) disebabkan oleh severe acute respiratory syndrome coronavirus 2 (SARS-CoV-2) yang pertama dilaporkan di Wuhan, Cina telah menyebar dengan cepat di berbagai negara di dunia dan telah menjadi pandemi global. Belum ada vaksin atau antivirus khusus untuk COVID-19 yang ditemukan hingga saat ini. Sebuah studi melaporkan terdapat 7,3% pasien kritis yang dirawat di ICU, 71% dari mereka membutuhkan ventilator, dan 38,5% dari mereka selamat. Kami melaporkan seorang pria berusia 54 tahun dengan Acute Respiratory Distress Syndrome (ARDS) COVID-19 yang sembuh dari penyakit tersebut. Uji real-time reverse transcriptase-polymerase chain reaction (RT-PCR) sampel nasofaring dan oropharingeal menunjukkan hasil positif SARS-CoV-2. Diagnosis ARDS juga sesuai dengan gejala klinis, laboratorium, fototoraks, dan CT scan. *Alcaligenes faecalis* dan *Candida albicans* juga diidentifikasi dari kultur sputum. Pengobatan untuk pasien ini adalah terapi kausal dan suportif, termasuk terapi antibiotik, antivirus, dan antifungal berdasarkan hasil kultur, resusitasi cairan, dan pasokan oksigen dari ventilator. Pasien ini sembuh dan dipulangkan pada hari ke-29. Fibrosis pada parenkim paru dan neuropati perifer sensorik terjadi setelah sembuh dari ARDS. Pemantauan klinis, laboratorium, dan fototoraks dilanjutkan setelah pasien keluar dari rumah sakit. Kasus ini menunjukkan pentingnya diagnosis dini dan pengobatan yang efektif untuk perawatan pasien COVID-19.*

Kata kunci: COVID-19; Acute Respiratory Distress Syndrome

Correspondence: Soedarsono, Jl. Mayjen Prof. Dr. Moestopo No. 6-8 Surabaya, East Java, Indonesia. E-mail: ssoedarsono@gmail.com

pISSN:2355-8393 • eISSN: 2599-056x • doi:

- Fol Med Indones. 2020;56: 235-244 • Received 20 Jun 2020 • Accepted 13 Aug 2020
- Open access under CC-BY-NC-SA license • Available at <https://e-journal.unair.ac.id/FMI/>

INTRODUCTION

On December 2019, several pneumonia cases of unknown etiology have been reported in Wuhan, Hubei province, China, with clinical presentations greatly resembling viral pneumonia (WHO 1 2020, Huang et al 2020). Deep sequencing analysis from lower respiratory tract samples indicated a novel coronavirus and the term 2019 novel coronavirus (2019-nCoV) was used by the World Health Organization (WHO) referring to this novel coronavirus (Huang et al 2020). The WHO announced the official name for the disease as coronavirus disease 2019 (COVID-19) and the official name for the virus was severe acute respiratory syndrome coronavirus 2 (SARS-CoV-2) (WHO 2 2020).

Currently, there is no vaccine or specific antiviral for COVID-19. A better understanding of COVID-19 management including supportive therapy was needed. Several reports have described the epidemiology and clinical features of COVID-19 cases. More specifically, through a detailed and comprehensive strategy, this report described the symptoms, biological abnormalities, radiographic abnormalities, and treatment of a case of COVID-19 with Acute Respiratory Distress Syndrome (ARDS) in Surabaya, Indonesia.

CASE REPORT

A 54-year-old man presented with viral pneumonia and respiratory failure on March 10, 2020. The patient was a nonsmoker. He had a long history of cough and there was no history of diabetes mellitus, hypertension, asthma, and tuberculosis. On admission to a private hospital, the patient reported a history of a one-week dry cough, headache, myalgia, and dyspnea followed with chest pain on illness day 7 (Table 1). The physical examination revealed a body temperature of 37.3 0C, blood pressure of 144/88 mmHg, pulse rate of 107 beats per minute, respiratory rate of 30 breaths per minute, and oxygen saturation of 95%. Clinical laboratory examination was done on the 1st day of hospitalization. It showed a low lymphocyte of 13.5 % and a high C-reactive protein of 242.7 mg/L (Table 2). First examination of chest X-ray and chest CT scan on the same day. Chest X-ray showed dominant bilateral opacity in the 2/3 lower lung, partially homogenous and patchy (Fig. 1). Chest CT scan showed extensive confluent ground glass opacity in the right superior and medial lobe, left superior lobe and lingual (dominantly in the peripheral zone), followed with consolidation in the bilateral right inferior lobe as seen in Fig. 2.

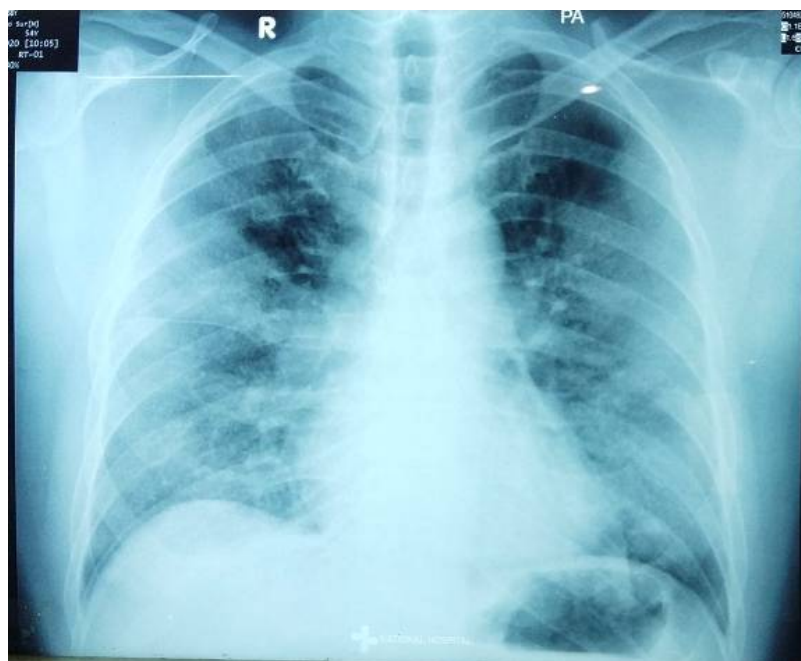


Fig. 1. Chest X-Ray, 10 March 2020 (Illness Day 7, Hospital Day 1).

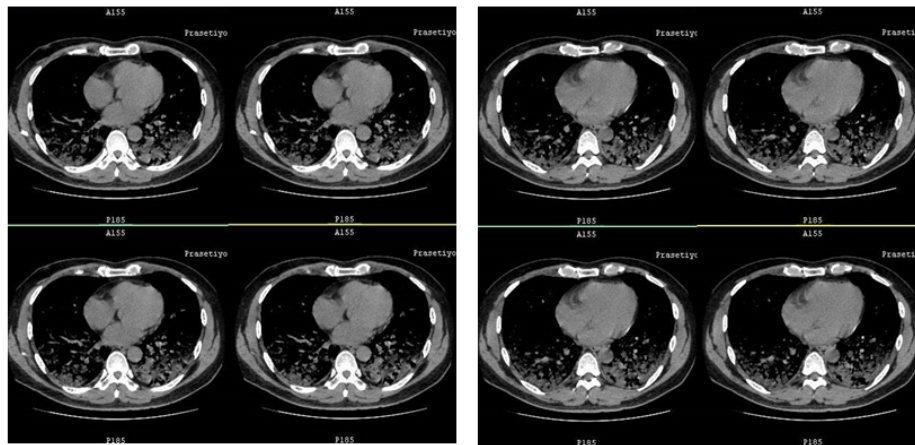


Fig. 2. Chest CT Scan, 10 March 2020 (Illness Day 7, Hospital Day 1).

Initial blood gas analysis of this patient showed severe hypoxemia ($\text{PaO}_2/\text{FiO}_2 = 68.39$). According to the Berlin definition, this was defined as severe oxygenation ($\text{PaO}_2/\text{FiO}_2 = 100$ mmHg with PEEP = 5 cm H₂O) (ARDS Definition Task Force 2012). Starting on the first hospitalization, the patient received a combination of antibiotics consisted of meropenem injection 1g every 8 hours, and Levofloxacin injection 750 mg every 24 hours, as well as supporting therapy. On the 2nd day of hospitalization (day 8 of illness), he reported a heavier shortness of breath. The patient was then transferred to Dr. Soetomo Hospital, one of the referral hospitals, to be treated in the ICU isolation room. Specimens such as blood, sputum, nasopharyngeal, and oropharyngeal swab specimens were to identify SARS-CoV-2, bacterial, and fungal culture examinations. The patient was also supported by O₂ NRM 15 lpm and then replaced by O₂ ventilator PEEP 8, FiO₂ 50% on the following day. Diagnosis of ARDS was established according to acute onset, severe hypoxemia ($\text{PaO}_2/\text{FiO}_2 < 200$) and diffuse bilateral pulmonary infiltrate on a chest X-ray or CT Scan Thorax.

The patient's nasopharyngeal and oropharyngeal swabs tested positive for SARS-CoV-2 by real-time reverse transcriptase-polymerase chain reaction (RT-PCR) assay. The general condition of the patient was weak with GCS of 4/5. Vital signs of body temperature and SO₂ were in normal ranges (36.9 °C and 95%, respectively), while other vital signs were out of normal ranges (blood pressure of 133/88 mmHg, pulse rate of 107 beats per minute, and respiratory rate of 30 times per minute). On hospital day 8, vital signs showed 162/98 mmHg of blood pressure, 121 beats per minute of pulse rate, and 24 times per minute of respiratory rate.

Added therapy during hospitalization were including Chloroquine for 10 days, Isoprenosin 500 mg every 8 hours given via nasogastric tube (NGT) for 7 days, 2 tablets of Lopinavir/Ritonavir every 12 hours for 7 days. Chloroquine and Lopinavir/Ritonavir were given based on the patient's severity/worsening clinical status.

Alcaligenes faecalis and *Candida albicans* were isolated from the sputum culture on hospital day 8. *Alcaligenes faecalis* was susceptible to Piperacillin-Tazobactam and *Candida albicans* was susceptible to Fluconazole sensitive. Meropenem injection and Levofloxacin were discontinued after given for 8 days and replaced with Piperacillin-Tazobactam pump 4.5 gr every 6 hours, then Fluconazole was started with the initial dose of 1x400 mg and followed by 1x200 mg every 24 hours. The patient experienced septic shock and hypoalbuminemia (2.9 g/dL) on hospital day 10 or illness day 16. Other than NGT diet of 200 ml every 4 hours and supported with O₂ ventilator PEEP 6, FiO₂ 55%, Triofusin IVFD E1000 500 ml in 24 hours, albumin infusion, and Norepinephrine pump starting from 50 nano.

General condition on day 6 to 9 of hospitalization (day 12 to 15 of illness) was shown with GCS of 1/1 (on sedation), and on day 10 to of hospitalization (day 16 to of illness) was shown with GCS of 1x1 (intubated). The following RT-PCR for SARS-CoV-2 showed negative on illness day 16 (hospital day 10). Serial chest X-ray on hospital day 6 to hospital day 22 showed a slow improvement (Fig. 3). On hospital day 16 (illness day 22), the clinical condition of the patient was improved, the dyspnea was getting better but still experienced an infrequent cough and weaning ventilator was done. Oxygen supply was replaced with a simple mask. Piperacillin-Tazobactam was given for 10 days, while Fluconazole was given for 3 weeks.

Table 1. Symptoms According to Day of Illness and Day of Hospitalization, March 4 to March 26, 2020

		Hospital (Day)																	
		Pre-hosp	D 1	D 2	D 3	D 4	D 5	D 6	D 7	D 8	D 9	D 10	D 11	D 12	D 13	D 14	D 15	D 16	
Day of illness		1-2	3-6	7	8	9	10	11	12	13	14	15	16	17	18	19	20	21	22
		Lab	Private Hospital					Dr. Soetomo Hospital											
Fever (°C)	Subjective fever	37.3	37.2	37.5	37.1	37.2	36.9	36.9	36	36.6	36.6	37.4	36.8	36.5	36.5	36.5	36.8	36.8	
Dry cough																			
Dyspnea																			
Myalgia																			
Headache																			
Respiratory failure			I	I	I	I	I	I	II	II	II	II	II	II					
Sensory peripheral neuropathy																			
Date (March 2020)		4-5	6-9	10	11	12	13	14	15	16	17	18	19	20	21	22	23	24	25

Table 2. Clinical Laboratory Results

Date (2020)		10 Mar	13 Mar	15 Mar	18 Mar	21 Mar	24 Mar	27 Mar	2 Apr
Measure	Reference Range	ID-7 HD-1	ID-10 HD-4	ID-12 HD-6	ID-15 HD-9	ID-18 HD-12	ID-21 HD-15	ID-27 HD-	ID-2 HD-
White blood cell (10 ³ /uL)	4.8-10.8	5.2	9.36	11.69	11.96	-	15.96	7.75	7.68
Lymphocyte (%)	19-48	13.5	5.8	3.7	4.0	-	6.2	9	15.9
Platelet (10 ³ /uL)	150-450	233	317	110	108	-	254	353	486
Hemoglobin (g/dL)	12-16	17.5	16.7	15.8	15.8	-	15.3	14.1	14.7
Hematocrit (HCT) (%)	37.7-53.7	49.3	45.9	46.9	47.9	-	45.2	40.4	42.8
Sodium (Na) (mmol/l)	136-145	-	132.6	138	133	137	143	-	-
Potassium (K) (mmol/l)	3.5-5.1	-	3.79	4.5	4.3	3.4	3.4	-	-
Glucose (mg/dL)	100-125	97	-	140	126	218	92	-	-
Blood urea nitrogen (mg/dL)	7-18	18	10	13	18	24	30	-	-
Creatinine (mg/dL)	0.6-1.3	1.0	0.6	0.7	0.8	1.0	0.86	-	-
Albumin (g/dL)	3.4-5	3.6	3.4	3.0	3.0	3.3	3.2	-	-
SGOT (U/L)	0-50	71.9	57.2	58	29	-	66	-	-
SGPT (U/L)	0-50	40.1	40.3	87	36	-	107	-	-
Procalcitonin (ng/ml)	<0.05	0.78	4.06	-	-	-	-	0.05	0.02
C-reactive protein (mg/L)	<6	242.7	94.5	-	-	-	13.8	-	-

Note: ID = Illness Day-, HD = Hospital Day-

Table 3. Blood Gas Analysis

	Hospital (Day)											
	D 2	D 4	D 6	D 7	D 8	D 9	D 10	D 11	D 12	D 13	D 14	D 15
Day of illness	8	10	12	13	14	15	16	17	18	19	20	21
pH	7.53	7.56	7.41	7.3	7.14	7.42	7.24	7.33	7.42	7.48	7.53	7.47
pCO ₂	26.9	31.1	33	63	83	57	57	55	49	37	47	42
pO ₂	55.4	79.4	91	93	112	80	89	99	96	74	78	71
HCO ₂	23	28.3	20.9	31	28.3	37	24.4	29	31.8	27.6	39.3	30.6
BE	2.2	3.3	-3.7	4.6	-0.7	12.5	-3.0	3.1	7.3	4.1	16.6	6.9
SO ₂	92.6	97.5	95	96	97	96	95	97	98	96	97	95
PaO ₂ / FiO ₂	68.39	115.07	182	-	224	145	148	15	240	185	195	180
A-aDO ₂	488.5	373.7	219	185	246	-	553	260.1	-	165	148.4	161.7
	March 2020											
Date	11	13	15	16	17	18	19	20	21	22	23	24

Table 4. Results of Real-Time Polymerase Chain Reaction Testing for SARS-CoV-2

Specimen	Illness Day 11 Hospital Day 5 (14 Mar 2020)	Illness Day 16 Hospital Day 10 (18 Mar 2020)	Illness Day 20 Hospital Day 14 (23 Mar 2020)
Nasopharyngeal swab	Positive	Negative	Negative
Oropharyngeal swab	Positive	Negative	Negative

Table 5. Given Supportive Therapy for Patient

	Hospital (Day)															
	D 1	D 2	D 3	D 4	D 5	D 6	D 7	D 8	D 9	D 10	D 11	D 12	D 13	D 14	D 15	D 16
Day of illness	7	8	9	10	11	12	13	14	15	16	17	18	19	20	21	22
Therapy																
IVFD	■	■	■	■	■	■	■	■	■	■	■	■	■	■	■	■
O ₂ NRM 15 ml			■	■	■	■										
O ₂ ventilator							■	■	■	■	■	■	■	■	■	
O ₂ simple mask 6 lpm																■
NE 50 nano											■	■	■			
NE 25 nano													■			
Meropenem inj 1gr				■	■	■	■	■	■	■						
Levofloxacin 750 mg		■	■	■	■	■	■	■								
Piperacillim-tazobactam pump: 4.5 gr										■	■	■	■	■	■	■
Isoprenosin 500 mg									■	■	■	■	■	■	■	
Lopinavir/ritonavir 2x2										■	■	■	■	■	■	■
Chloroquine										■	■	■	■	■	■	■
Fluconazole 1x400 mg									■							
Fluconazole 1x200 mg										■	■	■	■	■	■	■
Methylcobalt 500 mg																■
Alinamin F																■
Provelyn 75 mg																■
Date	March 2020															
	10	11	12	13	14	15	16	17	18	19	20	21	22	23	24	25

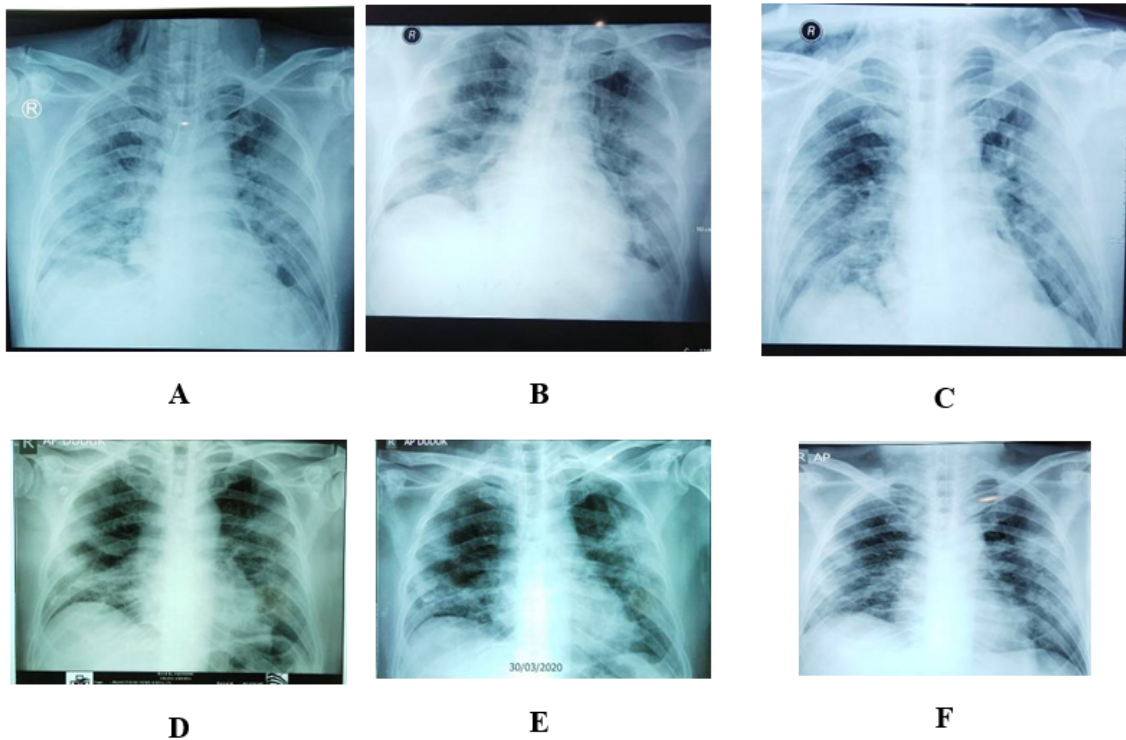


Fig. 3. Serial Chest Radiograph Showed A Slow Improvement (A-I). A. 15 March 2020 (Illness Day 12, Hospital Day 6); B. 16 March 2020 (Illness Day 13, Hospital Day 7); C. 19 March 2020 (Illness Day 16, Hospital Day 10); D. 27 March 2020 (Illness Day 24, Hospital Day 18); E. 30 March 2020 (Illness Day 27, Hospital Day 19); F. 2 April (Illness Day 30, Hospital Day 22).

Evaluation of chest CT scan of the patient on 7 April 2020 (illness day 35, hospital day 29) showed fibrosis in the lung peripheral basal and peripheral apex, dominantly in the posterior side of the right lung and inferior lobe of the left lung. Minimal ground glass opacity appeared on the posterior side of the right lung. A left bronchial retraction with minimal hilar retraction was seen. Trachea looked patent. Overall, minimal

pneumonia was seen in the anterior segment of the superior lobe of the right lung, extensive fibrosis accompanied by predominantly ground glass opacity in the bilateral peripheral lung base (Fig. 4). On this evaluation day of chest CT scan, the patient’s vital signs were stable and light mobility without an oxygen supply.

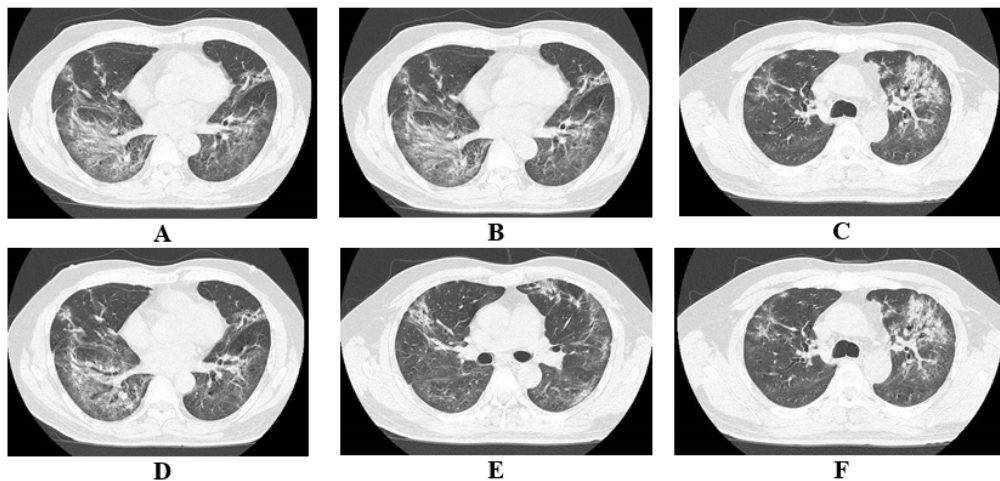


Fig. 4. Serial of Chest CT Scan, 7 April 2020 (Illness Day 35, Hospital Day 29)

DISCUSSION

This patient was discharged on hospital day 29 (7 April 2020). A lung fibrosis was shown by chest CT scan (Fig. 4). Chang et al (2018) reported a pneumonia patient with persistent lung fibrosis and new onset of ground glass opacity (GGO). After antibiotics treatment, the patient was discharged and was followed up at the outpatient clinic. The patient has received a short course of corticosteroid treatment (prednisolone 10 mg) daily for 3 months. After 7 months of illness, the chest CT showed resolution of the GGO and a significant improvement in lung fibrosis. One year after the illness, his pulmonary function was normal: the forced vital capacity 80%, forced expiratory volume in 1 s 86%, diffusing capacity for carbon monoxide 61%, and diffusing capacity divided by the alveolar volume 80%. He returned to his normal daily activities (Chang et al 2018).

A study in China reported of the 710 patients with SARS-CoV-2 pneumonia, 52/710 (7.3%) were critical patients treated in the ICU. Of the 52 critical patients, 32/52 (61.5%) died, 20/52 (38.5%) survived, 35/52 (67%) had ARDS, and 37/52 (71%) required mechanical ventilation (Yang et al 2020). In our hospital, there were 14 critical patients treated in the ICU. All critical patients had ARDS (100%). Of the 14 critical patients, 4/14 (28.5%) patients still receive ventilator, 3 (21.5%) patients survived, 1 (7%) patient is weaning ventilator (low care), and 6/14 (43%) died with *causa mortis* of acute kidney injury (AKI) and septic shock.

The most symptoms of survivors among critical patients with COVID-19 are fever (100%), cough (75%), dyspnea (60%), myalgia (10%), malaise (20%), arthralgia (5%), chest pain (5%), headache (5%), and vomiting (5%) (Yang et al 2020). Fever is often the major and initial symptom of COVID-19, which can be accompanied by no symptom or other symptoms such as dry cough, shortness of breath, muscle ache, dizziness, headache, sore throat, rhinorrhea, chest pain, diarrhea, nausea, and vomiting. Some patients experienced dyspnea and/or hypoxemia one week after the onset of the disease (Guan et al 2020). The early clinical and laboratory findings of COVID-19 pneumonia are fever, dry cough, and fatigue with normal WBC count, reduced lymphocyte count, and elevated C-reactive protein level (Han et al 2020). Our case presented symptoms of fever, dry cough, headache, myalgia and experienced dyspnea followed with chest pain on illness day 7. Laboratory findings are normal WBC count, low lymphocyte, high procalcitonin, and high C-reactive protein.

Comorbidities in COVID-19 patients were diabetes mellitus, hypertension with complications of acute respiratory distress syndrome (ARDS), acute kidney injury, cardiac injury, liver dysfunction, gastrointestinal hemorrhage, hospital-acquired pneumonia, bacteremia, and urinary tract infection (Yang et al 2020, Guan et al 2020). Bacteremia and fungal coinfection were found only in non survived patients. *Klebsiella pneumoniae*, *Pseudomonas aeruginosa*, *Serratia marcescens*, *Aspergillus flavus*, and *Aspergillus fumigates* were identified from respiratory tract secretions, and *Candida albicans* was identified in the urine culture (Yang et al 2020). Our case only had comorbidity of chronic bronchitis. *Alcaligenes faecalis* and *Candida albicans* were identified from sputum culture.

A study of 52 critical patients with COVID-19 reported 33 (63.5%) patients were treated with a high-flow nasal cannula, 37 (71%) with mechanical ventilation, 6 (11.5%) with prone position ventilation, 6 (11.5%) with extracorporeal membrane oxygenation (ECMO) (Yang et al 2020), while our case received supplemental oxygen of NRM, mechanical ventilator, and a simple mask.

Antiviral agents consisted of oseltamivir, ganciclovir, and lopinavir were given to 18 (35%), 14 (27%), and 7 (13.5%) patients, respectively (Yang et al 2020), while our case received lopinavir/ritonavir and chloroquine as antiviral treatment. Yang et al (2020) reported 49 (94%) patients received antibacterial agents, while our case received empirical antibiotics of levofloxacin and meropenem. After culture result was obtained, piperacillin-tazobactam was given as definitive antibiotic therapy according to the culture result (Yang et al 2020). Yang et al (2020) did not report any patient received antifungal therapy (Yang et al 2020), while our case received fluconazole according to the culture result showed *Candida albicans*. The detail of supportive therapy for our case was presented in Table 5.

As shown in Table 4, the initial nasopharyngeal and oropharyngeal swabs obtained from this patient on illness day 11 (hospital day 5) were positive for SARS-CoV-2. The specimens tested negative for SARS-CoV-2 on illness day 16 (hospital day 10), while Holshue et al (2020) reported the initial specimens obtained on illness day 4 tested positive for SARS-CoV-2. On illness day 12, the oropharyngeal swab tested negative for SARS-CoV-2. The nasopharyngeal swab remained positive for SARS-CoV-2 on illness day 12, but showed decreasing levels of virus. The patient received acetaminophen, ibuprofen, and guaifenesin for symptom management. Vancomycin and cefepime were given as antibiotics. Remdesivir was given as antiviral (Holshue et al 2020).

The early CT findings of COVID-19 are patchy ground glass opacity with or without consolidation involving multiple lobes, mainly in the peripheral zone, accompanied by halo sign, vascular thickening, crazy paving pattern, or air bronchogram sign (Han et al 2020), the most common patterns on chest CT were ground-glass opacity (56.4%) and bilateral patchy shadowing (51.8%) (Guan et al 2020). Abnormalities in chest radiography of COVID-19 patients featured by bilateral patchy shadows or ground glass opacity in the lungs. Patients often develop atypical pneumonia, acute lung injury, and acute respiratory distress syndrome (ARDS). When ARDS happens, uncontrolled inflammation, fluid accumulation, and progressive fibrosis severely compromise the gas exchange (Yi et al 2020). Chest radiograph of our case showed dominant bilateral opacity in the 2/3 lower lung, partially homogenous and patchy. Chest CT scan showed extensive confluent ground glass opacity in the right superior and medial lobe, left superior lobe, and lingual (dominantly in the peripheral zone), followed with consolidation in the bilateral right inferior lobe.

The long-term sequelae in patients with severe pneumonia, although not available for the present, could be the fibrotic changes such as reticulation, interlobular septal thickening, and traction bronchiectasis, which are usually seen in the fibrotic phase of lung injury (Kim et al 2020). At the end of treatment, our case's chest CT scan showed fibrosis in the peripheral basal and peripheral apex, dominantly in the posterior side of the right lung lobe and inferior side of the left lung lobe. Minimal ground glass opacity was presented in the posterior side of the right lung lobe. Minimal hilar retraction was also presented.

Our case reported sensory peripheral neuropathy symptoms of SARS-CoV-2 infection (felt after awake post-extubation). Troyer et al (2020) stated that following past influenza pandemics and CoV outbreaks, such complications have been described over highly variable periods, from weeks following acute respiratory symptoms in the case of neuromuscular and demyelinating processes, to decades after in-utero exposure to viral infection in the case of schizophrenia onset. Whether recovered SARS-CoV-2 patients will exhibit an increased incidence of delayed neurologic sequelae is currently unknown and remain to be seen over the next several months to years (Troyer et al 2020).

CONCLUSION

In conclusion, our case survived from COVID-19 after experienced ARDS. Many factors may play a role in

this survival case, including age, little comorbid, and the implementation of early supportive therapy, early initial antibiotic and on time use of the mechanical ventilator. Rapid diagnosis, wise use of diagnosis tools, and effective treatment including antibiotic, antiviral, antifungal, and supportive therapy were needed to manage this patient in the pandemic area.

REFERENCES

- ARDS Definition Task Force (2012). Acute respiratory distress syndrome: the Berlin Definition. *JAMA* 307, 2526-2533
- Chang CH, Juan YH, Hu HC, Kao KC, Lee CS (2018). Reversal of lung fibrosis: an unexpected finding in survivor of acute respiratory distress syndrome. *QJM: Int J Med* 111, 47-48
- Guan W, Ni Z, Hu Y, Liang W, Ou C, He J (2020). Clinical characteristics of coronavirus disease 2019 in China. *N Engl J Med* 382, 1708-1720
- Han R, Huang L, Jiang H, Dong J, Peng H, Zhang D (2020). Early clinical and CT manifestation of coronavirus disease 2019 (COVID-19) pneumonia. *Am J Roentgenol* 215, 1-6
- Holshue ML, DeBolt C, Lindquist S, Lofy KH, Wiesman J, Bruce H, et al (2020). First case of 2019 novel coronavirus in the United States. *N Engl J Med*, doi:10.156/NEJMoa2001191
- Huang C, Wang Y, Li X, Ren L, Zhao J, Hu Y, Zhang L, Fan G, et al (2020). Clinical features of patients infected with 2019 novel coronavirus in Wuhan, China. *Lancet*, [https://doi.org/10.1016/S0140-6736\(20\)30183-5](https://doi.org/10.1016/S0140-6736(20)30183-5)
- Kim, J.E., Heo, J.H., Kim, H.O., Song, S.H., Park, S.S., Park, T.H., Ahn, J.Y., Kim, M.K., Choi, J.P (2017). Neurological complications during treatment of middle east respiratory syndrome. *J Clin Neurol* 13, 227-233
- Troyer EA, Kohn JN, Hong S (2020). Are we facing a crashing wave of neuropsychiatric sequelae of COVID-19?: neuropsychiatric symptoms and potential immunologic mechanisms. *Brain, Behavior, and Immunity*, doi: <https://doi.org/10.1016/j.bbi.2020.04.027>
- World Health Organization 1 (2020). Novel coronavirus – China. Available from <http://www.who.int/csr/don/12-january-2020-novel-coronavirus-china/en/>. Accessed Jan 19, 2020
- World Health Organization 2 (2020). Naming the coronavirus disease (COVID-19) and the virus that causes it. Available from [https://www.who.int/emergencies/diseases/novel-coronavirus-2019/technical-guidance/naming-the-coronavirus-disease-\(covid-2019\)-and-the-virus-that-causes-it](https://www.who.int/emergencies/diseases/novel-coronavirus-2019/technical-guidance/naming-the-coronavirus-disease-(covid-2019)-and-the-virus-that-causes-it). Accessed Mar 24, 2020

Yang X, Xu J, Shu H, Xia J, Liu H, Wu, et al (2020). Clinical course and outcomes of critically ill patients with SARS-CoV-2 pneumonia in Wuhan, China: a single-centered, retrospective, observational study. *Lancet Respir Med*, [https://doi.org/10.1016/S2213-2600\(20\)30079-5](https://doi.org/10.1016/S2213-2600(20)30079-5)

Yi Y, Lagniton PNP, Ye S, Li E, Xu RH (2020). COVID-19: what has been learned and to be learned about the novel coronavirus disease. *Int J Biol Sci* 16, 1753-1766

Hal : Persetujuan Pengambilan Data

Kepada Yth :
Ketua Departemen
Pulmonologi dan Ilmu Kedokteran Respirasi
RSUD Dr. Soetomo
di Surabaya


Dengan hormat,

Saya yang bertandatangan di bawah ini:

Nama : Dr. Soedarsono, dr., Sp.P(K)
NIP : 195511231984101001
Judul Karya Ilmiah : Survival of A Coronavirus Disease-2019 (Covid-19)
Patient with Acute Respiratory Distress Syndrome
(ARDS) in Dr. Soetomo Hospital, Surabaya, Indonesia

Bersama ini kami memohon persetujuan dan perijinan untuk mengambil data rekam medis pasien RSUD Dr. Soetomo di Ruang Palem I dengan dokter penanggung jawab pasien (DPJP) Dr. Soedarsono, dr., Sp.P(K). Data tersebut akan kami publikasikan dalam bentuk laporan kasus, maka kami telah berkomitmen untuk menjaga dan menjamin kerahasiaan data pribadi pasien. Atas perhatian dan kerjasamanya kami sampaikan terima kasih.

Surabaya, 26 Januari 2020
Pemohon,



Dr. Soedarsono, dr., Sp.P(K)
NIP. 195511231984101001



UNIVERSITAS AIRLANGGA
FAKULTAS KEDOKTERAN
DEPARTEMEN PULMONOLOGI & ILMU KEDOKTERAN RESPIRASI

Jl. Mayjen Prof.Dr.Moestopo No. 6 – 8 Surabaya
Telp. 031.5501656 ; e-mail : pulmoua@gmail.com

SURAT KETERANGAN

No : 024/UN3.1.1/TU/I/2020

Yang bertanda tangan di bawah ini :

Nama : Isnin Anang Marhana, dr., SpP(K), FCCP, FISR
NIP : 19781107 200604 1 023
Pangkat / Golongan : Pembina / IV a
Jabatan : Ketua Departemen / KSM Pulmonologi & Ilmu Kedokteran
Respirasi FK. UNAIR - RSUD Dr. Soetomo Surabaya

MENGIZINKAN

Kepada: Peneliti Utama : Dr. Soedarsono, dr., Sp.P(K)
Judul Karya Ilmiah : Survival of A Coronavirus Disease-2019 (Covid-19) Patient with
Acute Respiratory Distress Syndrome (ARDS) in Dr. Soetomo
Hospital, Surabaya, Indonesia

Untuk melakukan pengambilan data pasien yang dirawat di RSUD Dr. Soetomo dengan dokter penanggung jawab pasien (DPJP) Dr. Soedarsono, dr., Sp.P(K) dan telah mendapat persetujuan dan ijin menggunakan informasi rekam medis dengan ketentuan menjaga etika penelitian. Data tersebut dapat dipublikasikan dalam bentuk laporan kasus sebagai pengembangan keilmuan.

Demikian surat keterangan ini dapat dipergunakan sebagaimana mestinya.

Dikeluarkan di : Surabaya
Pada Tanggal : 26 Januari 2020

Ketua Departemen



Isnin Anang Marhana, dr., Sp.P(K), FCCP, FISR
NIP. 19781107 200604 1 023

Lampiran :

1. Surat Permohonan Pengambilan Data