

# The Expression of Tumor Necrosis Factor Alpha and Alkaline Phosphatase Due to Induction of Combination Calcium Hydroxides and Propolis

*by* Nanik Zubaidah

---

**Submission date:** 22-Jan-2022 08:54PM (UTC+0800)

**Submission ID:** 1745938258

**File name:** to\_Induction\_of\_Combination\_Calcium\_Hydroxides\_and\_Propolis.pdf (2.27M)

**Word count:** 4242

**Character count:** 23040

## The Expression of Tumor Necrosis Factor Alpha and Alkaline Phosphatase Due to Induction of Combination Calcium Hydroxides and Propolis

Nanik Zubaidah<sup>1\*</sup>, Ira Widjiastuti<sup>1</sup>, Nirawati Pribadi<sup>1</sup>, Fresynandia Karyneisa Putri<sup>2</sup>,  
Reyz Pasenda Muljadi<sup>2</sup>, Felina Lucia Charyadie<sup>2</sup>, Khusnul Khotimah<sup>2</sup>

1. Staff of Conservative Dentistry Department, Faculty of Dental Medicine Universitas Airlangga, Indonesia.

2. Resident of Conservative Dentistry Department, Faculty of Dental Medicine Universitas Airlangga, Indonesia.

### Abstract

Exposed pulp will produce pro-inflammatory cytokines, which are the main target in inhibiting inflammation of the pulp. Early reparative dentin formation begins with the synthesis of extracellular matrix dentin such as type I collagen, which is believed to be the key of successful pulp capping treatment. Propolis is an alternative pulp capping material that is known to reduce inflammation in the exposed pulp. Calcium hydroxide (CH) is the gold standard for pulp capping material but many studies have shown some limitations on calcium hydroxide. This study was conducted to determine the expression of TNF- $\alpha$  and ALP after the application of a combination of calcium hydroxide and propolis extract as pulp capping material.

The maxillary first molars of sixty rats (Wistar) were mechanically perforated. Teeth were divided into 3 groups containing 20 each. Group I as a control, group II treated with calcium hydroxide, group III treated with calcium hydroxide and propolis. The final restoration is done by Cention. Teeth were extracted on days 3 and 7 and processed for immunohistochemical evaluation.

The differences in expression of TNF- $\alpha$  and ALP after treatment with calcium hydroxide compared with a combination of calcium hydroxide and propolis were statistically significant ( $p < 0.05$ ).

After application of the combination of Calcium hydroxide and propolis, the expression of TNF- $\alpha$  decreases and ALP expression increase, rather than only Calcium hydroxide.

Experimental article (J Int Dent Med Res 2021; 14(2): 543-548)

**Keywords:** Calcium hydroxide, propolis, ALP, TNF- $\alpha$ , odontoblast like cell.

**Received date:** 27 November 2020

**Accept date:** 29 January 2021

### Introduction

Caries is an infectious disease and is a progressive demineralization process in hard tooth tissue, such as enamel, dentin, and cementum, which is caused by interactions between bacteria on the tooth surface, and diet, especially carbohydrates. The current prevalence of caries in Indonesia is around 90.5%. The majority of Indonesian people are affected by caries and are not treated or visit a dentist until they show symptoms of a large and painful caries condition<sup>1</sup>. The doctor will clean the caries tissue by using a bur or excavator in the cavity. In the

cavity preparation procedure, pulp perforation often occurs due to the removal of carious tissue. If the pulp is open, to maintain vital pulp tissue, pulp capping direct will be carried out<sup>2</sup>.

Direct pup capping aims to form a tissue between dentin and pulp. The material commonly used for pulp capping is calcium hydroxide (Ca(OH)<sub>2</sub>). This material has antibacterial and mineralization capabilities which makes it the gold standard for pulp capping treatment materials with a pH of around 8.6 to 12. Ca (OH)<sub>2</sub> has high alkaline properties and activates an enzyme called Alkaline Phosphatase (ALP) which plays a role in dentin bridge formation and antimicrobial effects. The mechanism of ALP in the formation of dentin bridges is by releasing phosphate ions and reacting with calcium ions from the bloodstream and creating calcium phosphatase sediments in the organic matrix. Calcium phosphatase sediments are hydroxyapatite molecular units that play a role in the formation of dentin bridge<sup>3</sup>.

#### \*Corresponding author:

Nanik Zubaidah, drg., M.Kes., SpKG(K)  
Departement of Conservative Dentistry,  
Faculty of Dental Medicine,  
Universitas Airlangga, Jl. Prof. DR. Moestopo No. 47  
Surabaya - 60132, Indonesia  
E-mail: nanik-z@fkg.unair.ac.id

The pulp tissue protects itself against the lesion through several stages, namely the inflammatory response, collagen formation, and the formation of reparative dentin. Lesions on the pulp can be caused by the toxic effects of dental materials, pulp perforation due to preparation procedures and mechanical trauma during bur interventions or other dental instrumentation<sup>4</sup>.

The inflammatory process is an important mechanism needed to rebuild the structure and function of tissues as a mechanism of protection against injury. Inflammation is characterized by the flow of plasma protein fluid, and polymorphonuclear leukocytes (PMN) into tissues affected by injury<sup>2</sup>. Cells associated with inflammation of the pulp tissue are PMN leukocytes, lymphocytes, plasma cells, macrophages, and mast cells. Cells that play a role in acute inflammation produce cytokines, such as Tumor Necrosis Factor-alpha (TNF- $\alpha$ ) as a proinflammatory cytokine, and other important mediators during acute inflammation<sup>4</sup>. TNF- $\alpha$  is a proinflammatory cytokine called the master regulator among all cytokines that play a role in pulp inflammation, inducing vascular dilatation with increased permeability and enhancing inflammatory response<sup>5</sup>. TNF- $\alpha$  is also able to induce active NF- $\kappa$ B transcription factors that have an important role in regulating the inflammatory and immune responses<sup>6</sup>.

The formation of dentin in pulp perforation is characterized by increased vascularization and the initiation of an innate immune response in the affected area. This is related to the ability of pulp cells to secrete growth factors, which will start the stimulation of cell differentiation and neovascularization. There are three stages of dentinogenesis: (1) recruitment of progenitor cells, (2) signaling differentiation and (3) regulation of matrix secretion by cells<sup>7</sup>. Alkaline Phosphatase is a membrane-bound enzyme that play a role in mineralization in the process of dentin repair and is secreted by different odontoblast cells<sup>8</sup>. Odontoblast cells persist even though tooth growth has been completed. Odontoblast cells are the first cells that respond to pulp inflammation, some odontoblast cells will become necrotic and mesenchymal cells (dental pulp stem cells) will differentiate into odontoblast like cells that function as cells for the formation of tertiary reparative dentin<sup>9</sup>.

40

## Materials and methods

This study was an animal experiment using 60 upper maxillary first molar teeth (*Rattus norvegicus*) strain Wistar, male, aged 8-16 weeks, weight of 200-300 grams with fully grown molar teeth. A daily feed of 15-40 grams of pellets from BR-1 type chicken food mixed with one part of flour given for each mouse. Drinking water with the addition of libitium Hi-pro-vite 524-2 (Charoen Pokphand Indonesia) was added to the feed.

The combination of calcium hydroxide and propolis extract was made in the form of hydroxido-calico P.A. (Cobra, Brazil) and natural ingredients of propolis from *Apis Mellifera* bees in Malang (East Java, Indonesia) which were extracted using ethanol solvent by maceration method. The ingredients used were propolis extract, calcium hydroxide, cotton pellets, 10% NBF solution, 70% and 95% alcohol, ketamine HCl 50 mg/kg BB (Ketalar®, Warner Lambert, Ireland), xylazine 10 mg/kg BB (Rompun®, Bayer, Leverkusen, Germany), sterile phosphate saline buffer (PBS), Cention N batch material (Ivoclar, Vivadent), paraffin wax, and Immunostaining Kit test (Biocare, Concord). The equipment used are rats cages, bottles, 3 cc syringes (Onemed, Indonesia), micromotor (NSK, Japan), low speed hand-pieces (NSK, Japan), round taper diamond bur with 0.8 mm diameter, applicator ball, tweezers, glass plates, anesthesia boards, light microscopes (Nikon E100, Japan) and digital cameras (Canon Eos M10, Japan).

All rats were anesthetized with ketamine HCl (Ketalar®, Warner-Lambert, Irlandia) and xylazine (Rompun®, Bayer, Leverkusen, Jerman). Rats were placed in a container, the occlusal surfaces of teeth cleaned with cotton pellets. Class I preparation (Black classification) was created on the occlusal of right maxillary first molar using a low speed handpiece with a round tapered diamond bur (diameter 0.84 mm) until it reached the pulp chamber. The pulp was perforated (diameter 0.46 mm) with a low speed handpiece featuring a round diamond bur. The sample was randomly divided into three groups:

1. Group I: 20 rats which were the control group, no pulp capping material was applied, filled with Cention N (Ivoclar, VivadentR) only, 10 rats were sacrificed on days 3 and 10 rats on day 7;
2. Group II: 20 rats dental were perforated and



then closed with pulp capping of calcium hydroxide of 0.5 mm thick and temporary covered with Cention N (Ivoclar, VivadentR). Among 10 rats were sacrificed on days 3 and 10 rats on day 7;

3. Group III: 20 rats were perforated, pulp capping with a combination of calcium hydroxide and propolis, were filled with Cention N (Ivoclar, VivadentR), 10 rats were sacrificed on days 3 and 10 rats on day 7;

Histopathological preparations consisting of fixation; in 10% of buffered formalin, then decalcified with 10% of ethylenediaminetetraacetic acid (EDTA), and infiltration, purification, paraffin infiltration, embedding; embedded in paraffin and were cut with microtome, sectioning using glass objects. The samples were stained with immunohistochemical (IHC) and monoclonal antibody to determine TNF- $\alpha$  and ALP expression. Then were observed using a light microscope with a magnification of 400x. Odontoblasts that express TNF- $\alpha$  and ALP were shown brown in the cytoplasm of cells. The number of odontoblast cells expressed were counted as the number of cells per microscopic field at 400x magnification. Cell counting was performed among all control groups and treatment groups.

The results of the study were statistically analyzed using SPSS version 20. The Kolmogorov Smirnov test was used to determine data distribution. Statistical analysis was performed with a significance level of 5%.

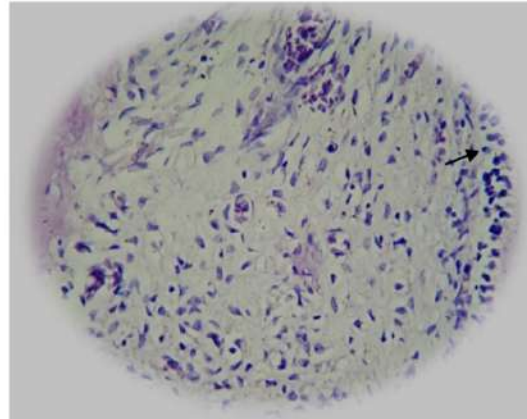
## Results

Histopathological examination with hematoxylin-eosin staining of rat's tooth odontoblast cells showed odontoblast cell morphology located in the peripheral part of the pulp chamber (Fig. 1).

The results of immuno-histochemical examination with DAB (Diamino Benzidine) staining of dental pulp odontoblast cells expressing TNF- $\alpha$  and ALP showing brown color (Fig. 2-5).

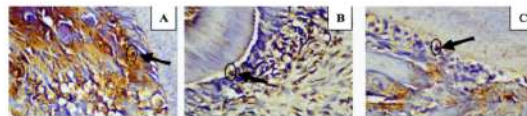
All the data on days 3 and 7 were normally distributed (K-S test,  $p > 0.05$ ). Statistical analysis of TNF- $\alpha$  between the control group and the treatment group, both on day 3 and 7 showed a significant difference ( $p < 0.05$ ),

and the statistical analysis of the Tukey test showed that there were significant differences between the control groups, the calcium hydroxide group and calcium hydroxide-propolis group. Table 1.



**Figure 1.** Histopathological image (400x magnification) of odontoblast cells in rat pulp with Hematoxylin-eosin staining.

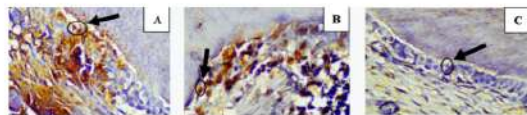
Note: Black arrows indicate the morphology of odontoblast cells with a round shape along the peripheral dentin.



**Figure 2.** Histopathological examination of dental pulp after treatment. A. Control group; B. Groups with the addition of Ca(OH)<sub>2</sub>; C. Group by the addition of Ca(OH)<sub>2</sub> plus propolis. Arrows indicate odontoblast cells expressing TNF- $\alpha$  (brown)

Note: A. Odontoblast cells expressing TNF- $\alpha$  in rat dental pulp (Control);

B. Odontoblast cells express TNF- $\alpha$  in rat dental pulp after Ca(OH)<sub>2</sub> application; C. Odontoblast cells express TNF- $\alpha$  in rat dental pulp after application of Ca(OH)<sub>2</sub> and propolis on the 3rd day.

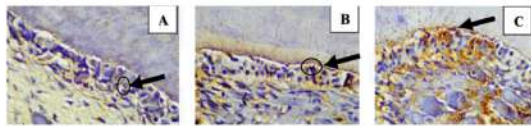


**Figure 3.** Rat tooth pulp odontoblast cells expressing TNF- $\alpha$  on day 7 (400x magnification). Black arrows indicate odontoblast cells that express TNF- $\alpha$  (brown).

Note: A. Odontoblast cells expressing TNF- $\alpha$  in the dental pulp of a rat (control);

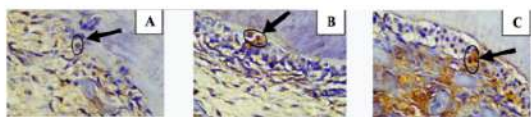
B. Odontoblast cells express TNF- $\alpha$  in the dental pulp of rat after the application of Ca(OH)<sub>2</sub>; C. Odontoblast cells express TNF- $\alpha$  in the dental pulp of rat after the application of Ca(OH)<sub>2</sub> and propolis on the 7th day.





**Figure 4.** Rat tooth pulp odontoblast cells expressing ALP on day 3 (400x magnification). Black arrows indicate odontoblast cells that express ALP (brown in color).

Note: A. Odontoblast cells that express ALP in the dental pulp of a rat (Control) on observation day 3; B. Odontoblast cells expressing ALP in the dental pulp of rat after Ca(OH)<sub>2</sub> application on observation day 3; C. Odontoblast cells expressing ALP in the dental pulp of rat after the application of Ca(OH)<sub>2</sub> and propolis on the 3rd day.



**Figure 5.** Rat tooth pulp odontoblast cells expressing ALP on day 7 (400x magnification). Black arrows indicate odontoblast cells that express ALP (brown in color).

Note: A. Odontoblast cells expressing ALP in the dental pulp of a rat (Control); B. Odontoblast cells that express ALP in the dental pulp of mice after Ca(OH)<sub>2</sub> application; C. Odontoblast cells that express ALP in the dental pulp of mice after applying Ca(OH)<sub>2</sub> and propolis on the 7th day.

Group	N	Day 3		Day 7	
		Mean	SD	Mean	SD
Control	10	9,34	1,88	13,78	2,74
Ca(OH) <sub>2</sub>	10	7,11	1,96	10	2,26
Ca(OH) <sub>2</sub> + Propolis	10	4,89	1,91	5,67	1,7

**Table 1.** TNF- $\alpha$  expression between control and treatment groups in dental pulp perforation, laboratory experimental in rats.

Group	N	Day 3		Day 7	
		Mean	SD	Mean	SD
Control	10	2,98	0,94	6,11	2,47
Ca(OH) <sub>2</sub>	10	7,22	2,04	11,78	2,52
Ca(OH) <sub>2</sub> + Propolis	10	11,34	2,98	15,22	5,26

**Table 2.** ALP expression between control and treatment groups in dental pulp perforation, laboratory experimental in rats (p-Value < 0,05).

Group	N	Day 3			Day 7		
		Control	Ca(OH) <sub>2</sub>	Ca(OH) <sub>2</sub> + Propolis	Control	Ca(OH) <sub>2</sub>	Ca(OH) <sub>2</sub> + Propolis
Control	10		0,039*	0,000*		0,003*	0,000*
Ca(OH) <sub>2</sub>	10			0,040*			0,001*
Ca(OH) <sub>2</sub> + Propolis	10						

**Table 3.** The results of the statistical analysis of the Tukey Test between the TNF- $\alpha$  group on days 3 & 7 can be seen in the following table.

Based on the Shapiro-Wilk test, on the 3rd and 7th day all samples were normally distributed (P > 0.05). Levene tests are

performed to assess homogeneity in two or more groups. Data on day 3 & 7 are homogeneous and normally distributed (K-S, p > 0.05) from both data. Table 2.

The ANOVA test between the 3 groups showed a significant difference on day 3 (p = 0,000) and day 7 (p = 0,000). Tukey test between two variables on days 3 & 7 can be seen in Table 3 and Table 4.

Group	N	Day 3						Day 7												
		Control			Ca(OH) <sub>2</sub>			Ca(OH) <sub>2</sub> + Propolis			Control			Ca(OH) <sub>2</sub>			Ca(OH) <sub>2</sub> + Propolis			
		Mean	SD	SD	Mean	SD	SD	Mean	SD	SD	Mean	SD	SD	Mean	SD	SD	Mean	SD	SD	
Control	10	2,98	0,94	1,11	2,47															
Ca(OH) <sub>2</sub>	10	7,22	2,04	1,78	2,52	0,000*	0,000*					0,000*	0,000*							
Ca(OH) <sub>2</sub> + Propolis	10	11,34	2,98	15,22	5,26							0,001*								0,108
Ca(OH) <sub>2</sub>	10																			
Ca(OH) <sub>2</sub> + Propolis	10																			

**Table 4.** The results of the statistical analysis of the Tukey test between the ALP group and day 3 & 7 can be seen in the following table. value < 0,05.

## Discussion

The main goal in conservative care in dentistry is to maintain the health and function of the pulp. Pulpal tissue has the ability to repair, heal, rearrange damaged tissue cells, and form a reparative dentin bridge<sup>4</sup>. If pulp damage or perforation occurs, pulp repair can be carried out by odontoblast cells through fibroblasts differentiation to become odontoblasts. Odontoblast cells will produce many important elements that play a role in the formation and mineralization process in restoring dental pulp<sup>10</sup>.

Disruption of pulp tissue will have an impact on inflammatory reactions to eliminate causes that harm the tissue or prevent widespread damage. Inflammatory reactions are the first step in the healing process<sup>10</sup>. Cells play a role in acute inflammation by producing cytokines, such as TNF- $\alpha$  as proinflammatory cytokines, which are important mediators during acute inflammation<sup>4</sup>. TNF- $\alpha$  is a proinflammatory cytokine called the master regulator among all cytokines that drive the pulp inflammation process. TNF- $\alpha$  can activate NF- $\kappa$ B transcription factors which have an important role in regulating the inflammatory and immune responses<sup>6</sup>.

The lowest average results of TNF- $\alpha$  expression were found in the combination group of calcium hydroxide and propolis extract, this was caused by propolis extract which was known to have antibacterial, anti-inflammatory activity with flavonoid content and Caffeic Acid Phenethyl

Ester (CAPE). Propolis extract has an important role in reducing the inflammatory response by inhibiting the arachidonic acid lipoxygenase pathway. Propolis extract can inhibit the expression of NF- $\kappa$ B into the cell nucleus by inhibiting the transcription of TNF- $\alpha$  gene. Based on previous research, propolis extract can suppress TNF- $\alpha$  production in inflammatory reactions in rats pulp tissue<sup>11</sup>.

Propolis as a carrier is needed by calcium hydroxide to be used as a paste and can affect its effectiveness, this is due to an influence on ion decomposition and diffusion. Calcium hydroxide with propolis as its carrier can diffuse through the dentinal tubules. The component of propolis solution also does not interfere with or reduce the breakdown of calcium hydroxide ions. The use of propolis as a carrier is also recommended to enhance the antibacterial action of calcium hydroxide<sup>12</sup>.

In this study, TNF- $\alpha$  expression was seen on day 3 and 7. The Tukey HSD test results showed that there were significant differences in the calcium hydroxide-propolis combination group on the 3rd and 7th days which meant that propolis extract was able to inhibit NF- $\kappa$ B expression by inhibiting NF- $\kappa$ B transcription compared with control group that was not treated with any capping material, and compared with calcium hydroxide group, *Meto et al*, research's suggest that the inflammatory response that still exists on day 7 is due to the nature of calcium hydroxide which can cause cell necrosis<sup>15</sup>. Pulpal tissue that is in contact with calcium hydroxide will experience superficial coagulation necrosis consisting of 3 layers of necrosis zones as thick as 1 - 1.5 cm. This will cause slight irritation to vital tissues<sup>16</sup>.

TNF- $\alpha$  expression increased more on day 7 compared to day 3 in both the control group and calcium hydroxide-propolis combination group, but when it compared to other groups the increase was not too significant. The inflammatory response has been completed in 8-15 days, and some cases up to 39 days, which means that on the 7th day the inflammatory process is still ongoing<sup>9</sup>. In another study on Brazilian propolis, TNF- $\alpha$  increased from day 7 and peaked at 14 days<sup>13</sup>. This shows that propolis extract plays a role in suppressing inflammation through modulation of cellular responses. Individual cellular responses are influenced by bacterial flora in rats, host

response to inflammation, and type of inflammation. Research conducted by Mori and Rodriguez (2014) showed that mixing calcium hydroxide and propolis on the 7<sup>th</sup> day still causes an inflammatory response in rats tissue, and will gradually disappear on the 14<sup>th</sup> day and 30<sup>th</sup> day<sup>14</sup>.

ALP is involved in the process of initial mineral deposition and calcification in tissues and plays an important role in the process of extracellular matrix mineralization. Another study shows that in healthy pulp there is little ALP activity, in reversible pulpitis there is ALP diffusion activity and in irreversible pulpitis the ALP activity is localized in macrophages and neutrophils. ALP activity can decrease with increased release of inflammatory mediators, such as TNF- $\alpha$  and IL-1 $\beta$  which have inhibitory effects on ALP synthesis<sup>15</sup>.

The highest expression of ALP activity is found in calcium hydroxide-propolis group, both on the 3<sup>rd</sup> and 7<sup>th</sup> day, this is because propolis extract can inhibit NF- $\kappa$ B into the cell nucleus so that by inhibiting the activation of NF- $\kappa$ B the gene transcription which secretes TNF- $\alpha$  can be inhibited. After transcription in DNA is inhibited during inflammation, TGF $\beta$ -1 is activated.

Propolis has a strong anti-inflammatory effect due to its flavanoid and CAPE. CAPE is a natural NF- $\kappa$   $\beta$  inhibitor, possesses anti-tumor and anti-inflammatory properties which affect pro-inflammatory mediators<sup>16</sup>. CAPE content via the MEK 1/2 pathway which activates Extracellular Signal Regulated Kinase (ERK2) which activates TGF- $\beta$ 1. Apart from going through the MEK 1/2 pathway, CAPE is able to directly induce TGF- $\beta$ 1 so that cell proliferation will increase. All of these reactions can induce odontoblast cells such as cell differentiation and ALP secretion will also increase so that it will affect mineralization and the quality of reparative dentin formation<sup>17</sup>.

Propolis can stimulate dental pulp regeneration because its ability to inhibit inflammatory reactions, infections, and pulp necrosis<sup>18</sup>. Propolis extract can directly induce TGF- $\beta$ 1 which is a growth factor that acts as an important regulator in the differentiation and proliferation of human pulp cells in the formation and repair of dentin. TGF- $\beta$ 1 will regulate the proliferation process, cells undergo mitosis and differentiate into odontoblast-like cells which are characterized by increased ALP activity.



Increased ALP can stimulate the process of releasing minerals from cells to start mineralization, then the process of formation of minerals<sup>19</sup>. Another study stated that calcium hydroxide and propolis extract can stimulate the formation of barriers in hard tooth tissue<sup>20</sup>.

In this study, ALP activity was examined on days 3 and 7. Tukey HSD test results showed that there were significant differences in the combination group of calcium hydroxide-propolis on the 3<sup>rd</sup> and 7<sup>th</sup> days, which means that increased ALP expression and healing had begun to occur on the 7<sup>th</sup> day, other studies showed that healing begins on day 7 with a histological picture of the presence of collagen fibers, fibroblasts, and blood vessel proliferation<sup>14</sup>.

This study found that TNF- $\alpha$  in the control group increased but odontoblast cells continued to express ALP, this is due on the 3<sup>rd</sup> and 7<sup>th</sup> day the inflammatory response was still occurring and the host was still in the process of homeostasis of inflammatory cells, it is known that pulp function is for tooth defense. The increase in ALP will only increase on days 14-28, TNF- $\alpha$  also plays a role in mineralization<sup>21</sup>. TNF- $\alpha$  will increase proliferation of dental pulp cells by inducing glycogen pathway synthase kinase, so that on the 7<sup>th</sup> day TNF- $\alpha$  is still produced, but TNF- $\alpha$  is able to induce DPSC (Dental Pulp Stem Cell) to mineralize so ALP will be produced .

## Conclusions

The expression of TNF- $\alpha$  decrease after application of calcium hydroxide and propolis, whereas ALP expression increase. The combination of calcium hydroxide and propolis can improve the repair of pulp injuries better than calcium hydroxide alone.

## Declaration of Interest

The authors declare that there were no conflicts of interest.

## References

1. Widjiastuti I, Yuanita T, Hutagalung J, Rukmo M, Safitri I. East Java Propolis Inhibits cytokine Pro-inflammatory in Odontoblast like cells Human Pulp. *Journal of Agricultural Science and Technology*. 2014;4(1):1-10.
2. Kunarti S. Pulp tissue inflammation and angiogenesis after pulp capping with transforming growth factor  $\beta$ 1. *Dent J (Majalah Kedokt Gigi)*. 2008;41(2):88.
3. Estrela C, Holland R. Calcium hydroxide: study based on scientific evidences. *J Appl Oral Sci*. 2003; 11(4): 269–82.
4. Parolia A, Kundabala M, Rao NN, et al. A comparative histological analysis of human pulp following direct pulp capping with Propolis, mineral trioxide aggregate and Dycal. *Aust Dent J*. 2010;55(1):59–64.
5. Kaya FA, Hamamci N, Basaran G, et al. inducing vascular dilatation with increased permeability and enhancing inflammatory response. *Journal of International Dental and Medical Research*. 2010;3(3):116-121.
6. Armutcu F, Akyol S, Ustunsoy S, Turan FF. Therapeutic potential of caffeic acid phenethyl ester and its anti-inflammatory and immunomodulatory effects (Review). *Exp Ther Med*. 2015;9(5):1582–8.
7. Octiara E. Dentin Reparatif dan Growth Factor yang Berperan Dalam Dentinogenesis Reparatif. *Dentika Dent J*. 2015;18(3):294–9.
8. Hasib A, Wahjuningrum DA, Kurniawan HJ, et al. ALP (Alkaline Phosphatase) Expression in Simple Fracture Incident in Rat (*Rattus Norvegicus*) Femur Bone Supplemented by Apis Mellifera Honey. *Journal of International Dental and Medical Research*. 2020; 13 (3):887-891
9. Goldberg M, Farges JC, Lacerda-Pinheiro S, Six N, Jegat N, Decup F, et al. Inflammatory and immunological aspects of dental pulp repair. *Pharmacol Res*. 2008;58(2):137–47.
10. Teti G, Salvatore V, Ruggeri A, Manzoli L, Gesi M, Orsini G, et al. In vitro reparative dentin: A biochemical and morphological study. *Eur J Histochem*. 2013;57(3):151–8.
11. Sabir A. The Effect of Propolis on Cytokines during Dental Pulp Inflammation. *J Apic*. 2016;31(1):97.
12. Montero JC, Mori GG. Assessment of ion diffusion from a calcium hydroxide-propolis paste through dentin. *Braz Oral Res*. 2012;26(4):318–22.
13. Spoto G, Fioroni M, Rubini C, Tripodi D, Di Stilio M, Piattelli A. Alkaline phosphatase activity in normal and inflamed dental pulps. *J Endod*. 2011;27(3):180–2.
14. Ansoorge S, Reinhold D, Lendeckel U. Propolis and some of its constituents down-regulate DNA synthesis and inflammatory cytokine production but induce TGF- $\beta$ 1 production of human immune cells. *Zeitschrift fur Naturforsch - Sect C J Biosci*. 2003;58(7–8):580–9.
15. de Moura SAL, Ferreira MAND, Andrade SP, Reis MLC, Noviello M de L, Cara DC. Brazilian green propolis inhibits inflammatory angiogenesis in a murine sponge model. *Evid Based Complement Alternat Med*. 2011;2011:182703..
16. Utari Kresnoadi U, Prabowo TSY. Expression of Interleukin-1 $\beta$  and TGF-B due to Induction with Natural Propolis Extract and Bovine Bone Graft Combination in Tooth Extraction Sockets Leading to Alveolar Bone Regeneration. *Journal of International Dental and Medical Research* 2020;13(3):935-938
17. Mori GG, da Silva Rodrigues S, Shibayama ST, Pomini M, do Amaral COF. Biocompatibility of a calcium hydroxide-propolis experimental paste in rats subcutaneous tissue. *Braz Dent J*. 2014;25(2):104–8.
18. Mooduto L, Fredline C, Sampoerno G, et al. Cytotoxicity of Sodium Hypochlorite, Chlorhexidine and Propolis on Human Periodontal Ligament Fibroblast Cell. *Journal of International Dental and Medical Research* 2019;12(2):476-480
19. Widjiastuti I, Suardita K, Saraswati W. The expressions of NF-kb and TGFb-1 on odontoblast-like cells of human dental pulp injected with propolis extracts. *Dent J (Majalah Kedokt Gigi)*. 2014;47(1):13.
20. Ozorio JEV, De Oliveira E Silva Carvalho LF, et al. Standardized propolis extract and calcium hydroxide as pulpotomy agents in primary pig teeth. *J Dent Child*. 2012;79(2):53–8.
21. Qin Z, Fang Z, Zhao L, Chen J, Li, et al. High dose of TNF- $\alpha$  suppressed osteogenic differentiation of human dental pulp stem cells by activating the Wnt/ $\beta$ -catenin signaling. *J Mol Histol*. 2015;46(4–5):409–20.

# The Expression of Tumor Necrosis Factor Alpha and Alkaline Phosphatase Due to Induction of Combination Calcium Hydroxides and Propolis

## ORIGINALITY REPORT

18%

SIMILARITY INDEX

12%

INTERNET SOURCES

13%

PUBLICATIONS

1%

STUDENT PAPERS

## PRIMARY SOURCES

1	<a href="http://www.thieme-connect.de">www.thieme-connect.de</a> Internet Source	1%
2	<a href="#">The Dental Pulp, 2014.</a> Publication	1%
3	<a href="http://issuu.com">issuu.com</a> Internet Source	1%
4	<a href="#">Ardo Sabir, Andi Sumidarti. "Interleukin-6 expression on inflamed rat dental pulp tissue after capped with Trigona sp. propolis from south Sulawesi, Indonesia", Saudi Journal of Biological Sciences, 2017</a> Publication	1%
5	<a href="http://japtr.org">japtr.org</a> Internet Source	1%
6	<a href="http://www.dovepress.com">www.dovepress.com</a> Internet Source	1%
7	<a href="http://www.medicopublication.com">www.medicopublication.com</a> Internet Source	1%



8	<a href="http://stemcellres.biomedcentral.com">stemcellres.biomedcentral.com</a> Internet Source	1 %
9	<a href="http://www.e-journal.unair.ac.id">www.e-journal.unair.ac.id</a> Internet Source	1 %
10	Pacios, M.G.. "Calcium hydroxide's association with different vehicles: in vitro action on some dentinal components", Oral Surgery, Oral Medicine, Oral Pathology, Oral Radiology and Endodontology, 200307 Publication	<1 %
11	<a href="http://persianjms.com">persianjms.com</a> Internet Source	<1 %
12	Maria Istiqomah Marini, Hastomo Angrosidy, Arofi Kurniawan, Mieke Sylvia Margaretha. "The anthropological analysis of the nasal morphology of Dayak Kenyah population in Indonesia as a basic data for forensic identification", Translational Research in Anatomy, 2020 Publication	<1 %
13	<a href="http://celljournal.org">celljournal.org</a> Internet Source	<1 %
14	Min, K.S.. "Effects of Proinflammatory Cytokines on the Expression of Mineralization Markers and Heme Oxygenase-1 in Human Pulp Cells", Journal of Endodontics, 200601 Publication	<1 %

15 [medcraveonline.com](http://medcraveonline.com) <1 %  
Internet Source

---

16 [Www.dovepress.com](http://www.dovepress.com) <1 %  
Internet Source

---

17 [www.molvis.org](http://www.molvis.org) <1 %  
Internet Source

---

18 [www.physiology.org](http://www.physiology.org) <1 %  
Internet Source

---

19 Güvenç Başaran, Törün Özer, Filiz Acun Kaya, Orhan Hamamci. "Interleukins 2, 6, and 8 levels in human gingival sulcus during orthodontic treatment", American Journal of Orthodontics and Dentofacial Orthopedics, 2006  
Publication

---

20 Sangwan, P., A. Sangwan, J. Duhan, and A. Rohilla. "Tertiary dentinogenesis with calcium hydroxide: A review of proposed mechanisms", International Endodontic Journal, 2013.  
Publication

---

21 [crimsonpublishers.com](http://crimsonpublishers.com) <1 %  
Internet Source

---

22 [www.sci-rep.com](http://www.sci-rep.com) <1 %  
Internet Source

---

[www.thieme-connect.com](http://www.thieme-connect.com)



23

&lt;1 %

24

"TERMIS EU 2008 Porto Meeting June 22–26, 2008 Porto Congress Center–Alfândega Portugal", Tissue Engineering Part A, 05/2008  
Publication

&lt;1 %

25

Fiona H Zhou, Bruce K Foster, Xin-Fu Zhou, Allison J Cowin, Cory J Xian. "TNF- $\alpha$  Mediates p38 MAP Kinase Activation and Negatively Regulates Bone Formation at the Injured Growth Plate in Rats", Journal of Bone and Mineral Research, 2006  
Publication

&lt;1 %

26

Graziela Garrido Mori, Sindineia da Silva Rodrigues, Sheila Tiekko Shibayama, Marcelo Pomini et al. "Biocompatibility of a Calcium Hydroxide-Propolis Experimental Paste in Rat Subcutaneous Tissue", Brazilian Dental Journal, 2014  
Publication

&lt;1 %

27

Tirang R. Neyestani. "Polyphenols and Immunity", Wild-Type Food in Health Promotion and Disease Prevention, 2008  
Publication

&lt;1 %

28

TjÅderhane, Leo, and Markus Haapasalo. "The dentin-pulp border: a dynamic interface

&lt;1 %

between hard and soft tissues : Dentin-pulp border", Endodontic Topics, 2009.

Publication

29

[etheses.whiterose.ac.uk](http://etheses.whiterose.ac.uk)

Internet Source

<1 %

30

[f1000research.com](http://f1000research.com)

Internet Source

<1 %

31

[jurnal.ugm.ac.id](http://jurnal.ugm.ac.id)

Internet Source

<1 %

32

[orca.cf.ac.uk](http://orca.cf.ac.uk)

Internet Source

<1 %

33

[www.frontiersin.org](http://www.frontiersin.org)

Internet Source

<1 %

34

[www.researchgate.net](http://www.researchgate.net)

Internet Source

<1 %

35

[zombiedoc.com](http://zombiedoc.com)

Internet Source

<1 %

36

Ummay Mahfuza Shapla, Jinat Raihan, Asiful Islam, Fahmida Alam, Naeem Solayman, Siew Hua Gan, Sakib Hossen, Ibrahim Khalil.

"Propolis: The future therapy against Helicobacter pylori -mediated gastrointestinal diseases", Journal of Applied Biomedicine, 2018

Publication

<1 %

[eprints.skums.ac.ir](http://eprints.skums.ac.ir)



37

Internet Source

&lt;1 %

38

"Poster abstracts of the 6th biennial meeting of the European Federation of Conservative Dentistry (EFCD) held in association with the 33th national congress of the College National des Enseignants en Odontologie Conservatrice (CNEOC), France, 9–11 May 2013, Paris, France", Clinical Oral Investigations, 2013

Publication

&lt;1 %

39

I G.A.W Ardani, Ira Willyanti, Ida B. Narmada. "Correlation between vertical components and skeletal class II malocclusion in ethnic Javanese", Clinical, Cosmetic and Investigational Dentistry, 2018

Publication

&lt;1 %

40

Jianxin Du, Qiang Wang, Pishan Yang, Xiaoying Wang. "FHL2 mediates tooth development and human dental pulp cell differentiation into odontoblasts, partially by interacting with Runx2", Journal of Molecular Histology, 2016

Publication

&lt;1 %

41

Retno Pudji Rahayu, Nirawati Pribadi, Ira Widjiastuti, Nur Ariska Nugrahani. "Combinations of propolis and Ca(OH)<sub>2</sub> in dental pulp capping treatment for the

&lt;1 %

# stimulation of reparative dentin formation in a rat model", F1000Research, 2020

Publication

---

42

T. Amano. "Responses of Rat Pulp Cells to Heat Stress in vitro", Journal of Dental Research, 05/01/2006

Publication

---

<1 %

---

Exclude quotes      On

Exclude matches      Off

Exclude bibliography      On



# The Expression of Tumor Necrosis Factor Alpha and Alkaline Phosphatase Due to Induction of Combination Calcium Hydroxides and Propolis

---

GRADEMARK REPORT

---

FINAL GRADE

**/100**

GENERAL COMMENTS

**Instructor**

---

PAGE 1

---

PAGE 2

---

PAGE 3

---

PAGE 4

---

PAGE 5

---

PAGE 6

---