

# Endodontic Retreatment in Underfilled Root Canal of Maxillary First Molar with Chronic Periapical Abscess: A Case Report

Nanik Zubaidah<sup>1</sup>, Kun Ismiyatin<sup>1</sup>, Cinitra Anindya<sup>2</sup>, Nindhira Puspita Sari<sup>2</sup>, Singgih Harseno<sup>2</sup>,  
Ahmad Afif Dzulfikar<sup>2</sup>, Dian Dwi Pratiwi<sup>2</sup>

<sup>1</sup>Staff, <sup>2</sup>Resident of Conservative Dentistry Department, Faculty of Dental Medicine, Universitas Airlangga

## Abstract

**Background:** The failure of endodontic treatment commonly caused by imperfect obturation, periodontal-periradicular lesions, untreated root canals, and some other factors. The failure may trigger the occurrence of secondary infections due to persistent bacteria. One of the abnormalities that appear after endodontic treatment is a periapical abscess. Endodontic failure can be overcome by endodontic retreatment, apical surgery, or extraction. During an endodontic retreatment, endodontic instruments are used to remove the root canal filling material and to repeat the steps of endodontic treatment to achieve the apical patency. **Purpose:** This case report presents management to overcome the failure of previous endodontic treatment with nonsurgical endodontic retreatment. **Case:** A 66 years old male patient came with a dull pain of tooth no 16 and uncomfortable when used for chewing since 2 months after endodontic treatment. The episodic swelling appeared since 3 months ago which then deflated. The objective examination showed a positive response to bite test and percussion test. Intraoral periapical radiograph confirmed an underfilled root canal, and a periapical radiolucency with a diffuse border on palatal root. **Case Management:** Based on the patient's history taking, radiographic, and clinical examination, endodontic retreatment was done and followed by porcelain fused to metal crown restoration. **Conclusion:** Endodontic retreatment is the appropriate treatment option to overcome the failure of the previous endodontic treatment that accompanied with a periapical lesion and to preserve its function in stomatognathic system.

**Keywords:** *endodontic retreatment, endodontic failure, chronic periapical abscess*

## Introduction

There are many causes of endodontic treatment failure including imperfect obturation, root perforation, external root resorption, periodontal-periradicular lesions, overfilling, the presence of a left root canal, periapical cysts, the lagging of broken instruments in the root canal, perforation of the nasal foramen and coronal

leakage <sup>1</sup>.

The main differences between endodontic therapy and endodontic retreatment are the necessity to remove filling materials from the root canals <sup>2</sup>. A good retreatment procedure required no visible debris observed on the instrument flutes <sup>3</sup>. Cases of retreatment always begin with a careful examination of the endodontic morphology of the involved tooth on pre-operative radiographs, because many times the failure of the first performed therapy is caused by a missed and untreated root canal <sup>4</sup>. To be able to find all the canals of a tooth root and biomechanically treat and obturate, a knowledge of root canal morphology is needed <sup>5</sup>.

---

### Corresponding Author:

**Kun Ismiyatin,**

Staff of Conservative Dentistry Department, Faculty of Dental Medicine, Universitas Airlangga. Mayjen. Prof. Dr. Moestopo Street 47, Surabaya - Indonesia. 60132.

E-mail: kun-is@fkg.unair.ac.id;

kunismiyatin.fkgua@gmail.com

Persistent microbiological infection plays an important role of endodontic failure <sup>6</sup>. One of the abnormalities that appear after endodontic treatment is a chronic periapical abscess. Chronic abscesses may not cause pain or only cause mild pain. Radiographic examination often shows a diffuse area of rarefaction of bone and thickened periodontal ligament <sup>7</sup>.

This case report presents management to overcome the failure of previous endodontic treatment with nonsurgical endodontic retreatment in underfilled root canal with a chronic periapical abscess.

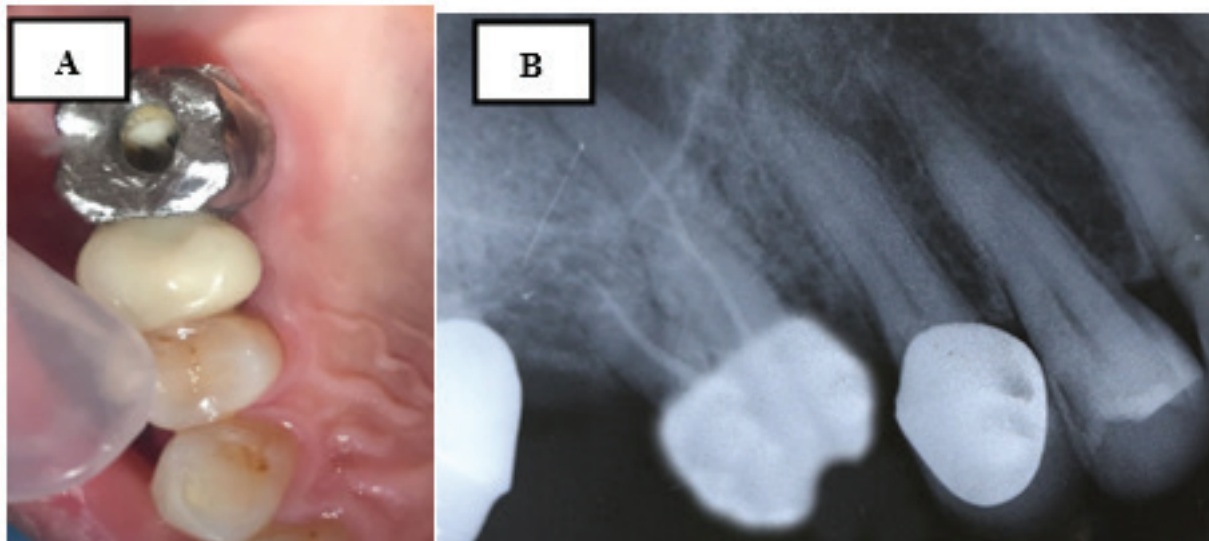
### Case Report

A 66 years old male patient came to the dental hospital of Universitas Airlangga with a dull pain of tooth no 16 and uncomfortable when used for chewing since 2 months after endodontic treatment. The episodic

swelling appeared since 3 months ago which then deflated. A week ago, the throbbing pain appeared and access opening were done by the previous General Practitioner. The patient has no medical history.

The objective examination showed there was a metal crown on tooth no 16 (Fig 1A), bite test (+), percussion test (+), vitality (-), gingivitis (+). Intraoral periapical radiographic confirmed that the patient had a deficient previous root canal treatment, with inadequate obturation, a radiopaque view on the root canal from pulp chamber to apical third, and periapical radiolucency with a diffuse border on palatal root (Fig 1B).

Treatment planning was endodontic retreatment with balance force preparation technique and single cone obturation technique. The final restoration chosen was fiber post and porcelain fused to metal crown.

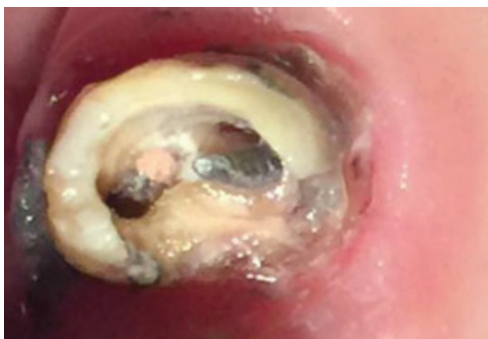

**Fig1.Pre operative image: (A) Clinical image; (B) Radiographic image**

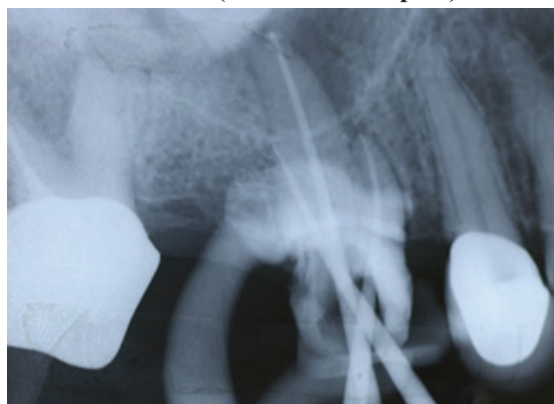Under patient's consent, endodontic retreatment started with the removal of the metal crown and the threaded post (Fig 2), then rubber dam was placed for isolation. Access opening and rewalling was performed. The removal of gutta percha using retreatment files (Dentsply Maillefer, Baillagues, Switzerland) was done,

followed by taking the radiographic image to evaluate the result of the gutta percha removal. After Glide path using K-Files #10 (Dentsply Maillefer, Baillagues, Switzerland) was established, a combination of electronic apex locator (Root ZX, J. Morita Corp, Tustin, California, USA) and periapical radiographs were used

to estimate working lengths. Biomechanical preparation was performed using Reciproc R40 (VDW, GmbH, Munich, Germany) on the palatal root canal; Reciproc R25 (VDW, Munich, Germany) on the mesiobuccal and distobuccal root canals. The motor used for reinstrumentation of the root canals was the VDW Silver Reciproc (VDW, Munich, Germany). The canals were irrigated with 2.5% NaOCl and aquadest throughout these processes. Gutta point trial radiographic image was taken (Fig 3), followed by the final irrigation with 2.5% NaOCl, 17% EDTA, and 2% Chlorhexidine Gluconate. Each time the irrigation solution was replaced, it was irrigated with sterile aquadest and activated using the EDDY system. The root canal was dried with sterile paper points. Intracanal medication (calcium hydroxide paste) was applied.



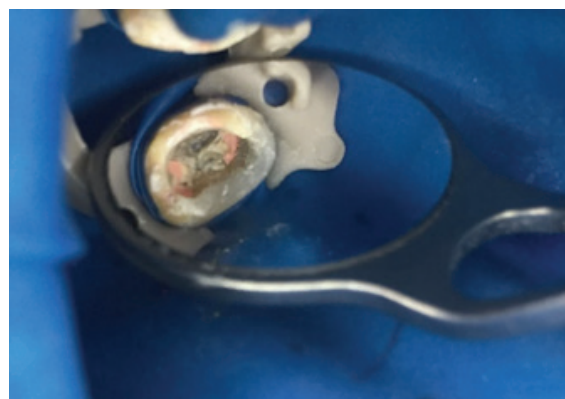
**Fig 2. Clinical image after the metal crown was removed (with threaded post)**



**Fig 3. Radiographic image**

A week after the first visit, the clinical examination showed palpation test (-), percussion test (-), swelling (-), normal periodontal tissue and temporary filling was in good condition. The tooth was isolated using rubber dam, then the canals were irrigated with 2.5% NaOCl, 17% EDTA, and 2% Chlorhexidine Gluconate. Each

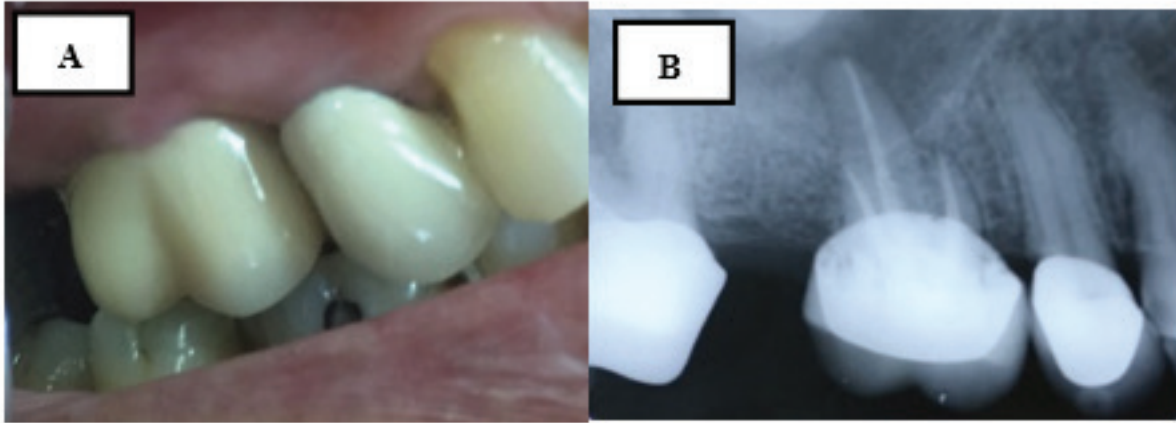
time the irrigation solution was replaced, it was irrigated with sterile aquadest and activated using the EDDY system. The root canal was dried with sterile paper points. Single cone technique was used to fill the root canals using R40 and R25 gutta-percha (VDW, Munich, Germany) and resin based sealer (Dentsply Maillefer, Ballaigues, Swiss). The radiographic image was taken to confirm the result of the obturation on the root canals (Fig 4).



**Figure 4. Obturation**

On the third visit, a week after the second visit, the clinical examination showed palpation test (-), percussion test (-), normal periodontal tissue and temporary filling was in good condition. Rubber dam was placed to isolate the tooth during the removal of the gutta percha for preparation of fiber post insertion. After the fiber post was inserted, preparation for the crown was performed, and the impression of mandibular and maxillary teeth were made. Bite registration were made, and the shade selection was performed using shade guide, (Vitapan3D master, Vita Zahnfabrik, Bad Sackingen, Germany). The shade chosen was 3M-3, then the provisional crown was inserted.

Six months after the third visit, the clinical examination showed percussion test (-), normal periodontal tissue and the provisional crown was in good condition. The provisional crown then removed and replaced with the porcelain fused to metal crown (Fig 5A) using luting cement (Fuji I Glass Ionomer Luting Cement, GC Europe). The occlusion and articulation were checked using articulating paper.



**Fig 5. A :Porcelain fused to metal crown insertion(Buccal view); B : Post operative radiographic image**

Follow up was performed six months after endodontic retreatment, the clinical examination showed no abnormality, percussion test (-), normal periodontal tissue and the porcelain fused to metal crown was in good condition. Radiographic examination showed healing of the periapical lesion (5B).

### **Discussion**

There are many factors that affect the success of endodontic treatment. All this time, endodontic failure has been associated to persistent infection of canals<sup>8</sup>. Cleaning and shaping technique, and also the measurement of the working length is the key of successful endodontic retreatment<sup>9</sup>. An inadequate obturation or overextended filling often plays a role in endodontic failure. Success rates are naturally lower for obturations which are under or overextended<sup>10</sup>.

Based on several studies, in different European countries, there is a large number of teeth needed to be retreated because of periapical lesion appeared from poor root-canal treatment. In 2004, Friedman reported healing rates of nonsurgical retreatment range between 74% and 98%<sup>11</sup>.

In this case report, the persistence of bacteria in the root canal occur because of inadequate obturation, resulting a periapical lesion, which was a periapical abscess. Chronic abscesses may not cause pain or

only cause mild pain, which sometimes, the patients is unaware to the symptoms. Therefore, non surgical endodontic treatment is needed to overcome the failure of the previous endodontic treatment.

Since the first-line treatment option for previously treated tooth is nonsurgical retreatment<sup>12</sup>, in this case report, those treatment was chosen. The function of retreated tooth can be maintained for a long time, even for a lifetime<sup>9</sup>.

The reciprocating, alternating or oscillatory movement in Reciproc file system (balanced force), is a system with a single-use file<sup>13,14</sup>. Using the reciprocal file system to remove the previous root filling materials is the most rapid method compared with other retreatment instruments<sup>9</sup>.

### **Conclusion**

Endodontic retreatment is the appropriate treatment option to overcome the failure of the previous endodontic treatment that accompanied with a periapical lesion and to preserve its function in stomatognathic system.

**Ethical Clearance:** Nil

**Source of Funding:** By self

**Conflict of Interest:** No

## References

1. Ariani NGA., Hadrianto W. Perawatan Ulang Saluran Akar Insisivus Lateralis Kiri Maksiladengan Medikamen Kalsium Hidroksi da-Chlorhexidine. *Maj Ked Gi* 2013; 20(1):52-7.
2. Friedman S., Stabholz A., Tamse A. Endodontic retreatment- Case selection and technique. Part 3. Retreatment techniques. *JOE* 1990; 16(11): 543-49.
3. Kasam S, Mariswamy AB. Efficacy of Different Methods for Removing Root Canal Filling Material in Retreatment - An In-vitro Study. *J Clin Diagn Res.* 2016;10(6):ZC06–ZC10. doi:10.7860/JCDR/2016/17395.7904.
4. Idris M., Sakkir, N., Nandakishore, KJ., & Kini, A. Endodontic retreatment of a mandibular second molar with four separate roots: A case report. *Journal of clinical and diagnostic research: JCDR* 2014;8(3):280.
5. Vertucci FJ. Root canal morphology and its relationship to endodontic procedures. *Endodontic Topics* 2005;10(1):3–29.
6. Endo MS, Ferraz CC, Zaia AA, Almeida JF, Gomes BP. Quantitative and qualitative analysis of microorganisms in root-filled teeth with persistent infection: Monitoring of the endodontic retreatment. *Eur J Dent.* 2013; 7:302–9.
7. Rakhma T., Untara RTE. Perawatansaluranakar satukunjungan pada gigi molar Pertama Kanan Mandibula Nekrosis Pulpadengan Abses Periapikal dan Fistula. *Maj Ked Gi* 2011; 18(1):117-21.
8. Ricucci D, Siqueira Jr JF. Recurrent apical periodontitis and late endodontic treatment failure related to coronal leakage: a case report. *J Endod.* 2011; 37(8): 1171-5.
9. Salicha RP, Ismiyatin K. Endodontic Retreatment Using Reciprocal File System in Underfilled Root Canal: A Case Report. *Acta Medica Philippina.* 2019; 53(5): 427-31.
10. Tabassum S, Khan FR. Failure of endodontic treatment: The usual suspects. *Eur J Dent.* 2016; 10(1):144–7.
11. Tomer AK, Miglani A, Chauhan P, Dubey S. Endodontic post and core retreatment –A case report. *International Journal of Applied Research.* 2017; 3(2): 239-41.
12. Torabinejad M, White SN. Endodontic treatment options after unsuccessful initial root canal treatment: Alternatives to single-tooth implants. *J Am Dents Assoc.* 2016; 147(3): 214-20.
13. Galiana MB, Gualdoni GM, Lugo de Langhe C, Montiel NB, Pelaez A. Revisión de desobturación de gutapercha con limas manuales, Xilol y Reciproc. *Odontostomatología.* 2018 Dec; 20(32):12–23.
14. Alsilani R, Jadu F, Bogari DF, Jan AM, Alhazzazi TY. Single file reciprocating systems : A systematic review and meta-analysis of the literature : Comparison of reciproc and WaveOne. *J Int Soc Prev Community Dent.* 2016 Sept-Oct; 6(5):402-9.