



# Source details

## International Journal of Surgery Case Reports

Scopus coverage years: from 2010 to Present

Publisher: Elsevier

ISSN: 2210-2612

Subject area: Medicine: Surgery

Source type: Journal

CiteScore 2021

0.9



SJR 2021

0.198



SNIP 2021

0.691



[View all documents >](#)

[Set document alert](#)

[Save to source list](#) [Source Homepage](#)

[CiteScore](#) [CiteScore rank & trend](#) [Scopus content coverage](#)

### i Improved CiteScore methodology



CiteScore 2021 counts the citations received in 2018-2021 to articles, reviews, conference papers, book chapters and data papers published in 2018-2021, and divides this by the number of publications published in 2018-2021. [Learn more >](#)

CiteScore 2021 ▼

$$0.9 = \frac{3,130 \text{ Citations } 2018 - 2021}{3,573 \text{ Documents } 2018 - 2021}$$

Calculated on 05 May, 2022

CiteScoreTracker 2022 ⓘ

$$0.8 = \frac{3,124 \text{ Citations to date}}{3,887 \text{ Documents to date}}$$

Last updated on 05 October, 2022 • Updated monthly

## CiteScore rank 2021 ⓘ

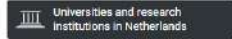
Category	Rank	Percentile
Medicine		
Surgery	#316/469	32nd

[View CiteScore methodology >](#) [CiteScore FAQ >](#) [Add CiteScore to your site](#)

# International Journal of Surgery Case Reports

## COUNTRY

Netherlands



## SUBJECT AREA AND CATEGORY

Medicine  
└ Surgery

## PUBLISHER

Elsevier BV

## H-INDEX

19

## PUBLICATION TYPE

Journals

## ISSN

22102612

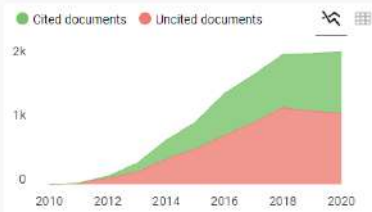
## COVERAGE

2010-2020

Support - Scopus journal

Gak takut gangguan internet dengan

telkomsel



International Journal of Surgery Case Reports

Q3

Surgery

Best quartile

SJR 2020  
0.23

powered by scimagojr.com

Show this widget in your own website

Just copy the code below and paste within your html code:


```
<a href="https://www.scimaj
```



ISSN 2210-2612

# INTERNATIONAL JOURNAL OF SURGERY CASE REPORTS

Advancing surgery through shared experience




ERUDITIO • DILIGENTIA • FIDES

EST. 2003

Actions for selected articles

Select all / Deselect all

 Download PDFs

 Export citations

Show all article previews

Contents

[Correspondence](#)

[Case Reports](#)

[Case Series](#)

[Corrigendum](#)

Case report • [Open access](#)

**Bilateral primary spontaneous pneumothorax with multiple bleb performed by VATS and wedge resection: A rare case in Indonesian adult and review article**

Nisya Hapsari, Resti Yudhawati

Article 106222

 Download PDF [Article preview](#) ▾

Case report • [Open access](#)

**A large renal bullet that resembles a large renal stone. A rare case scenario**

Diaa-Eldin Taha, Ali Abdel Raheem, Abdulhkam Aljarbou, Salem Bahdili, ... Ibrahim Alowidah

Article 106180

 Download PDF [Article preview](#) ▾

Case report • [Open access](#)

**Female primary urethral carcinoma: A rare case report**

Mochammad Ecky Pratama, Jufriady Ismy, Reno Kamarlis, Muhammad Puteh Mauny

Article 106100



[FEEDBACK](#) 

# International Journal of Surgery Case Reports

## Editor-in-Chief

Professor David Rosin, Barbados, West Indies

## Managing and Executive Editor

Dr Riaz Agha, London, UK

## Assistant Managing Editor

Maliha Agha, London, UK

## Senior Editors

Professor Hasan Alam, Michigan, USA  
Professor Raafat Afifi, Cairo, Egypt  
Dr Juan Barret, Barcelona, Spain  
Mr Ben Challacombe, London, UK  
Dr Xiaoping Chen, Wuhan, China

Dr Burcin Ekser, Indianapolis, USA  
Professor Joseph W Y Lau, Shatin, Hong Kong  
Dr Oliver Muensterer, New York, USA  
Dr Selwyn Rogers, Galveston, Texas  
Professor Jamsheer Talati, Karachi, Pakistan

Dr Mangesh Thorat, London, UK  
Professor Fu Chan Wei, Tapei, Taiwan  
Professor Rudy Leon De Wilde, Oldenburg, Germany

## Associate Editors

Professor Roberto Coppola, Rome, Italy  
Dr Veerappan Kasivisvanathan, London, UK  
Dr Richard Keijzer, Winnipeg, Canada, USA  
Dr Boris Kirshtein, Beer Sheva, Israel

Professor James McCaul, London, UK  
Miss Emma McGlone, London, UK  
Dr Dattatraya Muzumdar, Mumbai, India  
Professor Andy Petroianu, Minas Gerais, Brazil

Mr Shahzad Raja, London, UK  
Dr Kandiah Raveedran, Ipoh, Malaysia  
Dr Daniel Yeh, Boston, USA

## Assistant Editors

Dr Rafid Al-Mahfoudh, Oxford, UK  
Dr Hussein Atta, Boston, USA  
Dr Mohammad Bashashati, Texas, USA  
Professor Somprakus Basu, Varanasi, India  
Mr Andrew Beamish, Cardiff, UK  
Dr Anthony Charles, North Carolina, USA  
Dr Amitava Das, Hyderabad, India  
Dr Brian Davis, Texas, USA  
Dr Susana Adriana Esquivel, Córdoba, Mexico  
Professor Sheng Feng, Shanghai, China

Dr Juan Gomez Rivas, Madrid, Spain  
Dr Satoshi Ieiri, Kagoshima City, Japan  
Dr Haytham Kaafarani, Massachusetts, USA  
Dr Yogeesh Kamat, Karnataka, India  
Mr Omar Khan, London, UK  
Prof. Tsuyoshi Konishi, Osaka, Japan  
Dr Vito A Mannacio, Naples, Italy  
Dr Todd Manning, Oxford, UK  
Dr Zubing Mei, Shanghai, China  
Dr Umesh Metkar, Beth, Israel

Dr Indraneil Mukherjee, Staten Island, USA  
Dr Enyi Ofo, Adelaide, South Australia  
Dr Lena Perger, Albuquerque, USA  
Professor Prathamesh S Pai, Mumbai, India  
Dr Alfredas Smailys, Kaunas, Lithuania  
Prof. Peter Hyunsuk Suh, Seoul, South Korea  
Dr Dieter Weber, Perth, Australia  
Dr John Wee, Boston, USA  
Dr Honggyi Zhu, Shanghai, China

## Statistical Editors

Dr Derek Cooper, London, UK  
Professor Nora Donaldson, London, UK  
Professor Mary W Gray, Washington DC, USA

## Society Representative

Deniz Balci, Representative of the International Society of Liver Surgeons  
Rhiannon Harries, President, Association of Surgeons in Training  
Gene F. Coppa, President of the New York Surgical Society  
Xiao-ping Chen, President of the Chinese Chapter of International Hepato-Pancreato-Biliary Association

## Social Media Editor

Dr Riaz Agha, London, UK

## Assistant Commissioning Editors

Ahmed Al-Jabir, London, UK  
Zaid Alsafi, London, UK  
Thomas Franchi, Sheffield, UK  
Christos Iosifides, London, UK

Ahmed Kerwan, London, UK  
Mehdi Khan, London, UK  
Ginimol Matthew, London, UK  
Maria Nicola, London, UK

Niamh O'Neill, London, UK  
Catrin Sohrabi, London, UK

## Executive Committee

Professor David Albala, New York, USA  
Sir Graeme Catto, London, UK  
Professor David Cooper, Pittsburgh, USA  
Lord Ara Darzi, London, UK  
Professor Harold Ellis, London, UK  
Ather Enam, Karachi, Pakistan

Sir Barry Jackson, London, UK  
Professor Arthur Li Kwok-Cheung, Wanchai, Hong Kong  
Professor C H Leong, Central, Hong Kong  
Lord Ian McColl, London, UK

John Norcini, Philadelphia, USA  
Professor Susan Standing, London, UK  
Lord Robert Winston, London, UK  
Sir Magdi Yacoub, London, UK

## Editorial Board

**Raj Badwe**  
Mumbai, India  
**Michael Boscoe**  
Middlesex, UK  
**Rapheal Bueno**  
Boston, USA  
**Kris Chatamra**  
Bangkok, Thailand  
**Paul Coulthard**  
Manchester, UK  
**Anil d'Cruz**  
Mumbai, India  
**Mahesh Desai**  
Mumbai, India  
**Juan Gomez Rivas**  
Spain, Madrid

**David W. Green**  
London, UK  
**Iraj Harirchi**  
Tehran, Iran  
**Doris Henne-Bruns**  
Ulm, Germany  
**Delawir Kahn**  
Cape Town, South Africa  
**Xiaoxi Lin**  
Shanghai, China  
**Ashok Mahapatra**  
New Delhi, India  
**Todd Manning**  
Melbourne, Australia  
**Indraneel Mittra**  
Mumbai, India

**Vijay Naraynsingh**  
West Indies  
**Fabio Nicoli**  
London, UK  
**Anibal R. Núñez De Pierro**  
Buenos Aires, Argentina  
**Reuben Orda**  
Tel Aviv, Israel  
**Vladimir Semiglazov**  
St. Petersburg, Russia  
**Tejinder Singh**  
Ludhiana, India  
**Barbara L. Smith**  
Boston, USA  
**James Tatum**  
California, USA

**Thehnton Udwardia**  
Mumbai, India  
**Martin R. Weiser**  
New York, USA  
**Yixin Zhang**  
Shanghai, China  
**Jun Zhong**  
Shanghai, China  
**Zhao-Fan Xia**  
Shanghai, China

## Elsevier

### Executive Publisher

Ash Allan, Oxford, UK  
**Administrative Editor**  
Josie Hutchins, Oxford, UK  
**Marketing Manager**  
Jayne Dawkins, Philadelphia, USA

### Journal Manager

Tamsyn Hopkins, Exeter, UK  
**Senior Business Development Executive (Reprints)**  
Emma Steel, London, UK  
**Advertising Sales Manager**  
Robert Bayliss, London, UK

### Account Manager (Supplements)

Evelina Euren, Amsterdam, the Netherlands  
**Project Manager Supplements & E-business**  
Mónica Hernández-Sesma, Amsterdam, the Netherlands



## Case report

# Bilateral primary spontaneous pneumothorax with multiple bleb performed by VATS and wedge resection: A rare case in Indonesian adult and review article

Nisya Hapsari, Resti Yudhawati \*

Department of Pulmonology and Respiratory Medicine, Faculty of Medicine, Universitas Airlangga - Dr. Soetomo General Academic Hospital, Surabaya, Indonesia

## ARTICLE INFO

## Keywords:

Primary spontaneous pneumothorax  
Multiple blebs  
Wedge resection  
VATS

## ABSTRACT

**Background:** Bilateral primary spontaneous pneumothorax (PSP) is a rare case of lung disease.

**Case presentation:** A 20-year-old man with a complaint of shortness of breath is suspected of having PSP and tuberculosis. The patient underwent water seal drainage installation in both lung cavities, but showed no improvement. Multiple blebs were found after a few days. A wedge resection with VATS became an option. The patient had improved lung function after the procedure.

**Discussion:** The WSD installation showed lungs improvement. However, when trained for lung expansion, the lung condition became bad. After wedge resection with the help of VATS on multiple blebs, the lung had a significant improvement.

**Conclusion:** Wedge resection could be considered in PSP patients with multiple blebs.

## 1. Introduction

Primary spontaneous pneumothorax (PSP) is one of the most common lung diseases affecting adolescents and young adults [1]. The incidence of PSP is estimated at 18–24 cases/100,000 in men and 6–9.8 cases/100,000 in women [2]. It is reported that 90% of PSP cases occur with blebs or bullae [3] that indicates the need for bullectomy because there are ruptures easily and lungs fail to expand [3,4]. The most common PSP is unilateral while, bilateral PSP is reported in only about 1–2% [2,5]. We found a rare case of bilateral PSP patients with chest wall adhesions who underwent VATS (video-assisted thoracoscopic surgery) and wedge resection. Based on the findings, we are interested in reporting the case using the 2020 Surgical Case Report (SCARE) Guidelines [6].

## 2. Case presentation

A 20-year-old male, Javanese, with a complaint of shortness of breath. The patient experienced shortness of breath for  $\pm 2$  weeks and worsened a day before being admitted to the hospital. The complaint was accompanied by coughing 1 week before hospitalization. The

patient had no history of allergy and comorbid diseases (such as diabetes mellitus, hypertension, asthma, etc.). There was no history of lung disease in the family. Pulmonary function examination results obtained RR = 28  $\times$ /min. The examination showed a decrease in vocal fremitus and hyper resonance on percussion in both lung fields. On auscultation, there was decreased vesicular base sound in both lung fields. The results of blood gas analysis showed respiratory alkalosis with moderate hypoxemia with the administration of 3 lpm nasal O<sub>2</sub>. X-ray results showed bilateral pneumothorax, with a heavier left lung (Fig. 1). Furthermore, water seal drainage (WSD) was installed in both lungs.

On the third day of treatment, the patient showed improvement in RR = 26  $\times$ /min, Spo<sub>2</sub> = 96% with Nasal O<sub>2</sub> 3 lpm. On the 8th day of treatment, the patient's right lung had maximal expansion. The chest tube was clamped for 1  $\times$  24 h. On day 10, the GeneXpert was declared negative and the right lung collapsed. The clamp was reopened on the chest tube of the right lung, while the left lung had not shown improvement. On the 15th day, there was a change in lung conditions where the left lung was fully expanded and the right lung was still not fully expanded. The left lung clamp was performed on the 8th day on the right lung. On the 16th day, the left lung was still fully expanded but the right lung was still not fully expanded. The WSD in the left lung was

\* Corresponding author at: R. Yudhawati, Department of Pulmonology and Respiratory Medicine, Faculty of Medicine, Universitas Airlangga - Dr. Soetomo General Academic Hospital, Jl. Mayjend Prof. Dr. Moetopo 6 – 8, Airlangga, Gubeng, Surabaya, East Java 60286, Indonesia.

E-mail addresses: [nisya.hapsari@yahoo.com](mailto:nisya.hapsari@yahoo.com) (N. Hapsari), [resti.yudhawati2021@gmail.com](mailto:resti.yudhawati2021@gmail.com) (R. Yudhawati).

<https://doi.org/10.1016/j.ijscr.2021.106222>

Received 4 June 2021; Received in revised form 5 July 2021; Accepted 17 July 2021

Available online 20 July 2021

2210-2612/© 2021 The Authors. Published by Elsevier Ltd on behalf of IJS Publishing Group Ltd. This is an open access article under the CC BY-NC-ND license

(<http://creativecommons.org/licenses/by-nc-nd/4.0/>).

removed and still inflated (Fig. 2). At this time, the patient was diagnosed with a right secondary spontaneous pneumothorax.

On the 23rd day, the patient experienced severe shortness of breath. When the patient underwent a puncture test, his shortness of breath suddenly got severe with coughing up blood, cold sweat, and desaturation with a peripheral oxygen saturation of 85–86%. The paramedic team then installed contra ventile and mini WSD. After 2 chest tube insertions, shortness of breath did not decrease and increasing instead. Therefore, the patient was placed on a ventilator and chest tube. On the 24th day, a chest CT scan without contrast showed a right hydro-pneumothorax and a left pneumothorax that had a chest tube attached with a distal tip as high as VTh level 4–5 on the right side and as high as VTh 5–6 on the left side, multiple blebs in the apical segment of the superior lobe of the lung. Right and apicoposterior segments of the left superior lobe showed no bronchopleural fistula (Fig. 3).

On the 34th day, the patient underwent Wedge Resection with VATS. Multiple bullae in the left superior lobe were found with pulmonary adhesions to the chest wall. The attachment was released and continued with wedge resection with 4 staplers via uniportal VATS. Multiple blebs were found leaking in that section. A chest X-ray was conducted after wedge resection to evaluate the procedure. On the 38th day, the results of the GeneXpert tissue were negative. The WSD was removed on the 39th day (Fig. 4).

### 3. Discussion

Primary spontaneous pneumothorax is often asymptomatic. However, a larger pneumothorax can cause sudden dyspnea, chest pain, increased heart rate, anxiety, and increased hypotension and tachycardia. This condition indicates that pneumothorax has an intrapleural

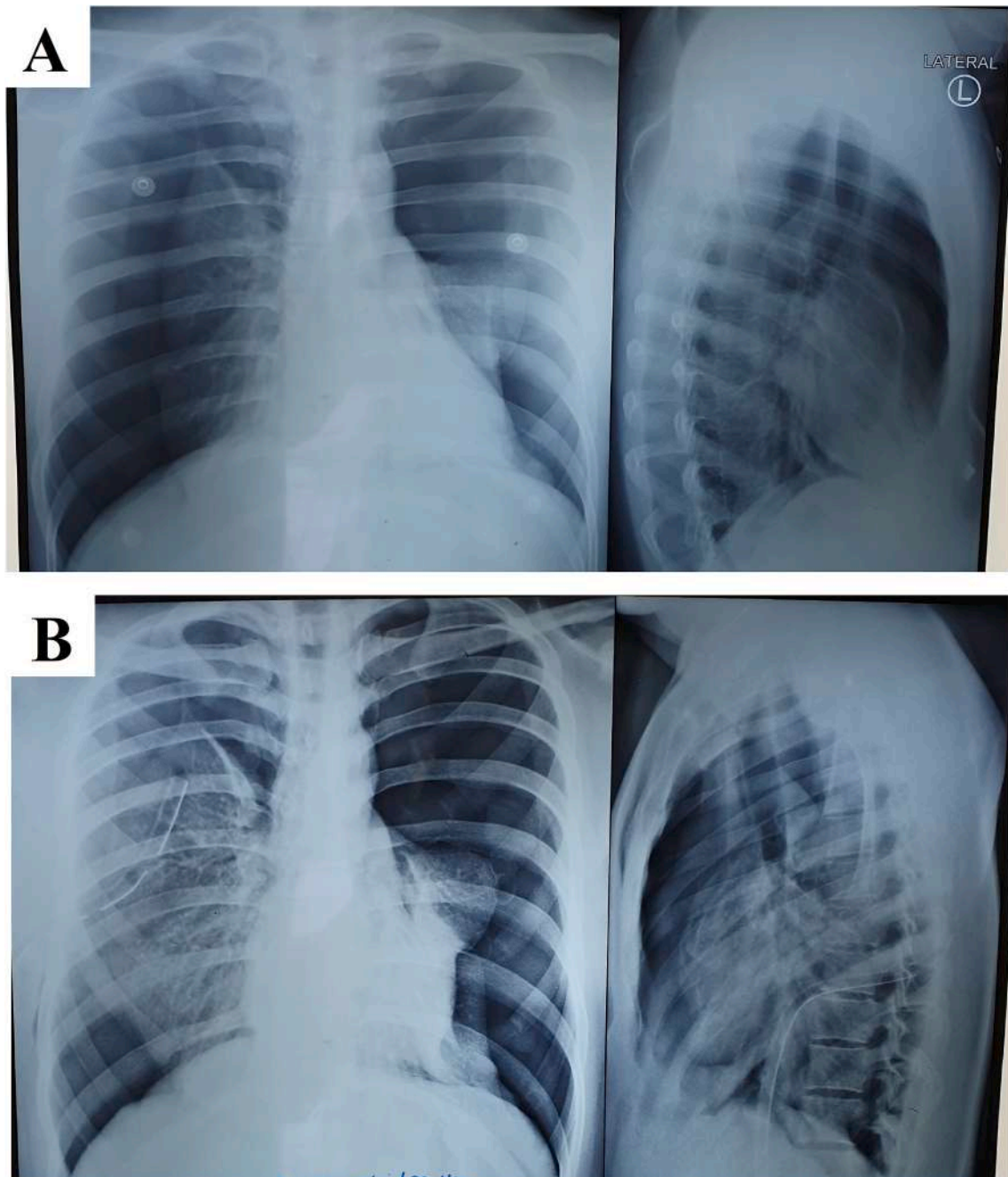


Fig. 1. A. Chest X-ray of anterior-posterior and left lateral before chest tube insertion; B. Chest X-ray of anterior-posterior and left lateral after chest tube insertion.

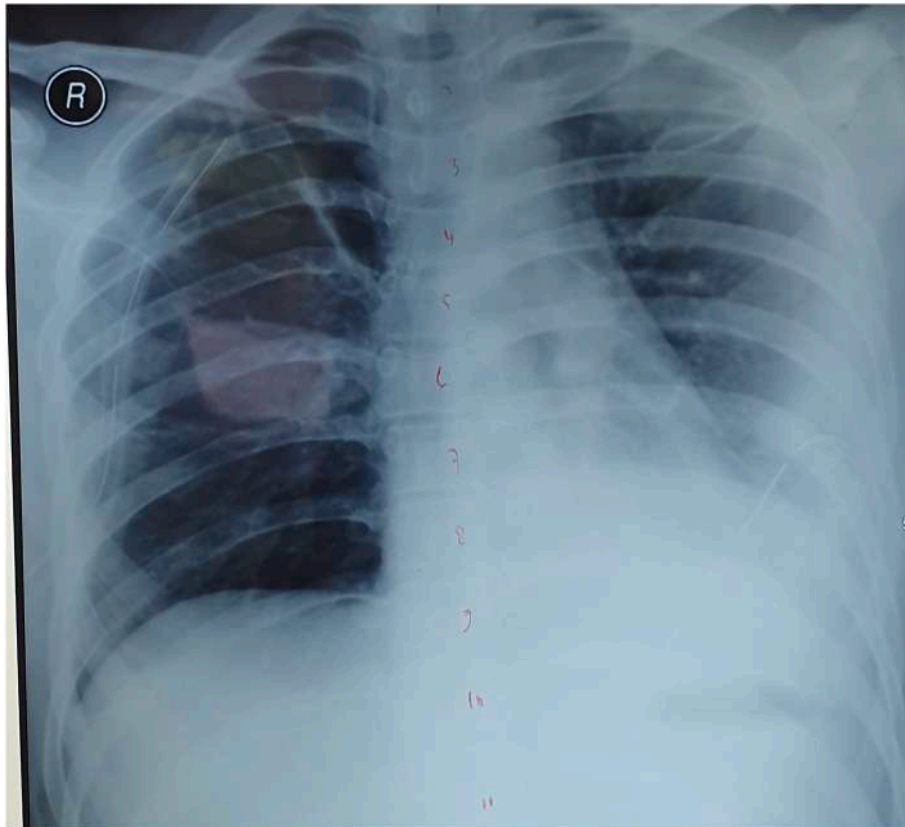


Fig. 2. Chest X-ray of anterior-posterior that shows a maximum expansion of right lung, while the left lung is still not in the maximum condition.

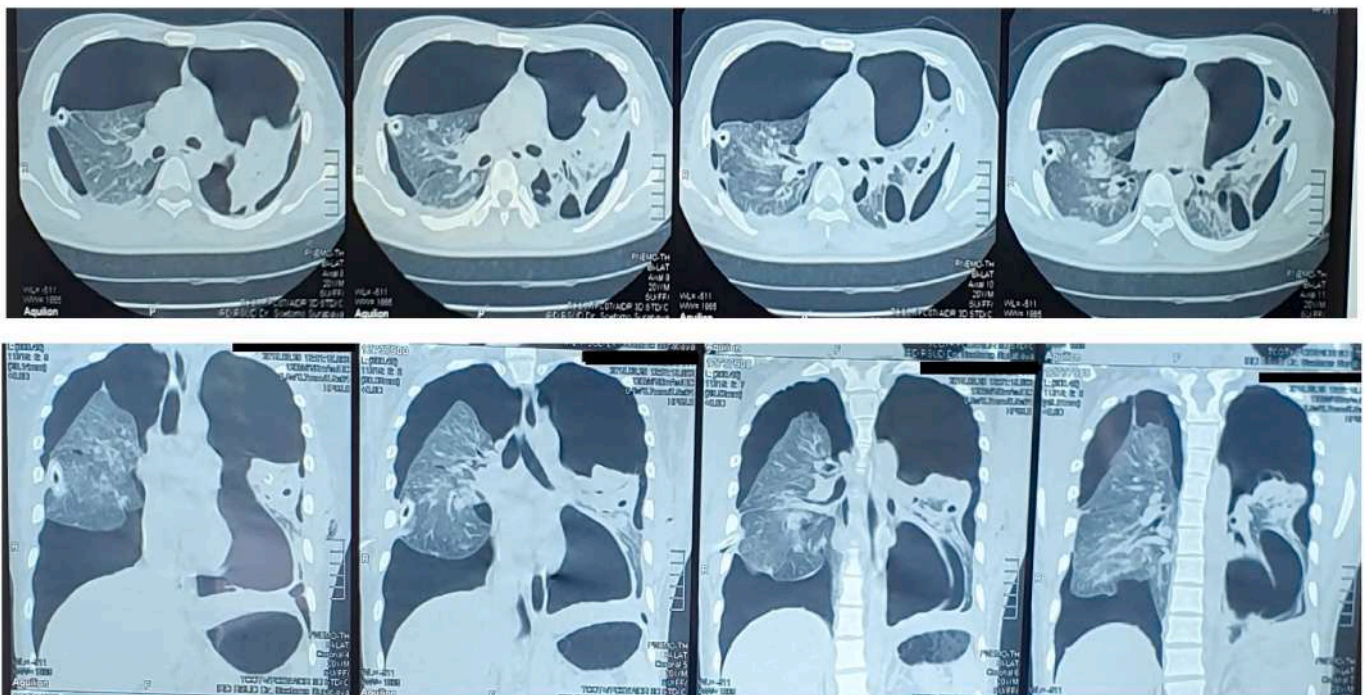


Fig. 3. CT scan showing multiple blebs in the apical segment of the right superior lobe and the apicoposterior segment of the left superior lobe.

pressure that exceeds atmospheric pressure, causing mediastinal deviation, reducing venous return, and cardiovascular collapse [7]. According to the British Thoracic Society guidelines (2003), approximately 50% of PSP patients go to the hospital >2 days after the onset of

symptoms [2].

Diagnosis of patients with PSP is conducted through an accurate medical history, detailed physical examination, and evaluation of radiological examinations. A chest X-ray taken with the patient standing



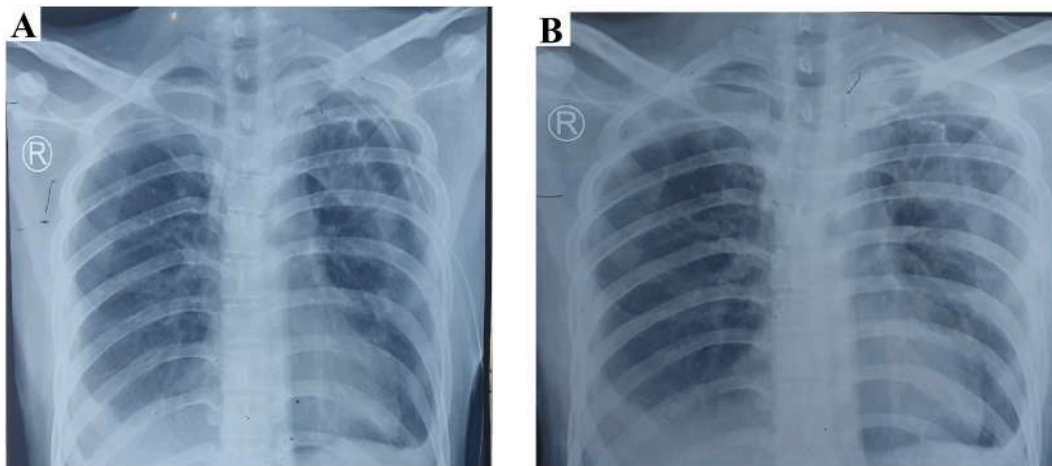


Fig. 4. Chest X-ray of anterior-posterior before (a) and after WSD removal (b).

(PA and lateral projections) has a sensitivity of about 70%. Thoracic computed tomography (CT) scan has a sensitivity of 100% and can determine the size of the pneumothorax. It can also assess changes in the lung parenchyma to determine the cause of the condition [2]. Observation can be performed as initial management in patients with a pneumothorax less than 1 cm. At the time of observation, PSP patients are administered with 100% oxygenation because it can increase the reabsorption time of pneumothorax by 4 times. The resolution of pneumothorax is about 1.3–2.2% of hemithorax volume per 24 h. The chest X-ray is repeated 4–6 h after diagnosis to ensure that pneumothorax is not enlarged. Once the pneumothorax is proven stable, the patient can be discharged and controlled through an outpatient clinic. Successful observation in patients with small PSP accounts for more than 80% of cases. Patients with small PSP have a lower potential recurrence rate when observed than with chest tube insertion [8].

Aspiration can be utilized as initial management for patients with primary pneumothorax. The procedure may be considered for younger patients (<50 years old) with a secondary pneumothorax of moderate size (1–2 cm in size). Percutaneous needle aspiration results from incomplete lung expansion in 59–83% of patients with PSP and 33–67% of patients with PSS. The recurrence rate of pneumothorax after aspiration is almost the same as after chest tube insertion. Chest tube insertion is the most common surgical procedure performed in thoracic surgery. Chest tube placement is indicated for patients with symptomatic PSP, as well as symptomatic, iatrogenic, and traumatic pneumothorax. The goal of chest tube placement is an expansion of the collapsed lung [8].

Surgery is a common method for pneumothorax with persistent air leakage (5–7 days after thoracic drainage), failure of lung expansion, repeated pneumothorax (ipsilateral or contralateral), bilateral spontaneous pneumothorax, hemothorax, patients with high-risk occupation (aircraft personnel, scuba divers). The goal of surgery for pneumothorax is to remove air from the pleural space (bleb resection) and prevent recurrence (removal of the intrapleural space). Small posterolateral thoracotomy, transaxillary mini-thoracotomy, minimally invasive endoscopic surgery (VATS) are common surgical procedures. Bullae can be removed by different surgical procedures, including lung resection, staple excision, electrocoagulation, suture ligation. To prevent recurrence of the pneumothorax, resection is combined with several procedures to remove the inter-pleural space. These procedures can include parietal pleurectomy (partial-apical or total), parietal pleural abrasion (mechanical pleurodesis), chemical pleurodesis (application of sclerosing agents). Open thoracotomy with bullectomy and pleural abrasion or pleurectomy can effectively reduce the recurrence rate by 1%. In minimally invasive surgery, not all blebs can be detected, and the recurrence rate is 5–10% higher, but the length of hospitalization is

shorter better postoperative lung air exchange, and less severe postoperative pain [8–10].

Open surgery is slightly superior or equally effective as the ‘closed’ thoracoscopy method but has higher morbidity. A thoracoscopy is recommended should there are clinical indications for invasive surgery. When performed without pleurodesis, the recurrence rate is very high up to 20%. Adequate pleurodesis is the basis for thoracoscopy, thereby preventing recurrence. All pleurodesis techniques are based on the successful induction of some form of pleural inflammatory agent. This can be achieved by mechanical abrasion, partial resection, or thoracoscopy installation of an abrasive agent (e.g. talc). There is evidence that the use of talc is safe, in both short and long-term studies and does not cause cancer, pulmonary fibrosis, impaired lung function, or impairment in subsequent thoracic surgery, and is the cheapest agent. Recurrence prevention techniques on thoracoscopy, be it ‘medical’ or ‘surgical’, usually show a recurrence rate of between 0 and 10% [2,11,12].

#### 4. Conclusion

A 20-year-old man with a complaint of shortness of breath is suspected of having PSP and tuberculosis. Water seal drainage is installed in both lung cavities. When treated for a few days, the lung condition has an ups and downs prognosis. GeneXpert results do not support the diagnosis of tuberculosis. Bleb is found in both lung cavities, thereby wedge resection is performed with VATS. After treatment, the lung condition improved and the WSD is removed.

#### Consent

We have requested the patient's consent to publish this case report for educational purposes.

#### Funding

None.

#### Ethical approval

We have conducted an ethical approval base on the Declaration of Helsinki at Ethical Committee in Dr. Soetomo General Academic Hospital, Surabaya, Indonesia.

#### Guarantor

Resti Yudawati.

**Research registration**

Not applicable.

**Provenance and peer review**

Not commissioned, externally peer-reviewed.

**CRediT authorship contribution statement**

Nisya Hapsari: collecting data, analysis, drafts, revisions, and supervision; Resti Yudhawati: methodology, analysis, revision, and review.

**Declaration of competing interest**

The authors declare that they have no conflict of interest.

**Acknowledgment**

We would like to thank Fis Citra Ariyanto for helping us in the editing and proofreading process.

**References**

- [1] P. Mendogni, J. Vannucci, M. Ghisalberty, M. Anile, B. Aramini, M.T. Congedo, et al., Epidemiology and management of primary spontaneous pneumothorax: a systematic review, *Interact. Cardiovasc. Thorac. Surg.* 30 (3) (2020) 337–345, <https://doi.org/10.1093/icvts/ivz290>.
- [2] A. Dzeljilji, W. Rokicki, M. Rokicki, K. Karus, New aspects in the diagnosis and treatment of primary spontaneous pneumothorax, *Kardiochir Torakochirurgia Pol.* 14 (1) (2017) 27–31, <https://doi.org/10.5114/kitp.2017.66926>.
- [3] Rob Hallifax J, Magda Laskawiec-Szkonter, Najib Rahman M, Predicting outcomes in primary spontaneous pneumothorax using air leak measurements, *Thorax* 74 (4) (2019) 410–412, <https://doi.org/10.1136/thoraxjnl-2018-212116>.
- [4] S.P. Luh, Review: diagnosis and treatment of primary spontaneous pneumothorax, *J Zhejiang Univ Sci B* 11 (10) (2010) 735–744, <https://doi.org/10.1631/jzus.B1000131>.
- [5] J. Kewcharoen, P. Morris, C. Kanitsoraphan, H. La, N. Sriratanaviriyakul, Simultaneous bilateral primary spontaneous pneumothorax: a case report and a review of the literature, *Case Rep. Pulmonol.* 2019 (2019) 6583842, <https://doi.org/10.1155/2019/6583842>.
- [6] R.A. Agha, T. Franchi, C. Sohrabi, G. Mathew, A. Kerwan, A. Thoma, et al., The SCARE 2020 guideline: updating consensus surgical CAse REport (SCARE) guidelines, *Int. J. Surg.* 84 (2020) 226–230, <https://doi.org/10.1016/j.ijsu.2020.10.034>.
- [7] X. Wang, L. Wang, H. Wang, H. Zhang, Simultaneous bilateral video-assisted thoracoscopic surgery for the treatment of primary spontaneous pneumothorax, *Cell Biochem. Biophys.* 71 (3) (2015) 1703–1708, <https://doi.org/10.1007/s12013-014-0393-7>.
- [8] P. Zarogoulidis, I. Kioumis, G. Pitsiou, K. Porpodis, S. Lampaki, A. Papaiwannou, et al., Pneumothorax: from definition to diagnosis and treatment, *J. Thorac. Dis.* 6 (Suppl 4) (2014), S372-S6, <https://doi.org/10.3978/j.issn.2072-1439.2014.09.24>.
- [9] S. Kepka, J.C. Dalphin, A.L. Parmentier, J.B. Pretalli, M. Gantelet, N. Bernard, et al., Primary spontaneous pneumothorax admitted in emergency unit: does first episode differ from recurrence? A cross-sectional study, *Can. Respir. J.* 2017 (2017), 2729548, <https://doi.org/10.1155/2017/2729548>.
- [10] J. Plojoux, M. Froudarakis, J.P. Janssens, P.M. Soccal, J.M. Tschopp, New insights and improved strategies for the management of primary spontaneous pneumothorax, *Clin. Respir. J.* 13 (4) (2019) 195–201, <https://doi.org/10.1111/crj.12990>.
- [11] M. Noppen, T. De Keukeleire, Pneumothorax, *Respiration* 76 (2) (2008) 121–127, <https://doi.org/10.1159/000135932>.
- [12] G. Cardillo, O.J. Bintcliffe, F. Carleo, L. Carbone, M. Di Martino, B.C. Kahan, et al., Primary spontaneous pneumothorax: a cohort study of VATS with talc poudrage, *Thorax* 71 (9) (2016) 847–853, <https://doi.org/10.1136/thoraxjnl-2015-207976>.



UNIVERSITAS AIRLANGGA  
 FAKULTAS KEDOKTERAN  
 DEPARTEMEN PULMONOLOGI & ILMU KEDOKTERAN RESPIRASI

Jl. Mayjen Prof.Dr.Moestopo No. 6 – 8 Surabaya  
 Telp. 031.5501656 ; e-mail : pulmoua@gmail.com

**SURAT KETERANGAN**

No : 494/301.10/TU/XI/2020

Yang bertanda tangan di bawah ini :

Nama : Isnin Anang Marhana, dr., SpP(K), FCCP, FISR  
 NIP : 19781107 200604 1 023  
 Pangkat / Golongan : Pembina / IV a  
 Jabatan : Ketua Departemen / KSM Pulmonologi & Ilmu Kedokteran  
 Respirasi FK. UNAIR - RSUD Dr.Soetomo Surabaya

**MENGIZINKAN**


Kepada: Peneliti Utama : Dr. Resti Yudhawati Meliana, dr.,Sp,P(K)  
 Peneliti Lain : Nisya Hapsari  
 Judul Karya Ilmiah : Seorang laki2 20 tahun dengan Pneumotoraks Spontan Primer  
 Bilateral yang dilakukan VATS dan Wedge Resection

Untuk melakukan pengambilan data pasien yang dirawat di RSUD Dr. Soetomo dengan dokter penanggung jawab pasien (DPJP) Dr. Resti Yudhawati Meliana, dr.,Sp,P(K) dan telah mendapat persetujuan dan ijin menggunakan informasi rekam medis dengan ketentuan menjaga etika penelitian. Data tersebut dapat dipublikasikan dalam bentuk laporan kasus sebagai pengembangan keilmuan.

Demikian surat keterangan ini dapat dipergunakan sebagaimana mestinya.

Dikeluarkan di : Surabaya  
 Pada Tanggal : 15 November 2020

Ketua Departemen,



Isnin Anang Marhana, dr., Sp.P(K), FCCP, FISR  
 NIP. 19781107 200604 1 023

Lampiran :

1. Surat Permohonan Pengambilan Data

Hal : Persetujuan Pengambilan Data

Kepada Yth :  
Ketua Departemen  
Pulmonologi dan Ilmu Kedokteran Respirasi  
RSUD Dr. Soetomo  
di Surabaya

Dengan hormat,

Dalam rangka penyelesaian tugas ilmiah PPDS-1 Pulmonologi dan Ilmu Kedokteran Respirasi, peserta didik kami bernama:

Nama : Nisya Hapsari  
NIM : 011818096302  
Judul Karya Ilmiah : Seorang laki2 20 tahun dengan Pneumotoraks Spontan Primer Bilateral yang dilakukan VATS dan Wedge Resection  
Pembimbing : Dr. Resti Yudhawati Meliana, dr.,Sp.P(K)

Bersama ini kami memohon persetujuan dan perijinan untuk mengambil data rekam medis pasien RSUD Dr. Soetomo di Ruang Palem I dengan dokter penanggung jawab pasien (DPJP) Dr. Resti Yudhawati Meliana, dr.,Sp.P(K). Data tersebut akan kami publikasikan dalam bentuk laporan kasus, maka kami telah berkomitmen untuk menjaga dan menjamin kerahasiaan data pribadi pasien. Atas perhatian dan kerjasamanya kami sampaikan terima kasih.

Surabaya, 15 November 2020  
Pemohon,

Dosen Pembimbing



Dr. Resti Yudhawati Meliana, dr.,Sp.P(K)  
NIP. 19761206 200912 2 002