



Source details

International Journal of Surgery Case Reports

Scopus coverage years: from 2010 to Present

Publisher: Elsevier

ISSN: 2210-2612

Subject area: Medicine: Surgery

Source type: Journal

CiteScore 2021

0.9



SJR 2021

0.198



SNIP 2021

0.691



[View all documents >](#)

[Set document alert](#)

[Save to source list](#) [Source Homepage](#)

[CiteScore](#) [CiteScore rank & trend](#) [Scopus content coverage](#)

i Improved CiteScore methodology



CiteScore 2021 counts the citations received in 2018-2021 to articles, reviews, conference papers, book chapters and data papers published in 2018-2021, and divides this by the number of publications published in 2018-2021. [Learn more >](#)

CiteScore 2021

$$0.9 = \frac{3,130 \text{ Citations } 2018 - 2021}{3,573 \text{ Documents } 2018 - 2021}$$

Calculated on 05 May, 2022

CiteScoreTracker 2022

$$0.8 = \frac{3,124 \text{ Citations to date}}{3,887 \text{ Documents to date}}$$

Last updated on 05 October, 2022 • Updated monthly

CiteScore rank 2021

Category	Rank	Percentile
Medicine		
Surgery	#316/469	32nd

[View CiteScore methodology >](#) [CiteScore FAQ >](#) [Add CiteScore to your site](#)

International Journal of Surgery Case Reports

COUNTRY

Netherlands



SUBJECT AREA AND CATEGORY

Medicine
Surgery

PUBLISHER

Elsevier BV

H-INDEX

19

PUBLICATION TYPE

Journals

ISSN

22102612

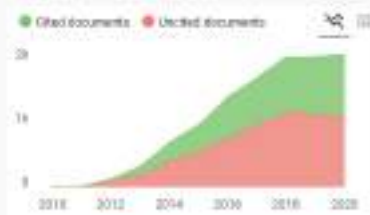COVERAGE

2010-2020

Support - Scopus journal

Gak takut gangguan internet dengan

Scopus



International Journal of
Surgery Case Reports

Q3

Surgery

Q1 2020

0.23

powered by scopus.com

Show this widget in
your own website

Just copy the code below
and paste within your HTML
CODE


14 Fresh-Tips.com



ISSN 2210-2612

INTERNATIONAL JOURNAL OF SURGERY CASE REPORTS

Advancing surgery through shared experience



ERUDITIO • DILIGENTIA • FIDES

EST. 2003

Actions for selected articles:

Select all / Unselect all

Download PDFs

Export citations

Show all article previews

Contents

Correspondence

Case Reports

Case Series

Corrigendum

Copyright © Open Access

Bilateral primary spontaneous pneumothorax with multiple lobe performed by VATS and wedge resection: A rare case in Indonesian adult and review article

Rizka Nugent, Rizki Nurhidayah

Article 106222

Download PDF Article preview

Copyright © Open Access

A large renal bullet that resembles a large renal stone. A rare case scenario

Dina Elidin Taha, Al-Abdel Mahseni, AbdulNiam Aljarsou, Salem Bahdih, ... Ibrahim Alkaidah

Article 106180

Download PDF Article preview

Copyright © Open Access

Female primary urethral carcinoma: A rare case report

Muhammad Eddy Pratama, Julialdy Irsy, Reno Keanan, Muhammad Fakhri Masry

Article 106100



Feedback



International Journal of Surgery Case Reports

Editor-in-Chief

Professor David Rosin, Barbados, West Indies

Managing and Executive Editor

Dr Riaz Agha, London, UK

Assistant Managing Editor

Maliha Agha, London, UK

Senior Editors

Professor Hasan Alam, Michigan, USA
Professor Raafat Afifi, Cairo, Egypt
Dr Juan Barret, Barcelona, Spain
Mr Ben Challacombe, London, UK
Dr Xiaoping Chen, Wuhan, China

Dr Burcin Ekser, Indianapolis, USA
Professor Joseph W Y Lau, Shatin, Hong Kong
Dr Oliver Muensterer, New York, USA
Dr Selwyn Rogers, Galveston, Texas
Professor Jamsheer Talati, Karachi, Pakistan

Dr Mangesh Thorat, London, UK
Professor Fu Chan Wei, Taipei, Taiwan
Professor Rudy Leon De Wilde, Oldenburg, Germany

Associate Editors

Professor Roberto Coppola, Rome, Italy
Dr Veerappan Kasivisvanathan, London, UK
Dr Richard Keijzer, Winnipeg, Canada, USA
Dr Boris Kirshtein, Beer Sheva, Israel

Professor James McCaul, London, UK
Miss Emma McGlone, London, UK
Dr Dattatraya Muzumdar, Mumbai, India
Professor Andy Petroianu, Minas Gerais, Brazil

Mr Shahzad Raja, London, UK
Dr Kandiah Raveedran, Ipoh, Malaysia
Dr Daniel Yeh, Boston, USA

Assistant Editors

Dr Rafid Al-Mahfoudh, Oxford, UK
Dr Hussein Atta, Boston, USA
Dr Mohammad Bashashati, Texas, USA
Professor Somprakus Basu, Varanasi, India
Mr Andrew Beamish, Cardiff, UK
Dr Anthony Charles, North Carolina, USA
Dr Amitava Das, Hyderabad, India
Dr Brian Davis, Texas, USA
Dr Susana Adriana Esquivel, Córdoba, Mexico
Professor Sheng Feng, Shanghai, China

Dr Juan Gomez Rivas, Madrid, Spain
Dr Satoshi Ieiri, Kagoshima City, Japan
Dr Haytham Kaafarani, Massachusetts, USA
Dr Yogeesh Kamat, Karnataka, India
Mr Omar Khan, London, UK
Prof. Tsuyoshi Konishi, Osaka, Japan
Dr Vito A Mannacio, Naples, Italy
Dr Todd Manning, Oxford, UK
Dr Zubing Mei, Shanghai, China
Dr Umesh Metkar, Beth, Israel

Dr Indraneil Mukherjee, Staten Island, USA
Dr Enyi Ofo, Adelaide, South Australia
Dr Lena Perger, Albuquerque, USA
Professor Prathamesh S Pai, Mumbai, India
Dr Alfredas Smailys, Kaunas, Lithuania
Prof. Peter Hyunsuk Suh, Seoul, South Korea
Dr Dieter Weber, Perth, Australia
Dr John Wee, Boston, USA
Dr Honggyi Zhu, Shanghai, China

Statistical Editors

Dr Derek Cooper, London, UK
Professor Nora Donaldson, London, UK
Professor Mary W Gray, Washington DC, USA

Society Representative

Deniz Balci, Representative of the International Society of Liver Surgeons
Rhiannon Harries, President, Association of Surgeons in Training
Gene F. Coppa, President of the New York Surgical Society
Xiao-ping Chen, President of the Chinese Chapter of International Hepato-Pancreato-Biliary Association

Social Media Editor

Dr Riaz Agha, London, UK

Assistant Commissioning Editors

Ahmed Al-Jabir, London, UK
Zaid Alsafi, London, UK
Thomas Franchi, Sheffield, UK
Christos Iosifides, London, UK

Ahmed Kerwan, London, UK
Mehdi Khan, London, UK
Ginimol Matthew, London, UK
Maria Nicola, London, UK

Niamh O'Neill, London, UK
Catrin Sohrabi, London, UK

Executive Committee

Professor David Albala, New York, USA
Sir Graeme Catto, London, UK
Professor David Cooper, Pittsburgh, USA
Lord Ara Darzi, London, UK
Professor Harold Ellis, London, UK
Ather Enam, Karachi, Pakistan

Sir Barry Jackson, London, UK
Professor Arthur Li Kwok-Cheung, Wanchai, Hong Kong
Professor C H Leong, Central, Hong Kong
Lord Ian McColl, London, UK

John Norcini, Philadelphia, USA
Professor Susan Standing, London, UK
Lord Robert Winston, London, UK
Sir Magdi Yacoub, London, UK

Editorial Board

Raj Badwe
Mumbai, India
Michael Boscoe
Middlesex, UK
Rapheal Bueno
Boston, USA
Kris Chatamra
Bangkok, Thailand
Paul Coulthard
Manchester, UK
Anil d'Cruz
Mumbai, India
Mahesh Desai
Mumbai, India
Juan Gomez Rivas
Spain, Madrid

David W. Green
London, UK
Iraj Harirchi
Tehran, Iran
Doris Henne-Bruns
Ulm, Germany
Delawir Kahn
Cape Town, South Africa
Xiaoxi Lin
Shanghai, China
Ashok Mahapatra
New Delhi, India
Todd Manning
Melbourne, Australia
Indraneel Mittra
Mumbai, India

Vijay Naraynsingh
West Indies
Fabio Nicoli
London, UK
Anibal R. Núñez De Pierro
Buenos Aires, Argentina
Reuben Orda
Tel Aviv, Israel
Vladimir Semiglazov
St. Petersburg, Russia
Tejinder Singh
Ludhiana, India
Barbara L. Smith
Boston, USA
James Tatum
California, USA

Thehnton Udwardia
Mumbai, India
Martin R. Weiser
New York, USA
Yixin Zhang
Shanghai, China
Jun Zhong
Shanghai, China
Zhao-Fan Xia
Shanghai, China

Elsevier

Executive Publisher

Ash Allan, Oxford, UK
Administrative Editor
Josie Hutchins, Oxford, UK
Marketing Manager
Jayne Dawkins, Philadelphia, USA

Journal Manager

Tamsyn Hopkins, Exeter, UK
Senior Business Development Executive (Reprints)
Emma Steel, London, UK
Advertising Sales Manager
Robert Bayliss, London, UK

Account Manager (Supplements)

Evelina Euren, Amsterdam, the Netherlands
Project Manager Supplements & E-business
Mónica Hernández-Sesma, Amsterdam, the Netherlands



Case report

Bilateral primary spontaneous pneumothorax with multiple bleb performed by VATS and wedge resection: A rare case in Indonesian adult and review article

Nisya Hapsari, Resti Yudhawati *

Department of Pulmonology and Respiratory Medicine, Faculty of Medicine, Universitas Airlangga - Dr. Soetomo General Academic Hospital, Surabaya, Indonesia

ARTICLE INFO

Keywords:

Primary spontaneous pneumothorax
Multiple blebs
Wedge resection
VATS

ABSTRACT

Background: Bilateral primary spontaneous pneumothorax (PSP) is a rare case of lung disease.

Case presentation: A 20-year-old man with a complaint of shortness of breath is suspected of having PSP and tuberculosis. The patient underwent water seal drainage installation in both lung cavities, but showed no improvement. Multiple blebs were found after a few days. A wedge resection with VATS became an option. The patient had improved lung function after the procedure.

Discussion: The WSD installation showed lungs improvement. However, when trained for lung expansion, the lung condition became bad. After wedge resection with the help of VATS on multiple blebs, the lung had a significant improvement.

Conclusion: Wedge resection could be considered in PSP patients with multiple blebs.

1. Introduction

Primary spontaneous pneumothorax (PSP) is one of the most common lung diseases affecting adolescents and young adults [1]. The incidence of PSP is estimated at 18–24 cases/100,000 in men and 6–9.8 cases/100,000 in women [2]. It is reported that 90% of PSP cases occur with blebs or bullae [3] that indicates the need for bullectomy because there are ruptures easily and lungs fail to expand [3,4]. The most common PSP is unilateral while, bilateral PSP is reported in only about 1–2% [2,5]. We found a rare case of bilateral PSP patients with chest wall adhesions who underwent VATS (video-assisted thoracoscopic surgery) and wedge resection. Based on the findings, we are interested in reporting the case using the 2020 Surgical Case Report (SCARE) Guidelines [6].

2. Case presentation

A 20-year-old male, Javanese, with a complaint of shortness of breath. The patient experienced shortness of breath for ± 2 weeks and worsened a day before being admitted to the hospital. The complaint was accompanied by coughing 1 week before hospitalization. The

patient had no history of allergy and comorbid diseases (such as diabetes mellitus, hypertension, asthma, etc.). There was no history of lung disease in the family. Pulmonary function examination results obtained RR = 28 \times /min. The examination showed a decrease in vocal fremitus and hyper resonance on percussion in both lung fields. On auscultation, there was decreased vesicular base sound in both lung fields. The results of blood gas analysis showed respiratory alkalosis with moderate hypoxemia with the administration of 3 lpm nasal O₂. X-ray results showed bilateral pneumothorax, with a heavier left lung (Fig. 1). Furthermore, water seal drainage (WSD) was installed in both lungs.

On the third day of treatment, the patient showed improvement in RR = 26 \times /min, Spo₂ = 96% with Nasal O₂ 3 lpm. On the 8th day of treatment, the patient's right lung had maximal expansion. The chest tube was clamped for 1 \times 24 h. On day 10, the GeneXpert was declared negative and the right lung collapsed. The clamp was reopened on the chest tube of the right lung, while the left lung had not shown improvement. On the 15th day, there was a change in lung conditions where the left lung was fully expanded and the right lung was still not fully expanded. The left lung clamp was performed on the 8th day on the right lung. On the 16th day, the left lung was still fully expanded but the right lung was still not fully expanded. The WSD in the left lung was

* Corresponding author at: R. Yudhawati, Department of Pulmonology and Respiratory Medicine, Faculty of Medicine, Universitas Airlangga - Dr. Soetomo General Academic Hospital, Jl. Mayjend Prof. Dr. Moetopo 6 – 8, Airlangga, Gubeng, Surabaya, East Java 60286, Indonesia.

E-mail addresses: nisya.hapsari@yahoo.com (N. Hapsari), resti.yudhawati2021@gmail.com (R. Yudhawati).

<https://doi.org/10.1016/j.ijscr.2021.106222>

Received 4 June 2021; Received in revised form 5 July 2021; Accepted 17 July 2021

Available online 20 July 2021

2210-2612/© 2021 The Authors. Published by Elsevier Ltd on behalf of IJS Publishing Group Ltd. This is an open access article under the CC BY-NC-ND license

(<http://creativecommons.org/licenses/by-nc-nd/4.0/>).

removed and still inflated (Fig. 2). At this time, the patient was diagnosed with a right secondary spontaneous pneumothorax.

On the 23rd day, the patient experienced severe shortness of breath. When the patient underwent a puncture test, his shortness of breath suddenly got severe with coughing up blood, cold sweat, and desaturation with a peripheral oxygen saturation of 85–86%. The paramedic team then installed contra ventile and mini WSD. After 2 chest tube insertions, shortness of breath did not decrease and increasing instead. Therefore, the patient was placed on a ventilator and chest tube. On the 24th day, a chest CT scan without contrast showed a right hydropneumothorax and a left pneumothorax that had a chest tube attached with a distal tip as high as VTh level 4–5 on the right side and as high as VTh 5–6 on the left side, multiple blebs in the apical segment of the superior lobe of the lung. Right and apicoposterior segments of the left superior lobe showed no bronchopleural fistula (Fig. 3).

On the 34th day, the patient underwent Wedge Resection with VATS. Multiple bullae in the left superior lobe were found with pulmonary adhesions to the chest wall. The attachment was released and continued with wedge resection with 4 staplers via uniportal VATS. Multiple blebs were found leaking in that section. A chest X-ray was conducted after wedge resection to evaluate the procedure. On the 38th day, the results of the GeneXpert tissue were negative. The WSD was removed on the 39th day (Fig. 4).

3. Discussion

Primary spontaneous pneumothorax is often asymptomatic. However, a larger pneumothorax can cause sudden dyspnea, chest pain, increased heart rate, anxiety, and increased hypotension and tachycardia. This condition indicates that pneumothorax has an intrapleural

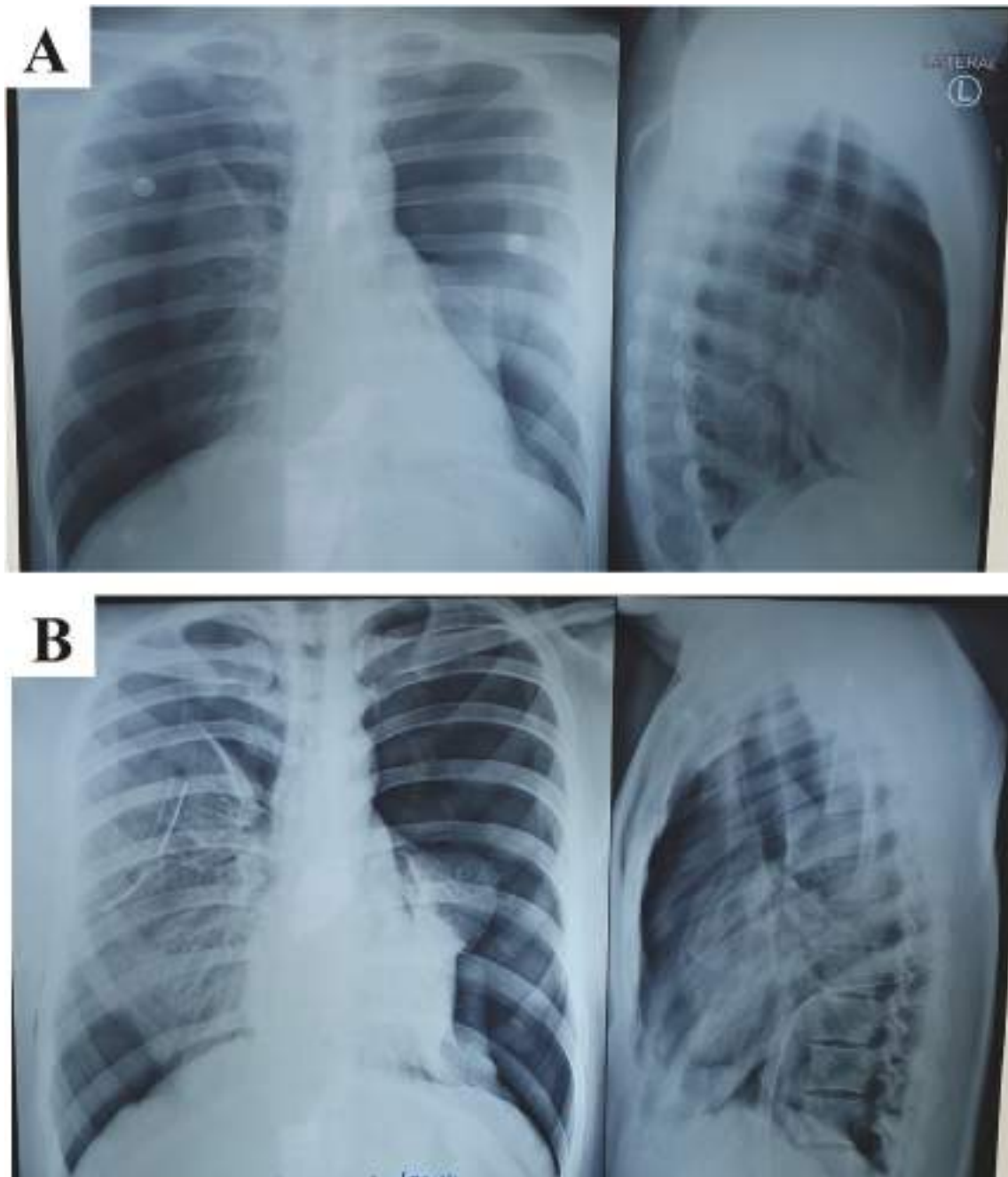


Fig. 1. A. Chest X-ray of anterior-posterior and left lateral before chest tube insertion; B. Chest X-ray of anterior-posterior and left lateral after chest tube insertion.

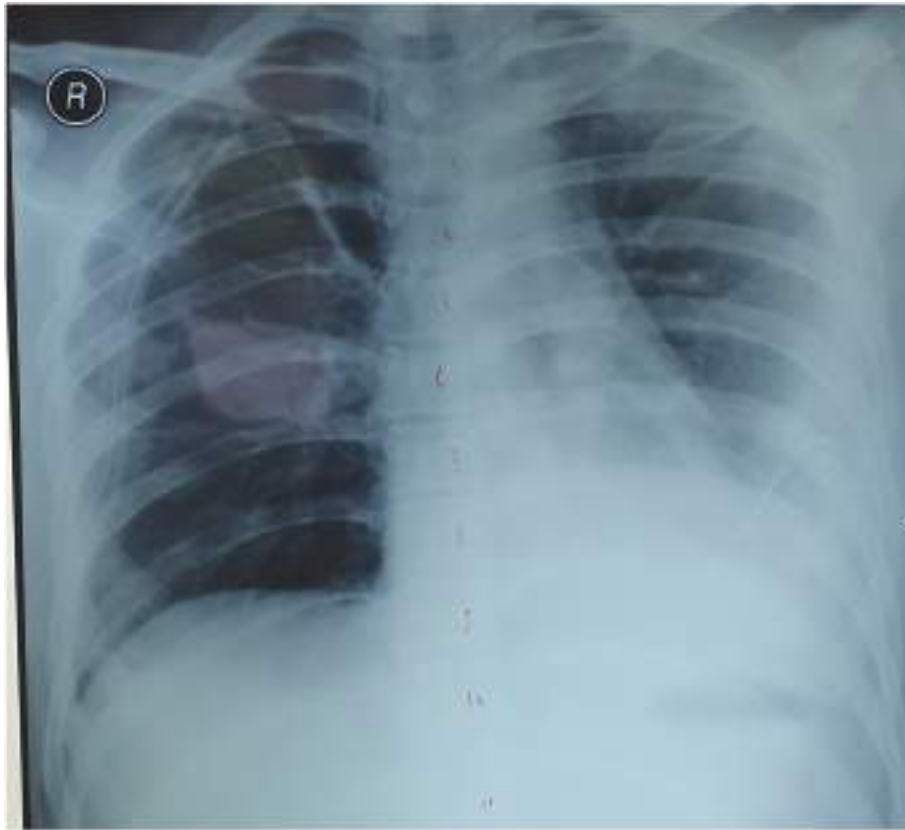


Fig. 2. Chest X-ray of anterior-posterior that shows a maximum expansion of right lung, while the left lung is still not in the maximum condition.

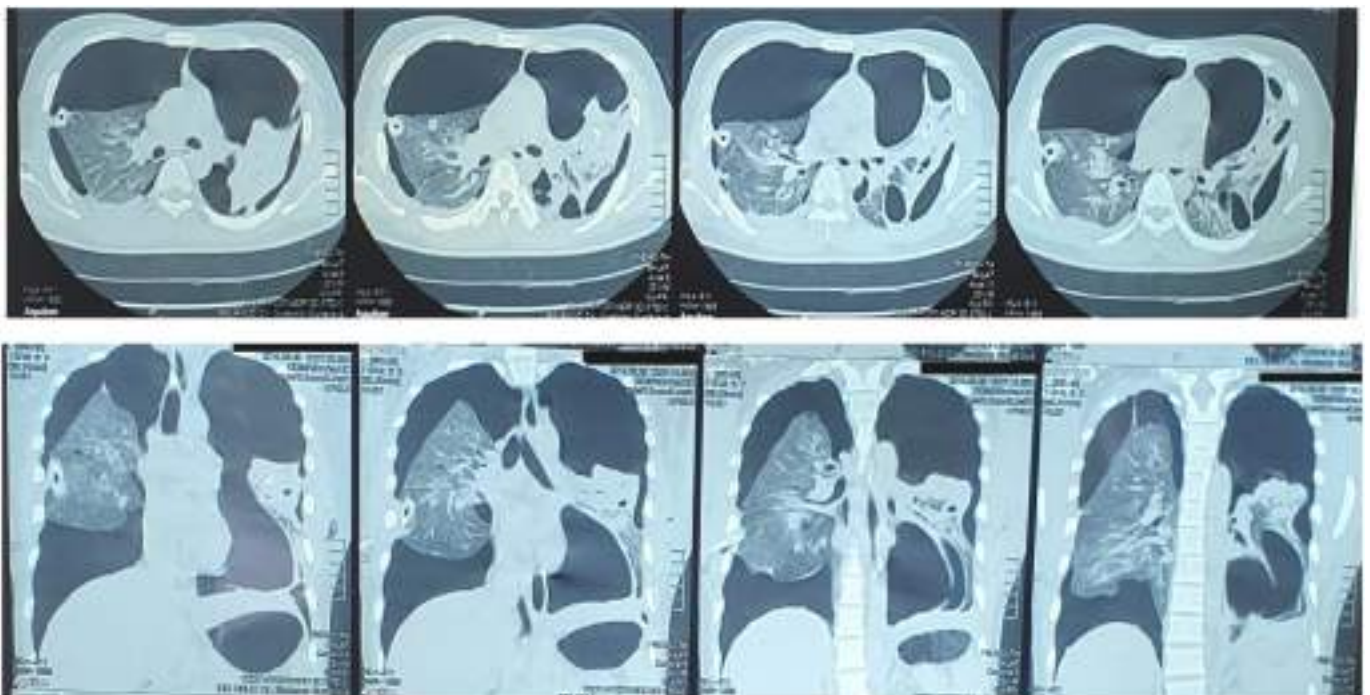


Fig. 3. CT scan showing multiple blebs in the apical segment of the right superior lobe and the apicoposterior segment of the left superior lobe.

pressure that exceeds atmospheric pressure, causing mediastinal deviation, reducing venous return, and cardiovascular collapse [7]. According to the British Thoracic Society guidelines (2003), approximately 50% of PSP patients go to the hospital >2 days after the onset of

symptoms [2].

Diagnosis of patients with PSP is conducted through an accurate medical history, detailed physical examination, and evaluation of radiological examinations. A chest X-ray taken with the patient standing

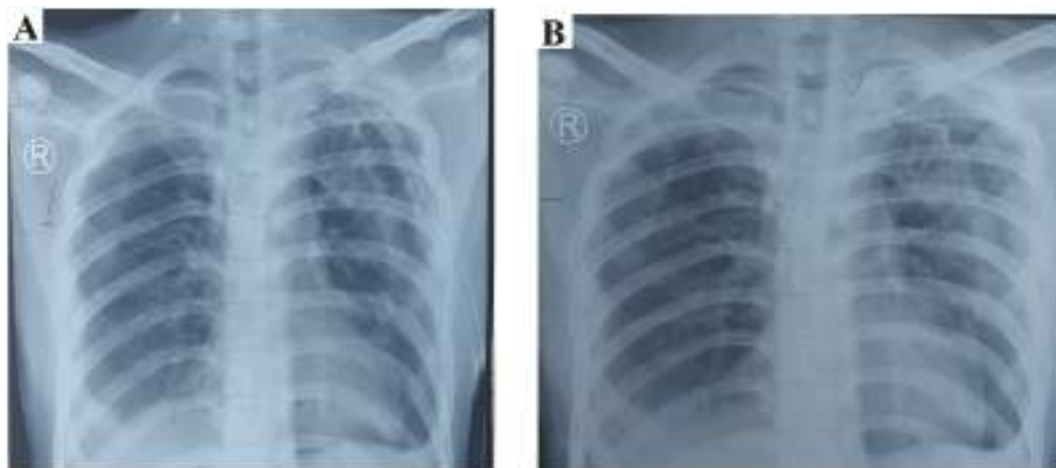


Fig. 4. Chest X-ray of anterior-posterior before (a) and after WSD removal (b).

(PA and lateral projections) has a sensitivity of about 70%. Thoracic computed tomography (CT) scan has a sensitivity of 100% and can determine the size of the pneumothorax. It can also assess changes in the lung parenchyma to determine the cause of the condition [2]. Observation can be performed as initial management in patients with a pneumothorax less than 1 cm. At the time of observation, PSP patients are administered with 100% oxygenation because it can increase the reabsorption time of pneumothorax by 4 times. The resolution of pneumothorax is about 1.3–2.2% of hemithorax volume per 24 h. The chest X-ray is repeated 4–6 h after diagnosis to ensure that pneumothorax is not enlarged. Once the pneumothorax is proven stable, the patient can be discharged and controlled through an outpatient clinic. Successful observation in patients with small PSP accounts for more than 80% of cases. Patients with small PSP have a lower potential recurrence rate when observed than with chest tube insertion [8].

Aspiration can be utilized as initial management for patients with primary pneumothorax. The procedure may be considered for younger patients (<50 years old) with a secondary pneumothorax of moderate size (1–2 cm in size). Percutaneous needle aspiration results from incomplete lung expansion in 59–83% of patients with PSP and 33–67% of patients with PSS. The recurrence rate of pneumothorax after aspiration is almost the same as after chest tube insertion. Chest tube insertion is the most common surgical procedure performed in thoracic surgery. Chest tube placement is indicated for patients with symptomatic PSP, as well as symptomatic, iatrogenic, and traumatic pneumothorax. The goal of chest tube placement is an expansion of the collapsed lung [8].

Surgery is a common method for pneumothorax with persistent air leakage (5–7 days after thoracic drainage), failure of lung expansion, repeated pneumothorax (ipsilateral or contralateral), bilateral spontaneous pneumothorax, hemothorax, patients with high-risk occupation (aircraft personnel, scuba divers). The goal of surgery for pneumothorax is to remove air from the pleural space (bleb resection) and prevent recurrence (removal of the intrapleural space). Small posterolateral thoracotomy, transaxillary mini-thoracotomy, minimally invasive endoscopic surgery (VATS) are common surgical procedures. Bullae can be removed by different surgical procedures, including lung resection, staple excision, electrocoagulation, suture ligation. To prevent recurrence of the pneumothorax, resection is combined with several procedures to remove the inter-pleural space. These procedures can include parietal pleurectomy (partial-apical or total), parietal pleural abrasion (mechanical pleurodesis), chemical pleurodesis (application of sclerosing agents). Open thoracotomy with bullectomy and pleural abrasion or pleurectomy can effectively reduce the recurrence rate by 1%. In minimally invasive surgery, not all blebs can be detected, and the recurrence rate is 5–10% higher, but the length of hospitalization is

shorter better postoperative lung air exchange, and less severe postoperative pain [8–10].

Open surgery is slightly superior or equally effective as the ‘closed’ thoracoscopy method but has higher morbidity. A thoracoscopy is recommended should there are clinical indications for invasive surgery. When performed without pleurodesis, the recurrence rate is very high up to 20%. Adequate pleurodesis is the basis for thoracoscopy, thereby preventing recurrence. All pleurodesis techniques are based on the successful induction of some form of pleural inflammatory agent. This can be achieved by mechanical abrasion, partial resection, or thoracoscopy installation of an abrasive agent (e.g. talc). There is evidence that the use of talc is safe, in both short and long-term studies and does not cause cancer, pulmonary fibrosis, impaired lung function, or impairment in subsequent thoracic surgery, and is the cheapest agent. Recurrence prevention techniques on thoracoscopy, be it ‘medical’ or ‘surgical’, usually show a recurrence rate of between 0 and 10% [2,11,12].

4. Conclusion

A 20-year-old man with a complaint of shortness of breath is suspected of having PSP and tuberculosis. Water seal drainage is installed in both lung cavities. When treated for a few days, the lung condition has an ups and downs prognosis. GeneXpert results do not support the diagnosis of tuberculosis. Bleb is found in both lung cavities, thereby wedge resection is performed with VATS. After treatment, the lung condition improved and the WSD is removed.

Consent

We have requested the patient's consent to publish this case report for educational purposes.

Funding

None.

Ethical approval

We have conducted an ethical approval base on the Declaration of Helsinki at Ethical Committee in Dr. Soetomo General Academic Hospital, Surabaya, Indonesia.

Guarantor

Resti Yudawati.

Research registration

Not applicable.

Provenance and peer review

Not commissioned, externally peer-reviewed.

CRedit authorship contribution statement

Nisya Hapsari: collecting data, analysis, drafts, revisions, and supervision; Resti Yudhawati: methodology, analysis, revision, and review.

Declaration of competing interest

The authors declare that they have no conflict of interest.

Acknowledgment

We would like to thank Fis Citra Ariyanto for helping us in the editing and proofreading process.

References

- [1] P. Mendogni, J. Vannucci, M. Ghisalberty, M. Anile, B. Aramini, M.T. Congedo, et al., Epidemiology and management of primary spontaneous pneumothorax: a systematic review, *Interact. Cardiovasc. Thorac. Surg.* 30 (3) (2020) 337–345, <https://doi.org/10.1093/icvts/ivz290>.
- [2] A. Dzeljilji, W. Rokicki, M. Rokicki, K. Karus, New aspects in the diagnosis and treatment of primary spontaneous pneumothorax, *Kardiochir Torakochirurgia Pol.* 14 (1) (2017) 27–31, <https://doi.org/10.5114/kitp.2017.66926>.
- [3] Rob Hallifax J, Magda Laskawiec-Szkonter, Najib Rahman M, Predicting outcomes in primary spontaneous pneumothorax using air leak measurements, *Thorax* 74 (4) (2019) 410–412, <https://doi.org/10.1136/thoraxjnl-2018-212116>.
- [4] S.P. Luh, Review: diagnosis and treatment of primary spontaneous pneumothorax, *J Zhejiang Univ Sci B* 11 (10) (2010) 735–744, <https://doi.org/10.1631/jzus.B1000131>.
- [5] J. Kewcharoen, P. Morris, C. Kanitsoraphan, H. La, N. Sriratanaviriyakul, Simultaneous bilateral primary spontaneous pneumothorax: a case report and a review of the literature, *Case Rep. Pulmonol.* 2019 (2019) 6583842, <https://doi.org/10.1155/2019/6583842>.
- [6] R.A. Agha, T. Franchi, C. Sohrabi, G. Mathew, A. Kerwan, A. Thoma, et al., The SCARE 2020 guideline: updating consensus surgical CAse REport (SCARE) guidelines, *Int. J. Surg.* 84 (2020) 226–230, <https://doi.org/10.1016/j.ijsu.2020.10.034>.
- [7] X. Wang, L. Wang, H. Wang, H. Zhang, Simultaneous bilateral video-assisted thoracoscopic surgery for the treatment of primary spontaneous pneumothorax, *Cell Biochem. Biophys.* 71 (3) (2015) 1703–1708, <https://doi.org/10.1007/s12013-014-0393-7>.
- [8] P. Zarogoulidis, I. Kioumis, G. Pitsiou, K. Porpodis, S. Lampaki, A. Papaiwannou, et al., Pneumothorax: from definition to diagnosis and treatment, *J. Thorac. Dis.* 6 (Suppl 4) (2014), S372-S6, <https://doi.org/10.3978/j.issn.2072-1439.2014.09.24>.
- [9] S. Kepka, J.C. Dalphin, A.L. Parmentier, J.B. Pretalli, M. Gantelet, N. Bernard, et al., Primary spontaneous pneumothorax admitted in emergency unit: does first episode differ from recurrence? A cross-sectional study, *Can. Respir. J.* 2017 (2017), 2729548, <https://doi.org/10.1155/2017/2729548>.
- [10] J. Plojoux, M. Froudarakis, J.P. Janssens, P.M. Soccal, J.M. Tschopp, New insights and improved strategies for the management of primary spontaneous pneumothorax, *Clin. Respir. J.* 13 (4) (2019) 195–201, <https://doi.org/10.1111/crj.12990>.
- [11] M. Noppen, T. De Keukeleire, Pneumothorax, *Respiration* 76 (2) (2008) 121–127, <https://doi.org/10.1159/000135932>.
- [12] G. Cardillo, O.J. Bintcliffe, F. Carleo, L. Carbone, M. Di Martino, B.C. Kahan, et al., Primary spontaneous pneumothorax: a cohort study of VATS with talc poudrage, *Thorax* 71 (9) (2016) 847–853, <https://doi.org/10.1136/thoraxjnl-2015-207976>.