

The pattern of osteocyte in dental socket bone regenerative induced by hydroxyapatite bovine tooth graft



Nanik Zubaidah^{1*}, Sri Kurnati¹, Nadira Nurin Febrianti²,
Arif Rahman Nurdianto³, Wanda Oktaria⁴, Muhammad Luthfi⁵

¹Department of Conservative Dentistry, Faculty of Dental Medicine, Universitas Airlangga, Surabaya – Indonesia;

²Undergraduate Student of the Faculty of Dental Medicine, Universitas Airlangga Surabaya – Indonesia;

³Lecture in Universitas Anwar Medika, Sidoarjo, Indonesia;

⁴Resident of Conservative Dentistry Department, Faculty of Dental Medicine, Universitas Airlangga, Surabaya- Indonesia;

⁵Department of Oral Biology, Faculty of Dental Medicine, Universitas Airlangga, Surabaya- Indonesia

*Corresponding to:

Nanik Zubaidah; Faculty of Dental Medicine, Jl. Mayjen. Prof. Dr. Moestopo No.47 Surabaya – Indonesia;
nanik-z@fkg.unair.ac.id

Received: 2022-08-20

Accepted: 2022-10-02

Published: 2022-11-09

ABSTRACT

Background: Tooth extraction is a procedure with the highest prevalence of causing alveolar bone damage. After extraction, the dimension will change. This procedure needs a balance of bone formation and resorption. Osteocytes are the most common cells in bone and have an essential role in bone formation. This study explores the effect of hydroxyapatite bovine tooth grafts on the number of osteocytes in the socket preservation process post-dental extraction.

Methods: A total of 28 Wistar rats, 14 control and 14 treatment groups, were extracted on the lower left incisor. Control group with PEG without induction and treatment group with bovine tooth graft and PEG induction. On the 14th and 28th days, the rats were euthanized. Then perform histological examination with HE staining and cell counting using a light microscope

Results: We found the treatment group had higher the average number of the osteocyte, which was 146.43 ± 11.41 on 14th day and 288.14 ± 161.91 on 28th day. There was a significant increase in osteocytes among the treatment group compared to the control ($p=0.000$).

Conclusion: Hydroxyapatite bovine tooth graft application as dental socket preservation was proven to increase the number of osteocyte cells in the alveolar bone of Wistar rats after extraction. Bovine tooth grafts as dental socket preservation materials increased the number of osteocytes at a peak at 28 days.

Keywords: Bovine tooth graft, regenerative dentistry, Osteocyte, Osteogenesis, Dental Health.

Cite This Article: Zubaidah, N., Kurnati, S., Febrianti, N.N., Nurdianto, A.R., Oktaria, W., Luthfi, M. 2022. The pattern of osteocyte in dental socket bone regenerative induced by hydroxyapatite bovine tooth graft. *Bali Medical Journal* 11(3): 1489-1493. DOI: 10.15562/bmj.v11i3.3844

INTRODUCTION

Tooth extraction is also one of the actions with the highest prevalence of causing complications or damage to the alveolar bone and surrounding tissue.¹⁻³ Damage to the alveolar bone can occur in endodontic surgery, one of which is in the act of surgical hemisection. Surgical hemisection removes one side of the dental root that has an infection or is necrotic by cutting the tooth into two pieces. In contrast, it has been done with endodontic treatment and obturation of the root canal on the remaining dental root.

Sockets formed after extraction, if not done with therapy, will experience a change in dimensions.⁴ In their review, Van der Weijden et al. showed that the clinical loss in width was greater than the loss in height, assessed clinically and radiographically.⁵ This dimensional change

occurs due to a progressive resorption process in the alveolar bone during the healing process. In this healing phase, it can cause about 20% to experience resorption of the horizontal plane of the alveolar bone and a decrease of about 50% in the vertical height of the bone wall.⁶

Socket preservation is one way to minimize dimensional changes in the alveolar bone by stimulating bone formation so that homeostasis between bone formation and resorption occurs.^{4,7} Socket preservation is done by applying a bone graft on the socket or area experiencing bone resorption.⁴ A good bone graft material must have any characteristics. It includes osteoconductive properties, stimulates growth factors, and is a stable material.⁸

The bovine tooth is one part of the cow that is part of the waste. It has morphology and chemical elements that are almost

similar to human teeth, one of which is the presence of hydroxyapatite. It has the character of stimulating osteoprogenitors that can support bone metabolism in sockets. The study on FTIR conducted by Ratnayake et al. showed a similar result of wavelength among hydroxyl, phosphate, and carbonate groups in hydroxyapatite in bovine teeth. In addition, the X-ray diffraction showed a higher profile than the synthetic hydroxyapatite. This study indicates a higher formation of bovine tooth hydroxyapatite than the synthetic product.⁹ There were no statistically significant differences between the bovine and human radicular dentin.¹⁰ It also has a similar number of dentin tubules and amino acid composition of enamel matrix protein to the bovine and human teeth. In contrast, the bovine tooth has a higher calcium ion release.¹¹

In the dentin of the bovine tooth, there

are also micro-porous that can help the adhesion and growth of cells to cause faster cell growth. The existence of micro-porous also supports the increase in mechanical strength when used as a graft material. It is also supported by research conducted by Ratnayake et al., which states that bovine dentine-derived hydroxyapatite has a higher mechanical strength than bovine bone graft, which has been widely used today.⁹

Hydroxyapatite bovine tooth graft can be applied to sockets with carrier substances. The most commonly used carrier is PEG. PEG was used in this study as a valuable carrier polymer to facilitate the delivery of bovine tooth grafts in tissues.¹² PEG is one of the materials with a high level of biodegradation in-vivo, so it is expected to be a beneficial carrier in bovine tooth grafts.¹³ PEG can increase solubility, reduce aggregation rates and increase the stability of bovine tooth graft particles, has low toxicity, is non-immunogenic, biocompatible, biodegradable, and has been approved by the FDA (Food and Drug Administration) for use in humans as a biomedical material.¹⁴

The study will be observed on the 14th and 28th days post-induction. Hassan and Al-Gahban showed that osteocytes could be identified in new trabeculae bones on the 14th day after intervention. Chairunas and Saputri showed that the peak expression of osteocytes was present on the 28th day after induction.^{15,16}

This study will explore the effect of a Bovine tooth graft supplemented with PEG as a carrier in the increase of osteocytes in the dental socket of Wistar rats on the 14th day and the 28th-day post-extraction

MATERIAL AND METHODS

The study was conducted at the Laboratory of Biochemistry, Faculty of Medicine Universitas Airlangga, and was approved by the ethics committee, Faculty of Dental Medicine, Universitas Airlangga (No. 490/HRECC). FODM/VIII/2021).

This study used 28 Wistar rats (*Rattus norvegicus* strain Wistar) and divided them into two groups, the treatment, and control groups, 14 rats per group, all male and healthy, aged 12-16 weeks, weighing 150-200 grams, and with no injuries or defects.^{17,18} Wistar rats were placed in

plastic cages for one week and fed and watered ad libitum with the replacement of husk every two days. The Wistar rats were located in a separate cage for every two rats and taken at an ambient temperature.^{18,19}

The rats were anaesthetized by injection with ketamine and xylazine intramuscularly in the femoral. Then the lower left of the tooth was extracted with forceps. We applied the treatment group with HAP-BTG+PEG in the dental socket, and the wound was closed by sewing.¹⁸ The control group was injected with PEG (Polyethylene glycol). All the Wistar rats were evaluated for 14 and 28 days, then euthanized using ketamine and xylazine until overdose and cutting of dental socket tissue. The tissue was immersed in formalin liquid and then processed to provide a paraffin block. The block tissue was cut 4

micrometers thick, put in glass, fixation, and stained with HE (Hematoxylin Eosin). The osteocytes were observed with a light microscope with a magnification of 400x in 5 microscopic fields. We perform statistical analysis of the total number of osteocytes of 5 microscopic fields with SPSS version 25.

RESULTS

The data from this study obtained a histological picture that shows the number of osteocyte cells (Figure 1, Arrow). Figure 1 shows that osteocyte cells in the 14th-day treatment group were significantly higher than in the control group. Also, in Figure 2, there is a significant difference in the number of osteocyte cells in the 28th-day treatment group to the control group.

Table 1. The average number of osteocyte cells per five microscopic fields in 14 and 28 days, and between control and treatment groups

Sample Group	N	Mean	Standard Deviation
14th-day Control Group (K1)	7	82.71	11.41
14th-day Treatment Group (P1)	7	146.43	12.10
28th-day Control Group (K2)	7	221.71	12.86
28th-day Treatment Group (P2)	7	288.14	16.91

Notes: Average results of the number of osteocyte cells in each sample group

Table 2. The significance among the number of osteocytes per 5 microscopic fields, of 14 versus 28 days, and between the control and treatment group

		28 th day		
		Control	Treatment	
14 th day	Mean	221.71	288.14	
	Control	82.71	P=0.000*	P=0.000***
	Treatment	146.43	- P=0.000*	
		P=0.000**		

Notes: *: p between 14th versus 28th days of the control groups or treatment groups; **: p between control versus treatment group at 28 days evaluation, and *** at 14 days.

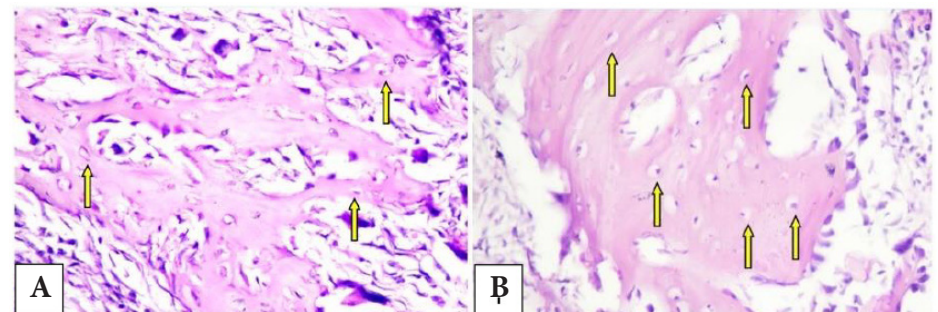


Figure 1. Microscopic view with 400x magnification of osteocyte cells (yellow arrow) in the 14th-day control group (A) and the 14th-day treatment group (B).

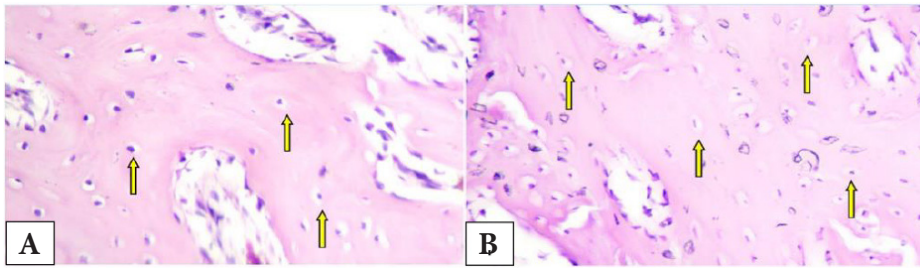


Figure 2. Microscopic examination with 400x magnification of osteocyte cells (arrows) in the 28th-day control group (a) and the 28th-day treatment group (b).

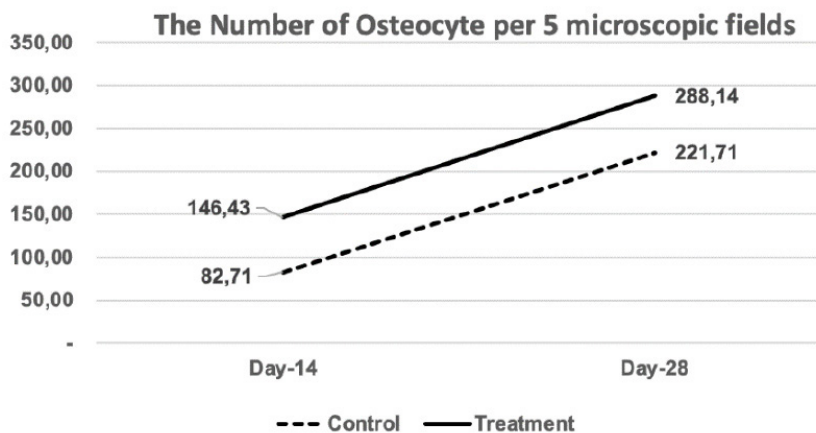


Figure 3. The chart of the number of osteocytes per 5 microscopic fields in 14 and 28 days, and between control and treatment groups.

All the data were statistically normal distribution (Shapiro Wilk test, $p=0.935$). We continued the statistical testing with ANOVA, followed by the Tukey test at a significant level of 0.05. There were significantly different between treatment (higher) versus the control group and in 28 days of evaluations versus 14 days ($p<0.001$). [Table 1](#), [Table 2](#) and [Figure 3](#).

DISCUSSION

Bovine teeth are an alternative material with morphology and chemical elements almost similar to human teeth. In cows, teeth found the presence of hydroxyapatite that can stimulate osteoprogenitors. This material can be used as a graft to support bone healing in sockets. This material has more apatite crystals than synthetic hydroxyapatite. Micro porous in bovine teeth can also help with cell adhesion and growth, so cell growth is faster.⁹

The treatment group was induced with a bovine tooth graft and PEG as the carrier in this experiment. PEG is a polymer that

serves as a valuable carrier to facilitate the delivery of bovine tooth grafts on tissues, and this material is absorbable.¹² This study uses PEG 400 and PEG 4000 to form a gel-shaped medium so that the bovine tooth graft can be distributed on the socket properly.¹⁷

Hydroxyapatite is a low-biodegradation material. Hartatiek et al. showed that scaffolds containing more hydroxyapatite would have longer biodegradation.¹³ The same study also mentioned that PEG has a high biodegradation level.¹⁸ The PEG, chitosan mixture, and 4% hydroxyapatite can produce scaffolds with the best biodegradation.¹³

Our study's results found an increase in the number of osteocytes in the 28th-day control group compared to the 14th-day control group and an increase in the 28th-day treatment group compared to the 14th-day treatment group. This study also showed that the number of osteocytes is higher in treatment compared to the control group. It means that HAp-BTG impacts more osteocyte increase, which

can speed up bone formation. Sadr et al. showed that the maximum bone formation stage is identified at 14 days, characterized by high osteoblastic activity to produce the osteocytes.¹⁹ Our study showed that the osteocytes increased within 14 days of evaluation and continuously increased until 28 days.

The results of the 28th day showed an increase in the number of osteocyte cells compared to the average number of osteocyte cells on the 14th day after tooth extraction. This result is in line with the previous study by Hassan and Al-Gahban showed that applying grape seed oil to a post-extraction dental socket in rabbit teeth can increase osteocytes until the peak after 28 days.¹⁵ Olaitan et al. also stated in their study on histology picture in the healing process of sockets after rabbit tooth extraction that the fourth week after removal obtained the highest amount of osteocytes compared to the second week after extraction.¹⁹ The study by Zubaidah et al. showed that there was increasing after the application of HAp-BTG (Hydroxyapatite Bovine tooth graft) in dental socket post-extraction of any biomarker of bone healing, such as collagen type 1, BSP, and significantly decreased MMP-8.²⁰ It means that the healing process of the bone socket is aggravated. Thus, osteocytes as a part of bone regenerative are also increasing for inducing bone healing.

Our study found that the results of the 14th-day treatment group were higher compared to the 14th-day control group and the 28th-day treatment group was higher compared to the 28th-day control group. The other study by Sari et al. showed that hydroxyapatite bovine tooth graft increased the bone development rate.²¹ Hydroxyapatite in bovine tooth grafts can stimulate osteoprogenitor's differentiation into bone-forming cells. Moreover, stimulate surrounding osteogenic cells for proliferation.²² The hydroxyapatite content in bovine tooth graft stimulates stem cells to proliferate faster and differentiate with scaffold formation.²² Calcium phosphate levels in hydroxyapatite will deposit and form apatite crystals. These apatite crystals will then form microporous, a suitable medium for mesenchymal cell proliferation and differentiation.²³⁻²⁵

The mesenchymal cells differentiate into osteoblasts and begin to secrete osteoids along areas that have been injected with bone grafts.²⁶ Bone in air-breathing vertebrates is a specialized tissue that developmentally replaces cartilage as simpler solid tissues. Bone is a living organ bound with any bone material. These materials include osteoblast, bone matrix, and osteocyte. The osteocytes are reorganized in the matrix as living cells. It communicates with each other through matrix canaliculi.²⁷ Bovine bone matrix proteins (BBMPs) also increase mineral deposition five folds compared to without intervention in in-vitro experimental. It was supported by osteoblast growth and differentiation, which also increased the osteocytes.^{28,29}

Increased proliferation and differentiation of mesenchymal cells into osteoblasts due to stimulation of hydroxyapatite bovine tooth graft leads to increased osteocyte cells in the induced area.³⁰ The increase of osteocytes will impact the rise of osteoprotegerin. That inhibits RANK and RANKL binds, decreasing bone resorption in the remodeling phase.^{31,32} This event results in the formation of alveolar bone to be more optimal so that homeostasis can balance bone formation and bone resorption in the socket.^{7,33}

CONCLUSION

In conclusion, our study showed that applying hydroxyapatite bovine tooth graft in dental socket post-extraction will impact: 1). increase the number of osteocytes; 2). optimize the bone healing process.

ACKNOWLEDGMENTS

We thank Mr Heri for supporting us during the animal experiments in the Laboratory of Biochemistry, Faculty of Medicine Universitas Airlangga

DISCLOSURE

Conflict of Interest

The authors declare no conflict of interest.

Funding

Self-funding

Author Contribution

Conceptual development, N.Z., M.L.; methodology, N.Z., M.L., SK.; validation, N.Z., M.L., SK.; data analysis, N.Z., M.L and SK.; investigation, N.Z., M.L SK.; resources, N.Z., NNF,WO, ARN.; writing—original draft preparation, N.Z., M.L., NNF, SKT; writing—review and editing, N.Z., M.L., ARN.; supervision, N.Z., M.L.; project administration, NNF; WO, ARN....All authors have read and agreed to the published version of the manuscript.

REFERENCES

- Goswami A, Ghorui T, Bandyopadhyay R, Sarkar A, Ray A. A General Overview of Post Extraction Complications-Prevention, Management and Importance of Post Extraction Advices. *Fortune J Heal Sci.* 2020;03(03):135-147. doi:10.26502/fjhs014
- Fan G, Shen Y, Cai Y, Zhao J hong, Wu Y. Uncontrollable bleeding after tooth extraction from asymptomatic mild haemophilia patients: two case reports. *BMC Oral Health.* 2022;22(1):1-8. doi:10.1186/s12903-022-02074-9
- Moran IJ, Richardson L, Heliotis M, Bewick A. A bleeding socket after tooth extraction. *BMJ.* 2017;357(box 1):1-5. doi:10.1136/bmj.j1217
- Nardiatmo SPS, Mapangara S, Jais AI. Socket preservation after tooth extraction : a systematic review Mempertahankan soket setelah pencabutan gigi : tinjauan sistematis. *Makassar Dent J.* 2019;8(2):91-96.
- Van Der Weijden F, Dell'Acqua F, Slot DE. Alveolar bone dimensional changes of post-extraction sockets in humans: A systematic review. *J Clin Periodontol.* 2009;36(12):1048-1058. doi:10.1111/j.1600-051X.2009.01482.x
- Fee L. Socket preservation. *Br Dent J.* 2017;222(8):579-582. doi:10.1038/sj.bdj.2017.355
- Listari KM, Ruhadi I, Ulfa N. Ekspresi Rankl Pada Defek Tulang Dengan Pemberian Xenograft Dibandingkan Dengan Xenograft Dan Prf. *E-Prodenta J Dent.* 2019;3(1):216-224. doi:10.21776/ub.eprodenta.2019.003.01.5
- Lobb DC, DeGeorge BR, Chhabra AB. Bone Graft Substitutes: Current Concepts and Future Expectations. *J Hand Surg Am.* 2019;44(6):497-505.e2. doi:10.1016/j.jhsa.2018.10.032
- Ratnayake JT, Ross ED, Dias GJ, et al. Preparation, characterisation and in-vitro biocompatibility study of a bone graft developed from waste bovine teeth for bone regeneration. *Mater Today Commun.* 2020;22:100732. doi:10.1016/j.mtcomm.2019.100732
- Tanaka JLO, Medici Filho E, Salgado JAP, et al. Comparative analysis of human and bovine teeth: Radiographic density. *Braz Oral Res.* 2008;22(4):346-351. doi:10.1590/S1806-83242008000400011
- Yassen GH, Platt JA, Hara AT. Bovine teeth as a substitute for human teeth in dental research: a review of the literature. *J*

- Oral Sci.* 2011;53(3):273-282. doi:10.2334/josnusd.53.273
- Larasati D, Sulistiani R. Kajian Efek Analgetik Dispersi Padat Ibuprofen - PEG 6000 Menggunakan Metode Writhing Test. *J Kesehat Madani Med.* 2020;11(01):35-43.
- Hartatiek, Yudyanto, Nada Shofura F, et al. Morphology, porosity, and biodegradation of PVA/CS/PEG/HA/P nanofiber composites as a scaffold in bone tissue engineering. *AIP Conf Proc.* 2020;2231(April):2-8. doi:10.1063/5.0002678
- Nugraha B. Application of PEG in Drug Delivery System. 2016;(January 2016):137-147. doi:10.1142/9789813140417_0006
- Hassan AA, AL-Ghaban NM. Histological Evaluation of the Effect of Local Application of Grape Seed Oil on Healing Process of Extracted Tooth Socket in Rabbits. *Diyala J Med.* 2019;17(2):70-84. doi:10.26505/djm.17024670515
- Chairunas, Saputri D, Putri MK. Daya Fitro-respon Ekstrak Etanol Daun Kelor (*Moringa oleifera*) Terhadap Sel Osteosit dan Matriks Tulang Mandibula Tikus (*Rattus norvegicus*). *Cakradonya Dent J.* 2020;12(2):83-88.
- Prahasanti C, Nugraha AP, Saskianti T, Suardita K, Riawan W, Ernawati DS. Exfoliated human deciduous tooth stem cells incorporating carbonate apatite scaffold enhance BMP-2, and BMP-7 and attenuate MMP-8 expression during initial alveolar bone remodeling in Wistar rats (*Rattus norvegicus*). *Clin Cosmet Investig Dent.* 2020;12(November):79-85. doi:10.2147/CCIDE.S245678
- Khoswanto C. A New Technique for Research on Wound Healing through Extraction of Mandibular Lower Incisors in Wistar Rats. *Eur J Dent.* 2019;13(2):235-237. doi:10.1055/s-0039-1694312
- Sadr K, Aghbali A, Sadr M, Abachizadeh H, Azizi M, Mesgari Abbasi M. Effect of Beta-Blockers on Number of Osteoblasts and Osteoclasts in Alveolar Socket Following Tooth Extraction in Wistar Rats. *J Dent (Shiraz, Iran).* 2017;18(1):37-42.
- Zubaidah N, Adventa Y, Pratiwi DD, Mooduto L, Setiawati EM, Kunarti S. The Pattern of Collagen, Col1A, BSP and MMP-8 in Alveolar Bone Socket Post Tooth Extraction of *Rattus Norvegicus* Strain Wistar After Induced with Hydroxyapatite Bovine Tooth Graft. *J Int Dent Med Res.* 2021;14(4):1447-1452.
- Sari DS, Maduratna E, Ferdiansyah, et al. Osteogenic Differentiation and Biocompatibility of Bovine Teeth Scaffold with Rat Adipose-derived Mesenchymal Stem Cells. *Eur J Dent.* 2019;13(2):206-212. doi:10.1055/s-0039-1694305
- Kresnoadi U, Rahayu RP, Rubianto M, Sudarmo SM, Budi HS. TLR2 signalling pathway in alveolar bone osteogenesis induced by Aloe vera and xenograft (XCB). *Braz Dent J.* 2017;28(3):281-286. doi:10.1590/0103-6440201600834
- Vijayan A, Sabareeswaran A, Kumar GSV. PEG grafted chitosan scaffold for dual growth factor delivery for enhanced wound healing. *Sci Rep.* 2019;9(1):1-12. doi:10.1038/s41598-019-55214-7.

24. Olaitan OH, Komolafe OA, Owotade FJ, Saka OS. Histologic Assessment of Extraction Sockets Following Tooth Extraction : Suitability of a Rabbit Model. *Niger J Dent Res*. 2019;4(1):1-4.
25. Chul Ho Jang, Cho GW, Song A-J. Effect of Bone Powder / Mesenchymal Stem Cell / BMP2 / Fibrin Glue on Osteogenesis in a Mastoid Obliteration Model. *In Vivo (Brooklyn)*. 2020;34:1103-1110. doi:10.21873/invivo.11881
26. Sari RP, Kurniawan H. Effectiveness of Anadara granosa shell-Stichopus hermanni granules at accelerating woven bone formation fourteen days after tooth extraction. *Dent J (Majalah Kedokt Gigi)*. 2019;52(4):177. doi:10.20473/j.djmg.v52.i4.p177-182
27. Blair HC, Larrouture QC, Li Y, et al. Osteoblast differentiation and bone matrix formation in vivo and in vitro. *Tissue Eng - Part B Rev*. 2017;23(3):268-280. doi:10.1089/ten.tub.2016.0454
28. Musson DS, Gao R, Watson M, et al. Bovine bone particulates containing bone anabolic factors as a potential xenogenic bone graft substitute. *J Orthop Surg Res*. 2019;14(1):1-11. doi:10.1186/s13018-019-1089-x
29. Rupani A, Balint R, Cartmell SH. Osteoblasts and their applications in bone tissue engineering. *Cell Health Cytoskeleton*. 2012;4:49-61. doi:10.2147/CHC.S21845
30. Anisah A, Delina M, Aisah N, Gustiono D. Pembuatan Graft Tulang Dengan Proses Ekstraksi Senyawa Hidroksiapatit Dari Tulang Korteks Sapi. *Spektra J Fis dan Apl*. 2018;3(1):31-36. doi:10.21009/spektra.031.05
31. Kattimani VS, Kondaka S, Lingamaneni KP. Hydroxyapatite--Past, Present, and Future in Bone Regeneration. *Bone Tissue Regen Insights*. 2016;7:BTRI.S36138. doi:10.4137/btri.s36138
32. Huntley R, Jensen E, Gopalakrishnan R, Mansky KC. Bone morphogenetic proteins: Their role in regulating osteoclast differentiation. *Bone Reports*. 2019;10(September 2018). doi:10.1016/j.bonr.2019.100207
33. Graunaite I, Lodiene G, Maciulskiene V. Pathogenesis of Apical Periodontitis: a Literature Review. *J Oral Maxillofac Res*. 2011;2(4):1-15. doi:10.5037/jomr.2011.2401.



This work is licensed under a Creative Commons Attribution