

# A 28-YEAR-OLD MAN WITH MEDIASTINAL SEMINOMA TREATED WITH BEP

*by* Laksmi Wulandari

---

**Submission date:** 20-Dec-2022 12:20PM (UTC+0800)

**Submission ID:** 1984854135

**File name:** case\_report\_folia-rizki.pdf (350.92K)

**Word count:** 3109

**Character count:** 17625

## Case Report

### A 28-YEAR-OLD MAN WITH MEDIASTINAL SEMINOMA TREATED WITH BEP

Agustinus Rizki, <sup>2</sup>Laksmi Wulandari<sup>ID</sup>

Department of Pulmonology and Respiratory Medicine, Faculty of Medicine, Universitas Airlangga / Dr. Soetomo General Academic Hospital, Surabaya, Indonesia

#### ABSTRACT

<sup>14</sup>Seminoma is a type of germ cell tumor. In this case, <sup>10</sup>presentation, a rare primary germ cell tumor was reported in the form of mediastinal seminoma. A 28-year-old man with symptoms of shortness of breath, chest pain, swelling in the right upper extremity, enlarged lymph nodes in the colli region. Thoracic physical examination revealed signs of pleural fluid in the right hemithorax. After obtaining the results of radiological and pathological investigations, a mediastinal mass was obtained, then BEP chemotherapy was given. After 3 cycles of chemotherapy, a partial response was obtained. Patients with mediastinal seminoma treated with BEP base chemotherapy gave a partial response.

**Keywords:** Germ cell tumor; mediastinal seminoma; health risk

#### ABSTRAK

Seminoma merupakan salah satu jenis dari Germ Cell Tumor. Pada presentasi kasus ini dilaporkan germ cell tumor berupa seminoma mediastinum yang jarang terjadi. Pria 28 tahun dengan gejala sesak napas, nyeri dada, bengkak pada ekstremitas atas kanan, didapatkan pembesaran kelenjar getah bening di regio colli. Pemeriksaan fisik toraks didapatkan tanda terdapat cairan pleura pada hemitoraks kanan. Setelah didapatkan hasil pemeriksaan penunjang radiologis dan patologi didapatkan massa mediastinal kemudian dilakukan pemberian kemoterapi BEP. Setelah dilakukan kemoterapi sebanyak 3 siklus didapatkan partial respons. Pasien dengan seminoma mediastinum dengan tatalaksana kemoterapi BEP base memberikan partial respon.

**Kata kunci:** Germ cell tumor; seminoma mediastinum; risiko kesehatan

**Correspondence:** <sup>2</sup>Laksmi Wulandari, Department of Pulmonology and Respiratory Medicine, Faculty of Medicine, Universitas Airlangga/Dr. Soetomo General Academic Hospital, Surabaya 60286, Indonesia. Email: laksmigts@yahoo.co.id

pISSN:2355-8393 • eISSN: 2599-056x • doi: 10.20473/fmi.v57i4.21037

• Fol Med Indones. 2021;57:351-356 • Submitted 15 Feb 2021 • Revised 20 Oct 2021 • Accepted 2 Nov 2021

• Open access under CC-BY-NC-SA license • Available at <https://e-journal.unair.ac.id/FMI/>

## INTRODUCTION

Seminomas are part of the germ<sup>17</sup>l tumor. Seminomas of mediastinal masses are rare. The International Germ Cell Consensus Classi<sup>17</sup>tion classifies mediastinal seminomas as stage III with good, moderate and poor risk categories based on clinical factors including histology, primary tumor location, metastases, and<sup>10</sup>um tumor marker levels. In this case, we reported on the diagnosis and management of a mediastinal seminoma causing a chylothorax and receiving BEP therapy.

## CASE REPORT

<sup>5</sup>Mr. F, a 28-year-old man, came with complaints of shortness of breath, intermittent right chest pain, no complaints of cough, no fever, no decrease in appetite, no weight loss, and no night sweats. The patient complained that his right hand and arm were swollen.

<sup>9</sup>The patient did not reveal the history of trauma, high blood pressure, diabetes mellitus, heart disease, chronic liver disease, asthma and tuberculosis treatment. The patient was a smoker with Brinkman index of 60.

Tachycardia and tachypnea were found in the patient. On head and neck examination, we obtained enlarged lymph nodes in the left and right colli region measuring 2 cm as well as colli edema. Thoracic physical examination revealed pleural fluid in the right hemithorax. Edema was found in the right upper limb.

Laboratory examination showed leukocytosis 10110/ $\mu$ L, granulocytosis 91.7%, hypoalbumin 2.92 gr/dL, and CRP increase of 57.63. Pleural fluid examination obtained dominant polymorphonuclear exudate with cholesterol 10 and triglyceride 858. Blood gas examination obtained metabolic acidosis compensated alkalosis respiratory without hypoxemia.

**19** Chest X-ray showed a blunted right costophrenic angle with homogeneous opacity in 2/3 lower right hemithorax, there was a profile of mass with a blunt edge and obtuse angle on the right perihilar, infiltrates at 1/3 of the right upper hemithorax (Figure 1a).

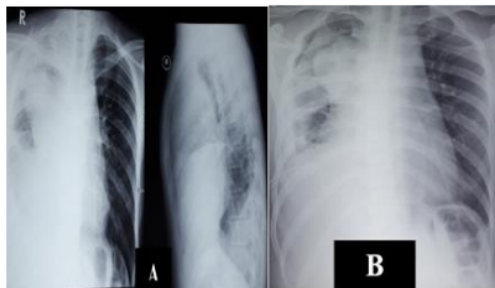


Figure 1. (A) Pre-chest tube thoracic x-ray (B) Post-chest tube thoracic x-ray

The examination of tumor markers showed LDH 551, beta-HCG 12.49 and AFP 3.8. Pleural fluid cell block examination did not show malignant cells. Examination of chest CT scan with contrast (Figure 2) showed solid lesion (34 HU) with calcified component (48 HU) within, well-defined, irregular edges measuring +/- 6.7 x 10.1 x 13.3 cm at anteromedial mediastinum – where by using contrast- showed enhancement (68 HU). The lesion appeared to encase the superior vena cava to the left side. Anatomical pathology examination with Fine Needle Aspiration Biopsy with CT-scan guidance showed malignant round cell carcinoma with suspicion of non-Hodgkin's lymphoma. Abdominal ultrasound (USG) examination did not show liver metastases and enlarged lymph nodes in the paraaortic. Abnormalities in the liver, gallbladder, spleen, pancreas, and kidney were not found. The patient underwent a core biopsy with thoracic ultrasound guidance and microscopic examination showed pieces of tissue with tumor growth arranged in lobules, consisting of proliferation of

anaplastic cells, rounded nucleus, relatively monotonous, hyperchromatic, narrow cytoplasm, mitosis 6/10 HPF. Fibrous connective tissue was also visible with lymphocyte infiltration. Tumor grew invasively among the fibrous connective tissue stroma, suggesting seminoma. Immunohistochemical examination (IHC) showed positive CD117 on tumor membrane, CD45 negative in tumor cells, positive in mature lymphocytes, positive PLAP in cytoplasm of tumor cells, and negative CK in tumor cells. Immunohistology examination confirmed the diagnosis of mediastinal seminoma.

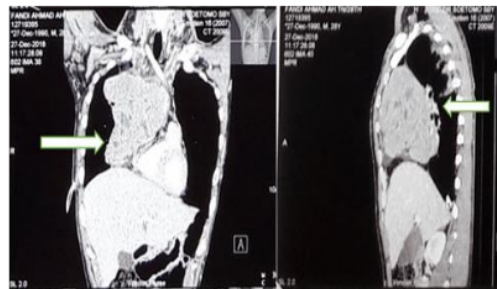


Figure 2. Chest CT-scan with contrast

**11** The patient received 100 mg/m<sup>2</sup> etoposide chemotherapy and 20 mg/m<sup>2</sup> cisplatin on days 1-5. Bleomycin was given 30,000 units on day 2, 9 and 16. During chemotherapy, clinical evaluation showed complaints of nausea, blackened skin, and hair loss. Laboratory tests showed leukopenia as a side effect of degree 2 chemotherapy. The patient received management of chemotherapy side effects.

After the second and third cycles of chemotherapy, side effects of degree 2 chemotherapy appeared, in the form of nausea and blackened skin and accompanied by leukopenia. After 3 cycles of chemotherapy, the general condition of the patient was sufficient, with subjective complaints of intermittent chest pain which improved with the administration of symptomatic therapy.

The patient underwent an evaluation of a thoracic CT scan without and with contrast (Figure 3) with the results, namely solid lesion (30 HU) and necrotic areas (16 HU), with calcification (257 HU) within, well-defined, irregular edges, size +/- 7.4 x 6.6 x 8.4 cm in the anteromedial mediastinum – where by contrast- showed enhancement (65 HU). Lesions appeared attached to the heart, causing pericardial effusion with a maximum thickness of +/- 2.1 cm. The lesion appeared to tighten, constrict and force the superior vena cava to the left side, accompanied by a thrombus in the superior vena cava, right and left brachiocephalic vein, right and

left internal jugular vein, left subclavian vein, encasing ascending aorta, right pulmonary artery and right pulmonary vein, right and left jugular vein, left subclavian vein, encasing ascending aorta, right pulmonary artery and right pulmonary vein, right left jugular vein, left subclavian vein, encasing ascending aorta, right pulmonary artery and right pulmonary vein, abutting main left bronchus accompanied by collateral veins in anterior right and left hemithorax. There was a bleb (-980 HU) sized +/- 2.7 x 4.4 x 2.6 cm in the apical segment of the superior lobe of the right lung. Lymph node enlargement was found to be +/- 0.6 cm in the right upper paratrachea, +/- 0.8 cm in the left upper paratrachea, +/- 0.7 cm in the lower left paratrachea and +/- 0.8 in the lower right paratrachea. Fluid density (19HU) was found in the right pleural cavity, loculated with thickening of the pleura +/- 0.4 cm, fluid density was visible in the left pleural cavity.

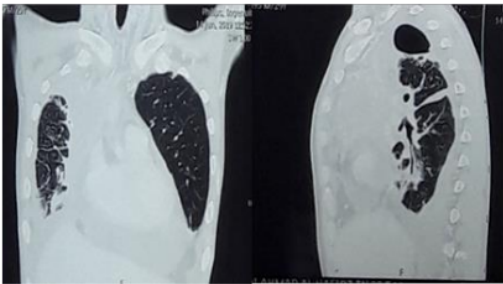


Figure 3. Chest CT scan without and with contrast evaluation after 3 cycles of BEP chemotherapy

The fourth cycle of the chemotherapy was given based on the results of the CT scan evaluation, in which the tumor size shrunk <30% (partial response). Clinical evaluation after the fourth cycle of the chemotherapy showed complaints of nausea and blackened skin, which was the side effect of degree 2 chemotherapy. The patient was unable to continue the 5<sup>th</sup> cycle chemotherapy, because the patient died.

## DISCUSSION

Symptoms, physical and radiological examination of chylothorax are the same as pleural effusion. Because of the presence of fluid in the thoracic cavity, the patient often experienced tightness. Pleuritic pain and fever were rare in the patient, because chyle did not irritate the pleural surface and did not cause inflammation. Long-term loss of chyle causes nutrient loss, hypovolemia, electrolyte disturbances, decreased leukocytes which may cause patient's death (Light & Lee 2016).

Chylothorax is the presence of chyle in pleural cavity and emerges after damage or obstruction of the thoracic duct. In the chyle, there are high concentrations of triglycerides. The diagnosis is made through the analysis of pleural fluid containing high triglycerides and is confirmed by the findings of chylomicrons (Parikh & Rajesh 2018).

In the patient Mr. F, we found symptoms of shortness of breath, no fever, chest pain disappeared. Laboratory tests showed hypokalemia and hypoalbuminemia. Pleural fluid examination showed elevated triglyceride levels and normal total cholesterol levels.

Chylothorax can be classified as traumatic and non-traumatic. The causes of non-traumatic chylothorax include malignancy (50%), sarcoidosis, retrosternal goiter, amyloidosis, superior vena cava thrombosis, benign tumors, congenital duct abnormalities (15%), and lymphatic canal diseases, such as yellow nail syndrome, lymphangioliomyomatosis (10%), and hemangiomas (17%) (Maldonado et al. 2009, Light & Lee 2016). Chylothorax due to lymphoma malignancy is found in 70% of cases, with higher numbers in non-Hodgkin than Hodgkin. Thoracic duct obstruction can also be caused by a metastatic process (McGrath et al. 2010).

Mr. F underwent thoracic CT-scan without and with contrast, and showed solid lesion (34 HU) with calcified component (48 HU) within, well-defined, irregular edges measuring +/- 6.7 x 10.1 x 13, 3 cm in anteromedial mediastinum which, by contrasting, revealed contrast enhancement (68 HU). The lesion appeared to encase the superior vena cava to the left side which was in the anterior mediastinum. The presence of a mass in the anteromedial mediastinum in Tn. F provided a diagnosis of chylothorax etiology due to malignancy.

After examination of core biopsy and anatomic pathology, microscope observation showed tumors arranged in lobules, consisting of proliferation of anaplastic cells, with rounded nuclei, relatively monotonous, hyperchromatic, narrow cytoplasm, mitosis 6/10 HPF, including visible connective tissue fibrous with lymphocyte infiltration. Tumors grew invasively among the fibrous connective tissue stroma, suggesting mediastinal seminomas.

In mediastinal tumors, serum tumor markers examined are Fetoprotein (AFP), HCG and Lactate Dehydrogenase (LDH). Seminoma never secretes AFP. If there is an increase in AFP levels, the tumor must be classified as a non-seminoma germ cell tumor (NSGCT)

(Friedlander et al 2014). Examination of tumor markers in Mr. F showed AFP 3.8 (normal), LDH 551 (increased), and beta-HCG 12.49 (increased). The results of the tumor marker examination indicated seminoma.

IHC examination is needed to differ mediastinal seminomas from other types of mediastinal tumors. CD45 (leukocyte common antigen) is a receptor-linked protein tyrosine phosphatase expressed in all leukocytes. Positive CD-45 examination is seen in 97% of B cells and in 90% of T cell lymphomas (Alikhan et al. 2016, Al Shaarani et al. 2019, King & Lam. 2020). CD117 (C-KIT) is a glycoprotein transmembrane that functions for the development and defense of germ cells. C-KIT is an IHC tumor marker to differentiate extragonadal seminomas from embryonal carcinoma. C-KIT tests were positive in 98% of those examined for seminomas (Nakagawa et al. 2005, Kriegsmann et al. 2015).

Placental Alkaline Phosphatase (PLAP) is a collection of 4 isoenzymes from the liver, bones, placenta and digestive tract. These isozymes are also produced by seminomas. PLAP examination can differ germ cell tumors, including seminoma or nonseminoma germ cell types. On histopathological examination, yolk sac tumor and seminoma have most similar profile (Yao et al. 2012). To differ yolk sac tumor from seminoma, cytokeratin (CK) examination is used. CK examination will be positive for all preparations of yolk sac tumor, while in seminoma, it will be positive in 43% of all examinations (Cheville et al. 2000).

IHC examination results in Mr. F showed positive CD117 on tumor membrane, negative CD45 in tumor cells, positive in mature lymphocytes, positive PLAP in tumor cell cytoplasm, and negative CK in tumor cells. In conclusion, the tumor in the patient was a germ cell tumor of seminoma type.

Determination of the seminoma stage is performed using the American Joint Committee on Cancer (AJCC)

(Table 1). The International Germ Cell Consensus Classification (Table 2) classifies stage III seminomas into good, intermediate and poor risk categories based on clinical factors, including histology, location of primary tumors, metastases, and serum tumor marker levels. Patients with rapid metastatic progression and life-threatening symptoms such as coughing up blood and suspected seminoma should be treated promptly using cisplatin-based chemotherapy, although it has not been diagnosed from histological tissue (Boujelbene et al. 2011, Jameson et al. 2018).

Patients with good prognosis are given chemotherapy in 3 cycles of bleomycin, etoposide, cisplatin (BEP) or 4 cycles of etoposide, cisplatin (EP). Patients at intermediate and poor risk of metastases are given 4 cycles of BEP chemotherapy or 4 cycles of etoposide, ifosfamide, cisplatin (VIP). Maintenance doses and schedules are important to note because dose changes and chemotherapy delays are associated with poor prognosis. Serum marker tumors are important to be examined at the time of management and must be normal during or after treatment. Chemotherapy using cisplatin can cause myelosuppression, nausea, vomiting and hair loss. Cisplatin can cause nephrotoxic, ototoxic and peripheral neuropathy. Bleomycin can cause pulmonary toxicity with an increased risk in patients over 40 years, with kidney damage, smokers, and cumulative use of bleomycin (Boujelbene et al. 2011, Jameson et al. 2018).

Based on the JCC, Mr. F was included in stage 3C seminoma. Based on the International Germ Cell Consensus Classification, the patient was at poor risk. Chemotherapy using BEP regimen had been carried out. After 3 cycles of chemotherapy, an evaluation using a thoracic CT scan without and with contrast was carried out and the results showed that tumor lesions relatively shrank. Side effects of 2<sup>nd</sup> degree chemotherapy include nausea, blackened skin, hair loss and leukopenia. In the course of his disease the patient died with complaints of shortness of breath for 5 days before undergoing the 5th cycle chemotherapy.

Table 1. American Joint Committee on Cancer (AJCC)

Clinical Stage	TNM (UICC/AJCC) Category				Blood tumor markers (S)		
	T	N	M	S	LDH	βHCG (mIU/ml)	AFP (ng/ml)
<b>0</b>	pTis	carcinoma in situ	N0	M0	-	-	-
<b>IA</b>	pT1	Limited to the testis and/or epididym, without lymphatic or vascular invasion, the tumor can infiltrate the tunica albuginea but not the tunica vaginalis	N0	M0	Any S level	Any LDH level	Any βHCG level
<b>IB</b>	pT2	Limited to the testis and/or epididym, without lymphatic or vascular invasion, or spread through the tunica albuginea and invasion of the tunica vaginalis	N0	M0	Any S level	Any LDH level	Any βHCG level
	pT3	Infiltration of the spermatic cord					
	pT4	Infiltration of the scrotal wall					
<b>IIA</b>	Any T stage		N1 (≤ 2 cm)	M0	Any S level	Any LDH level	Any βHCG level
<b>IIB</b>	Any T stage		N1 (> 2 - 5 cm)	M0	Any S level	Any LDH level	Any βHCG level
<b>IIC</b>	Any T stage		N1 (> 5 cm)	M0	Any S level	Any LDH level	Any βHCG level
<b>IIIA/B/C</b>	Any T stage		Any N stage	M1a (non-regional nodes or lung metastasis)	Any S level	Any LDH level	Any βHCG level
<b>IIIC</b>	Any T stage		Any N stage	M1b (other metastasis sites)	Any S level	Any LDH level	Any βHCG level
<b>IIIC</b>		Mediastinal primary tumor	Any N stage	Any M stage	Any S level	Any LDH level	Any βHCG level

Source: Boujelbene et al. (2011).

Table 2. International germ cell consensus classification

Risk Groups	Seminoma	Non Seminoma Germ Cell Tumor
Good	Any primary site; Normal AFP, any HCG, any LDH; Absent non-pulmonary visceral metastasis	Gonadal or retroperitoneal primary site; Absent non-pulmonary visceral metastasis; AFP <1000 ng/ml HCG <5000 mIU/mL LDH < 1.5x upper limit or normal
Intermediate	Any primary site; Normal AFP, any HCG, any LDH; Presence of non-pulmonary visceral metastasis	Gonadal or retroperitoneal primary site; Absent non-pulmonary visceral metastasis; At least one of: AFP 1000 – 10000 ng/mL HCG 5000-50.000 mIU/mL LDH 1.5 – 10 x upper limit or normal
Poor	Unapplicable	Mediastinal primary site; Presence of non-pulmonary visceral metastasis; At least one of: AFP >10000 ng/mL HCG >50000 mIU/mL LDH >10 x upper limit or normal

Source: Jameson et al. (2018)

**CONCLUSION**

A 28-year-old man suffered from chylothorax and primary mediastinal seminoma. The main clinical manifestation of the patient's disease was shortness of breath due to pleural effusion. Results of analysis supported the diagnosis of chylothorax. Examination

was performed to determine the etiology of chylothorax, comprising laboratory tests, measurement of tumor markers, pleural fluid block cells, chest X-ray, and thoracic CT scan with contrast. The results of the examination supported the diagnosis of chylothorax resulting from malignancy.

The establishment of the diagnosis of malignancy was performed by examining chest CT scan with contrast, tumor markers, core biopsy, histopathology and IHC, the results of which supported the diagnosis of mediastinal seminoma. The patient received bleomycin, etoposide and cisplatin chemotherapy for the management of mediastinal seminomas. Therapy evaluation was carried out by clinical and radiological assessment. Radiological evaluation of CT scan after the third BEP chemotherapy cycle showed tumor size shrunk to <30% (partial response). The patient died before undergoing 5<sup>th</sup> cycle chemotherapy.

## REFERENCES

- Al Shaarani M, Shackelford RE, Master SR, et al (2019). Plasmablastic lymphoma, a rare entity in bone marrow with unusual immunophenotype and challenging differential diagnosis. *Case Reports in Hematology* 2010, 1-10.
- Alikhan M, Song JY, Sohani AR, et al (2016). Peripheral T-cell lymphomas of follicular helper T-cell type frequently display an aberrant CD3<sup>-</sup>/dimCD4<sup>+</sup> population by flow cytometry: An important clue to the diagnosis of a Hodgkin lymphoma mimic. *Modern Pathology* 29, 1173-1182.
- Boujelbene N, Cosinschi A, Boujelbene N, et al (2011). Pure seminoma: A review and update. *Radiat Oncol* 6, 1-12.
- Cheville JC, Rao S, Iczkowski KA, et al (2000). Cytokeratin expression in seminoma of the human testis. *Am J Clin Pathol* 113, 582-588.
- Friedlander TW, Ryan CJ, Small EJ, et al. (2014). Testicular cancer: Abelloff's Clinical oncology. Elsevier Ltd, Canada.
- Jameson JL, Kasper DL, Longo LD, et al (2018). Harrison's principles of internal medicine: 20th edition. Mc Graw Hill Education, New York.
- King JF, Lam JT (2020). A practical approach to diagnosis of B-cell lymphomas with diffuse large cell morphology. *Arch Pathol Lab Med* 144, 160-167.
- Kriegsmann M, Muley T, Harms A, et al (2015). Differential diagnostic value of CD5 and CD117 expression in thoracic tumors?: A large scale study of 1465 non-small cell lung cancer cases. *Diagn Pathol* 10, 1-6.
- Light RW, Lee YCG (2016). Pneumothorax, chylothorax, hemothorax and fibrothorax: Sixth edit. Elsevier Inc, Canada.
- Light RW, Lee YCG (2016). Textbook of pleural diseases. CRC Press, Florida.
- Maldonado F, Hawkin F, Daniels C, et al (2009). Pleural fluid characteristic of chylothorax. *Mayo Clin Proc* 84, 129-133.
- McGrath EE, Blades Z, Anderson PB (2010). Chylothorax: Aetiology, diagnosis and therapeutic options. *Respir Med* 104, 1-8.
- Nakagawa K, Matsuno Y, Kunitoh H, et al (2005). Immunohistochemical KIT (CD117) expression in thymic epithelial tumors. *Chest* 128, 140-144.
- Parikh D. Rajesh PB (2018). Chylothorax. Tips tricks thorac surgery. Springer, Switzerland.
- Yao X-D, Hong Y-P, Ye D-W, et al (2012). Primary yolk sac tumor of seminal vesicle: A case report and literature review. *World Journal of Surgical Oncology* 10, 1-5.

# A 28-YEAR-OLD MAN WITH MEDIASTINAL SEMINOMA TREATED WITH BEP

## ORIGINALITY REPORT

17%

SIMILARITY INDEX

14%

INTERNET SOURCES

13%

PUBLICATIONS

0%

STUDENT PAPERS

## PRIMARY SOURCES

1	<a href="http://portal.research.lu.se">portal.research.lu.se</a> Internet Source	2%
2	<a href="http://repository.unair.ac.id">repository.unair.ac.id</a> Internet Source	2%
3	<a href="https://123userdocs.s3-website-eu-west-1.amazonaws.com">123userdocs.s3-website-eu-west-1.amazonaws.com</a> Internet Source	1%
4	Brandon Hayes-Lattin. "Hematopoietic Cell Transplantation in Germ Cell Tumors", Thomas Hematopoietic Cell Transplantation, 12/12/2003 Publication	1%
5	<a href="http://medicopublication.com">medicopublication.com</a> Internet Source	1%
6	<a href="http://www.nature.com">www.nature.com</a> Internet Source	1%
7	<a href="http://journals.uair.arizona.edu">journals.uair.arizona.edu</a> Internet Source	1%



8	"Encyclopedia of Cancer", Springer Science and Business Media LLC, 2011 Publication	1 %
9	turkjphysiotherrehabil.org Internet Source	1 %
10	Oncology, 2006. Publication	1 %
11	S. Baltaci. "P53, bcl-2 and bax immunoreactivity as predictors of response and outcome after chemotherapy for metastatic germ cell testicular tumours", BJU International, 5/2001 Publication	<1 %
12	Yulong Chen, Changyuan Li, Lijun Xu, Hongjing Lin, Youbin Cui, Jean Deslauriers. "Novel Treatment for Chylothorax After Esophagectomy With 50% Glucose Pleurodesis", Annals of Vascular Surgery, 2010 Publication	<1 %
13	coek.info Internet Source	<1 %
14	"Pathology and Biology of Human Germ Cell Tumors", Springer Nature, 2017 Publication	<1 %
15	Douglas E. Eglen, Thomas M. Ulbright. "The Differential Diagnosis of Yolk Sac Tumor and	<1 %

Seminoma: Usefulness of Cytokeratin, Alpha-Fetoprotein, and Alpha-1-Antitrypsin Immunoperoxidase Reactions", American Journal of Clinical Pathology, 1987

Publication

---

16

"Mount Sinai Expert Guides", Wiley, 2019

Publication

---

<1 %

17

Connolly, R.M.. "High-Dose Chemotherapy plus Stem Cell Transplantation in Advanced Germ Cell Cancer: A Review", European Urology, 200907

Publication

---

<1 %

18

Stephenson, Andrew J., and Timothy D. Gilligan. "Neoplasms of the Testis", Campbell-Walsh Urology, 2012.

Publication

---

<1 %

19

[ejechocard.prod-oup.highwire.org](http://ejechocard.prod-oup.highwire.org)

Internet Source

---

<1 %

20

[www.puo.pl](http://www.puo.pl)

Internet Source

---

<1 %

21

Jean-Pierre Droz. "Management of advanced germ-cell tumors of the testis", Nature Clinical Practice Urology, 05/2008

Publication

---

<1 %

Exclude quotes Off

Exclude matches < 10 words

Exclude bibliography On

# A 28-YEAR-OLD MAN WITH MEDIASTINAL SEMINOMA TREATED WITH BEP

---

[GRADEMARK REPORT](#)

---

FINAL GRADE

**/0**

GENERAL COMMENTS

**Instructor**

---

PAGE 1

---

PAGE 2

---

PAGE 3

---

PAGE 4

---

PAGE 5

---

PAGE 6

---