

# MEDIASTINAL NON-HODGKIN'S LYMPHOMA METASTATIC TO RIGHT ATRIUM MIMICKING RIGHT ATRIAL MYXOMA

*by* Laksmi Wulandari

---

**Submission date:** 20-Dec-2022 12:19PM (UTC+0800)

**Submission ID:** 1984853512

**File name:** case\_report\_folia-gemilang.pdf (368.34K)

**Word count:** 3534

**Character count:** 19293

## Case Report

### MEDIASTINAL NON-HODGKIN'S LYMPHOMA METASTATIC TO RIGHT ATRIUM MIMICKING RIGHT ATRIAL MYXOMA

Gemilang Khusnurrohman, <sup>2</sup> Laksmi Wulandari <sup>1B</sup>

Department of Pulmonology and Respiratory Medicine, Faculty of Medicine/Dr. Soetomo General Academic Hospital, Surabaya, Indonesia

#### ABSTRACT

In this case report, the anatomical pathology results in the form of B cell type LNH, but at the age of 36 years and the risk factor in this patient was a former <sup>6</sup> active smoker. In the anatomical pathology results, the results of the B-High Grade Cell Type LNH were also obtained. B-cell type <sup>6</sup> non-hodgkin's lymphoma can be mutated in the MYC gene (v-myc avian myelocytomatosis viral oncogene homolog) and the BCL-2 and BCL-6 (B-cell lymphoma) genes. If this morphology is found, then the patient's prognosis is poor. Most of these patients were males and the incidence was in the mediastinal area. Mediastinal NHL could develop and enlarge to involve the heart and pericardium. The spread could occur directly and lymphogens. These metastatic tumors were often misdiagnosed with atrial myxoma. In this case report, exploration of the right atrium and open mediastinal biopsy was performed. An open biopsy of the mediastinum revealed a mediastinal mass that enlarged to enter the right atrium. Atrial myxoma was not found. Primary lymphoma growth could also occur in the heart. This condition was called primary cardiac lymphoid (PCL). This case was very rare and was often considered an atrial myxoma. The patient died 10 days after discharge from the hospital. While the patient was eating, the patient had a seizure and the patient was immediately taken to the emergency department of Dr. Soetomo General Academic Hospital, Surabaya, and entered the ER (Resuscitation) ER room, but the patient died after being assisted for approximately two hours. Most likely the cause of the patient's death was a thromboembolic tumor in the right atrium that was released, so that it entered the bloodstream of the brain, causing the patient to have seizures. It was suspected that the cause of the patient's death was the presence of a tumor thrombus that separated into an embolism from the right atrium due to the large size of the tumor. Patients suffering from high-rate NHL had a greater percentage of suffering from tumor thromboembolism as many as 10.6% compared to the Low type and Hodgkins lymphoma (LH) (5.8% and 7.25%).

**Keywords:** Mediastinal tumor; non-hodgkin's lymphoma; atrial myxoma; health risk

#### ABSTRAK

Pada laporan kasus ini, didapatkan hasil patologi anatomi berupa LNH tipe Sel B, namun pada usia 36 tahun dan faktor resiko pada pasien ini merupakan mantan perokok aktif. Pada hasil patologi anatomi juga didapatkan hasil LNH tipe Sel B-High Grade. Limfoma non-Hodgkins tipe sel-B dapat bermutasi pada gen MYC (v-myc avian myelocytomatosis viral oncogene homolog) dan gen BCL-2 dan BCL-6 (B-cell lymphoma). Jika ditemukan morfologi seperti ini, maka prognostik pasien tersebut buruk. Kebanyakan pasien ini merupakan laki-laki dan kejadiannya di daerah mediastinum. LNH Mediastinum dapat berkembang dan bertambah besar, lalu masuk ke bagian dalam jantung bahkan pericardium. Penyebarannya dapat secara langsung atau limfogen. Tumor metastatik ini sering salah diagnosis dengan atrial miksoma. Pada laporan kasus ini, dilakukan eksplorasi biopsy terbuka pada atrium kanan. Didapatkan tumor mediastinum yang menyebar hingga ke atrium kanan, tidak didapatkan atrial miksoma. Limfoma primer juga dapat terjadi langsung di dalam jantung. Kondisi langka ini disebut dengan limfoid Kardiak Pimer, yang sangat jarang bahkan sering salah didiagnosa sebagai atrial miksoma. Pasien meninggal 10 hari setelah keluar rumah sakit. Pada saat pasien sedang makan, pasien mengalami kejang, lalu pasien segera diantar ke IGD RSUD Dr. Soetomo Surabaya, dan masuk ruang RES (Resusitasi) IGD, namun pasien meninggal setelah dilakukan pertolongan selama kurang lebih dua jam. Kemungkinan besar yang menyebabkan pasien meninggal ialah tumor tromboemboli pada bagian atrium kanan yang lepas, sehingga masuk ke dalam aliran darah otak, dan membuat pasien kejang. Diduga penyebab kematian pasien ialah adanya tumor trombus yang lepas menjadi emboli dari atrium kanan yang disebabkan oleh besarnya ukuran tumor. Pasien yang menderita LNH tipe High Rate memiliki persentase lebih besar untuk menderita tromboemboli tumor, yaitu sebesar 10,6% dibanding tipe Low dan Limfoma Hodgkins (LH) (5,8% dan 7,25%).

**Kata kunci:** tumor mediastinum; limfoma non-hodgkin; miksoma atrium; risiko kesehatan

**Correspondence:** <sup>2</sup> Laksmi Wulandari, Department of Pulmonology and Respiratory Medicine, Faculty <sup>3</sup> Medicine/Dr. Soetomo General Academic Hospital, Surabaya, Indonesia. Email: laksmigts@yahoo.co.id

pISSN:2355-8393 • eISSN: 2599-056x • doi: 10.20473/fmi.v57i4.21031

• Fol Med Indones. 2021;57:345-350 • Submitted 15 Feb 2021 • Revised 20 Oct 2021 • Accepted 2 Nov 2021  
• Open access under CC-BY-NC-SA license • Available at <https://e-journal.unair.ac.id/FMI/>

## INTRODUCTION

Mediastinum is located in the middle of the thoracic cavity, between the diaphragm, pleural cavity, and thoracic inlet. In general, mediastinum is divided into 3 compartments, namely the anterior, medial, and posterior (Broaddus et al. 2016). Mediastinal tumors that grow in the anterior part are lipoma, liposarcoma, teratoma, lymphoma, and others (Silva et al. 2014). Lymphoma has an incidence of between 10%-20%, both in young adults and the elderly. Based on their histopathology, lymphomas are divided into two kinds, namely Hodgkins lymphoma and non-Hodgkin's lymphoma (NHL) (Broaddus et al. 2016).

In Indonesia, NHL, along with Hodgkin's lymphoma, holds the 6<sup>th</sup> rank of malignancy (National Cancer Prevention Committee 2016). NHL can occur in all parts of body. Mediastinal NHL can develop and enlarge to involve the heart and pericardium. The spread can occur directly and lymphogens, such as spread/metastases usually occur about 20 months after the initial diagnosis. Symptoms that can be experienced by the patients are usually not specific. New symptoms arise when lymphomas grow large, while pericardium effusion has been formed. The usual symptoms are tightness, chest pain, arrhythmias, cardiac tamponade, myocardial ischemia, and right heart failure (Bligh et al. 2017). In some cases, it is difficult to distinguish whether it is a primary tumor in the heart or the presence of tumor development that enters the heart.

This case report discussed a patient with non-Hodgkins lymphoma mediastinal right atrial metastases resembling right atrial myxoma from initial treatment to death. Therefore, the discussion was limited to non-Hodgkin's lymphoma. The patient was not exposed to other substances except cigarettes. The patient was an active smoker for 10 years ago with 10-12 cigarettes per day, for 5 years, and quit. There was no data regarding the patient's infection to date regarding the etiology of infection. This case report also did not include a post-mortem autopsy report, because it was not performed.

## CASE REPORT

A male patient, aged 32 years, came with complaints of intermittent shortness of breath since three months before hospitalization. Cough was rare, and the phlegm was thick white. He had decreased weight and appetite during the past month. Swelling slowly occurred on the face and neck in the last three months. There was no fever, chest pain, and night sweats.

The results of FNAB (Fine Needle Aspiration Biopsy) and Thorax-Guiding CT scan suspected thymoma. The patient had received anti-tuberculosis drugs (ATD) for 3 months, but it did not heal. The patient had a right and left chest fluid collection as many as 1000 mL yellowish liquid for each. The patient smoked approximately 1 pack per day for 5 years and had stopped since 10 years ago. On thoracic examination, the chest wall movement was symmetrical, intercostal space widened bilaterally, and the trachea remained in the middle. A reduction in palpated fremitus was found in lower 2/3 of both hemithoraces, dull in 2/3 of both hemithoraces. The vesicle decreased in 2/3 of both lower hemithoraces. No additional breath sounds were obtained. Non-pitting edema was found on the right and left arm.

Laboratory tests showed an increase in SGPT, direct bilirubin, LDH, and reactive hepatitis-B. BGA (Blood Gas-Analysis) which showed perfectly compensated respiratory alkalosis with mild hypoxemia. Fluid analysis showed pleural exudate. The initial chest x-ray at the hospital for 3 weeks earlier showed a profile of homogeneous opacity in the lower right and left hemithorax, suggesting bilateral pleural effusion (Figure 1).

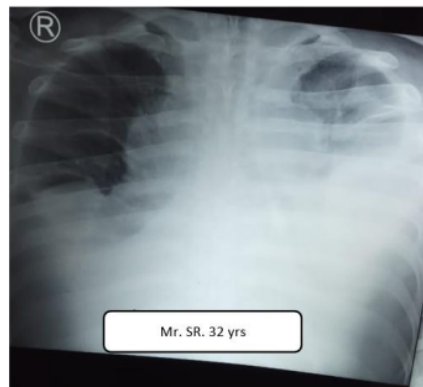


Figure 1. Chest x-ray of homogeneous opacity in lower right and left hemithorax

Contrast thoracic CT examination showed a well-differentiated hypodense lesion measuring about 7.4 x 4.8 cm in the anterior mediastinum attached to and surrounded vascularity entering the left atrium and pleural effusion was found in the right hemithorax (Figure 2).

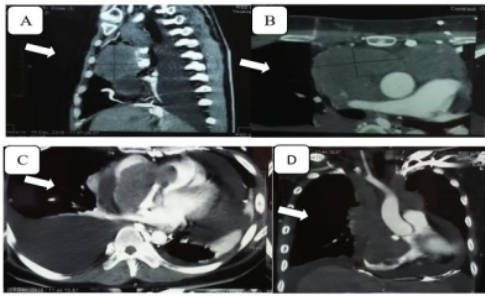
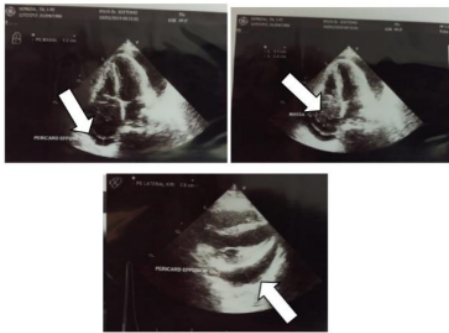


Figure 2. Contrast thoracic CT. A. Sagittal plane. B. Axial plane. C. Pericardial effusion (arrow) D. Suspected thrombus tumor, differential diagnosis of atrial myxoma (arrow)

In radiological evaluation in 3 weeks later, a profile of homogeneous hemithoracic opacity of the left and right hemisphere was obtained, with the one on the left side was more severe. An amount of 900 mL of left pleural fluid was serohemorrhagically evacuated. Tumor marker AFP (beta-fetoprotein) revealed 3.8 ng/mL and CEA (Carcino-embryonic Antigen): 4.63 ng/mL. HCV was non-reactive.

Abdominal USG did not show metastases. Ascites in the pelvic cavity were minimal. During USG-guided core biopsy, we accidentally found a profile of right atrial myxoma. Blood tests showed WBC (White Blood Cell): 21700, neutrophil: 88.8%, SGOT: 51 SGPT: 111, potassium: 2.8 and procalcitonin: 0.09. Echocardiography was performed with the results showing pericardial effusion and mass that filled the atrium, suspected myxoma with a differential diagnosis of atrial thrombus (Figure 3).



**Note:** Pericardial effusion and mass with differential diagnosis of thrombus tumors filled the right atrium, measuring 4.5 cm x 5.4 cm. Pericardial effusion was massive in the left lateral 2.8 cm, and moderate in the basal 1.2 cm

Figure 3. Echocardiography shows pericardial effusion and mass with differential diagnosis of thrombus tumors

Thoracic CT examination showed an anterior mediastinal mass (about 10.9 x 5.1 x 7.6 cm) with 55-9 HU contrast enhancement that infiltrated and filled the right atrium and superior vena cava, right and left brachiocephalic vein to jugular vein, and caused thrombus tumors to fill totally the right atrium, superior vena cava, pericardial effusion (density 12 HU, m<sub>2</sub> thickness 2.9 cm) was present, a single nodule in the anterior segment of the superior lobe of the right lung (size 0.6 cm), and there was a sub-centimeter lymph node at left supraclavicular (about 1.4 cm) and right upper paratracheal (about 1.3 cm). No atelectasis fluid in the right and left pleural cavities, and no lytic processes were found (Figure 4).

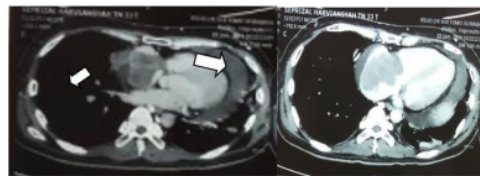


Figure 4. Thoracic CT contrast

FOB (Fiber Optic Bronchoscopy) was performed with the result that no mass was obtained, but narrowing was obtained due to the extraluminal pressure of the main carina and the left main bronchi (Figure 5). The results of BAL (Broncho Alveolar Lavage) examination, brushing cytology, forceps, and biopsy aspiration did not reveal malignant cells.

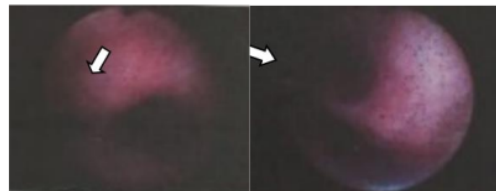

Figure 5. FOB constriction was found due to extraluminal pressure of main carina (left figure) and left main bronchus (right figure)

Open biopsy findings from the mediastinum revealed that the mediastinum mass had enlarged to enter the right atrium. Atrial myxoma was not found. Anatomic pathology (AP) examination showed poorly differentiated carcinoma, non-Hodgkin's lymphoma with IHC (immunohistochemistry) of positive CD45 and negative CK. CD-3 IHC examination revealed negative on the tumor cell membrane, positive on mature T lymphocytes, CD-20: positive on the tumor cell membrane (B-cell), Ki-67: 90% proliferation index. Conclusion: Non-Hodgkin Lymphoma, type-B cells, high-grade. Two months after treatment, the



patient reported a seizure and died at home with the probable cause of death of mediastinal NHL thromboembolism that had spread into the right atrium.

## DISCUSSION

The etiology of NHL is caused by such infections (Epstein-Barr Virus, Burkitt Lymphoma types related HIV, Human Herpes Virus-8, *Helicobacter pylori*) or environmental exposure (herbicides, cigarettes, arsenic, halomethane, asbestos) (Theodore et al. 2019). This patient was a smoker with a Brinkman index of 60. There were no signs of infection.

Primary lymphoma growth can also occur in the heart (Singh et al. 2016). This condition is called primary cardiac lymphoid (PCL). This case is very rare and often considered an atrial myxoma. It was also found that various tumors can metastasize into the heart, ranging from the most common types, such as bronchogenic carcinoma, malignant melanoma, malignant lymphoma, pancreatic carcinoma, and others (Kuriakose et al. 2015, Sweni et al. 2019). These metastatic tumors are often misdiagnosed with atrial myxoma. In this case report, exploration of the right atrium and open mediastinal biopsy was performed. An open biopsy of the mediastinum revealed a mediastinal mass that enlarged to enter the right atrium. Atrial myxoma was not found.

Aging is most likely an important factor in the pathogenesis of B-cells NHL, because this tumor is found mainly in the older age group, and there is an increase in the incidence in each age group over 55 years (Diumenjo et al. 2016). In this case report, anatomical pathology examination showed cell B-type high-grade NHL, but the patient was a 36-year-old with a risk factor of a former active smoker.

In mediastinal NHL, in addition to the manifestations of shortness, systemic complaints were also found, such as body weakness, fever, and weight loss. In addition, there can be superior vena cava syndrome (VCSS), chest pain, hoarseness, and abdominal fluid (ascites) (Mihaljevi et al 2014). In this patient, we found shortness of breath, swelling of the face and neck due to VCSS, and weight loss.

Diagnostic tests included a complete blood examination, clinical chemistry, tumor markers of AFP, LDH, and beta-HCG, continued with examination with core biopsy guided by ultrasound or chest CT scan with contrast. Then, we also examined the anatomy histopathology along with the IHC

(immunohistochemistry) (National Cancer Prevention Committee 2016).

Anatomic histopathology examination of the tissue was done by immunohistochemical (IHC) examination of CD45, CD20, CD3, and Ki67. According to The National Guideline of Medical Service from the National Cancer Prevention Committee in 2016 states that in lymphoma examination, the proliferation rate was considered high if Ki 67 was more than 30%. In this case, IHC examination was carried out with positive CD45, positive CD20, negative CD3, and Ki67 with a 90% proliferation index (high proliferation rate). Ki67 was a patient's prognostic factor, and it was one of the evaluation parameters after Rituximab chemotherapy. The higher the proliferation index, the worse the patient's prognosis (He et al. 2014).

The NHL staging system was used according to Ann Arbor Staging (Table 1) (National Cancer Prevention Committee, Naeim et al. 2018):

Table 1. Ann-arbor staging

Stages	Description
I	Involvement of a single lymphatic site
II	Involvement of two or more lymph node regions on the same side of the diaphragm: II.2: Involvement of two lymph node regions in one side of the diaphragm II.3: Involvement of three lymph node regions in one side of the diaphragm II.E: Non-diffuse/well-defined involvement of one lymph node region in one side of the diaphragm and one side of a single extralymphatic organ
III	Involvement of lymph nodes in both sides of the diaphragm
IV	Diffuse involvement in one or more extralymphatic organs

Stage information is added behind, A or B or C. A: without constitutional symptoms, B: with constitutional symptoms, such as fever, cold sweats, or weight loss of more than 10%, and C: extranodal involvement (National Cancer Prevention Committee 2016, Naeim et al. 2018).

The patient did not undergo full-body lymph node ultrasound and contrast abdominal CT scan. However, the abdominal ultrasound did not show lymph node enlargement. Thoracic CT scan showed a single nodule (0.6 cm) in the anterior segment of the superior lobe of the right lung, and there was sub-centimeter lymph node in the left supraclavicular (1.4 cm) and right upper paratrachea (1.3 cm). According to the Ann-Arbor staging, it indicated that the patient was at stage III (enlarged lymph nodes on both sides of the diaphragm) with constitutional symptoms: B, so that the patient was at stage IIIB.

The patient died 10 days after being discharged. The patient had a seizure. The most likely cause of the patient's death was a thromboembolic tumor detached within the right atrium, so that it entered the bloodstream of the brain, and caused the patient to spasm.

A patient suffering from high-rate type NHL type had a greater percentage of having tumors thromboembolism as much as 10.6%, compared to those with Low and Hodgkin's lymphoma (HL) types (5.8% and 7.25%) (Mohren et al. 2005). In this case report, the suspected cause of death of the patient was the presence of a thrombus tumor which was detached and lead to embolism from the right atrium due to the large size of the tumor, because the location of the LNH was in the atrium. It was very likely that parts of the LNH were released following the atrial movement, so that when it released, it became an embolism, and there was a possibility of clogging the pulmonary blood vessels, coronary arteries in the heart and in the central nervous system. Lekovic et al (2010) state that Compression of Large mediastinal vessels were common in patients with Primary Mediastinal Large B-Cell Lymphoma, predisposing with venous thrombosis. The incidence of this complication is still unknown.

Furthermore, Eltawansy et al (2015) had found that the malignancy had a causal relationship with deep vein thrombosis which can be secondary to the mechanical stress of the tumor on the venous system draining blood from the affected body part or it can be a secondary systemic phenomenon of thrombogenic material released into the circulation from the tumorigenic network. Venous thromboembolism (VTE) is found at autopsy in at least 50% of cancer patients. However, assessment of the true incidence of VTE in cancer patients is difficult, because most patients receive chemotherapy which can trigger VTE. Therefore, this patient was likely to experience thromboembolism too.

## CONCLUSION

A male patient, 32 years old, came with complaints of shortness of breath. A contrast thoracic CT scan showed anteromedial mediastinal tumor and pericardial effusion. Echocardiography showed a suspicion of right atrial myxoma with differential diagnosis of thrombus tumor in the right atrium. Open biopsy showed a suspicion of NHL. IHC revealed CD-3, CD-20 and Ki-67. The patient died of suspected mediastinal NHL thromboembolism that spread in the right atrium, because the location of the LNH was in the atrium. It was very likely that parts of the LNH

were released following the atrial movement, so that when it was released, it had become an embolism, and there would be a possibility of clogging the pulmonary blood vessels and coronary arteries in the heart and in the central nervous system.

## REFERENCES

- Bligh MP, Borgaonkar JN, Burrell SC, et al (2017). Spectrum of CT findings in thoracic extranodal non-hodgkin lymphoma. *Radiographics* 37, 439-461.
- Broadus VC, Mason RJ, Gotway MB (eds) (2016). Murray & Nadel's textbook of respiratory medicine. 6th ed. Elsevier, Canada.
- Diunenjo MC, Abriata G, Forman D, et al (2016). The burden of non-Hodgkin lymphoma in Central and South America. *Cancer Epidemiol* 44, 168-177.
- Eltawansy SA, Rao M, Ceniza S, et al (2015). Mediastinal B-cell lymphoma presenting with jugular subclavian deep vein thrombosis as the first presentation. *Case Report in Vascular Medicine* 2015, 1-5.
- He X, Chen Z, Fu T, et al (2014). Ki-67 is a valuable prognostic predictor of lymphoma but its utility varies in lymphoma subtypes: Evidence from a systematic meta-analysis. *BMC Cancer* 14, 1-13.
- Kuriakose R, Melvani R, Gangadharan V, et al (2015). Right atrial metastatic melanoma with unknown primaries. *Case Reports in Cardiology* 2015, 1-4.
- Lekovic D, Miljic P, Mihaljevic B (2010). Increased risk of venous thromboembolism in patients with primary mediastinal large B-cell lymphoma. *Thrombosis Research* 126, 477-480.
- Mihaljevi B, Jakovi L, Jankovi S (2014). Mediastinal lymphomas - Differential diagnosis. *Mil Pharm Rev* 65, 166-170.
- Mohren M, Markmann I, Jentsch-Ullrich K, et al (2005). Increased risk of thromboembolism in patients with malignant lymphoma: A single-centre analysis. *Br J Cancer* 92, 1349-1351.
- Naeim F, Rao PN, Song S, et al (2018). Atlas of hematopathology: Morphology, immunophenotype, cytogenetics, and molecular approaches. Academic Press, United States.
- National Cancer Prevention Committee (2016). Panduan penatalaksanaan LIMFOMA non-Hodgkin's. Kementerian Kesehatan Republik Indonesia, Jakarta.
- Silva M, Bankier AA, Eisenberg RL (2014). Anterior mediastinal masses. *Am Roentgen Ray Soc* 203, 128-138.
- Singh B, Ip R, Al-Rajjal AI, et al (2016). Primary cardiac lymphoma: Lessons learned from a long survivor. *Case Reports in Cardiology* 2016, 1-5.

Sweni S, Fontana M, Martinez-Naharro a A, et al (2019). Intracardiac melanoma metastases on 18F-FDG PETCT—A case report and review of literature with imaging features. *BJR Case Rep* 5, 1-6.

Vincent T, DeVita Jr, Rosenberg SA, et al (2019). DeVita, Hellman and Rosenberg's cancer: Principles & practice of oncology (cancer principles and practice of oncology) 11th edition. Wolters Kluwer, United States of America.

# MEDIASTINAL NON-HODGKIN'S LYMPHOMA METASTATIC TO RIGHT ATRIUM MIMICKING RIGHT ATRIAL MYXOMA

## ORIGINALITY REPORT

11%

SIMILARITY INDEX

9%

INTERNET SOURCES

8%

PUBLICATIONS

1%

STUDENT PAPERS

## PRIMARY SOURCES

1	<a href="http://www.ncbi.nlm.nih.gov">www.ncbi.nlm.nih.gov</a> Internet Source	3%
2	<a href="http://repository.unair.ac.id">repository.unair.ac.id</a> Internet Source	2%
3	<a href="http://repository.wima.ac.id">repository.wima.ac.id</a> Internet Source	2%
4	<a href="http://etheses.whiterose.ac.uk">etheses.whiterose.ac.uk</a> Internet Source	1%
5	"Pediatric Lymphomas", Springer Science and Business Media LLC, 2007 Publication	<1%
6	" Aggressive Non - Hodgkin's Lymphomas ", Wiley, 2006 Publication	<1%
7	G FISCHER. "Hematologic Diseases", Anesthesia and Uncommon Diseases, 2006 Publication	<1%
8	Danijela Lekovic, Predrag Miljic, Biljana Mihaljevic. "Increased risk of venous	<1%



# thromboembolism in patients with primary mediastinal large B-cell lymphoma", Thrombosis Research, 2010

Publication

9

docksci.com

Internet Source

<1 %

10

www.cureus.com

Internet Source

<1 %

Exclude quotes Off

Exclude matches < 10 words

Exclude bibliography On

# MEDIASTINAL NON-HODGKIN'S LYMPHOMA METASTATIC TO RIGHT ATRIUM MIMICKING RIGHT ATRIAL MYXOMA

---

GRADEMARK REPORT

---

FINAL GRADE

**/0**

GENERAL COMMENTS

**Instructor**

---

PAGE 1

---

PAGE 2

---

PAGE 3

---

PAGE 4

---

PAGE 5

---

PAGE 6

---