



## Experimental Research

## The effect of allogenic freeze-dried platelet-rich plasma in increasing the number of fibroblasts and neovascularization in wound healing



Iswinarno Doso Saputro, Sitti Rizaliyana, Dhitta Aliefia Noverta\*

Department of Plastic Reconstructive and Aesthetic Surgery, Faculty of Medicine Universitas Airlangga / Dr. Soetomo General Academic Hospital, Surabaya, Indonesia

## ARTICLE INFO

## Keywords:

Allogenic freeze-dried platelet-rich plasma (PRP)  
 Full-thickness  
 Number of fibroblasts  
 Number of neovascularization  
 Rabbit  
 Wound healing

## ABSTRACT

**Background:** To evaluate the use of allogenic freeze-dry PRP for the full-thickness wound healing process in experimental animals (rabbits).

**Material and methods:** This study is an experimental research using the posttest-only design, a simple randomized design. Thirty rabbits were randomly divided into six groups (three control groups and three treatment groups), and each group consisted of five subjects. Skin-thick cuts were made on the back of each rabbit. Wounds in the control group were treated using a paraffin gauze, and allogenic freeze-dried PRP was given to the treatment group; observations were made on the 3rd, 9th, and 14th days. The *t*-test on two random samples and Mann-Whitney were used to process data. The results were significant at  $p < 0.05$ .

**Results:** There were significant differences in the average number of fibroblasts the control groups and the treatment groups on day 3 ( $p = 0.009$ ), day 9 ( $p = 0.023$ ), and day 14 ( $p < 0.001$ ). There were also major differences in the average amount of neovascularization between the control group and the treatment group on day 3 ( $p = 0.034$ ), day 9 ( $p < 0.001$ ), and day 14 ( $p < 0.001$ ).

**Conclusions:** The application of allogenic freeze-dried PRP was confirmed to be able to increase the number of fibroblasts and neovascularization in the full-thickness wound healing process in rabbits.

## 1. Introduction

Wounds are problems often encountered by every doctor, whether injuries caused by trauma, systemic disorders, or those made by doctors during surgery. Wounds can be defined as integral damages to the skin or a break in the continuity of a tissue [1]. The process of wound healing occurs through the phases of hemostasis, inflammation, proliferation, and remodeling that begin immediately after the onset of the lesion. Wounds that fail to heal according to these phases, will cause more aesthetically displeasing scar tissue than wound that heal within this timeframe and can lead to function impairment [1]. More than 6 million people per year in the United States experience wounds that do not heal and spent approximately USD 25 billion in health costs in 2012 [2]. Modern wound treatment has experienced very rapid development in the medical world, notably in the last two decades because of advances in health technology and various new innovations to accelerate wound healing. One of the most promising and developing modern dressing alternatives is a dressing product containing platelet-rich plasma (PRP).

Platelets play important roles in the wound healing process by releasing inflammatory mediators and acting as natural sources of growth factors. In the wound healing process, growth factors such as the platelet-derived growth factor (PDGF) and transforming growth factor beta 1 (TGF- $\beta$ 1) will encourage fibroblasts to proliferate, migrate, and increase the formation of an extracellular matrix and stimulate cells to create new blood vessels [3,4]. PRP is plasma that contains up to 140,000–400,000/ $\mu$ l concentrated platelets and is obtained from the isolation of whole-blood centrifugation results [5]. Large, standardized, safe, and affordable sources of PRP are available in blood transfusion units. Platelets produced by the transfusion units have an age limit of 3–7 days, after which the platelets could no longer be used; therefore, many platelet units are wasted every year. In some case studies in several hospitals, the percentage of wasted platelets ranges from 2% to 38% of the total platelet production [6]. These wasted platelet units should be managed as PRP allogenic sources for tissue regeneration therapy [5].

Currently, the platelets for clinical applications originate from patients themselves (they are autologous). These autologous products can eliminate concerns about immunological reactions and disease

\* Corresponding author. Department of Plastic Reconstructive and Aesthetic Surgery, Faculty of Medicine Universitas Airlangga, Jl. Mayjen. Prof. Dr. Moestopo 4–6, Surabaya, 60132, Indonesia.

E-mail address: [drdhitta07@yahoo.co.id](mailto:drdhitta07@yahoo.co.id) (D.A. Noverta).

<https://doi.org/10.1016/j.amsu.2021.103217>

Received 20 October 2021; Received in revised form 24 December 2021; Accepted 24 December 2021

Available online 3 January 2022

2049-0801/© 2022 The Authors. Published by Elsevier Ltd on behalf of IJS Publishing Group Ltd. This is an open access article under the CC BY-NC-ND license

(<http://creativecommons.org/licenses/by-nc-nd/4.0/>).

transmission. However, autologous therapy cannot be performed in patients who have deficiency or abnormal platelet function. Some patients also do not have the courage to have large amounts of blood drawn. Therefore, the application of allogenic (derived from other individuals in one species) PRP is required as an alternative to growth factor therapy [5].

One among the methods of utilizing allogenic PRP in the Tissue Bank Installation is the freeze-drying technique. This method has advantages, the drying process does not use high temperature; therefore, it is best applied for substances that are susceptible to heat. Various growth factors contained in platelets are protein molecules that are susceptible to high temperature, so its application is considered appropriate for processing allogenic PRP products. Then the freezing process could damage the structure of immunoglobulin protein molecules and antigens found on the surface of the platelet membrane [7]. Thus, freeze-drying technique is expected to not increase the immunological risk but also maintain the content of the growth factor in PRP, which plays important roles in the wound healing process [5].

For a Reconstructive and Aesthetic Plastic Surgeon, problems and treatment of wounds are paramount to be studied. Based on the mentioned backgrounds, the researcher intends to evaluate the effectiveness of allogenic freeze-dried PRP application on the wound healing process in experimental animals (rabbits).

## 2. Material and methods

### 2.1. Research design

This study is an experimental research with a posttest-only design, a simple randomized design. The dependent variables are the number of fibroblasts and neovascularization, and the independent variables are the administration of a paraffin gauze and allogenic freeze-dried PRP. This experiment used male New Zealand rabbits (*Oritolagus cuniculus*) aged 9–12 months with a body weight of 2500–3000 gr. Each rabbit was kept in one cage and in one room and was fed the same amount and type of feed. The animals that had been experimented proceeded to cremation. Female rabbits were not used to avoid the influence of progesterone and estrogen hormones on the wound healing process. Estrogen and progesterone would activate macrophages in a different way, resulting in wound healing, angiogenesis, and remodeling [8]. The samples are 30 wounds on the rabbits back calculated using Federer's formula and randomly divided into six groups (three control groups and three treatment groups), and each group consisted of five subjects. The control group is comprised subjects that received treatment using the paraffin gauze and were observed on day 3, day 9, and day 14, whereas the treatment group included the subjects that received treatment using allogenic freeze-dried platelet-rich plasma (PRP) and were observed on day 3, day 9, and day 14. The observation day is according to the phases of wound healing, that the inflammatory phase occurs shortly after the trauma until the 5th day. Meanwhile, the proliferative phase occurs on day 3 to day 21 and the remodeling phase occurs on day 21 to 1 year.

This research was conducted at the Faculty of Veterinary, Universitas Airlangga, Indonesia for treatment of experimental animals and at the Department of Anatomy and Histology, Faculty of Medicine, Universitas Airlangga, Indonesia for collection and evaluation of histological data on wounds.

### 2.2. Preparation of PRP

Allogenic PRP preparations were obtained from blood samples taken from donor rabbits intentionally sacrificed for their blood, added with 0.15 cm<sup>3</sup> of sodium citrate anticoagulant for every 5 cc of whole blood, put in a 5-cc sterile tube, and then centrifuged at 4000 rpm for 10 min to separate plasma and blood cells [9]. The supernatant was removed, and the obtained plasma was centrifuged again at 4000 rpm for 10 min to get PRP [5]. The obtained PRP was frozen in a –83 °C freezer for 12 h and

then put in a lyophilization machine for 8–12 h. This freeze-drying process takes 8–12 h. The freeze-drying process is a drying process with a freezing method and then drying with the sublimation drying technique [10], so that allogenic PRP will be lyophilized. This freeze-drying technique can leave 1% moisture content [5].

### 2.3. Animal experiment

Each rabbit was assigned a number on its leg for identification. Rabbits were sedated using Ketamine of 50 mg/kg body weight and Xylazine of 5 mg/kg body weight intramuscularly until they fell asleep. Each of them received prophylactic antibiotic penicillin procain of 100 mg/kg body weight intramuscularly. Disinfection was done using Povidone Iodine 10% and Savlon 1:30. Then, the rabbits were shaved at their back. Full-thickness 3 × 3 cm wounds were made on the right and left back using the no. 15 scalpel blade. Each full-thickness wound on the right back was treated using a paraffin gauze and covered with a transparent dressing to keep it moist. The full-thickness wound on the left back was treated with allogenic freeze-dried PRP and then closed with a transparent dressing. On treatment day 3, full-thickness wounds on rabbits in the control group and the treatment group were taken for skin biopsy and sacrificed (according to the data collection stage). Full-thickness wounds on rabbits in the control groups on days 9 and 14 and treatment groups on days 9 and 14 received treatment and dead tissue excision every three days using Savlon 1:30 and NaCl 0.9%. The control full-thickness wound on the right back was treated with a paraffin gauze and covered with a transparent dressing, whereas the full-thickness wound on the left back was treated with allogenic freeze-dried PRP and then covered with a transparent dressing. On treatment day 9, the full-thickness wounds on rabbits in the control group and the treatment group were taken for skin biopsy and sacrificed. On treatment day 14, full-thickness wounds on rabbits in the control group and the treatment group were withdrawn for skin biopsy and sacrificed. The sacrifice was performed by injecting Phenobarbital of 60–100 mg/kg of intraperitoneal body weight in the slightly mid-lateral area between processus xyphoideus and tuberculum pubicum.

Specimens were obtained from each wound through excision in the full-thickness scars on the right and left back of the rabbits, each measuring 4 × 4 cm deep in the fascia. Specimens were stored immediately in a 10% formalin solution for tissue fixation and sent for histological examination to the Department of Anatomy and Histology, Faculty of Medicine [11,12].

### 2.4. Fibroblast calculation

The number of fibroblasts was obtained through histopathological examination with Mallory Azan staining, with the characteristic of forming a group with a line parallel to the reddish cytoplasm, between the bluish collagen coir and its density. The number of fibroblasts was calculated manually using the graticule micrometer on a microscope with a 400x magnification.

### 2.5. Neovascularization examination

Neovascularization was observed histologically through Mallory Azan examination by looking at the number of blood vessel lumens. The number of identified lumens was lumen illustrations with the endothelial layer on the wall, and the erythrocyte cells inside the lumens were easily detected.

### 2.6. Statistical analysis

Data were processed using the *t*-test on two random samples and the Mann–Whitney *U* test. The results were significant at *p* < 0.05.

### 3. Results

#### 3.1. Number of fibroblasts

The number of fibroblasts was obtained from the average number of fibroblasts observed on histological preparations with Mallory Azan staining viewed at 400x magnification under a microscope in 10 fields of view. The fibroblasts appeared as cells with a reddish cytoplasm and were located between a bluish collagen coir (Fig. 1).

The average number of fibroblasts in control groups was lower than that in treatment groups, and they were significantly different on days 3 ( $p = 0.009$ ), 9 ( $p = 0.023$ ), and 14 ( $p < 0.001$ ). On day 3, the number of fibroblasts in the control group was  $37.58 \pm 2.90$ , and that in the treatment group was  $45.50 \pm 3.78$ . On day 9, the number of fibroblasts in the control group was  $45.60 \pm 6.74$ , and that in the treatment group was  $56.14 \pm 4.93$ . On day 14, the number of fibroblasts in the control group was  $49.06 \pm 5.84$ , and that in the treatment group was  $74.08 \pm 4.61$ .

#### 3.2. Amount of neovascularization

The number of neovascularization variable was obtained from the average number of blood vessel lumens observed on histological preparations using Mallory Azan staining viewed at 400x magnification under a microscope in 10 fields of view. Neovascularization appears as a lumen with reddish endothelial walls and is accompanied by blood cells clustered in the lumen (Fig. 2).

The average numbers of neovascularization in the control groups were lower than those in treatment groups, and they were significantly different on days 3 ( $p = 0.034$ ), 9 ( $p < 0.001$ ), and 14 ( $p < 0.001$ ). On day 3, the number of neovascularization in the control group was  $18.54 \pm 1.85$ , and that in the treatment group was  $27.60 \pm 7.70$ . On day 9, the number of neovascularization in the control group was  $26.30 \pm 3.13$ , and that in the treatment group was  $44.90 \pm 3.59$ . On day 14, the number of neovascularization in the control group was  $32.96 \pm 1.72$  and the treatment group was  $60.96 \pm 2.18$ .

### 4. Discussion

PRP was selected as the treatment agent since it had demonstrated effective and efficient results in several clinical trials. In this study, the microscopic observations were measured and compared, which were the number of fibroblasts and neovascularization between the control and the treatment groups on days 3, 9, and 14. Fibroblast and neovascularization observations were selected as research parameters because these parameters were considered to be the easiest to process and observe in a simple examination.

In the other studies on PRP, it is stated that activated macrophage cells produce more than 30 types of growth factors and induction of inflammatory factors that cause inflammation faster than normal wound healing [1,13]. In several studies, it is suggested that platelets induce




Fig. 2. Microscopic view of neovascularization lumens. (400x magnification).

macrophages as an activated early inflammatory factor and induce a complex wound healing process [14]. Platelet levels that are three to five times greater than platelet levels, in theory, induce a faster inflammatory process; therefore, the wound healing process will be stimulated faster than ordinary wound healing [14].

The wound healing process begins with an inflammatory phase influenced by the activation of platelets, neutrophils and macrophages, whose levels increase up to 5 or 7 days after the injury. Then, in the proliferation phase, this factor is replaced by growth factors for wound healing cells, including the growth of fibroblasts and new blood vessel (endothelial) cells, and new fibroblasts appear toward the end of the inflammatory phase and the beginning of the proliferation phase [15].

In the Mann-Whitney test in this study, there are significant differences ( $p < 0.05$ ) in the average number of fibroblasts in the control group and that in the treatment group on days 3, 9, and 14 (Table 1). In the treatment group, on day 3, it was discovered that the average number of fibroblasts is close to that in the control group on day 9. Equally, the treatment group on day 9 had a higher average number of fibroblasts than that in the control group on day 14. This suggests that the application of PRP can increase the number of fibroblasts in the wound healing process. This is in accordance with previous theory and research. PRP has high concentrations of several growth factors and factors that can stimulate fibroblast migration, including PDGF, TGF- $\beta$ , epidermal growth factor, and fibronectin. Based on research conducted by Hara et al. [16], PRP can trigger fibroblast proliferation through activation of the extracellular signal regulated kinase (ERK) 1/2. Fibroblasts play a very prominent role in the proliferation phase of wound healing. Fibroblasts synthesize collagen. The formed collagen fibers create the strength by joining the wound edges. During this phase, granulation fills the wound, and keratinocytes migrate to fuse the epithelium [13].

There are significant differences ( $p < 0.05$ ) in the average number of neovascularization in the control group and that in the treatment group on days 3, 9, and 14 (Table 2). In the treatment group, on day 3, it was discovered that the average number of neovascularization was higher than that in the control group on day 9. Similarly, the treatment group had a higher average number of neovascularization on day 9 than that of the control group on day 14. This suggests that the use of PRP can increase the amount of neovascularization in the wound healing process. This is in accordance with previous research. Based on research conducted by Kurita et al. [17] and Hara et al. [16], PRP has a high

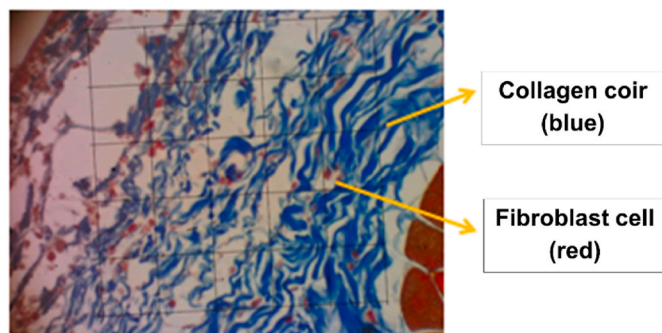


Fig. 1. Microscopic image of fibroblast cells (400x magnification).

Table 1

The average number of fibroblasts in the control and treatment groups on days 3, 9, and 14.

Group	Number of Fibroblasts		
	Day 3	Day 9	Day 14
Control	$37.58 \pm 2.90$	$45.60 \pm 6.74$	$49.06 \pm 5.84$
Treatment	$45.50 \pm 3.78$	$56.14 \pm 4.93$	$74.08 \pm 4.61$
<b>P-value</b>	0.009	0.023	<0.001

**Table 2**

The average number of neovascularization in the control and treatment groups on days 3, 9, and 14.

Group	Number of Neovascularization		
	Day 3	Day 9	Day 14
Control	18.54 ± 1.85	26.30 ± 3.13	32.96 ± 1.72
Treatment	27.60 ± 7.70	44.90 ± 3.59	60.96 ± 2.18
<b>P-value</b>	0.034	<0.001	<0.001

concentration of vascular epidermal growth factor (VEGF), which can regulate the formation of new blood vessels and vascularization by stimulating the proliferation of vascular endothelial cells and increasing vascular permeability. Based on research conducted by Bir et al. [18], PRP can induce angiogenesis because it contains various growth factors, including stromal cell-derived factor 1 $\alpha$  (SDF-1 $\alpha$ ), platelet-derived growth factor BB (PDGF-BB), insulin-like growth factor-1 (IGF-1), VEGF, and basic fibroblast growth factor (bFGF).

The present study proved microscopically that the number of fibroblasts and neovascularization in the administration of PRP has increased compared to that in standardized treatments; this is expected to be evidence regarding the role of PRP in the wound healing process. Research on the safety of using allogenic freeze-dried PRP was previously conducted by Rachmawati, which revealed that there was no inflammatory response and that there was an increase in IgM levels in subjects given allogenic freeze-dried PRP [5]. The study compared the application of autologous with allogenic PRP injected intramuscularly into rabbits.

## 5. Conclusions

The application of allogenic freeze-dried PRP was confirmed to increase the number of fibroblasts and the amount of neovascularization in the full-thickness wound healing process in rabbits. In future research, it is expected that further exploration of the effect of allogenic freeze-dried PRP in wound healing will be continued in humans.

## Limitations of the study

The limitation of this study is that the observation of variables is seen only histologically. We suggest to conduct future research to observe immunohistochemical aspect, which can detect the presence and location of specific proteins to see the expression of growth hormone that accelerates wound healing.

## Funding source

None.

## Ethical approval

This study has been approved by Animal Care and Use Committee (ACUC) of Universitas Airlangga No. 1. KE.203.12.2019.

## Consent

None.

## Author contribution

**Iswinarno Doso Saputro:** Supervision, Conceptualization, Writing-Original draft preparation, Writing- Reviewing and Editing. **Sitti Rizalijana:** Data curation, Writing- Original draft preparation. **Dhitta Aliefia Noverta:** Writing- Original draft preparation, Methodology, Software, data analysis and interpretation.

## Registration of research studies

1. Name of the registry:
2. Unique Identifying number or registration ID:
3. Hyperlink to your specific registration (must be publicly accessible and will be checked):

## Guarantor

Iswinarno Doso Saputro, Sitti Rizalijana, Dhitta Aliefia Noverta

## Declaration of competing interest

The authors report no conflict of interest in this study.

## Acknowledgements

None.

## Appendix A. Supplementary data

Supplementary data to this article can be found online at <https://doi.org/10.1016/j.amsu.2021.103217>.

## References

- [1] D.S. Perdanakusuma, Struktur Kulit Skin Grafting [Skin Structure Skin Graft], Airlangga University Press, Surabaya, Indonesia, 2006.
- [2] K.L. Baquerizo Nole, E. Yim, F. Van Driessche, et al., Wound research funding from alternative sources of federal funds in 2012, *Wound Repair Regen.* 22 (3) (2014) 295–300, <https://doi.org/10.1111/wrr.12175>.
- [3] P. Harrison, D. Keeling, Clinical tests of platelet function, in: A.D. Michelson (Ed.), *Platelets*, second ed., PA: Elsevier, Philadelphia, 2007, pp. 445–466.
- [4] E. Canalis, Clinical review 35: growth factors and their potential clinical value, *J. Clin. Endocrinol. Metab.* 75 (1) (1992) 1–4, <https://doi.org/10.1210/jcem.75.1.1618994>.
- [5] T. Rachmawati, Efek penggunaan allogenic freeze dried platelet rich plasma terhadap respon imunologis kelinci [The effect of using allogenic freeze dried platelet rich plasma on the immunological response of rabbits], in: Master's Thesis. Surabaya, Indonesia, Universitas Airlangga, 2015. Available at: <http://repository.unair.ac.id/39309/>. (Accessed 2 May 2020).
- [6] D.A. Novis, S. Renner, R.C. Friedberg, M.K. Walsh, A.J. Saladino, Quality indicators of fresh frozen plasma and platelet utilization, *Arch. Pathol. Lab Med.* 126 (5) (2002) 527–532, <https://doi.org/10.5858/2002-126-0527-qioffp>.
- [7] Z.Y. Zhang, A.W. Huang, J.J. Fan, K. Wei, D. Jin, B. Chen, G. Pei, The potential use of allogeneic platelet-rich plasma for large bone defect treatment: immunogenicity and defect healing efficacy, *Cell Transplant.* 22 (1) (2013) 175–187.
- [8] C.E. Routley, G.S. Ashcroft, Effect of estrogen and progesterone on macrophage activation during wound healing, *Wound Repair Regen.* 17 (1) (2009) 42–50.
- [9] K. Harmon, R. Hanson, J. Bowen, et al., Guidelines for the Use of Platelet-Rich Plasma. Las Vegas, The International Cellular Medical Society, NV, 2012.
- [10] J.G. Seiler 3rd, J. Johnson, Iliac crest autogenous bone grafting: donor site complications, *J. South Orthop. Assoc.* 9 (2) (2000) 91–97.
- [11] J.A. Kiernan, *Histological and Histochemical Methods: Theory and Practices*, fourth ed., Scion, Bloxham, UK, 2008.
- [12] T. Hardjono, *Buku Ajar Histologi [Histology Textbook]*, Universitas Negeri Yogyakarta, Yogyakarta, Indonesia, 2011.
- [13] G.C. Gurtner, V.W. Wong, Wound healing: normal and abnormal, in: C.H. Thorne, K.C. Chung, A.K. Gosain, G.C. Gurtner, B.J. Mehrara (Eds.), *Grabb and Smith's Plastic Surgery*, seventh ed., Lippincott-William and Wilkins, Philadelphia, PA, 2014, pp. 13–19.
- [14] R.E. Marx, Platelet-rich plasma: evidence to support its use, *J. Oral Maxillofac. Surg.* 62 (4) (2004) 489–496, <https://doi.org/10.1016/j.joms.2003.12.003>.
- [15] C.C. Lima, A.P.C. Pereira, J.R.F. Silva, et al., Ascorbic acid for the healing of skin wounds in rats, *Braz. J. Biol.* 69 (4) (2009) 1195–1201, <https://doi.org/10.1590/s1519-69842009000500026>.
- [16] T. Hara, N. Kakudo, N. Morimoto, T. Ogawa, F. Lai, K. Kusumoto, Platelet-rich plasma stimulates human dermal fibroblast proliferation via a Ras-dependent extracellular signal-regulated kinase 1/2 pathway, *J. Artif. Organs* 19 (4) (2016) 372–377, <https://doi.org/10.1007/s10047-016-0913-x>.
- [17] J. Kurita, M. Miyamoto, Y. Ishii, et al., Enhanced vascularization by controlled release of platelet-rich plasma impregnated in biodegradable gelatin hydrogel, *Ann. Thorac. Surg.* 92 (3) (2011) 837–844, <https://doi.org/10.1016/j.athorasur.2011.04.084>.
- [18] S.C. Bir, J. Esaki, A. Marui, et al., Angiogenic properties of sustained release platelet-rich plasma: characterization in-vitro and in the ischemic hind limb of the mouse, *J. Vasc. Surg.* 50 (4) (2009) 870–879, <https://doi.org/10.1016/j.jvs.2009.06.016>.