



Vascular Endothelial Growth Factor, Epidermal Growth Factor, and Epithelialization Analysis on Full-Thickness Wound Applied with Topical Erythropoietin

Noi Maya Anggrita Sari¹, Iswinarno Doso Saputro*¹, Magda Rosalina Hutagalung¹

Department of Plastic Reconstructive Aesthetic Surgery, Faculty of Medicine, Universitas Airlangga, Dr. Soetomo General Academic Hospital, Surabaya, Indonesia

Abstract

Edited by: Ksenija Bogoeva-Kostovska
Citation: Sari NMA, Saputro ID, Hutagalung MR. Vascular Endothelial Growth Factor, Epidermal Growth Factor, and Epithelialization Analysis on Full-Thickness Wound Applied with Topical Erythropoietin. Open Access Maced J Med Sci. 2022 Feb 15; 10(B):915-919. https://doi.org/10.3889/oamjms.2022.8476
Keywords: Epidermal growth factor; Epithelialization rate; Medical care; Vascular endothelial growth factor; Wound healing
***Correspondence:** Iswinarno Doso Saputro, Department of Plastic Reconstructive Aesthetic Surgery, Faculty of Medicine, Universitas Airlangga - Dr. Soetomo General Academic Hospital, Surabaya, Indonesia. E-mail: noizarkandy@gmail.com
Received: 12-Jan-2022
Revised: 01-Feb-2022
Accepted: 05-Feb-2022
Copyright: © 2022 Noi Maya Anggrita Sari, Iswinarno Doso Saputro, Magda Rosalina Hutagalung
Funding: This research did not receive any financial support
Competing Interests: The authors have no conflicts of interest regarding this investigation.
Open Access: This is an open-access article distributed under the terms of the Creative Commons Attribution-NonCommercial 4.0 International License (CC BY-NC 4.0)

BACKGROUND: Skin wounds are a major challenge, such as full-thickness wounds that need a long time to heal. However, the addition of erythropoietin can accelerate the wound healing process.

AIM: This study was aimed to determine the effect of topical erythropoietin administration on vascular endothelial growth factor (VEGF), epidermal growth factor (EGF), and epithelialization in the wound healing process.

METHODS: This was randomized controlled trial. Full-thickness wounds were created on the back of each white rat. No treatment was administered in the control group (n=16), and topical erythropoietin was applied in the treatment group (n=16). The rats were euthanized on day 3 and day 6 post-surgery, respectively. The expression levels of VEGF, EGF, and microscopic epithelialization rate were examined.

RESULTS: The level of EGF expression in the treatment group increased significantly on day 3 by 2.84 times compared to the control group and on day 6 increased to 4.89 times compared to the control group (p < 0.001). The level of VEGF expression in the treatment group on day 3 increased 2.18 times compared to the control group and on day 6 increased to 2.65 times compared to the control group (p < 0.001). Meanwhile, epithelialization in the treatment group on day 3 increased 1.3 times compared to the control group and on day 6 increased up to 7.62 times compared to the control group (p < 0.001).

CONCLUSION: Topical administration of erythropoietin could increase the expression of VEGF, EGF, and epithelialization in both early inflammatory and proliferative phases.

Introduction

Skin wounds provide a significant challenge to the medical system as well as a significant societal burden in the United States and around the world. Wounds have an impact on nearly 2.5% of the U.S. population's quality of life. They also cost more than \$25 billion each year in the United States and contributes significantly to health-care costs [1], [2]. Skin wounds that have been affected by an underlying illness, such as vasculopathy or diabetes, frequently fail to heal, resulting in persistent ulcers, or full-thickness wounds [3], [4].

The problem with full-thickness wounds is that the exposed structures are frequently dysvascular and blocked. Wound closure must occur in layers and takes a long time [5]. Optimal full-thickness wound management requires thorough knowledge of wound healing principles and practices [6]. The wound healing process can be divided into numerous stages, including direct hemostasis, acute inflammation, proliferation, and maturation. The development of new blood vessels,

known as angiogenesis, is a critical action associated with the proliferative stage [2].

Levi-Montalcini and Cohen found growth factors beginning in 1,500 and agreed that growth factors play a significant function in increasing the process of tissue wound healing [7]. Vascular endothelial growth factor (VEGF) and epidermal growth factor (EGF) are two growth factors that are strongly associated with the angiogenesis process [8]. VEGF promotes angiogenesis, endothelial cell proliferation, and vasculogenesis. EGF works mainly to stimulate the growth of epithelial cells along the wound area as well to fight fibroblasts and smooth muscle cells [9], [10].

In recent years, a growth factor that is undergoing increasing research is erythropoietin. Erythropoietin is a glycoprotein hormone that can stimulate angiogenesis [11]. Various studies have been conducted to prove that the administration of erythropoietin accelerates the speed of wound healing [12], [13], [14]. In 2010, Hamed *et al.* found that topical erythropoietin treatment quadrupled the speed of wound repair in diabetic rats with full-thickness wounds and reduced cell apoptosis [15]. Topical erythropoietin

administration has been found to promote wound healing by increasing skin regeneration and inducing granulation tissue development through neovascularization [16], [17]. However, several of these trials are still limited to diabetes circumstances, and no definitive study on full-thickness wounds has been conducted.

As a result, the purpose of this study was to demonstrate the effect of topical erythropoietin administration on full-thickness wounds of Wistar rats on the levels of VEGF and EGF, as well as epithelialization during the wound healing phase.

Materials and Methods

This study had been approved from the Ethics Committee of Dr. Soetomo General Academic Hospital Surabaya, Indonesia. This was an experimental study with a randomized post-test only control group design. Thirty-six white rats (*Rattus norvegicus*) were randomly assigned into two groups equally. Full-thickness wounds with a size of 2 cm were created on the backs of each white rat. No treatment was administered in the first group as a control group, and topical erythropoietin was applied in the second groups as a treatment group. Each wound from both groups was covered with hydrocolloid dressing as peri-wound management and transparent dressing (Figures 1 and 2). In this study, with effective topical doses varying from 100–600 IU/time [15], [18], [19]. Erythropoietin was applied topically to wounds at 100 IU or around 0.05 mL (1 drop) (Figure 2). The rats will be euthanized on day 3 and day 6 post-surgery. The other nine rats from each group were examined on day 3 (the inflammatory phase) and the other nine rats from each group on day 6 (the proliferation phase). The expression levels of VEGF, EGF, and microscopic epithelialization rate were examined. Variance equality data will be analyzed statistically using SPSS 21 with level at $p = 0.001$.

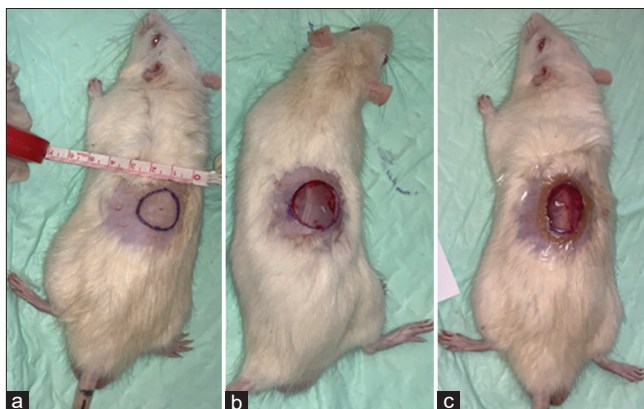


Figure 1: Making wounds on the backs of the control group rats. (a) Size of the wound; (b) full-thickness wound; and (c) closed with hydrocolloid on the margins and transparent dressing over the wound

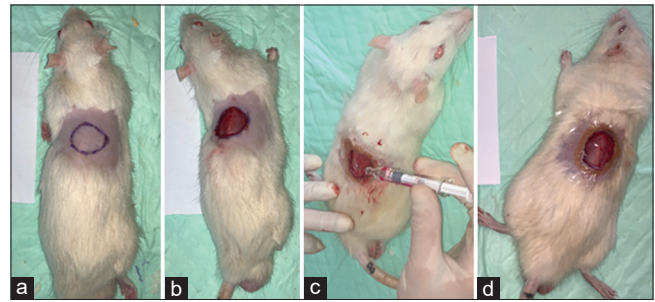


Figure 2: Making wounds on the backs of the treatment group rats. (a) Design and size of the wound; (b) full-thickness wound; (c) topical erythropoietin application; and (d) closed with hydrocolloid on the margins and transparent dressing over the wound

Results

The level of VEGF expression in the treatment group on day 3 increased 2.18 times compared to the control group and on day 6 increased to 2.65 times compared to the control group. There was a significance in the level of VEGF between rats without and with topical erythropoietin ($p < 0.001$; Table 1). From immunohistochemical staining, it can be seen that the amount of VEGF appears to be higher in the treatment group (Figure 3).

Table 1: Level of VEGF among groups from ImageJ Software

Groups	No.	VEGF expression (%) Mean \pm SD	p
1 (a) Control day 3	9	19.48 \pm 4.074	<0.001
1 (b) Control day 6	9	21.74 \pm 7.560	
2 (a) Treatment day 3	9	51.72 \pm 13.692	
2 (b) Treatment day 6	9	47.41 \pm 13.260	

VEGF: Vascular endothelial growth factor.

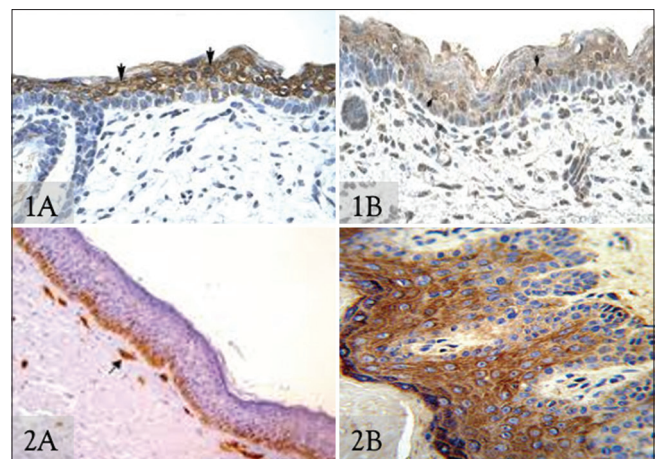


Figure 3: Immunohistochemical staining for vascular endothelial growth factor on each group. (1A) control day 3; (1B) control day 6; (2A) treatment day 3; and (2B) treatment day 6

The level of EGF expression in the treatment group was significantly increased on day 3, increasing 2.84 times compared to the control group, and on day 6, increased to 4.89 times compared to the control group. There was a significant difference in the level of EGF between rats without and with topical erythropoietin ($p < 0.001$; Table 2). From Immunohistochemical staining, it can be seen that the amount of EGF appears to be higher in the treatment group (Figure 4).

Table 2: Level of EGF expression among groups from ImageJ Software

Groups	No.	EGF expression (%) Mean \pm SD	p
1 (a) Control day 3	9	10.22 \pm 2.551	<0.001
1 (b) Control day 6	9	17.72 \pm 4.733	
2 (a) Treatment day 3	9	50.00 \pm 11.927	
2 (b) Treatment day 6	9	50.50 \pm 6.235	

EGF: Epidermal growth factor.

Epithelialization rate in the treatment group on day 3 increased 1.3 times compared to the control group and on day 6 increased up to 7.62 times compared to the control group.

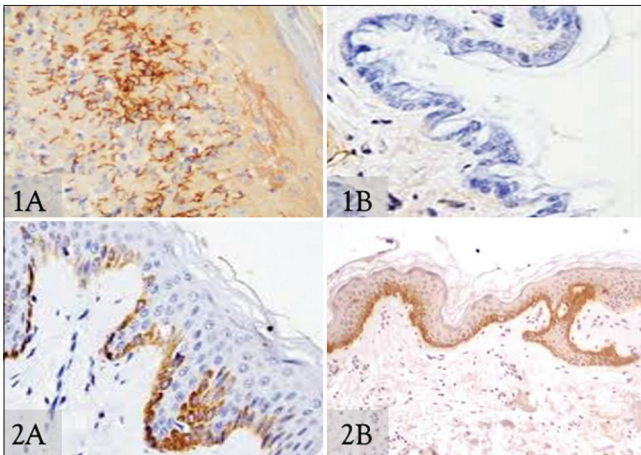


Figure 4: Immunohistochemical staining for epidermal growth factor on each group. (1A) control day 3; (1B) control day 6; (2A) treatment day 3; and (2B) treatment day 6

There was a significant difference in the epithelialization rate between rats without and with topical erythropoietin ($p < 0.001$; Table 3). From immunohistochemical staining, it was seen that the epithelialization rate seemed to increase more in the treatment group (Figure 5).

Discussion

Topical erythropoietin was chosen as the treatment in this study, because it is one of the various non-surgical therapeutic modalities currently available, which means that it has been shown to have a good effect on wound healing. What distinguishes this study from the previous studies is that this study using topical erythropoietin for acute wound healing is the first study in Indonesia to be conducted. The expression levels of VEGF, EGF, and epithelialization were chosen as the research parameters because these parameters are considered to best describe the wound healing process.

Table 3: Epithelialization rate among groups

Groups	No.	Median (Min - Max)	p
1 (a) Control day 3	9	23.9 (13–17.9)	<0.001
1 (b) Control day 6	9	12.9 (12–14.9)	
2 (a) Treatment day 3	9	17.6 (16,618.5)	
2 (b) Treatment day 6	9	98.3 (82,8–145.5)	

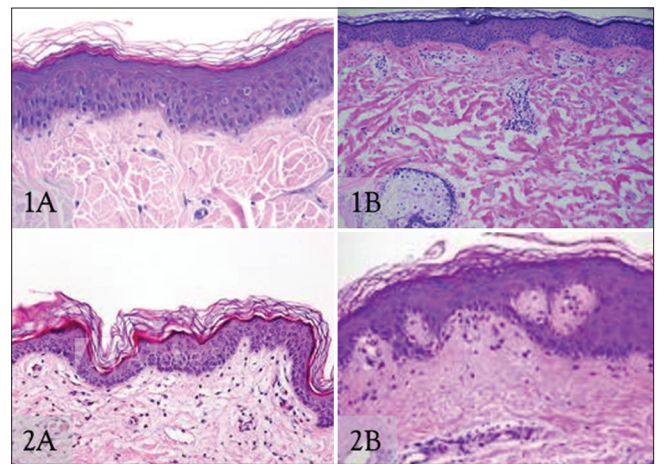


Figure 5: Immunohistochemical staining for epithelialization on each group. (1A) Control day 3; (1B) control day 6; (2A) treatment day 3; and (2B) treatment day 6

Erythropoietin is an angiogenic agent that induces endothelial cells to mitosis. The activation, migration, and proliferation of endothelial cells, as well as the maturation of cell junctions and the surrounding basement membrane, all contribute to the development of new functional capillary structures. VEGF influences each of these phases [14]. Hence, indirectly, giving erythropoietin can trigger the emergence of VEGF. Increased levels of VEGF and EGF in the treatment group on day 6 (representing the beginning of the proliferative phase). In addition to activating cells, it stimulates angiogenesis and endothelial cell proliferation and plays a vital role in vasculogenesis. Epithelial cells grow along the wound area, as well as against fibroblasts and smooth muscle cells [20]. Platelets and macrophages release VEGF in response to tissue injury early in wound healing. Furthermore, hypoxia caused by metabolic dysfunction is a significant inducer of VEGF release into the wound microenvironment. Another clinical trial found that VEGF promotes re-epithelialization of diabetic foot ulcers by increasing blood vessel development [21], [22].

Erythropoietin receptor can also influence and activate macrophages. EGF is a growth factor that is produced by platelets, macrophages, and monocytes [23], [24]. Hence, indirectly, the addition of erythropoietin to the wound can increase the formation of EGF. EGF began to be produced by platelets since the beginning of the inflammatory phase (hemostasis), as evidenced by an increase in EGF levels of more than 2 times on day 3, which was produced by macrophages. Platelets in this phase activate macrophages to start producing other growth factors [25]. This phase overlaps with the proliferative phase and is characterized by increased production of VEGF on day 3 and 6. The levels were not significant on the 6th day. This is because the wound that has undergone epithelial closure or the wound on the subject indicates that the proliferative phase has begun and the remodeling phase has begun [23], [26].

Epithelialization through the wound margin occurs early in the inflammatory phase and rapidly at the end of the proliferative phase [27]. That is evidenced by the significant difference in the number of cells per field of view on days 3 and 6, where on day 6 showed proliferation. The phase has begun to end and the remodeling phase has begun to progress, as reflected by an increase of up to 7.62 times compared to the control. The increase in epithelializing activity on day 6 indicated that topically administered erythropoietin stimulated epithelial mitotic activity in the wound area. Re-epithelialization is regarded as a key component of wound healing. It is critical that epithelialization occurs as soon as feasible after tissue injury and epithelial disruption. The keratinocytes begin migrating into the defect after around 24 h. This occurs as a result of different interactions between cells and the extracellular matrix, as well as various growth factors and cytokines [19].

Full-thickness wounds have their own difficulties in the wound healing process. The wound healing process that must be in layers causes the process to take longer. Combined with some problems that may be encountered during the wound healing process, such as the possibility of infection and the appearance of pus between the layers, so, speeding up the process of closing the wound is one solution [1], [6], [5]. From the results of this study, it can be seen that the addition of erythropoietin for 6 days can accelerate the process of full-thickness wound healing in rats through the process of increasing growth factors such as VEGF and EGF which are correlated with wound epithelialization.

Conclusion

Levels of VEGF, EGF, and epithelialization in full-thickness wounds of rats given topical erythropoietin increased more than those without erythropoietin. These results indicate that topical application of erythropoietin can accelerate the wound healing process, especially in full-thickness wounds. This study is the first study to use topical erythropoietin as a treatment modality for acute full-thickness wound healing in Indonesia. This positive result can be a new hope for patients and medical personnel in accelerating the wound healing process so as to reduce morbidity due to full-thickness wounds.

Acknowledgment

The author is grateful to the Research and Innovation Institute, Universitas Airlangga who has

helped in proofreading the manuscript and improving the Grammarly spelled.

References

1. Sen CK. Human wound and its burden: Updated 2020 compendium of estimates. *Adv Wound Care*. 2021;10:281-92. <https://doi.org/10.1089/wound.2021.0026> PMID:33733885
2. Veith AP, Henderson K, Spencer A, Sligar AD, Baker AB. Therapeutic strategies for enhancing angiogenesis in wound healing. *Adv Drug Deliv Rev*. 2019;146:97-125. <https://doi.org/10.1016/j.addr.2018.09.010> PMID:30267742
3. Fuchs C, Pham L, Henderson J, Stalnaker KJ, Anderson RR, Tam J. Multi-faceted enhancement of full-thickness skin wound healing by treatment with autologous micro skin tissue columns. *Sci Rep*. 2021;11:1-13. <https://doi.org/10.1038/s41598-021-81179-7> PMID:33462350
4. Mahmoudi M, Gould L. Opportunities and challenges of the management of chronic wounds: A multidisciplinary viewpoint. *Chronic Wound Care Manag Res*. 2020;7:27-36. <https://doi.org/10.2147/cwcmr.s260136>
5. Flood M, Weeks B, Anaeme KO, Aguirre H, Hobizal KB, Jiongco SE, *et al*. Treatment of deep full-thickness wounds containing exposed muscle, tendon, and/or bone using a bioactive human skin allograft: A large cohort case series. *Wounds*. 2020;32:164-73. PMID:32804658
6. Rivera AE, Spencer JM. Clinical aspects of full-thickness wound healing. *Clin Dermatol*. 2007;25:39-48. <https://doi.org/10.1016/j.clindermatol.2006.10.001> PMID:17276200
7. Zeliadt N. Rita levi-montalcini: NGF, the prototypical growth factor. *Proc Natl Acad Sci*. 2013;110:4873-6. <https://doi.org/10.1073/pnas.1302413110> PMID:23515326
8. Kumar V, Abbas AK, Aster JC. Robbins & Cotran Pathologic Basis of Disease E-Book. 10th ed. Netherlands: Elsevier Health Sciences; 2020.
9. Brown GL, Curtsinger L 3rd, Brightwell JR, Ackerman DM, Tobin GR, Polk HC Jr., *et al*. Enhancement of epidermal regeneration by biosynthetic epidermal growth factor. *J Exp Med*. 1986;163:1319-24. <https://doi.org/10.1084/jem.163.5.1319> PMID:3486247
10. Epstein JB, Gorsky M, Guglietta A, Le N, Sonis ST. The correlation between epidermal growth factor levels in saliva and the severity of oral mucositis during oropharyngeal radiation therapy. *Cancer*. 2000;89:2258-65. [https://doi.org/10.1002/1097-0142\(20001201\)89:11<2258:aid-cnrc14>3.0.co;2-z](https://doi.org/10.1002/1097-0142(20001201)89:11<2258:aid-cnrc14>3.0.co;2-z) PMID:11147596
11. Elliott S, Sinclair AM. The effect of erythropoietin on normal and neoplastic cells. *Biologics*. 2012;6:163-89. <https://doi.org/10.2147/btt.s32281> PMID:22848149
12. Hamed S, Ullmann Y, Egozi D, Keren A, Daod E, Anis O, *et al*. Topical erythropoietin treatment accelerates the healing of cutaneous burn wounds in diabetic pigs through an aquaporin-3-dependent mechanism. *Diabetes*. 2017;66:2254-65. <https://doi.org/10.2337/db16-1205>

- PMid:28546424
13. Siebert N, Xu W, Grambow E, Zechner D, Vollmar B. Erythropoietin improves skin wound healing and activates the TGF- β signaling pathway. *Lab Invest*. 2011;91:1753-65. <https://doi.org/10.1038/labinvest.2011.125>
PMid:21894148
 14. Toleubayev M, Dmitriyeva M, Kozhakhmetov S, Igissinov N, Turebayev M, Omarbekov A, et al. Regenerative properties of recombinant human erythropoietin in the wound healing. *Open Access Maced J Med Sci*. 2021;9:113-7. <https://doi.org/10.3889/oamjms.2021.5813>
 15. Hamed S, Ullmann Y, Masoud M, Hellou E, Khamaysi Z, Teot L. Topical erythropoietin promotes wound repair in diabetic rats. *J Invest Dermatol*. 2010;130:287-94. <https://doi.org/10.1038/jid.2009.219>
PMid:19626038
 16. Galeano M, Altavilla D, Cucinotta D, Russo GT, Calò M, Bitto A, et al. Recombinant human erythropoietin stimulates angiogenesis and wound healing in the genetically diabetic mouse. *Diabetes*. 2004;53:2509-17. <https://doi.org/10.2337/diabetes.53.9.2509>
PMid:15331568
 17. Galeano M, Altavilla D, Bitto A, Minutoli L, Calò M, Cascio PL, et al. Recombinant human erythropoietin improves angiogenesis and wound healing in experimental burn wounds. *Crit Care Med*. 2006;34:1139-46. <https://doi.org/10.1097/01.ccm.0000206468.18653.ec>
PMid:16484928
 18. Bader A, Lorenz K, Richter A, Scheffler K, Kern L, Ebert S, et al. Interactive role of trauma cytokines and erythropoietin and their therapeutic potential for acute and chronic wounds. *Rejuvenation Res*. 2011;14:57-66. <https://doi.org/10.1089/rej.2010.1050>
PMid:21329452
 19. Yaghobee S, Rouzmeh N, Aslroosta H, Mahmoodi S, Khorsand A, Kharrazifard MJ. Effect of topical erythropoietin (EPO) on palatal wound healing subsequent to free gingival grafting (FGG). *Braz Oral Res*. 2018;32:e55. <https://doi.org/10.1590/1807-3107bor-2018.vol32.0055>
PMid:29898030
 20. Johnson KE, Wilgus TA. Vascular endothelial growth factor and angiogenesis in the regulation of cutaneous wound repair. *Adv Wound Care*. 2014;3:647-61. <https://doi.org/10.1089/wound.2013.0517>
PMid:25302139
 21. Park JW, Hwang SR, Yoon IS. Advanced growth factor delivery systems in wound management and skin regeneration. *Molecules*. 2017;22:1-20. <https://doi.org/10.3390/molecules22081259>
PMid:28749427
 22. Yamakawa S, Hayashida K. Advances in surgical applications of growth factors for wound healing. *Burn Trauma*. 2019;7:1-13. <https://doi.org/10.1186/s41038-019-0148-1>
PMid:30993143
 23. Hong JP, Park SW. The combined effect of recombinant human epidermal growth factor and erythropoietin on full-thickness wound healing in diabetic rat model. *Int Wound J*. 2014;11:373-8. <https://doi.org/10.1111/j.1742-481x.2012.01100.x>
PMid:23078553
 24. Bretz CA, Dlvoky V, Prchal J, Kunz E, Simmons AB, Wang H, et al. Erythropoietin signaling increases choroidal macrophages and cytokine expression, and exacerbates choroidal neovascularization. *Sci Rep*. 2018;8:1-12. <https://doi.org/10.1038/s41598-018-20520-z>
PMid:29391474
 25. Darmono S, Perdanakusuma DS, Nata'atmadja BS. Comparison of the total amount of macrophages on full thickness wound bed in the use of tulle, freeze-dried amnion, and microbial cellulose. *Indian J Forensic Med Toxicol*. 2020;14:1922-7. <https://doi.org/10.37506/ijfmt.v14i2.3218>
 26. Nurmaulinda DS, Budi AS, Zarasade L, Utomo B. Epidermal growth factor (EGF) representing the role of other growth factors contained in platelet-rich plasma (PRP). *Bali Med J*. 2021;10:757-62. <https://doi.org/10.15562/bmj.v10i2.2524>
 27. Pastar I, Stojadinovic O, Yin NC, Ramirez H, Nusbaum AG, Sawaya A, et al. Epithelialization in wound healing: A comprehensive review. *Adv Wound Care (New Rochelle)*. 2014;3:445-64. <https://doi.org/10.1089/wound.2013.0473>
PMid:25032064