

Deviation and Atrophy of Middle Phalanx of Hand Following Partial Separation in Syndactyly Patient Their Fault or Ours

by Diana Murtiati Kusuma

Submission date: 01-May-2021 03:17PM (UTC+0800)

Submission ID: 1575198386

File name: artial_Separation_in_Syndactyly_Patient_Their_Fault_or_Ours.pdf (1.01M)

Word count: 1631

Character count: 8826

Deviation and Atrophy of Middle Phalanx of Hand Following Partial Separation in Syndactyly Patient: Their Fault or Ours?

Diana Murtiati Kusuma^a, Beta Subakti Nata'atmadja^a,
Iswinarno Doso Saputro^{a*}, Sitti Rizaliyana^a

³ ^aDepartment of Plastic Reconstructive and Aesthetic Surgery, Faculty of Medicine Universitas Airlangga

ARTICLE INFO

Keywords:
Deviation
Atrophy
Phalanx
Syndactyly
Separation
Hand
Reconstruction

ABSTRACT

⁵ **Backgrounds:** Syndactyly is failure of differentiation in which the fingers fail to separate into individual appendages. It is the most common congenital hand anomaly, with an incidence of 1 in 2,000 to 2,500 live births. Surgical separation of fingers as early as 6 month-old is indicated when syndactyly involves digits of unequal length (i.e., ring and little fingers). Early separation is also required in complex syndactyly and cases of acrosyndactyly. The timing of surgery of all other cases of syndactyly remains somewhat controversial; most suggest surgical correction before age of 18 months, whereas others prefer to wait until after this age.

Case Presentation and Operation Technique: A 13-year old boy, presented with fusion of all fingers of the right hand at birth. Prior to his current visit, he underwent partial separation of the right fingers at the age of 6 y.o. at a local hospital. Following partial separation, the fingers did not grow normally. Current X-ray showed atrophy and deviation of middle phalanx. We performed separation of syndactyly between index and middle finger, and between fourth and small finger in our hospital. Interdigital webbings are released using local flap and the remaining raw surface is covered using full-thickness skin grafts. On follow up, the patient showed good functional and aesthetic outcome. He is able to write with his right hand with better coordination.

Discussion: Complex syndactyly reconstruction is a challenging surgical problem. Common post surgical findings include rotational deformity, angular deformity, and nail deformity. We describe how we have altered our approach in these findings.

Conclusion: Congenital syndactyly should be corrected early in life. Careful dissection, the use of a dorsal rectangular flap in combination with 2 volar triangular flaps, and use of full thickness skin grafts ensure a satisfactory outcome and minimize the number of operations per web.

Syndactyly is a condition well documented both in textbooks and current literature mainly because it is the most common congenital hand defect.¹

⁶ Coming from the Greek word *syn* (meaning together) and *dactyly* (meaning digits), it describes an embryological failure of finger separation.² Commonly found in some species,

³ * Corresponding author: Iswinarno Doso Saputro - Department of Plastic Reconstructive and Aesthetic Surgery, Faculty of Medicine Universitas Airlangga
Email address: iswinarno@yahoo.com (I. D. Saputro)

including birds and kangaroos, it has a large aesthetic and functional significance for humans born with the condition. It is believed to have a genetic component, and this has been the subject of research over the last decade.¹

Syndactyly is the failure of differentiation in which the fingers fail to separate into individual appendages, usually occurring during the 6-8 weeks of embryologic development. The etiology of syndactyly is approximately 10-60% familial genetic disorder and autosomal dominant. The most common congenital abnormality of the hand is more common in Caucasians with a rate of 1 per 2000-2500 births with male-to-female ratio of 2:1.³

The operative management of this condition has been, aside from conservative approach, the only definitive care for these patients, but new options are becoming available as our understanding of the condition develops.¹

The current mainstay for the treatment and management of syndactyly is surgery. The indications for surgery in general for hand anomalies including syndactyly are: degree of function required by the patient and whether delaying surgery may alter hand function and grip development.⁴

CASE PRESENTATION AND OPERATION TECHNIQUE

A 13-year old boy was admitted, presenting with fusion of all right fingers at birth. There are no other co-morbidities and no

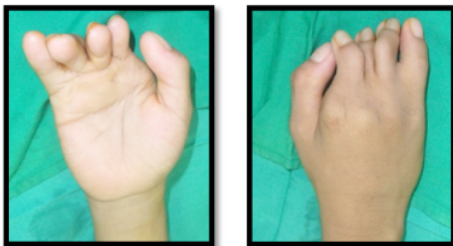


Figure 1. Boy, 13 years old with abnormal growth of right fingers after partial separation

family members suffer from similar anomaly. Prior to his current visit, he underwent partial separation of the right fingers at the age of 6 y.o. at local hospital. Following partial separation, the fingers did not grow normally (Figure 1).

Current X-ray showed atrophy and deviation of the middle phalanx (Figure 4). We report separation between index and middle finger, and between fourth finger and small finger, performed in our hospital (Figure 2).

The dorsal and palmar skin flaps were outlined with a marker before dissection. (Figure. 2). Interdigital webbings are released using local flap.

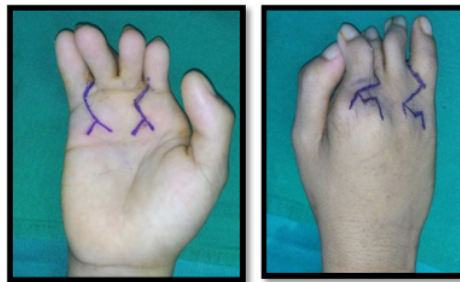


Figure 2. Local flap design for separation of syndactyly

For the reconstruction of first web, the skin flaps were altered. A rectangular flap with a broad base was elevated dorsally, whereas from the volar surface 2 rectangular flaps were elevated. These 2 volar flaps were laterally-based and their proximal side was dissected at the level at which the distal side of the dorsal flap was sutured volarly.⁴

⁸ The remaining raw surface is covered using full-thickness skin grafts. The full thickness skin graft was harvested from inguinal area and the remaining scar is perfectly sutured.

Associated malformations of the involved fingers were corrected during the separation of the digits in the majority of the patient. Priority was given to the separation of the second and fourth web whereas the third web was reconstructed at a later stage. The time interval between the separation of adjacent webs ranged from 3 to 6 months.

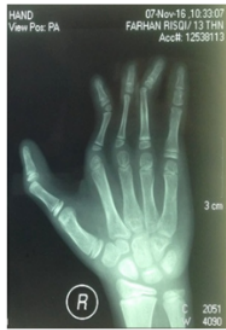

Figure 4. X-ray of the right hand of the patient (after partial separation)

Postoperatively, the hand was immobilized in a bulky dressing. Skin graft was evaluated on the fifth day.

On follow up visits, the patient showed good functional and aesthetic outcome. The functional outcome in hands with multiple syndactylies were impressive. Although the surgery did not return the hand to normal cosmetic appearance, the improvement in function made these hands useful for daily activities. He was able to write with his right hand with better coordination (Figure 5).

DISCUSSION

Complex syndactyly reconstruction is challenging. Syndactyly between digits with different length, such as the thumb and index or the ring and small fingers, should be corrected within the first year of life because the difference of length creates angular and rotational deformity to the longest finger, if left untreated for a long time.¹ In addition, the complex complicated syndactyly should be operated upon early in life to correct the bony and articular deformities and prevent further disturbance of the digital function.²

For psychological reasons, even simple syndactyly should be operated upon before the beginning of school life, that is, before the age of 5 years old.¹

The age of the patient during the separation of the webbed fingers is important and the

basic criteria for the timing of operation are the complexity of the syndactyly as well as the length discrepancy between the involved fingers, especially in complete syndactylies.⁴

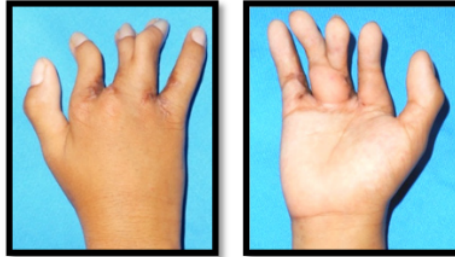

Figure 5. After 3 month full separation between index and middle finger, and between third finger and small finger

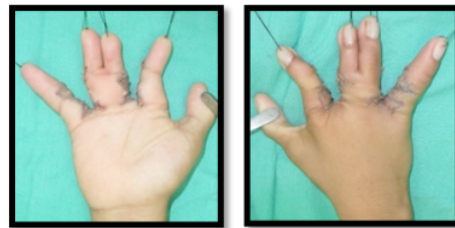


Figure 3. After separation surgery between index and middle finger, and between third finger and small finger

Common post surgical findings include rotational deformity, angular deformity and nail deformity. On deformity, finger is typically rotated away from and deviated toward the site of the previous complex syndactyly. We describe how we have altered our approach on these findings.

The patients who had complex complete syndactyly in digits of unequal length and came late for reconstruction, needed more surgeries to reach satisfactory results compared to patients that came early and correction of the syndactyly was done simultaneously with the correction of the skeletal deformities.⁵

In addition, the function of these digits were limited and remained so in cases of late correction. In some cases of complete

syndactyly with a common nail, a minor rotational deformity of the distal phalanx of the longer digit was present in late follow-up visits. This could be explained either as natural evolution of the bone and soft tissue of the digits with syndactyly or by the pull of pigmented skin graft, which cannot follow the growth of the digit.³

CONCLUSION

In conclusion, congenital syndactyly should be corrected early in life, taking into consideration the basic principles of web reconstruction and simultaneous correction of the skeletal deformities that might coexist.⁶ Careful dissection using loupe magnification, the use of a dorsal rectangular flap in combination with 2 volar triangular flaps, and use of full thickness skin grafts ensure a satisfactory outcome and minimize the number of operations per web.⁴

REFERENCES

1. Jordan D, Hindocha S, Dhital M, Saleh M, Khan W. The epidemiology, genetics and future management of syndactyly. *Open Orthop J* [Internet]. 2012;6:14-27. Available from: <http://www.ncbi.nlm.nih.gov/pmc/articles/PMC3308320/>
2. Upton J. Management of Disorders of Separation - Syndactyly. In: Mathes SJ, Hentz VR, editors. *Plastic Surgery*. 2nd Editio. Saunders; 2005. p. 139-84.
3. Havlik RJ. Common Congenital Hand Anomalies. In: Thorne CH, Chung KC, Gosain AK, Gurtner GC, Mehrara BJ, Rubin JP, et al., editors. *Grabb and Smith's Plastic Surgery*. 7th Editio. Philadelphia: Lippincott Williams & Wilkins; 2014. p. 890-9.
4. Vekris MD, Lykissas MG, Soucacos PN, Korompilias A V., Beris AE. Congenital syndactyly: Outcome of surgical treatment in 131 webs. *Tech Hand Up Extrem Surg*. 2010;14(1):2-7.
5. Miura T, Nakamura R, Suzuki M, Watanabe K. Cleft Hand, Syndactyly, and Hypoplastic Thumb. *J Hand Surg Am*. 1992;17B(3):365-70.
6. Burke F, McGrouther D, Smith P. *Principles of Hand Surgery*. New York: Churcill-Livingstone; 1990.

Deviation and Atrophy of Middle Phalanx of Hand Following Partial Separation in Syndactyly Patient Their Fault or Ours

ORIGINALITY REPORT

12%

SIMILARITY INDEX

7%

INTERNET SOURCES

8%

PUBLICATIONS

0%

STUDENT PAPERS

PRIMARY SOURCES

1	"European Surgical Orthopaedics and Traumatology", Springer Science and Business Media LLC, 2014 Publication	3%
2	emedicine.qa01.medscape.com Internet Source	2%
3	jprjournal.com Internet Source	2%
4	journals.sagepub.com Internet Source	1%
5	F. Mády. "Ankle and Foot", Color Atlas of Clinical Orthopedics, 2009 Publication	1%
6	www.ncbi.nlm.nih.gov Internet Source	1%
7	"Congenital Anomalies of the Upper Extremity", Springer Science and Business Media LLC, 2015 Publication	1%

8

dl.umsu.ac.ir

Internet Source

1 %

9

European Surgical Orthopaedics and
Traumatology, 2014.

Publication

<1 %

10

Yakup Cil. "Distally based venous flap: a new
technique for the correction of syndactyly
without skin graft in adult patients",
MUSCULOSKELETAL SURGERY, 10/30/2009

Publication

<1 %

11

M Le Hanneur, A Cambon-Binder, M. Bachy, F.
Fitoussi. "Treatment of congenital syndactyly",
Hand Surgery and Rehabilitation, 2020

Publication

<1 %

Exclude quotes On

Exclude matches Off

Exclude bibliography On

Deviation and Atrophy of Middle Phalanx of Hand Following Partial Separation in Syndactyly Patient Their Fault or Ours

GRADEMARK REPORT

FINAL GRADE

/100

GENERAL COMMENTS

Instructor

PAGE 1

PAGE 2

PAGE 3

PAGE 4
