

04. Guideline for the diagnosis, treatment and long-term management of cutaneous lupus erythematosus-4

by Qianjin Lu

Submission date: 18-May-2022 04:05PM (UTC+0800)

Submission ID: 1838960865

File name: and_long-term_management_of_cutaneous_lupus_erythematosus-4.pdf (4.51M)


Word count: 16762

Character count: 94327



ELSEVIER

Journal of Autoimmunity

journal homepage: www.elsevier.com/locate/jautimm

Guideline for the diagnosis, treatment and long-term management of cutaneous lupus erythematosus

Qianjin Lu^{a,b,*}, Hai Long^{c,**}, Steven Chow^d, Syarief Hidayat^e, Retno Danarti^f, Yulianto Listiawan^g, Danqi Deng^h, Qing Guoⁱ, Hong Fang^j, Juan Tao^k, Ming Zhao^c, Leihong Xiang^l, Nan Che^m, Fen Liⁿ, Hongjun Zhao^o, Chak Sing Lau^p, Fong Cheng Ip^q, King Man Ho^r, Arnelfa C. Paliza^s, Chan Vicheth^t, Kiran Godse^u, Soyun Cho^v, Chew Swee Seow^w, Yoshiki Miyachi^x, Tran Hau Khang^y, Rataporn Ungpakorn^z, Hassan Galadari^{aa}, Rashmikant Shah^{ab}, Kehu Yang^{ac,ad}, Youwen Zhou^{ae}, Carlo Selmi^{af,ag}, Amr H. Sawalha^{ah}, Xuan Zhang^{ai,aj}, Yaolong Chen^{ac,ak,***}, Chrang-Shi Lin^{al,****}

^a Institute of Dermatology, Chinese Academy of Medical Sciences and Peking Union Medical College, Nanjing, China

^b Key Laboratory of Basic and Translational Research on Immune-Mediated Skin Diseases, Chinese Academy of Medical Sciences, Nanjing, China

^c Department of Dermatology, The Second Xiangya Hospital, Central South University, Changsha, China

^d Pantai Hospital, Kuala Lumpur, Malaysia

^e League of ASEAN Dermatologic Societies, Kuala Lumpur, Malaysia

^f Department of Dermatology and Venereology, Gadjah Mada University, Yogyakarta, Indonesia

^g Department of Dermatology and Venereology, Airlangga University, Surabaya, Indonesia

^h Department of Dermatology, The Second Affiliated Hospital of Kunming Medical University, Kunming, China

ⁱ Department of Dermatology, Sun Yat-Sen Memorial Hospital, Sun Yat-Sen University, Guangzhou, China

^j Department of Dermatology, The First Affiliated Hospital, Zhejiang University School of Medicine, Hangzhou, China

^k Department of Dermatology, Union Hospital, Tongji Medical College, Huazhong University of Science and Technology, Wuhan, China

^l Department of Dermatology, Huashan Hospital, Fudan University, Shanghai, China

^m Department of Rheumatology and Immunology, The First Affiliated Hospital of Nanjing Medical University, Nanjing, China

ⁿ Department of Rheumatology and Immunology, The Second Xiangya Hospital, Central South University, Changsha, China

^o Department of Rheumatology and Immunology, Xiangya Hospital, Central South University, Changsha, China

^p Division of Rheumatology and Clinical Immunology, Department of Medicine, Queen Mary Hospital, Hong Kong, China

^q Department of Dermatology, Yung Fung Shee Dermatological Clinic, Hong Kong, China

^r Social Hygiene Service, Department of Health, Hong Kong Government, Hong Kong, China

^s Department of Dermatology, Faculty of Medicine and Surgery, University of Santo Tomas, Manila, Philippines

^t Department of Dermatology, Khmer Soviet Friendship Hospital, Phnom Penh, Cambodia

^u D. Y. Patil University School of Medicine, Nerul, Navi Mumbai, India

^v Department of Dermatology, Seoul National University Boramae Medical Center, Seoul, South Korea

^w National Skin Center, Singapore, Singapore

^x Shizuoka Graduate University of Public Health, Japan

^y National Hospital of Dermatology, Vietnamese Society of Dermatology and Venereology, Hanoi, Viet Nam

^z Skin and Aesthetic Lasers Clinic, Bumrungrad International Hospital, Bangkok, Thailand

^{aa} College of Medicine and Health Sciences, United Arab Emirates University, Al Ain, United Arab Emirates

^{ab} Department of Dermatology, KRS Derma Care, Mumbai, India

^{ac} Evidence-Based Medicine Center, School of Basic Medical Sciences, Lanzhou University, Lanzhou, China

^{ad} Key Laboratory of Evidence Based Medicine and Knowledge Translation of Gansu Province, Lanzhou, China

^{ae} Department of Dermatology and Skin Science, University of British Columbia, Vancouver, BC, Canada

^{af} Rheumatology and Clinical Immunology, Humanitas Clinical and Research Center- IRCCS, Rozzano, Milan, Italy

^{ag} Department of Biomedical Sciences, Humanitas University, Pieve Emanuele, Milan, Italy

31

* Corresponding authors. Institute of Dermatology, Chinese Academy of Medical Sciences and Peking Union Medical College, 12 Jiangwangmiao Street, Xuanwu District, Nanjing, Jiangsu, 210042, China.

** Corresponding author. Department of Dermatology, The Second Xiangya Hospital, Central South University, 139 Middle Renmin Road, Changsha, Hunan, 410011, China.

*** Corresponding authors. Evidence-based Medicine Center, School of Basic Medical Sciences, Lanzhou University, Lanzhou, Gansu, China.

**** Corresponding author. Asian Dermatological Association (ADA).

E-mail addresses: qianlu5860@pumcderm.cams.cn (Q. Lu), dr.hailong@csu.edu.cn (H. Long), chenyaolong@vip.163.com (Y. Chen), linsintaiwan@gmail.com (C.-S. Lin).

<https://doi.org/10.1016/j.jaut.2021.102707>

Received 9 July 2021; Accepted 13 July 2021

Available online 5 August 2021

0896-8411/© 2021 Elsevier Ltd. All rights reserved.

^{a1} Divisions of Rheumatology, Departments of Pediatrics and Medicine & Lupus Center of Excellence, University of Pittsburgh, Pittsburgh, PA, USA

^{a2} Department of Rheumatology, Beijing Hospital, National Center of Gerontology, Chinese Academy of Medical Sciences and Peking Union Medical College, Beijing, China

^{a3} Clinical Immunology Center, Medical Epigenetics Research Center, Chinese Academy of Medical Sciences and Peking Union Medical College, Beijing, China

^{a4} Chinese GRADE Center, Lanzhou University, Lanzhou, China

^{a5} Asian Dermatological Association (ADA)

ARTICLE INFO

Keywords:

Lupus erythematosus (LE)
Consensus
Evidence-based
Pregnancy
Pediatric
Pulsed dye laser (PDL)

ABSTRACT

Cutaneous lupus erythematosus (CLE) is an inflammatory, autoimmune disease encompassing a broad spectrum of subtypes including acute, subacute, chronic and intermittent CLE. Among these, chronic CLE can be further classified into several subclasses of lupus erythematosus (LE) such as discoid LE, verrucous LE, LE profundus, chilblain LE and Blaschko linear LE. To provide all dermatologists and rheumatologists with a practical guideline for the diagnosis, treatment and long-term management of CLE, this evidence- and consensus-based guideline was developed following the checklist established by the international Reporting Items for Practice Guidelines in Healthcare (RIGHT) Working Group and was registered at the International Practice Guideline Registry Platform. With the joint efforts of the Asian Dermatological Association (ADA), the Asian Academy of Dermatology and Venereology (AADV) and the Lupus Erythematosus Research Center of Chinese Society of Dermatology (CSD), a total of 25 dermatologists, 7 rheumatologists, one research scientist on lupus and 2 methodologists, from 16 countries/regions in Asia, America and Europe, participated in the development of this guideline. All recommendations were agreed on by at least 80% of the 32 voting physicians. As a consensus, diagnosis of CLE is mainly based on the evaluation of clinical and histopathological manifestations, with an exclusion of SLE by assessment of systemic involvement. For localized CLE lesions, topical corticosteroids and topical calcineurin inhibitors are first-line treatment. For widespread or severe CLE lesions and (or) cases resistant to topical treatment, systemic treatment including antimalarials and (or) short-term corticosteroids can be added. Notably, antimalarials are the first-line systemic treatment for all types of CLE, and can also be used in pregnant patients and pediatric patients. Second-line choices include thalidomide, retinoids, dapsone and MTX, whereas MMF is third-line treatment. Finally, pulsed-dye laser or surgery can be added as fourth-line treatment for localized, refractory lesions of CLE in cosmetically unacceptable areas, whereas belimumab may be used as fourth-line treatment for widespread CLE lesions in patients with active SLE, or recurrence of ACLE during tapering of corticosteroids. As for management of the disease, patient education and a long-term follow-up are necessary. Disease activity, damage of skin and other organs, quality of life, comorbidities and possible adverse events are suggested to be assessed in every follow-up visit, when appropriate.

53

1. Introduction

Lupus erythematosus is a chronic, inflammatory, autoimmune disease encompassing a broad spectrum of subtypes, which includes systemic lupus erythematosus (SLE) and cutaneous lupus erythematosus (CLE). Whereas SLE generally involves multiple organs and systems, CLE mainly affects skin and mucosa and can be further classified into a couple of distinct subtypes based on their different clinical and histopathological features as well as serological findings. Due to the complexity of classification and low incidence of many subtypes, correct diagnosis of CLE, especially its less common subtypes, is sometimes challenging in clinical practice for dermatologists and other experts treating patients with lupus, such as rheumatologists. Meanwhile, unlike SLE, there has not been any drug or therapeutic intervention licensed for treatment of CLE so far except for hydroxychloroquine. Empirical and “off-label” application of topical and systemic medications are still common in treatment for CLE.

In 2017, a guideline for treatment of CLE has been developed by the European Dermatology Forum in cooperation with the European Academy of Dermatology and Venereology (EADV) [1]. However, the target readers of this guideline are specialists on lupus other than all dermatologists, and how to diagnose CLE and its subtypes has not been mentioned in this guideline. Also in 2017, an Asian recommendation for the management of CLE was compiled based on a comprehensive review of literature by the Asian Academy of Dermatology and Venereology (AADV) [2]. Later in 2019, an updated guideline for diagnosis and treatment of CLE was published in Chinese language by the Center for Lupus Erythematosus Research, Chinese Society of Dermatology (CSD), in which typical clinical pictures of different CLE subtypes were

incorporated for readers to gain a straightforward impression of their manifestations [3]. With clinical progress in recent years, increasingly accumulated new evidence and updated opinions need to be incorporated in the guideline. The aim of the present work is to provide all dermatologists and rheumatologists with a practical guideline for the diagnosis, treatment and long-term management of CLE by incorporating evidence-based recommendations and expert opinions.

2. Methods

On the basis of the “S2k guideline for treatment of cutaneous lupus erythematosus - guided by the European Dermatology Forum (EDF) in cooperation with the European Academy of Dermatology and Venereology (EADV)” and “AADV/Asia recommendation for the management of cutaneous lupus erythematosus”, both published in 2017 [1,2], as well as the “Guideline for diagnosis and treatment of cutaneous lupus erythematosus (2019)” published in Chinese language [3], the authors aimed to develop an updated and more comprehensive guideline for both diagnosis, treatment and long-term management of CLE.

In cooperation with the Asian Dermatological Association (ADA) and AADV, Prof. Qianjin Lu as president of CSD and director of the Center for Lupus Erythematosus Research of CSD, proposed and initiated this work. A total of 25 dermatologists, 7 rheumatologists, one research scientist on lupus and 2 methodologists with expertise on guideline development, from 16 countries/regions in Asia, America and Europe, were nominated as members of the guideline committee during March through June in 2021. Prof. Yaolong Chen, who has long-term experience in the development of guidelines, participated as a methodological advisor. Prof. Hai Long, who had expertise in both clinical practice and clinical trials of CLE and SLE, drafted a preliminary manuscript based on a comprehensive review of literature and was responsible for the collection of comments, suggestions and complementary opinions from all members,

¹ Qianjin Lu and Hai Long contributed equally to this work.

and the organization of discussions on major issues/questions until final completion of the revision.

Due to the limited clinical evidence available for most of therapeutic measures applied for CLE, all participants in the guideline committee agreed to develop this guideline based on both expert consensus and evidence. This guideline took into accounts the checklist established by the international RIGHT (Reporting Items for Practice Guidelines in Healthcare) Working Group [4] and was registered at the International Practice Guideline Registry Platform (<http://www.guidelines-registry.org>, Registration No. IPGRP-2021CN189). Prior to the group discussion, the preliminary draft of the guideline was distributed to each expert in the guideline committee for preview. Comments, suggestions and complementary opinions were collected by the end of June 2021, and further discussions and revisions were made for each part of the guideline including the differential diagnosis (Table 1) and the treatment algorithm (Fig. 1), which included sequentially a presentation of the draft recommendation, the relevant evidence, open discussion, initial voting or revision of the recommendation and final voting, if necessary. As to the discussion, internal and external evidence were taken into account. Voting results for each recommendation were collected. Recommendations passing a 90% agreement or above in votes were regarded as strong consensus, and recommendations with a

Table 1
Differential diagnosis of CLE.

Subtypes of CLE	Differential diagnosis
ACLE	<ul style="list-style-type: none"> • Rosacea • Photosensitive dermatitis • Dermatomyositis • Seborrheic dermatitis • Drug eruption • Pemphigus erythematous
SCLE	<ul style="list-style-type: none"> • Tine corporis • Erythema annulare centrifugum • Psoriasis • Pityriasis rosea • Sweet's syndrome • Secondary syphilis • Erythema multiforme • Granuloma annular
DLE	<ul style="list-style-type: none"> • Polymorphous light eruption • Seborrheic dermatitis • Lupus vulgaris • Actinic keratosis • Sarcoidosis • Morphea (Localized scleroderma) • Lichen planus • Psoriasis • Basal cell carcinoma • Vitiligo • Chronic cheilitis
VLE	<ul style="list-style-type: none"> • Verruca vulgaris • Psoriasis • Dermatofibroma
LEP	<ul style="list-style-type: none"> • Localized scleroderma • Idiopathic lobular panniculitis • Weber-Christian disease • Lymphoma
CHLE	<ul style="list-style-type: none"> • Other cutaneous vasculitis • Chilblain
BLLE	<ul style="list-style-type: none"> • Linear lichen planus • Lichen striatus • Linear psoriasis • Linear scleroderma
TLE	<ul style="list-style-type: none"> • Lymphocytic infiltration of skin • Sweet's syndrome

Abbreviations: ACLE, acute cutaneous lupus erythematosus. SCLE, subacute cutaneous lupus erythematosus. DLE, discoid lupus erythematosus. VLE, verrucous lupus erythematosus. LEP, lupus erythematosus profundus. CHLE, chilblain lupus erythematosus. BLLE, Blaschko linear lupus erythematosus. TLE, tumid lupus erythematosus.

70–89% agreement in votes were regarded as consensus. All recommendations passed with a >80% agreement.

A revised version of the manuscript was disseminated to each participating author for his or her final approval. Each consented recommendation was highlighted in bold and presented using standardized wording as follows:

- “We recommend ...”, referring to a strong positive recommendation;
- “We suggest ...”, referring to a moderate positive recommendation;
- “We cannot make a recommendation with respect to ...”, referring to a difficulty in making a positive or negative recommendation due to conflicting evidence or lack of evidence;
- “We suggest against ...”, referring to a moderate negative recommendation;
- “We recommend against ...”, referring to a strong negative recommendation.

3. Classification of CLE

CLE is classified into four major categories on the basis of clinical manifestations, histopathological features and serological abnormalities: acute CLE (ACLE), subacute CLE (SCLE), chronic CLE (CCLE) and intermittent CLE (ICLE). Among them, ACLE generally presents as a mucocutaneous manifestation, accompanied by other organ or system involvement, in patients with SLE, and some patients present without other organ involvement [5]. Up to 50% of patients with SCLE meet the criteria for SLE, while SCLE patients generally have only mild systemic involvement [6]. An estimated 20% of SCLE patients tend to develop Sjogren's syndrome [7]. CCLE includes several subtypes such as discoid lupus erythematosus (DLE), verrucous lupus erythematosus (VLE), LE profundus (LEP), chilblain LE (CHLE) and Blaschko linear lupus erythematosus (BLLE). ICLE is a special category that specifically refers to tumid lupus erythematosus (TLE), also known as lupus erythematosus tumidus or LET), a most photosensitive subset of LE, which preferentially occurs in sun-exposed areas. For each subtype of CLE, a typical clinical picture of the skin manifestation is presented in Fig. 2.

It is noteworthy that co-existence of CLE with other immune-related disorders such as lichen planus [8], dermatomyositis [9], anti-phospholipid antibody syndrome (APS) [10] or other autoimmune diseases may sometimes occur, which is defined as an overlap syndrome.

4. Diagnosis and clinical assessment of CLE

4.1. Recommendations

- We recommend an exclusion of SLE before making a diagnosis of CLE. (97% consensus)
- We suggest an assessment of disease activity and damage of CLE at baseline before treatment and at each follow-up, when appropriate, during treatment. (97% consensus)

Currently, there are no standardized diagnostic criteria for each subtype of CLE. Diagnosis of CLE should be based on a comprehensive consideration of patient history, clinical manifestations, laboratory tests and skin biopsy. Direct immunofluorescence (DIF) can often be valuable to assist the diagnostic procedures. Differential diagnosis can vary significantly depending on each subtype of CLE, which is summarized in Table 1. In recent years, artificial intelligence-based application platforms in smartphone have been developed to assist the diagnosis and classification of CLE [11,12].

Of note, an exclusion of other organ damage beyond skin lesions is necessary before establishing the diagnosis of CLE, because the skin lesions of ACLE, DLE, VLE or even LEP can be a part of the clinical manifestations in a patient with SLE. A comprehensive evaluation of all organs and systems by history taking and physical examination, detection of serum autoantibodies including anti-nuclear antibody (ANA),

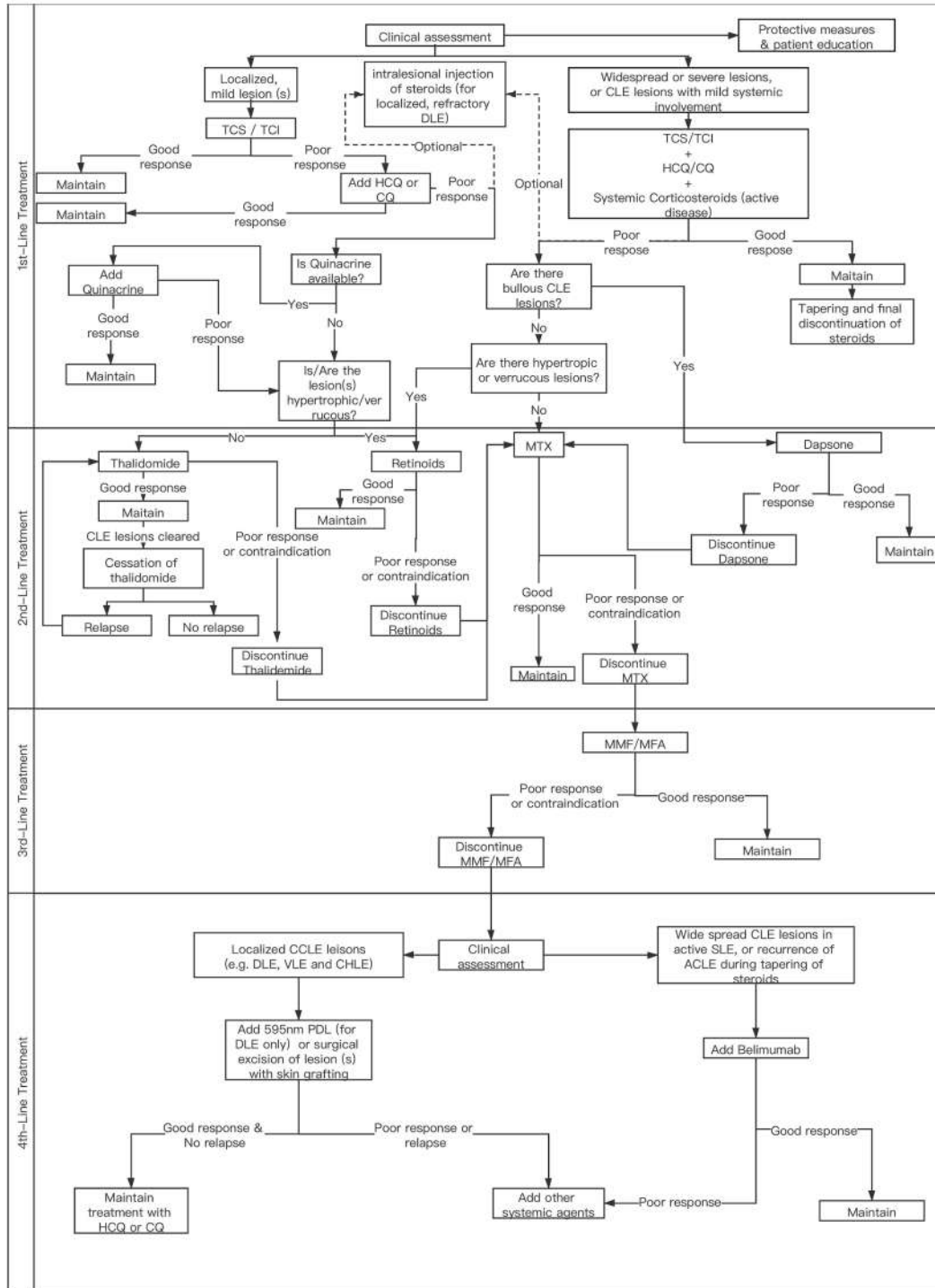


Fig. 1. The recommended algorithm of treatment for CLE. Abbreviations: CLE, cutaneous lupus erythematosus. TCS, topical corticosteroids. TCI, topical calcineurin inhibitors. HCQ, hydroxychloroquine. CQ, chloroquine. MTX, methotrexate. MMF, mycophenolate mofetil. MPA, mycophenolic acid. DLE, discoid lupus erythematosus. VLE, verrucous lupus erythematosus. CHLE, chilblain lupus erythematosus. PDL, pulsed-dye laser.

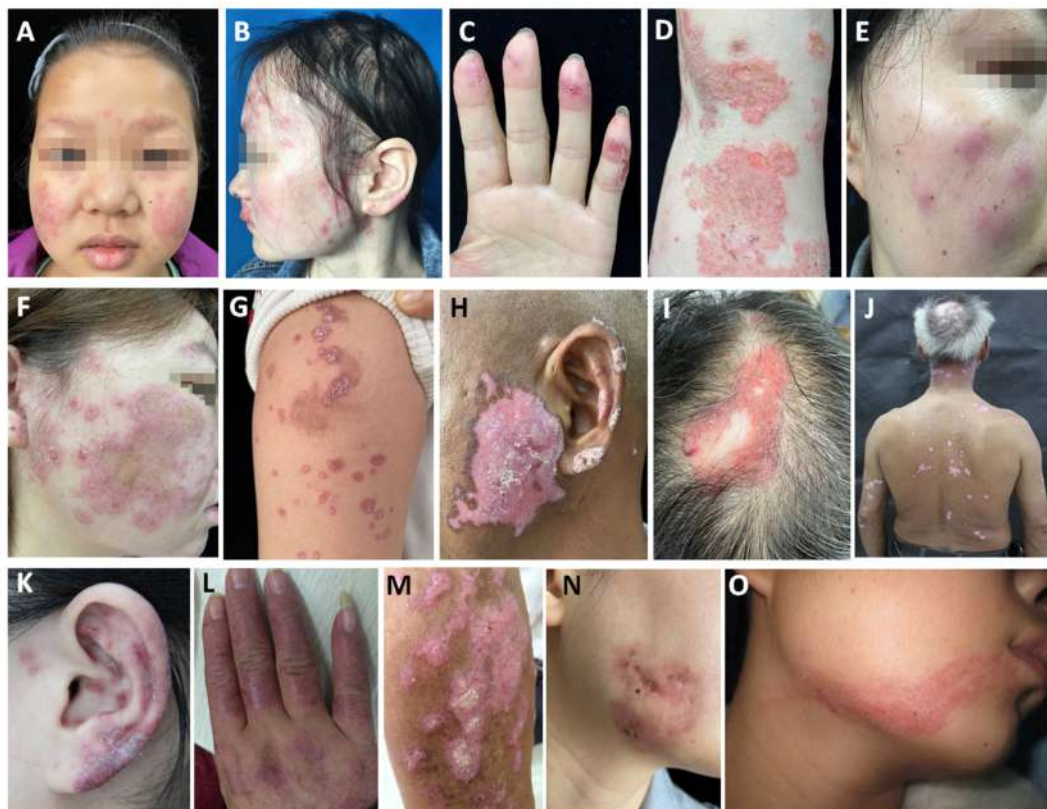

Fig. 2. Representative skin lesions of each subtype of CLE. (A–C) ACLE: typical manifestations of malar rash (“butterfly erythema”), diffuse alopecia and vasculitis of fingers, respectively. (D) BSLE: characterized by blisters and bullae on the erythema, which involve widespread area including the head, neck, trunk and limbs. (E) ICLE (also called LET): discrete, nonscaly, erythematous plaques or nodular skin lesions mainly involving sun-exposed areas (especially the face, the lateral and posterior neck, upper trunk and extensor surfaces of the arms). (F,G) SACLE: the annular subtype (F) and the papulosquamous or psoriasiform subtype (G), respectively, both of which mainly involves the sun-exposed area. (H,I) DLE: discoid erythematous plaques with firmly adherent scales/crusts, central atrophy and scarring, with hypopigmentation and hyperpigmentation, whose predilection sites include the face, auricle, and scalp, respectively. DLE of the scalp often leads to scarring alopecia. (J) DDLE: DLE lesions involving not only the head and neck, but also the trunk and upper limbs. (K,L) CHLE: chilblain-like edematous erythema or puffy nodules that can evolve into central erosion or ulceration sometimes, mainly involving cold-exposed acral areas (fingers, toes, heels, ears and nose). (M) VLE: DLE-like skin lesion(s) characterized by verrucous hyperplasia of the epidermis. (N) LEP: tender, indurated, erythematous plaques or deep nodules that can evolve into ulceration, disfiguring atrophy and scarring. (O) BLLE: a DLE-like, linear plaque of the skin along the Blaschko line. Abbreviations: CLE, cutaneous lupus erythematosus. ACLE, acute CLE. BSLE, bullous systemic lupus erythematosus. ICLE, intermittent CLE. LET, lupus erythematosus tumidus. SACLE, subacute CLE. DLE, discoid lupus erythematosus. DDLE, disseminated DLE. CHLE, chilblain lupus erythematosus. VLE, verrucous lupus erythematosus. LEP, lupus erythematosus profundus. BLLE, Blaschko linear lupus erythematosus.

anti-double strand DNA (dsDNA), anti-Sm and other anti-extractable nuclear antigen antibodies, and laboratory tests of complete blood count, urinalysis, urine protein to creatinine ratio, erythrocyte sedimentation rate and complements 3 and 4, are necessary. A newly identified epigenetic biomarker, IFI44L gene promoter demethylation in whole blood cell samples, has shown both a high sensitivity and a high specificity (both above 90%) for the diagnosis of SLE [13]. Detected by high-resolution melting-quantitative polymerase chain reaction (HRM-qPCR) assay, this IFI44L methylation biomarker can be a potential laboratory test to help distinguish SLE from DLE, with a sensitivity of 96.00%, a specificity of 72.55%, a positive predictive value of 77.42% and a negative predictive value of 94.87%, when 25% methylation is defined as the cutoff value [14].

Upon establishing the diagnosis of CLE, a clinical assessment of the disease activity and damage can be helpful to the determination of therapeutic strategies and to the evaluation of treatment efficacy at each follow-up in the future. Cutaneous Lupus Erythematosus Disease Area and Severity Index (CLASI), a clinical measurement tool developed in

2005, has been the first instrument used for evaluation of disease activity and damage in CLE patients [15,16]. This instrument is overall useful in clinical trials, however, its scoring methods cannot give an accurate assessment in some subtypes of CLE [17]. For example, the CLASI activity score consists of erythema and scale/hypertrophy scores only, and thus cannot reflect the severity of edema, infiltration or subcutaneous nodules, which are important features of LET and LEP and necessary for evaluate their disease activity. Therefore, Revised Cutaneous Lupus Erythematosus Disease Area and Severity Index (RCLASI) was developed as an improved version of the CLASI, with more various clinical features of the different subtypes of CLE taken into account [15, 16]. The validity and applicability of RCLASI has been validated by a series of reliability studies, supporting it as a more suitable instrument than CLASI for the clinical evaluation of CLE activity and damage in different disease subtypes in clinical studies [15,16].

5. Treatment of CLE

Treatment of CLE should be individualized due to the high clinical heterogeneity of this disease. A long-term management of CLE is recommended. Patient education on the risk factors, protective measures and the necessity of a long-term follow-up is a basis for a better treatment outcome. Recommendations on the application of each topical or systemic agent for treatment of CLE, as well as considerations for special groups of patients such as pregnant women and children, are present as follows.

5.1. Risk factors and protective measures for CLE

5.1.1. Recommendations

- We recommend protection against UV and sunlight exposure, including avoidance of unprotected outdoor activities, seeking shade, wearing protective clothing, and application of sunscreens, in all CLE patients. We recommend against any UV light as treatment for patients with CLE. Meanwhile, we suggest Vitamin D supplementation in patients who keep long-term sun protection. (97% consensus)
- We recommend cessation of smoking in all CLE patients. (100% consensus)
- We recommend to perform a thorough history of drug/medicine use in CLE patients, especially in patients with SCLÉ and patients with LET. (100% consensus)
- If the patients with CLE have a history of Koebner phenomenon, we suggest avoidance of trauma, surgery, cryotherapy and invasive laser treatment of the skin unless it is necessary or unavoidable or its benefit outweighs the risk. (88% consensus)

68

5.1.1.1. Ultraviolet radiation. Ultraviolet (UV) radiation is one of the environmental factors involved in triggering cutaneous symptoms in patients with various subtypes of LE, in particular LET and SCLÉ, demonstrated by phototesting studies in more than 500 patients [18–22]. A randomized, vehicle-controlled, double-blind study confirmed that the use of a highly protective broad-spectrum sunscreen (sun protection factor 60) prevents UV-induced skin lesions in 25 patients with different subtypes of CLE. Similarly, a monocentric, prospective, open-label study determined that the use of a broad-spectrum liposomal sunscreen with a very high sun protection factor (50+ or 60) prevents UV-induced damage in patients with CLE [19,21]. Besides, it is worth noting that individuals, such as patients with CLE, that avoid direct exposure to sunlight and frequently use sunscreen have suboptimal serum 25-hydroxyvitamin D levels throughout the year [23–25].

5.1.1.2. Cigarette smoking. The influence of smoking behavior on CLE was analyzed in a cross-sectional study of 838 patients with CLE in 14 different European countries [26]. Its data showed a negative impact of cigarette smoking on disease severity and on therapeutic efficacy of antimalarials (hydroxychloroquine and chloroquine) for CLE. A meta-analysis of 1398 patients with CLE showed cigarette smoking is associated with a 2-fold decrease in the proportion of patients who achieved cutaneous improvement with antimalarials and smoking cessation may enhance cutaneous improvement in CLE [27]. Moreover, cigarette smoking as a risk factor influencing cutaneous manifestations of LE has been demonstrated in a multicenter prospective case-control study of 102 patients with CLE [28]. A descriptive analysis of 215 patients with CLE also determined that cigarette smoking is associated with an increase risk and a higher disease activity of CLE [29].

5.1.1.3. Drugs. Drug-induced CLE (DI-CLE) can be classified into two major subtypes, namely, drug-induced SCLÉ (DI-SCLÉ) and chronic

cutaneous drug-induced lupus erythematosus (CCDILE) [30]. DI-SCLÉ is the most common subtype, and is more frequently seen in older female patients [31]. Two reviews summarizing a total of 205 patients with DI-SCLÉ suggested that triggering drugs fell into more than 10 categories, highlighted by proton pump inhibitors, antihypertensives (e.g. calcium channel blockers, beta blockers, angiotensin-converting enzyme inhibitors and diuretics) and antifungals [31,32]. CCDILE is rare, and often associated with fluorouracil agents and anti-TNF α [33,34]. Recently, an observational retrospective study summarized the clinical data from 1994 patients with DI-CLE recorded between 1967 and June 2019 using VigiBase, the World Health Organization global individual case safety reports database, which included reports collected by national drug authorities in over 130 countries [35]. This analysis identified a list of 94 drugs as associated with DI-CLE, among which drugs associated with the highest number of reported DI-CLE cases include anti-TNF biologics (e.g. etanercept, adalimumab and infliximab), proton pump inhibitors (e.g. omeprazole) and terbinafine [35].

5.1.1.4. Koebner phenomenon. Koebner phenomenon has been occasionally reported in patients with CLE following traumas, scratching effects, operation scars, contact dermatitis, pressure from clothing, application of liquid nitrogen, or exposure to strong sun light, infections or heat [36–40].

5.1.1.5. Hormones. Exogenous estrogens are rarely prescribed for female patients with LE, because of concerning about potential negative effects, while two randomized studies published in the New England Journal of Medicine and a systemic review and meta-analysis revealed no increase in risk of lupus progression with use of estrogens [41–43]. To our knowledge, there are no data concerning use of exogenous estrogens in patients with CLE.

5.1.1.6. Radiotherapy. Currently, a connective tissue disorders is not regard as an absolute contraindication to radiotherapy (RT) [44,45], while few studies proposed that RT might be the trigger of CLE [46,47].

5.2. Topical and localized treatment for CLE

5.2.1. Topical corticosteroids and intralesional injection of corticosteroids

5.2.1.1. Recommendations.

- We recommend topical corticosteroids as first-line treatment for a short term (up to several weeks) in all CLE lesions except the lesions on the scalp where prolonged use of topical corticosteroids may be necessary and allowed. (94% consensus)
- We suggest intralesional injection of corticosteroids for localized, refractory DLE. (97% consensus)

84

Multiple randomized controlled trials (RCTs) have highlighted topical steroids as the primary treatment for CLE. In 2017, the Cochrane Systematic Review database included a total of 5 RCTs in DLE treatment [48]. An RCT trial involving 78 DLE patients comparing a potent corticosteroid cream, i.e., 0.05% fluocinonide, with a low-potency corticosteroid cream, i.e., 1% hydrocortisone, showed that localized high-potency corticosteroids were more effective than low-potency corticosteroids in treating DLE lesions (27% versus 10%) [49]. A study conducted by Barikbin and colleagues compared the efficacy of 0.1% betamethasone 17-valerate cream and 1% pimeumus cream in the treatment of facial DLE and showed a 73% improvement in severity of skin lesions in the 0.1% betamethasone 17-valerate cream group [50], similar to the improvement in the 1% pimeumus cream group. In another study evaluated with a modified GLASI score by Pothinamthong and colleagues [51], DLE patients in Thailand treated topically with

0.05% clobetasol for 6 weeks led to a greater improvement in disease activity than did patients treated with 0.1% tamoxifen ointment (average change of CLASI score from baseline: 5.29 vs. 3.52). Due to the commonly seen side effects such as atrophy, telangiectasia, and steroid-induced rosacea, topical application of glucocorticoids should be intermittent and not exceeding several weeks consecutively. A common recommendation is to use it for 2 weeks and then maintain it only on weekends [52]. Patients with scalp lesions may require prolonged use of topical steroids [52].

As an empirical treatment, intralesional injection of triamcinolone may be beneficial to patients with localized, refractory DLE [53–55].

5.2.2. Calcineurin inhibitors

5.2.2.1. Recommendation.

- We recommend calcineurin inhibitors as an alternative first-line option for topical treatment of DLE and other active, edematous CLE lesions, particularly lesions on the face. (97% consensus)

Topical calcineurin inhibitors including 0.03% and 0.1% tacrolimus ointments and 1% pimecrolimus cream provide another choice of topical treatment for CLE. Compared to topical corticosteroids, topical calcineurin inhibitors have a better safety profile, without the concern of steroid-associated side effects such as skin atrophy, telangiectasia and hyperpigmentation. Kuhn and colleagues conducted a multicenter, randomized, double-blind, vehicle-controlled trial to evaluate the efficacy of 0.1% tacrolimus ointment in treatment of CLE lesions [56]. For each participant among the 30 patients with different subtypes of CLE, two selected skin lesions were treated with 0.1% tacrolimus ointment and vehicle, respectively, twice daily for 12 weeks. Compared with CLE lesions treated with the vehicle control, significant improvement was observed in lesions treated with 0.1% tacrolimus ointment, especially in patients with acute, edematous, non-hyperkeratotic CLE lesions, e.g., LET [56]. The previously mentioned study of 21 Thai patients with DLE comparing the efficacy of 0.05% clobetasol propionate and 0.1% tacrolimus ointment showed improvements in disease activity in both treatment groups, although 0.05% clobetasol propionate was better than 0.1% tacrolimus ointment [51]. A randomized, controlled clinical trial included 41 patients with labial DLE, among which 22 patients were treated with 0.03% tacrolimus ointment and 19 were treated with 0.1% triamcinolone acetonide cream. After a 3-week treatment, 20 participants in the tacrolimus group and 19 in the triamcinolone group completed the study, showing a complete response rate of 70% and 89.5%, respectively. There were no significant difference in complete response rate or reduction in erosion and erythema between the two treatment groups [57]. A retrospective study including 18 treatment-resistant patients with CLE suggests that a specially formulated preparation of tacrolimus 0.3% in clobetasol propionate 0.05% ointment may be superior to single drug treatment with either 0.1% tacrolimus or 0.05% clobetasol propionate ointment [58].

Barikbin and colleagues compared the efficacy of an 8-week treatment with 1% pimecrolimus cream and 0.1% betametasone 17-valerate cream, respectively, in patients with DLE [50]. The results showed that the DLE disease activity decreased by 84% and 73%, respectively, in the two treatment groups, with the difference not statistically significant [50]. Other observational studies have documented the efficacy of 1% pimecrolimus cream in treatment of CLE patients [59,60].

5.2.3. Topical retinoids

5.2.3.1. Recommendation.

- We suggest topical retinoids as second-line treatment in VLE and other hyperkeratotic lesions of CLE, especially in cases refractory to topical corticosteroids or topical calcineurin inhibitors. (100% consensus)

Retinoids, including tazarotín gel, 0.05% retinoid cream and 0.025% retinoic acid gel, have not been tested by RCT studies for their efficacy in treating CLE. But a series of case reports have suggested its efficacy in hypertrophic lesions of CLE, especially VLE [61–63]. Most of these reported cases had failed to respond to topical corticosteroids or calcineurin inhibitors and were successfully treated by topical retinoids [62, 63].

5.2.4. Pulsed-dye laser

5.2.4.1. Recommendation.

- We suggest PDL as fourth-line treatment for refractory, inactive cases of DLE when conventional therapies with topical and systemic agents have failed. Importantly, PDL treatment must be performed by board-certified dermatologists. (84% consensus)

Pulsed-dye laser (PDL) can selectively destruct blood vessels and cause a coagulative effect in the upper dermis by targeting oxyhemoglobin within the erythrocytes. PDL has been reported to be applied in the treatment of refractory DLE lesions with the speculation that its therapeutic effect may lead to a suppression of the inflammation in DLE lesions. A randomized, double-blind, controlled clinical trial including 48 DLE lesions from 9 patients demonstrated that an addition of 595 nm PDL therapy on the basis of conventional treatment improved erythema, texture, and overall skin appearance of DLE. [64] A few cases series have also shown favorable efficacy and safety of PDL treatment in patients with CLE [65–75].

5.3. Systemic treatment for CLE

5.3.1. Antimalarials

5.3.1.1. Recommendations.

- We recommend antimalarials, especially HCQ, as first-line systemic treatment in all CLE patients with widespread or severe skin lesions. (100% consensus)
- To avoid the risk of irreversible retinopathy, we recommend HCQ at a daily dose of ≤ 5 mg/kg real body weight or CQ at a daily dose of ≤ 2.3 mg/kg real body weight, and we recommend against a combination therapy of HCQ with CQ. We recommend an ophthalmological examination at baseline and annually after 5 years of starting treatment with HCQ or CQ, or annually after starting treatment in the presence of risk factors of retinopathy. (94% consensus)
- We suggest quinacrine as an add-on therapy if available, by clinicians who have experience in the use of this drug, for cases refractory to monotherapy with HCQ. (91% consensus)
- We suggest an examination of G6PD activity, if available, before antimalarial treatment. (88% consensus)

Antimalarial drugs have long been considered as a first-line systemic treatment for all CLE subtypes, and there have been currently three CLE-related RCT studies. A double-blind, randomized, placebo-controlled, Phase III trial including 103 patients with active CLE (CLASI activity

score ≥ 4) conducted by Yokogawa and colleagues evaluated the efficacy of hydroxychloroquine (HCQ) for treating CLE lesions [76]. After a 16-week double-blind period, the investigator's global assessment showed a significantly greater proportion of "improved" and "remarkably improved" patients in the HCQ group than in the placebo group (51.4% versus 8.7%, respectively), albeit the difference between the two groups in the improvement of CLASI score at week 16 from baseline was not statistically significant. The other secondary end points such as the central photo evaluation, patient's global assessment, the Skindex-29 score, and investigator's global assessment supported the efficacy of HCQ. Ruzicka and colleagues compared the roles of HCQ and acitretin in different CLE subtypes [77]. After 8 weeks of treatment, 50% of the 30 patients treated with HCQ showed improvement, while 46% of the 28 patients treated with acitretin improved. The incidence of side-effects was higher in the acitretin group, which necessitated the discontinuation of acitretin treatment in 4 patients. Bezerra and his colleagues compared clofazimine with chloroquine (CQ). Good responses were observed in 12 (75%) of the 16 patients in the clofazimine group and in 14 (82.4%) of the 17 patients in the CQ group [78]. 18.8% of patients treated with clofazimine and 41.2% of patients treated with CQ had a complete response, respectively, although the difference was not statistically significant [78]. According to an analysis based on the European Society of Cutaneous Lupus Erythematosus (EUSCLE) Core Set Questionnaire, the application rates of HCQ and CQ in 1002 patients were 56.7% and 30.8%, respectively, and the effective rates were 81.5% and 86.9%, respectively [79]. In a retrospective study evaluating the therapeutic efficacy of HCQ on 35 Japanese patients with CLE, 87% of patients had either complete or partial response and 54.3% had complete improvement by 16 weeks [80]. Notably, CLE tends to take more time to improve than ACLE, and partial or non-improvement rates at 16 weeks were higher in the CLE patients.

Retinopathy is the main toxicity, and also a contraindication, of HCQ and CQ. Based on a retrospective study evaluating the data of 2361 patients who were treated with HCQ continuously for at least five years, the American Academy of Ophthalmology concluded that treatment with HCQ at a daily dose of ≤ 5.0 mg/kg for up to 10 years is at low risk for HCQ-associated retinal toxicity [81,82]. As regard to CQ, the American Academy of Ophthalmology also suggest a maximum dosage for safety consideration, which is ≤ 2.3 mg/kg/d [82]. Patients should receive a basic ocular fundus examination within the first 6 months of treatment. Pre-existing macular degeneration, renal insufficiency (glomerular filtration rate < 60 ml/min), tamoxifen comedication, daily dose > 5 mg/kg HCQ can increase the risk of retinopathy. Thus, these patients should have an annual ocular fundus examination from the start of treatment, and those without these risk factors are advised to take an annual fundus examination five years after the start of treatment with HCQ or CQ [82,83].

Quinacrine may be added for cases refractory to monotherapy of HCQ or CQ. In a prospective cohort study of 128 patients, 67% of 15 patients who did not respond to HCQ began to respond to a combined treatment with HCQ and quinacrine, showing a decrease in the median (interquartile range) activity score from 6.0 (4.8–8.3) to 3.0 (0.75–5.0), without an increased risk of retinopathy [84].

For safety concern, it should be noted that high-dose antimalarials can induce acute hemolytic crisis in patients with glucose-6-phosphate dehydrogenase (G6PD) deficiency, whose incidence is highest in Africa, Asia and Mediterranean populations [85].

5.3.2. Systemic corticosteroids

5.3.2.1. Recommendations.

- We recommend systemic corticosteroids as first-line treatment in addition to antimalarials in patients with severe or

widespread active CLE lesions and in CLE patients with systemic involvement. (97% consensus)

- We recommend gradual tapering and final discontinuation of systemic corticosteroids when CLE becomes under control. During the tapering and after discontinuation of systemic corticosteroids, we recommend the continuation of treatment with antimalarials or other corticosteroids-sparing agents. (100% consensus)
- To reduce the risk of corticosteroids-associated side-effects, we recommend against long-term maintenance treatment with corticosteroids in CLE patients without systemic involvement. (100% consensus)

In a prospective, cross-sectional, multicenter study conducted by EUSCLE, systemic corticosteroids were shown to be effective in 94.3% of the 413 CLE patients using this treatment, an efficacy higher than all other systemic drugs used for CLE treatment [79]. Treatment with systemic corticosteroids usually starts with a small to medium dose, e.g. prednisone 0.5 mg/(kg \cdot d), which is tapered down after control of disease and finally stopped [86,87]. To avoid the well-known side-effects including Cushing syndrome, infections, peptic ulcers, osteoporosis and cataracts [88], long-term glucocorticoid maintenance therapy is not recommended for CLE patients with no systemic involvement [89].

5.3.3. Thalidomide and lenalidomide

5.3.3.1. Recommendations.

- We recommend thalidomide as second-line treatment for refractory CLE, especially DLE and SCLE, preferably in addition to antimalarials. (88% consensus)
- We suggest against lenalidomide for the treatment of CLE. (97% consensus)

Four uncontrolled trials investigating the efficacy of thalidomide in patients with several subtypes of CLE, including DLE, showed high remission rates (98–100%) after treatment with thalidomide [90–92]. Similarly, high response rates were reported in observational studies and case series (67–100%) [93,94]. Among these studies, Cuadrado and co-workers evaluated the efficacy of thalidomide in 48 patients with severe CLE that was unresponsive to antimalarials, prednisolone, methotrexate, azathioprine and (or) cyclosporin [94]. After thalidomide treatment, 29 cases (60%) showed complete response, 10 cases (21%) showed partial response and 9 patients (19%) had no response. Peripheral neuropathy occurred in 13 patients (27%), 11 of which were confirmed by electromyogram. A recent systemic review revealed a much higher incidence of neural system adverse reactions. According to its summarization, up to 50–70% of patients treated with thalidomide develop neural symptoms or neuropathy, as confirmed by electrophysiological examination of the peripheral nerves [95].

As a structural analogue of thalidomide, lenalidomide has a lower incidence of adverse reactions, especially neuropathy. In a subgroup analysis, Cortes-Hernandez and co-workers found that complete remission was achieved in 12 of 14 patients with refractory CLE after treatment with lenalidomide, among which DLE and SCLE took a shorter time to achieve complete remission than LEP [96]. A case series indicates that patients with LEP do not respond to treatment with lenalidomide [97]. There has also been concerns that lenalidomide may induce lupus erythematosus [98].

5.3.4. Retinoids

5.3.4.1. Recommendation.

- We recommend systemic retinoids as second-line treatment for refractory CLE, especially hyperkeratotic lesions and VLE, preferably in addition to antimalarials. (100% consensus)

Retinoids were suggested as second-line systemic therapy for CLE by the 'American Academy of Dermatology' guidelines in 1996 [99]. Ruzicka et al. conducted a double-blind, randomized, multicenter trial in 1992 to compare the efficacy of acitretin (50 mg/d) and HCQ (400 mg/d) in 28 and 30 CLE patients, respectively [77]. Overall improvement was seen in 46% (13/28) of the patients treated with acitretin and in 50% (15/30) of the patients treated with HCQ. In addition, oral isotretinoin has been reported to be effective in the treatment of refractory SCLE [100,101]. For VLE and (or) hypertrophic lesions of CLE, sporadic case reports have shown significant therapeutic effects of either acitretin or isotretinoin [102,103].

The recommended daily dose of acitretin and isotretinoin in treatment for CLE is 0.2–1.0 mg/kg body weight. It usually takes 2–6 weeks for patients to achieve treatment response [104], however, relapse of CLE can occur shortly after withdrawal of retinoids [100,101].

5.3.5. Dapsone

5.3.5.1. Recommendations.

- We recommend dapsone as second-line treatment in refractory CLE, especially bullous lesions of CLE or bullous systemic lupus erythematosus (BSLE), preferably in addition to antimalarials and systemic corticosteroids. (97% consensus)
- To reduce the risk of its severe side effects, we recommend examination of G6PD activity and HLA-B*13:01 alleles prior to the initiation of treatment with dapsone. (100% consensus)
- We recommend to begin with a low-dose (50 mg/day) of dapsone and to increase the dose according to treatment response and side-effects. The dose of dapsone must not exceed the upper limit of 1.5 mg/kg/day. (100% consensus)

Dapsone is mainly used in the treatment of BSLE [105], and it is also used in DLE and SCLE where the conventional treatment is not satisfactory [106,107]. Recommended by the European League Against Rheumatism (EULAR), dapsone (100 mg/day) alone or in combination with prednisone, is the treatment of choice for BSLE [108]. A retrospective analysis of 34 CLE patients showed that dapsone was effective in more than 50% of CLE patients with or without antimalarial drugs [109]. Successful treatment of LEP with dapsone has been reported in 11 cases [110].

For safety concern, dapsone is not recommended in patients with G6PD deficiency to avoid one of its severe side effects, hemolytic anemia, in these individuals. Recent studies have confirmed that HLA-B*13:01 is associated with the development of dapsone hypersensitivity syndrome, a fatal side effects of this drug, among patients with leprosy treated with this drug [111]. Thus, dapsone is not recommended in individuals carrying the HLA-B*13:01 allele. HLA-B*13:01 is present in about 2–20% of individuals in Chinese population, 1.5% in Japanese, 1–12% in Indians, and 2–4% in Southeast Asians, while it is largely absent in Europeans and Africans [111].

5.3.6. Methotrexate (MTX)

5.3.6.1. Recommendations.

- We recommend low-dose MTX, usually less than 15 or 20 mg per week, preferably subcutaneously, as second-line treatment for refractory CLE, especially SCLE. (97% consensus)
- We suggest intake of folic acid at a dose of 5–10 mg/week to reduce side effects of MTX during the treatment with MTX. (91% consensus)
- We suggest regular monitoring of complete blood counts and serum levels of liver enzymes during long-term use of MTX. (100% consensus)

A systematic review included a RCT and two observational trials looking at MTX in the treatment of CLE [95,112–114]. In the RCT study of 41 SLE patients comparing the efficacy and safety of MTX and chloroquine (CQ) for skin manifestations of SLE, the skin lesions in both groups were significantly improved after a 24-week treatment, with no significant difference between groups, demonstrating that low-dose methotrexate can be as effective as CQ [112]. In the two observational trials, improvement was achieved in most patients. Briefly, a retrospective analysis of 43 patients with CLE showed that MTX significantly reduced disease activity, with improvement in skin lesions recorded in 98% of patients treated with MTX; and in addition, 15 of these patients switched from intravenous to subcutaneous administration of MTX at subsequent follow-up, demonstrating a similar therapeutic effect [115]. In the other retrospective analysis, 10 of the 12 patients with CLE receiving weekly administrations of 10–25 mg MTX showed significant improvement, whereas two patients did not respond to this treatment [114].

The side effects of methotrexate are mainly hair loss and elevated aminotransferase [116]. Folic acid supplementation with MTX is recommended to reduce the side effects of elevated liver enzymes [117,118]. As to safety profiles, a large-scale retrospective analysis including patients with rheumatic diseases investigated 2093 patients on oral MTX and 949 patients on subcutaneous MTX. The results showed that subcutaneous MTX had a non-significant trend to lower rates of neutropenia and only a slightly higher rate of transaminitis despite significantly higher doses than oral MTX; and in addition, continuation rates of subcutaneous MTX were higher than that of oral MTX when adjusted for follow-up duration, suggesting a superior tolerability of subcutaneous administration of this drug [119].

5.3.7. Mycophenolate mofetil (MMF) and other immunosuppressant agents

5.3.7.1. Recommendations.

- We recommend MMF as third-line treatment for refractory CLE, preferably in addition to antimalarials. (100% consensus)
- We suggest initiation of MMF at a dose of 500 mg twice daily that can be increased or tapered later depending on treatment response and side effects. (97% consensus)
- We suggest MPA as an alternative choice for MMF. (97% consensus)
- We suggest against azathioprine, cyclophosphamide and cyclosporine as a treatment for CLE without systemic involvement. (97% consensus)

There is a lack of randomized controlled trials on the application of immunosuppressant agents such as mycophenolate mofetil (MMF), azathioprine, cyclophosphamide and cyclosporine in CLE. Nonetheless, the therapeutic efficacy of MMF in refractory CLE, in combination with HCQ and (or) systemic corticosteroids, has been repeatedly reported

[120–122]. A retrospective analysis evaluating 24 patients with CLE recalcitrant to antimalarials showed that MMF was well tolerated and effective in treating CLE as an add-on therapy to standard treatment. In these 24 patients, MMF was started at doses ranging from 500 to 1000 mg per day and then increased to an average dose of 2750 mg per day, which resulted in a complete or partial response in all patients, with an average time of 2.76 months to clinical response [121].

Upon oral administration, MMF is completely metabolized to its active moiety, mycophenolic acid (MPA). Kreuter et al. treated 10 patients with intractable SCLÉ by oral administration of enteric-coated mycophenolate sodium, an advanced formulation delivering MPA, at 1440 mg/day as a monotherapy for 3 months, and observed significant improvement in CLASI scores, although these preliminary data need to be supported by large samples [122].

Azathioprine, cyclophosphamide, and cyclosporine have been mainly used for the treatment of SLE. Clinical evidence of these drugs in the management of CLE is lacking.

5.3.8. Belimumab

5.3.8.1. Recommendation.

- We suggest belimumab as fourth-line treatment for widespread, refractory CLE lesions in patients with active SLE, especially those who have repeated recurrence of ACLE lesions during tapering of systemic corticosteroids. (100% consensus)

The therapeutic efficacy and safety of belimumab, a monoclonal antibody selectively targeting soluble human B cell-activating factor (BAFF, also known as B lymphocyte stimulator or BlyS), in SLE has been supported by recent evidence from multi-center RCT trials and real-world studies. However, there is currently no RCT trials designed for treatment of CLE. A case-series report showed that belimumab was effective in treating 16 patients with CLE that were refractory to conventional therapies [123]. In a phase III, randomized, placebo-controlled trial of belimumab in patients with SLE in China, Japan and South Korea including 677 participants, patients with baseline mucocutaneous BILAG score of A or B improved 44.3% in the placebo group and 57.8% in the Belimumab group after a 52-week treatment ($p = 0.025$), which reflect a favorable therapeutic effect of belimumab in skin and mucosal lesions of SLE [124].

5.4. Drugs for management of CLE during pregnancy

5.4.1. Recommendations

- We suggest topical glucocorticoids, except for potent and superpotent glucocorticoids, as first-line treatment for CLE lesions in pregnant patients. (97% consensus)
- We cannot make a recommendation with respect to topical calcineurin inhibitors in pregnant patients with CLE. (88% consensus)
- We suggest hydroxychloroquine with or without low-dose prednisone as first-line maintenance treatment for CLE patients during pregnancy. (97% consensus)
- Due to the teratogenic effects of retinoids, it is forbidden to treat pregnant patients or patients preparing for pregnancy with systemic retinoids. During treatment with systemic retinoids and the immediate period after treatment cessation (isotretinoin: 3 month; acitretin: 2 years), effective contraception is strongly recommended. (100% consensus)
- Due to the teratogenic effects of thalidomide, MTX, MMF and MPA, it is forbidden to treat pregnant patients or patients preparing for pregnancy with any of these drugs. Effective

contraception is strongly recommended during treatment with any of these teratogenic drugs. (100% consensus)

Pregnancy medication for CLE patients should basically comply with the 2017 EULAR guidelines for women with SLE [125]. Hydroxychloroquine is a drug that has been tested for safety during pregnancy. A randomized, placebo-controlled study enrolling 20 consecutive pregnant patients with SLE ($n = 17$) or DLE ($n = 3$) has revealed a beneficial role of HCQ in controlling disease activity and preventing lupus flares during pregnancy, as well as a good safety profile with no detriment to the health of pregnant patients and their neonates [126]. For patients with SLE, low-dose prednisone as a maintenance treatment is usually continued during pregnancy if lupus activity is controlled well, and regular follow-up is recommended [127,128].

The application of topical glucocorticoids of any potency during pregnancy does not increase the risk of preterm delivery, fetal death, birth defects or low Apgar score [129]. However, a very large cumulative dosage of potent to very potent topical corticosteroids during pregnancy is probably associated with low birth weight [129].

Absorption of topical calcineurin inhibitors (i.e., tacrolimus and pimecrolimus) through the skin barrier is very limited when treated with standard doses [130]. It is reported that 50–70% of tacrolimus in maternal blood passes through the placental barrier, based on measurements of blood collected from the umbilical cord at birth [131]. However, no evidence from clinical trials has been available to evaluate the efficacy and safety of topical tacrolimus during pregnancy in patients with CLE.

Mycophenolic acid and methotrexate should be avoided because of known or possible teratogenic properties [125]. Retinoids and thalidomide have definite teratogenic effects and are contraindicated in women planning pregnancy or during pregnancy [132,133]. Pregnancy should be avoided during treatment with systemic retinoids and within 3 months after withdrawal of isotretinoin or 2 years after withdrawal of acitretin. Isotretinoin is not allowed to be used during breastfeeding.

5.5. Drugs for management of pediatric patients with CLE

5.5.1. Recommendations

- We suggest topical glucocorticoids as first-line treatment for CLE in pediatric patients, especially for localized CLE lesions. (97% consensus)
- We suggest hydroxychloroquine as first-line systematic treatment for CLE in pediatric patients. (100% consensus)

Clinical evidence for both topical and systemic treatments of CLE in pediatric patients is still lacking. For children with CLE, dosage should be adjusted and growth should not be affected as much as possible. Topical corticosteroids and oral hydroxychloroquine are commonly used in clinical practice. Due to the side effects of MMF, it is not recommended for long-term use in children for CLE lesions without systemic involvement, and is only used as a treatment for refractory CLE [134]. Thalidomide should not be used in children unless as a rescue therapy for CLE refractory to routine treatment. Peripheral neuropathy is a commonly seen dose-dependent side effect of this drug, and children older than 12 years of age may be more prone to this adverse effect than younger patients [135,136].

5.6. Surgical treatment for CLE

5.6.1. Recommendations

- We suggest surgical excision of the lesion followed by skin grafting using full-thickness abdominal skin as fourth-line treatment for refractory, localized lesions of CLE, especially DLE, VLE and CHLE, in cosmetically unacceptable areas when

conventional therapies with topical and systemic treatments have failed or are intolerable to the patients. This surgical intervention must be combined with medical treatment with antimalarials and (or) systemic corticosteroids. (84% consensus)

Although CLE lesions are seldom treated surgically, there have been a few reports of cases with recalcitrant lesions successfully treated by surgical removal of the lesions with skin grafting when treatment with antimalarials, systemic corticosteroids and thalidomide was continued. This method was tried in two patients with CHLE resistant to conventional treatments [137]. These patients received surgical excision of the lesions followed by full-thickness free skin grafting obtained from the abdominal region. No recurrence was observed in the operated area 7 years (case 1) and 3 years (case 2) after surgery, respectively, although the lesions persisted in the areas where lesions had not been adequately excised and where lesions were not operated upon. Similar surgical treatment has also been reported in cases of DLE recalcitrant to conventional therapies including systemic corticosteroids and MMF [138]. However, a relapse of the DLE lesions occurred several months after discontinuation of the immunosuppressant agents, which was successfully cleared again by a secondary surgical removal and skin grafting combined with a maintenance treatment with systemic corticosteroids and MMF.

The effectiveness of this method may be explained by the surgical removal of the pathological epidermis and dermis, and that the skin graft comes from anatomical regions not exposed to the sun.

6. Monitoring of patients with CLE

CLE requires long-term disease monitoring due to its chronic and relapsing course. The frequency of disease management can be adapted to the severity and activity of disease, the patient's clinical condition, and the medication and treatment response.

6.1. Clinical and laboratory evaluations

6.1.1. Recommendation

12

- We suggest assessment of disease activity, skin damage and other organ damage, quality of life, comorbidities and possible adverse events in every follow-up visit, when appropriate. (97% consensus)

For clinical assessment of disease activity and skin damage of CLE, the aforementioned CLASI scoring instrument and its improved version, RCLASI, have been widely used in clinical trials [15,16]. Compared to CLASI, RCLASI has taken into account more detailed clinical features of the various subtypes of CLE and is a better choice than its predecessor.

Basic laboratory assessments include complete blood count, erythrocyte sedimentation rate (ESR), serum creatinine, urinalysis, urine protein to creatinine ratio, serum level of complement C3 and C4, serum level of 25-hydroxyvitamin D, serum calcium and potassium, and serum albumin. Examination of serum autoantibodies at baseline and every 6–12 months or in case of relapse may help earlier recognition of progression into SLE or overlap syndrome with other connective tissue diseases. These autoantibodies include ANA, a spectrum of anti-extractable nuclear antigens (ENA) autoantibodies, lupus anticoagulant and antiphospholipid antibodies (anticardiolipin antibodies and anti- β 2-glycoprotein-1 antibodies). Toxicity or side effects of treatment agents including antimalarials, corticosteroids, methotrexate, thalidomide and retinoids should be alerted.

6.2. Preconception evaluation

6.2.1. Recommendation

- We recommend a preconception evaluation on the control of lupus, other risk factors of pregnancy and medication use for patients with CLE preparing for pregnancy, preferentially by both an obstetrician and a dermatologist or rheumatologist. (97% consensus)

The preconception evaluation is an essential step to minimize the risk of maternal and fetal complications in lupus patients and to improve the prognosis of high-risk pregnancies [139]. Screening is performed for high-risk pregnancy including uncontrolled lupus, systemic episodes or severe flare(s) of lupus within the last half year, uncontrolled hypertension, previous severe preeclampsia, severe pulmonary hypertension, organ failure, HELLP (hemolysis, elevated liver enzymes, and low platelet count) syndrome, stroke within the last 6 months, the history of obstetric complications, APS, the need for a daily dose of corticosteroid above 10 mg, and the positivity of anti-SSA or anti-SSB autoantibodies. In addition, creatinine clearance less than 40 ml/min is a relative contraindication.

Laboratory evaluation includes complete blood count, coagulation test, serum transaminases, serum creatinine, urinary sediment (leukocyturia, hematuria), urinary protein (urine protein to creatinine ratio or quantification of 24-hour urine protein), HBV, HCV, HIV, TPHA-VDRL, toxoplasmosis and measles serology, lupus anticoagulant and antiphospholipid antibodies, serum anti-SSA, anti-SSB and anti-dsDNA antibodies, complement (C3 and C4), thyroid stimulating hormone and anti-thyroid peroxidase antibodies, and serum hydroxychloroquine level if the test is available [140].

6.3. Pregnancy evaluation

6.3.1. Recommendations

- We recommend a regular, close monitoring of the health status for patients with CLE during pregnancy by both an obstetrician and a dermatologist or rheumatologist. (100% consensus)
- We recommend a consultation on management of lupus during the perinatal period by a dermatologist or rheumatologist. (100% consensus)

All pregnant women with CLE should be closely monitored by multidisciplinary assessment. Usually, monitoring should be performed monthly during pregnancy and more frequently at the end of pregnancy and during the perinatal period, which can be individually adjusted according to the patient's pregnant status and adverse obstetric history, if applicable. Clinical assessment and laboratory examinations on lupus activity are generally performed every 2–3 months. Ultrasound monitoring is carried out routinely in each trimester of pregnancy. For patients with APS or presence of antiphospholipid antibodies or lupus anticoagulant, it is recommended to perform Doppler ultrasound examination of the uterus at 22 weeks of gestation (WG) and umbilical Doppler ultrasound assessment of amniotic fluid volume and fetal biometrics at 28 and 36 WG, respectively. For patients with anti-SSA and (or) anti-SSB positivity, it is proposed to carry out a fetal echocardiography screening at least every two weeks during 16 through 24 WG, which should be performed even weekly in case that these patients had a history of atrioventricular block or the patients' sibling(s) had neonatal lupus erythematosus [141]. During the perinatal period, a consultation on management of lupus by a dermatologist or rheumatologist is beneficial.

6.4. Progression of CLE to SLE

6.4.1. Recommendation

- We suggest a routine screening of SLE in regular follow-up visit for all patients with CLE. (94% consensus)

A patient is considered to have experienced a transition to SLE if the patient has been diagnosed as CLE and later progresses to fulfill the EULAR/ACR classification criteria for SLE in the follow-up period [142]. The British Isles Lupus Assessment Group's (BILAG) disease activity index and the Systemic Lupus Erythematosus Disease Activity Index 2000 (SLEDAI-2K) can be used to determine systemic involvement and disease activity, respectively, in patients with CLE who progress to SLE [143,144].

6.5. Discontinuation of treatment

6.5.1. Recommendation

- We suggest discontinuation of systemic corticosteroids following tapering of the dosage when CLE lesions are controlled, and we suggest against a long-term maintenance treatment with systemic corticosteroids for patients with CLE. (100% consensus)

CCLE has a chronic, recurrent course of disease and usually needs long-term treatment. For ACLE, SCLE and ICLE, a maintenance treatment with antimalarials is generally recommended even if the lupus lesions have resolved, and long-term follow-up and monitoring are required. There has been no evidence so far to support a life-long treatment for CLE or to set a time point for discontinuation of maintenance treatment. Nonetheless, for patients treated with systemic corticosteroids, tapering of corticosteroids followed by its discontinuation upon control of CLE is recommended to reduce side effects.

6.5.2. Summary

CLE can be classified into ACLE, SCLE, CCLE and ICLE, and its diagnosis is mainly based on the evaluation of clinical manifestations and histopathological features. DIF of the biopsy skin and a series of laboratory examinations including serum autoantibodies such as ANA, ENAs and antiphospholipid antibody, may be of help in the diagnosis and differential diagnosis. Evaluation of systemic involvement is necessary to exclude the diagnosis of SLE and should be a crucial part of disease monitoring for patients with CLE during the follow-up period. As a basis of disease management for all patients with CLE, patient education and a long-term follow-up are always necessary to help monitor the disease activity, systemic involvement, comorbidities and possible adverse events.

There are a variety of treatment measures for CLE, however, only limited options are supported by high-quality clinical evidence such as randomized controlled trials. For localized CLE lesions, topical corticosteroids and topical calcineurin inhibitors are the first choices of treatment. For widespread or severe CLE lesions and (or) cases resistant to topical treatment, systemic treatment including antimalarials and (or) short-term corticosteroids can be added on the basis of topical treatment. Notably, antimalarials are the first-line systemic treatment for all types of CLE, and can also be used in pregnant patients and pediatric patients. Second-line choices include thalidomide, retinoids, dapsone and MTX, whereas MMF is considered as third-line treatment. Finally, PDL treatment and surgery can be added as fourth-line treatment for localized, refractory lesions, whereas belimumab may be used as fourth-line treatment for widespread CLE lesions in patients with active SLE or recurrence of ACLE during tapering of corticosteroids. Nonetheless, high-quality evidence from phase 3 clinical trials is still warranted for most of these treatment measures to demonstrate their efficacy, safety

and practical value in various subtypes of CLE.

22

Declaration of competing interest

The authors declare that they have no conflict of interest.

Acknowledgement

The development of this guideline was supported by the ADA, AADV, and the Lupus Erythematosus Research Center of CSD. QL was funded by the Non-profit Central Research Institute Fund of Chinese Academy of Medical Sciences (No. 2020-RC320-003), YC was funded by the Research Unit for Evidence-Based Evaluation and Guidelines in Lanzhou University, Chinese Academy of Medical Sciences (No. 202101), and HL was supported by programs of Hunan Provincial Department of Science and Technology (No. 2018RS3031) and Hunan Provincial Health Commission (No. 2019-196) during the completion of this work. We thank Dr. Wenhui Zhou, Dr. Bingyi Yang, Dr. Xin Wang and Dr. Bo Zhang, from the Department of Dermatology, The Second Xiangya Hospital of Central South University, China, for their excellent assistance in the literature search, computer graphics and preparation for the consensus voting in the development of this guideline.

References

- [1] A. Kuhn, E. Aberer, Z. Bata-Csörgő, M. Caproni, A. Dreher, C. Frances, R. Gläser, H.W. Klötgen, A. Landmann, B. Marinovic, F. Nyberg, R. Olteanu, A. Ranki, J. C. Szepietowski, B. Vole-Platzer, S2k guideline for treatment of cutaneous lupus erythematosus - guided by the European Dermatology Forum (EDF) in cooperation with the European Academy of Dermatology and Venerology (EADV), *J. Eur. Acad. Dermatol. Venereol.* 31 (2017) 389–404, <https://doi.org/10.1111/jdv.14053>.
- [2] S. Hidayat, S. Chow, Y. Kasjmir, AADV/ASIA Recommendation for the Management of Cutaneous Lupus Erythematosus, Anak Immortal Indonesia Foundation, Indonesia, 2017.
- [3] Centre for Lupus Erythematosus Research, Chinese Society of Dermatology, Guideline for diagnosis and treatment of cutaneous lupus erythematosus, *Chin. J. Dermatol.* 52 (2019) 149–155, <https://doi.org/10.3760/cma.jissn.0412-4030.2019.03.001>.
- [4] Y. Chen, K. Yang, A. Marušić, A. Qaseem, J.J. Meerpohl, S. Flottorp, E.A. Akl, H. J. Schünemann, E.S. Chan, Y. Falck-Ytter, F. Ahmed, S. Barber, C. Chen, M. Zhang, B. Xu, J. Tian, F. Song, H. Shang, K. Tang, Q. Wang, S.L. Norris, A reporting tool for practice guidelines in health care: the RIGHT statement, *Ann. Intern. Med.* 166 (2017) 128–132, <https://doi.org/10.7326/m16-1565>.
- [5] Q. Li, H. Wu, W. Liao, M. Zhao, V. Chan, L. Li, M. Zheng, G. Chen, J. Zhang, C.-S. Lau, Q. Lu, A comprehensive review of immune-mediated dermatopathology in systemic lupus erythematosus, *J. Autoimmun.* 93 (2018), <https://doi.org/10.1016/j.jaut.2018.07.007>.
- [6] J. Tiao, R. Feng, K. Carr, J. Okawa, V.P. Werth, Using the American College of Rheumatology (ACR) and Systemic Lupus International Collaborating Clinics (SLICC) criteria to determine the diagnosis of systemic lupus erythematosus (SLE) in patients with subacute cutaneous lupus erythematosus (SCLE), *J. Am. Acad. Dermatol.* 74 (2016) 862–869, <https://doi.org/10.1016/j.jaad.2015.12.029>.
- [7] E. Bernacchi, R. Neri, M. Caproni, B. Loggini, P. Fabbri, S. Bombardieri, Annular subacute cutaneous lupus erythematosus lesions and polymyositis onset in a patient with primary Sjogren's syndrome: how should this unusual association be classified? *Lupus* 22 (2013) 312–315, <https://doi.org/10.1177/0961203312474703>.
- [8] T. Komori, A. Otsuka, T. Honda, Y. Kaku, K. Kabashima, A case of chilblain lupus erythematosus with lupus erythematosus/lichen planus overlap syndrome, *J. Eur. Acad. Dermatol. Venereol.* 31 (2017) e424–e425, <https://doi.org/10.1111/jdv.14239>.
- [9] A.L. Marano, J.M. Clarke, M.A. Morse, A. Shah, W. Barrow, M.A. Selim, R. P. Hall 3rd, A.R. Cardones, Subacute cutaneous lupus erythematosus and dermatomyositis associated with anti-programmed cell death 1 therapy, *Br. J. Dermatol.* 181 (2019) 580–583, <https://doi.org/10.1111/bjd.17245>.
- [10] R. Paule, N. Morel, V. Le Guern, M. Fredi, L. Coutte, M. Belhocine, L. Mouthon, C. le Jeunne, A. Chauvin, J.C. Piette, N. Costedoat-Chalumeau, Classification of primary antiphospholipid syndrome as systemic lupus erythematosus: analysis of a cohort of 214 patients, *Autoimmun. Rev.* 17 (2018) 866–872, <https://doi.org/10.1016/j.autrev.2018.03.011>.
- [11] H. Wu, H. Yin, H. Chen, M. Sun, X. Liu, Y. Yu, Y. Tang, H. Long, B. Zhang, J. Zhang, Y. Zhou, Y. Li, G. Zhang, P. Zhang, Y. Zhan, J. Liao, S. Luo, R. Xiao, Y. Su, J. Zhao, F. Wang, J. Zhang, W. Zhang, J. Zhang, K. Hu, L. Yuan, D. Deng, Y. Liang, B. Yang, Q. Lu, A deep learning-based smartphone platform for cutaneous lupus erythematosus classification assistance: simplifying the diagnosis of complicated diseases, *J. Am. Acad. Dermatol.* (2021), <https://doi.org/10.1016/j.jaad.2021.02.043>.

- [12] H. Wu, H. Yin, H. Chen, M. Sun, X. Liu, Y. Yu, Y. Tang, H. Long, B. Zhang, J. Zhang, Y. Zhou, Y. Li, G. Zhang, P. Zhang, Y. Zhan, J. Liao, S. Luo, R. Xiao, Y. Su, J. Zhao, F. Wang, J. Zhang, W. Zhang, J. Zhang, Q. Lu, A deep learning, image based approach for automated diagnosis for inflammatory skin diseases, *Ann. Transl. Med.* 8 (2020) 581, <https://doi.org/10.21037/atm.2020.04.39>.
- [13] M. Zhao, Y. Zhou, B. Zhu, M. Wan, T. Jiang, Q. Tan, Y. Liu, J. Jiang, S. Luo, Y. Tan, H. Wu, P. Renauer, M. Del Mar Ayala Gutiérrez, M. J. Castillo Palma, R. Ortega Castro, C. Fernández-Roldán, E. Raya, R. Faria, C. Carvalho, M. E. Alarcón-Riquelme, Z. Xiang, J. Chen, F. Li, G. Ling, H. Zhao, X. Liao, Y. Lin, A. H. Sawalha, Q. Lu, IFI44L promoter methylation as a blood biomarker for systemic lupus erythematosus, *Ann. Rheum. Dis.* 75 (2016) 1998–2006, <https://doi.org/10.1136/annrheumdis-2015-208410>.
- [14] B. Zhang, T. Zhou, H. Wu, M. Zhao, Q. Lu, Difference of IFI44L methylation and serum IFN- α 1 level among patients with discoid and systemic lupus erythematosus and healthy individuals, *J. Transl. Autoimmun.* 4 (2021) 100092, <https://doi.org/10.1016/j.jtauto.2021.100092>.
- [15] J. Albrecht, L. Taylor, J.A. Berlin, S. Dulay, G. Ang, S. Fakharzadeh, J. Kantor, E. Kim, G. Militello, K. McGinnis, S. Richardson, J. Treat, C. Vittorio, A. Van Voorhees, V.P. Werth, The CLASI (cutaneous lupus erythematosus disease area and severity index): an outcome instrument for cutaneous lupus erythematosus, *J. Invest. Dermatol.* 125 (2005) 889–894, <https://doi.org/10.1111/j.0022-202X.2005.23889.x>.
- [16] A. Kuhn, A.M. Meuth, D. Bein, S. Amler, S. Beissert, M. Böhm, R. Brehler, J. Ehrchen, S. Grundmann, M. Faust, V. Ruland, M. Schiller, P. Schulz, S. Ständer, C. Sauerland, W. Köpcke, T.A. Luger, G. Bonsmann, Revised cutaneous lupus erythematosus disease area and severity index (RCLASI): a modified outcome instrument for cutaneous lupus erythematosus, *Br. J. Dermatol.* 163 (2010) 83–92, <https://doi.org/10.1111/j.1365-2133.2010.09799.x>.
- [17] D. Bein, E. Kuehn, A.M. Meuth, S. Amler, M. Faust, F. Nyberg, C. Sauerland, T. A. Luger, G. Bonsmann, A. Kuhn, Evaluation of disease activity and damage in different subtypes of cutaneous lupus erythematosus using the CLASI, *J. Eur. Acad. Dermatol. Venereol.* 25 (2011) 652–659, <https://doi.org/10.1111/j.1468-3083.2010.03844.x>.
- [18] A. Kuhn, M. Sonntag, D. Richter-Hintz, C. Oslişo, M. Megahed, T. Ruzicka, P. Lehmann, Photostesting in lupus erythematosus: a 15-year experience, *J. Am. Acad. Dermatol.* 45 (2001) 86–95, <https://doi.org/10.1067/mjd.2001.114589>.
- [19] A. Kuhn, K. Gensch, M. Faust, A.M. Meuth, F. Boyer, P. Dupuy, P. Lehmann, D. Metzke, T. Ruzicka, Photoprotective effects of a broad-spectrum sunscreen in ultraviolet-induced cutaneous lupus erythematosus: a randomized, vehicle-controlled, double-blind study, *J. Am. Acad. Dermatol.* 64 (2011) 37–48, <https://doi.org/10.1016/j.jaad.2009.12.053>.
- [20] C. Calderon, H.D. Zucht, A. Kuhn, A. Wozniacka, J.C. Szepletowski, F. Nyberg, M. Weichenthal, A. Piantone, P. Budde, A multicenter photoprovocation study to identify potential biomarkers by global peptide profiling in cutaneous lupus erythematosus, *Lupus* 24 (2015) 1406–1420, <https://doi.org/10.1177/0961203315596077>.
- [21] N. Patsinakidis, J. Wenzel, A. Landmann, R. Koch, J. Gerf, T.A. Luger, D. Metzke, C. Surber, A. Kuhn, Suppression of UV-induced damage by a liposomal sunscreen: a prospective, open-label study in patients with cutaneous lupus erythematosus and healthy controls, *Exp. Dermatol.* 21 (2012) 958–961, <https://doi.org/10.1111/exd.12035>.
- [22] A. Kuhn, M. Hermann, S. Kleber, M. Beckmann-Welle, K. Fehsel, A. Martin-Villalba, P. Lehmann, T. Ruzicka, P.H. Kramer, V. Kolb-Bachofen, Accumulation of apoptotic cells in the epidermis of patients with cutaneous lupus erythematosus after ultraviolet irradiation, *Arthritis Rheum.* 54 (2006) 939–950, <https://doi.org/10.1002/art.21658>.
- [23] G. Heine, A. Lahl, C. Müller, M. Worm, Vitamin D deficiency in patients with cutaneous lupus erythematosus is prevalent throughout the year, *Br. J. Dermatol.* 163 (2010) 863–865, <https://doi.org/10.1111/j.1365-2133.2010.09948.x>.
- [24] E. Cutillas-Marco, M. Morales-Suárez-Varela, A. Marquina-Vila, W. Grant, Serum 25-hydroxyvitamin D levels in patients with cutaneous lupus erythematosus in a Mediterranean region, *Lupus* 19 (2010) 810–814, <https://doi.org/10.1177/0961203309360807>.
- [25] E. Cutillas-Marco, A. Marquina-Vila, W.B. Grant, J.J. Vilata-Corell, M.M. Morales-Suárez-Varela, Vitamin D and cutaneous lupus erythematosus: effect of vitamin D replacement on disease severity, *Lupus* 23 (2014) 615–623, <https://doi.org/10.1177/0961203314522338>.
- [26] A. Kuhn, J. Sigges, C. Biazar, V. Ruland, N. Patsinakidis, A. Landmann, S. Amler, G. Bonsmann, Influence of smoking on disease severity and antimalarial therapy in cutaneous lupus erythematosus: analysis of 1002 patients from the EUSCLE database, *Br. J. Dermatol.* 171 (2014) 571–579, <https://doi.org/10.1111/bjd.13006>.
- [27] F. Chasset, C. Francès, S. Barete, Z. Amoura, L. Arnaud, Influence of smoking on the efficacy of antimalarials in cutaneous lupus: a meta-analysis of the literature, *J. Am. Acad. Dermatol.* 72 (2015) 634–639, <https://doi.org/10.1016/j.jaad.2014.12.025>.
- [28] P. Boeckler, A. Cosnes, C. Francès, G. Hedelin, D. Lipsker, Association of cigarette smoking but not alcohol consumption with cutaneous lupus erythematosus, *Arch. Dermatol.* 145 (2009) 1012–1016, <https://doi.org/10.1001/archdermatol.145.9.1012>.
- [29] M.D.P. Arévalo-Bermúdez, S. Paradelo, V. Balboa-Barreiro, E. Fonseca, Cutaneous lupus erythematosus: factors related to cutaneous activity and damage in a cohort of 260 patients from A Coruña, Spain, *Lupus* 29 (2020) 1021–1030, <https://doi.org/10.1177/0961203320930094>.
- [30] Y. He, A.H. Sawalha, Drug-induced lupus erythematosus: an update on drugs and mechanisms, *Curr. Opin. Rheumatol.* 30 (2018) 490–497, <https://doi.org/10.1097/bor.0000000000000522>.
- [31] G.C. Lowe, C.L. Henderson, R.H. Grau, C.B. Hansen, R.D. Sontheimer, A systematic review of drug-induced subacute cutaneous lupus erythematosus, *Br. J. Dermatol.* 164 (2011) 465–472, <https://doi.org/10.1111/j.1365-2133.2010.10110.x>.
- [32] R. Laurinaviciene, L.H. Sandholdt, A. Bygum, Drug-induced cutaneous lupus erythematosus: 88 new cases, *Eur. J. Dermatol.* 27 (2017) 28–33, <https://doi.org/10.1684/ejd.2016.2912>.
- [33] T. Yoshimasa, A. Hiroi, K. Ueda, F. Furukawa, Discoid lupus erythematosus (DLE)-like lesion induced by uracil-tegafur (UFT), *Eur. J. Dermatol.* 11 (2001) 54–57.
- [34] A.V. Marzano, P. Vezzoli, C. Crosti, Drug-induced lupus: an update on its dermatologic aspects, *Lupus* 18 (2009) 935–940, <https://doi.org/10.1177/0961203309106176>.
- [35] L. Kawka, P. Mertz, F. Chasset, B. Lebrun-Vignes, J.E. Salem, L. Arnaud, Characterization of drug-induced cutaneous lupus: analysis of 1994 cases using the WHO pharmacovigilance database, *Autoimmun. Rev.* 20 (2021) 102705, <https://doi.org/10.1016/j.autrev.2020.102705>.
- [36] Y.Z. Ji, X.L. Mei, F.L. Wei, S.R. Liu, Y.B. Ji, A secondary discoid lupus erythematosus induced by scald of edible oil: an illustration of Koebner phenomenon, *J. Cosmet. Dermatol.* 19 (2020) 1699–1701, <https://doi.org/10.1111/jocd.13189>.
- [37] R.F. Wang, M. Maher, C. Chung, J.A. Kaffenberger, Koebner phenomenon of discoid lupus erythematosus on old tattoos, *Lupus* 28 (2019) 241–243, <https://doi.org/10.1177/0961203318815578>.
- [38] M. Jolly, Discoid lupus erythematosus after tattoo: Koebner phenomenon, *Arthritis Rheum.* 53 (2005) 627, <https://doi.org/10.1002/art.21334>.
- [39] A. Lukacs, S. Karpati, E. Temesvari, Nickel-induced Koebner phenomenon in chronic cutaneous lupus erythematosus, *J. Dtsch Dermatol Ges* 9 (2011) 475–476, <https://doi.org/10.1111/j.1610-0387.2010.07589.x>.
- [40] E. Berger, M. Robinson, R. Patel, A.G. Franks Jr., Koebner phenomenon to heat in cutaneous (discoid) lupus erythematosus (lupus ab-igne), *Dermatol. Online J.* 18 (2012) 17.
- [41] M. Petri, M.Y. Kim, K.C. Kalunian, J. Grossman, B.H. Hahn, L.R. Sammaritano, M. Lockshin, J.T. Merrill, H.M. Belmont, A.D. Askanaase, W.J. McCune, M. Heath-Holmes, M.A. Dooley, J. Von Feldt, A. Friedman, M. Tan, J. Davis, M. Cronin, B. Diamond, M. Mackay, L. Sigler, M. Fillius, A. Rupel, F. Licciardi, J.P. Buyon, Combined oral contraceptives in women with systemic lupus erythematosus, *N. Engl. J. Med.* 353 (2005) 2550–2558, <https://doi.org/10.1056/NEJMoa051135>.
- [42] J. Sánchez-Guerrero, A.G. Uribe, L. Jiménez-Santana, M. Mestanza-Peralta, P. Lara-Reyes, A.H. Seuc, M.D. Cravioto, A trial of contraceptive methods in women with systemic lupus erythematosus, *N. Engl. J. Med.* 353 (2005) 2539–2549, <https://doi.org/10.1056/NEJMoa050817>.
- [43] A. Rojas-Villarraga, J.V. Torres-Gonzalez, M. Ruiz-Sternberg, Safety of hormonal replacement therapy and oral contraceptives in systemic lupus erythematosus: a systematic review and meta-analysis, *PLoS One* 9 (2014), e104303, <https://doi.org/10.1371/journal.pone.0104303>.
- [44] A.B. Patel, C.L. Hallemeier, I.A. Petersen, A.W. Jensen, T.G. Osborn, R.C. Miller, Acute and late toxicities of radiotherapy for patients with discoid lupus erythematosus: a retrospective case-control study, *Radiat. Oncol.* 7 (2012) 22, <https://doi.org/10.1186/1748-717x-7-22>.
- [45] V. Benk, A. Al-Herz, D. Gladman, M. Urowitz, P.R. Fortin, Role of radiation therapy in patients with a diagnosis of both systemic lupus erythematosus and cancer, *Arthritis Rheum.* 53 (2005) 67–72, <https://doi.org/10.1002/art.20912>.
- [46] E. Durmaz, B. Atalar, E. Sezer, E. Ozyar, E.D. Çetin, Cutaneous lupus erythematosus induced by radiotherapy for breast carcinoma, *J. Dtsch Dermatol Ges* 17 (2019) 832–833, <https://doi.org/10.1111/ddg.13888>.
- [47] I. Kolm, E. Pawlik, N. Eggmann, J. Kamarachev, K. Kerl, L.E. French, G. F. Hofbauer, Subacute cutaneous lupus erythematosus triggered by radiotherapy, *Case Rep. Dermatol.* 5 (2013) 232–236, <https://doi.org/10.1159/000354721>.
- [48] S. Jessop, D.A. Whitelaw, M.J. Grainge, P. Jayasekera, Drugs for discoid lupus erythematosus, *Cochrane Database Syst. Rev.* 5 (2017) CD002954, <https://doi.org/10.1002/14651858.CD002954.pub3>.
- [49] H.H. Roenigk Jr., J.S. Martin, P. Eichorn, J.N. Gilliam, Discoid lupus erythematosus. Diagnostic features and evaluation of topical corticosteroid therapy, *Cutis* 25 (1980) 281–285.
- [50] B. Barikbin, S. Givrad, M. Yousefi, F. Eskandari, Pimecrolimus 1% cream versus betamethasone 17-valerate 0.1% cream in the treatment of facial discoid lupus erythematosus: a double-blind, randomized pilot study, *Clin. Exp. Dermatol.* 34 (2009) 776–780, <https://doi.org/10.1111/j.1365-2230.2008.03138.x>.
- [51] P. Pothinanthong, P. Janjumsang, A comparative study in efficacy and safety of 0.1% tacrolimus and 0.05% clobetasol propionate ointment in discoid lupus erythematosus by modified cutaneous lupus erythematosus disease area and severity index, *J. Med. Assoc. Thai.* 95 (2012) 933–940.
- [52] H. Shi, J.E. Gudjonsson, J.M. Kahlenberg, Treatment of cutaneous lupus erythematosus: current approaches and future strategies, *Curr. Opin. Rheumatol.* 32 (2020) 208–214, <https://doi.org/10.1097/BOR.0000000000000704>.
- [53] L.G. Okon, V.P. Werth, Cutaneous lupus erythematosus: diagnosis and treatment, *Best Pract. Res. Clin. Rheumatol.* 27 (2013) 391–404, <https://doi.org/10.1016/j.berh.2013.07.008>.
- [54] A.Y. Chang, V.P. Werth, Treatment of cutaneous lupus, *Curr. Rheumatol. Rep.* 13 (2011) 300–307, <https://doi.org/10.1007/s11926-011-0180-z>.

- [55] D.P. McCauliffe, Cutaneous lupus erythematosus, *Semin. Cutan. Med. Surg.* 20 (2001) 14–26, <https://doi.org/10.1053/sder.2001.23091>.
- [56] A. Kuhn, K. Gensch, M. Faust, S.W. Schneider, G. Bonsmann, N. Gaebele-Wissing, P. Lehmann, A. Wons, P. Reitmeir, V. Ruland, T.A. Luger, T. Ruzicka, Efficacy of tacrolimus 0.1% ointment in cutaneous lupus erythematosus: a multicenter, randomized, double-blind, vehicle-controlled trial, *J. Am. Acad. Dermatol.* 65 (2011) 54–64, <https://doi.org/10.1016/j.jaad.2010.03.037>, 64 e51–52.
- [57] X. Wang, L. Zhang, J. Luo, Z. Wu, Y. Mei, Y. Wang, X. Li, W. Wang, H. Zhou, Tacrolimus 0.03% ointment in labial discoid lupus erythematosus: a randomized, controlled clinical trial, *J. Clin. Pharmacol.* 55 (2015) 1221–1228, <https://doi.org/10.1002/jcph.537>.
- [58] V. Madan, P.J. August, R.J. Chalmers, Efficacy of topical tacrolimus 0.3% in clobetasol propionate 0.05% ointment in therapy-resistant cutaneous lupus erythematosus: a cohort study, *Clin. Exp. Dermatol.* 35 (2010) 27–30, <https://doi.org/10.1111/j.1365-2230.2009.03351.x>.
- [59] A. Kreuter, T. Gambichler, F. Breuckmann, F.M. Pawlak, M. Stucker, A. Bader, P. Altmeier, M. Freitag, Pimecrolimus 1% cream for cutaneous lupus erythematosus, *J. Am. Acad. Dermatol.* 51 (2004) 407–410, <https://doi.org/10.1016/j.jaad.2004.01.044>.
- [60] A. Tlacuilo-Parra, E. Guevara-Gutierrez, F. Gutierrez-Murillo, A. Soto-Ortiz, F. Barba-Gomez, M. Hernandez-Torres, M. Salazar-Paramo, Pimecrolimus 1% cream for the treatment of discoid lupus erythematosus, *Rheumatology* 44 (2005) 1564–1568, <https://doi.org/10.1093/rheumatology/kei093>.
- [61] E. Seiger, S. Roland, S. Goldman, Cutaneous lupus treated with topical tretinoin: a case report, *Cutis* 47 (1991) 351–355.
- [62] M. Terao, S. Matsui, I. Katayama, Two cases of refractory discoid lupus erythematosus successfully treated with topical coretinolate, *Dermatol. Online J.* 17 (2011) 15.
- [63] K.R. Edwards, W.A. Burke, Treatment of localized discoid lupus erythematosus with tazarotene, *J. Am. Acad. Dermatol.* 41 (1999) 1049–1050, [https://doi.org/10.1016/s0190-9622\(99\)70278-1](https://doi.org/10.1016/s0190-9622(99)70278-1).
- [64] P. Perknimitr, N. Tekacharin, R. Panchaprateep, J. Wittitsuwannakul, P. Tangtanatakul, N. Hirankarn, P. Asawanonda, Pulsed-dye laser as an adjuvant treatment for discoid lupus erythematosus: a randomized, controlled trial, *J. Dermatol. Treat.* 30 (2019) 81–86, <https://doi.org/10.1080/09546634.2018.1468063>.
- [65] P. García-Montero, R. Pérez-Mesoner, A. Barrutiá-Borque, P. Boixeda, Usefulness of pulsed dye laser in cutaneous lupus erythematosus, *Actas Dermosifiliogr* 110 (2019) 398–399, <https://doi.org/10.1016/j.ad.2018.03.020>.
- [66] S. Brás, B. Gonzalez, G. Segurado-Miravalles, P. Boixeda, Treatment of lupus erythematosus of the eyelids with pulsed dye laser, *Laser Med. Sci.* 33 (2018) 215–219, <https://doi.org/10.1007/s10103-016-2131-4>.
- [67] M.T. Díez, P. Boixeda, C. Moreno, J.A. Gonzalez, M.L. Zamorano, P.J. Olasolo, Histopathology and immunohistochemistry of cutaneous lupus erythematosus after pulsed dye laser treatment, *Dermatol. Surg.* 37 (2011) 971–981, <https://doi.org/10.1111/j.1524-4725.2011.02041.x>.
- [68] M.T. Truchuelo, P. Boixeda, J. Alcántara, C. Moreno, E. de las Heras, P.J. Olasolo, Pulsed dye laser as an excellent choice of treatment for lupus tumidus: a prospective study, *J. Eur. Acad. Dermatol. Venereol.* 26 (2012) 1272–1279, <https://doi.org/10.1111/j.1468-3083.2011.04281.x>.
- [69] M.P. Ekbäck, A. Troilius, Laser therapy for refractory discoid lupus erythematosus when everything else has failed, *J. Cosmet. Laser Ther. : Off. Publ. Eur. Soc. Laser Dermatol.* 15 (2013) 260–265, <https://doi.org/10.3109/14764172.2013.787802>.
- [70] O. Yélanos, E. Roé, E. Baselga, L. Puig, Pediatric cutaneous lupus erythematosus treated with pulsed dye laser, *Pediatr. Dermatol.* 31 (2014) 113–115, <https://doi.org/10.1111/pde.12248>.
- [71] A. Erceg, H.J. Bovenschen, P.C. van de Kerckhof, E.M. de Jong, M.M. Seyger, Efficacy and safety of pulsed dye laser treatment for cutaneous discoid lupus erythematosus, *J. Am. Acad. Dermatol.* 60 (2009) 626–632, <https://doi.org/10.1016/j.jaad.2008.11.904>.
- [72] O. Baniandrés, P. Boixeda, P. Belmar, A. Pérez, Treatment of lupus erythematosus with pulsed dye laser, *Laser Surg. Med.* 32 (2003) 327–330, <https://doi.org/10.1002/lsm.10169>.
- [73] C. Raulin, C. Schmidt, S. Hellwig, Cutaneous lupus erythematosus-treatment with pulsed dye laser, *Br. J. Dermatol.* 141 (1999) 1046–1050, <https://doi.org/10.1046/j.1365-2133.1999.03203.x>.
- [74] M. Núñez, P. Boixeda, E.S. Miralles, R.F. de Misa, A. Ledo, Pulsed dye laser treatment of telangiectatic chronic erythema of cutaneous lupus erythematosus, *Arch. Dermatol.* 132 (1996) 354–355.
- [75] M. Núñez, P. Boixeda, E.S. Miralles, R.F. de Misa, A. Ledo, Pulsed dye laser treatment in lupus erythematosus telangiectoides, *Br. J. Dermatol.* 133 (1995) 1010–1011, <https://doi.org/10.1111/j.1365-2133.1995.tb06945.x>.
- [76] N. Yokogawa, H. Eto, A. Tanikawa, T. Ikeda, K. Yamamoto, T. Takahashi, H. Mizukami, T. Sato, N. Yokota, F. Furukawa, Effects of hydroxychloroquine in patients with cutaneous lupus erythematosus: a multicenter, double-blind, randomized, parallel-group trial, *Arthritis Rheum.* 69 (2017) 791–799, <https://doi.org/10.1002/art.40018>.
- [77] T. Ruzicka, C. Sommerburg, G. Goerz, P. Kind, H. Mensing, Treatment of cutaneous lupus erythematosus with acitretin and hydroxychloroquine, *Br. J. Dermatol.* 127 (1992) 513–518, <https://doi.org/10.1111/j.1365-2133.1992.tb14851.x>.
- [78] E.L. Bezerra, M.J. Vilar, P.B. da Trindade Neto, E.I. Sato, Double-blind, randomized, controlled clinical trial of clofazimine compared with chloroquine in patients with systemic lupus erythematosus, *Arthritis Rheum.* 52 (2005) 3073–3078, <https://doi.org/10.1002/art.21358>.
- [79] J. Sigges, C. Biazar, A. Landmann, V. Ruland, N. Patsinakis, S. Amler, G. Bonsmann, A. Kuhn, E. Co-Authors, Therapeutic strategies evaluated by the European society of cutaneous lupus erythematosus (EUSCLE) Core set Questionnaire in more than 1000 patients with cutaneous lupus erythematosus, *Autoimmun. Rev.* 12 (2013) 694–702, <https://doi.org/10.1016/j.autrev.2012.10.005>.
- [80] Y. Ootake, Y. Yamaguchi, M. Kanaoka, A. Akita, N. Ikeda, M. Aihara, Varied responses to and efficacies of hydroxychloroquine treatment according to cutaneous lupus erythematosus subtypes in Japanese patients, *J. Dermatol.* 46 (2019) 285–289, <https://doi.org/10.1111/1346-8138.14802>.
- [81] R.B. Melles, M.F. Marmor, The risk of toxic retinopathy in patients on long-term hydroxychloroquine therapy, *JAMA Ophthalmol* 132 (2014) 1453–1460, <https://doi.org/10.1001/jamaophthalmol.2014.3459>.
- [82] M.F. Marmor, U. Kellner, T.Y. Lai, R.B. Melles, W.F. Mieler, O. American Academy of, Recommendations on screening for chloroquine and hydroxychloroquine retinopathy (2016 revision), *Ophthalmology* 123 (2016) 1386–1394, <https://doi.org/10.1016/j.ophtha.2016.01.058>.
- [83] C. Fiehn, T. Ness, C. Weseloh, C. Specker, D. Hadjiski, J. Detert, K. Kruger, D.G. K. Pharmakotherapie, Safety management in treatment with antimalarials in rheumatology. Interdisciplinary recommendations on the basis of a systematic literature review, *Zeitschrift Rheumatol.* (2020), <https://doi.org/10.1007/s00393-020-00785-4>.
- [84] A.Y. Chang, E.W. Piette, K.P. Foering, T.R. Tenhave, J. Okawa, V.P. Werth, Response to antimalarial agents in cutaneous lupus erythematosus: a prospective analysis, *Arch. Dermatol.* 147 (2011) 1261–1267, <https://doi.org/10.1001/archdermatol.2011.191>.
- [85] O. Brandt, A. Rieger, A. Geusau, G. Stingl, Peas, beans, and the Pythagorean theorem - the relevance of glucose-6-phosphate dehydrogenase deficiency in dermatology, *J Dtsch Dermatol Ges* 6 (2008) 534–539, <https://doi.org/10.1111/j.1610-0387.2008.06640.x>.
- [86] R.R. Winkelmann, G.K. Kim, J.Q. Del Rosso, Treatment of cutaneous lupus erythematosus: review and assessment of treatment benefits based on oxford Centre for evidence-based medicine criteria, *J Clin Aesthet Dermatol* 6 (2013) 27–38.
- [87] C.B. Hansen, K.W. Dahle, Cutaneous lupus erythematosus, *Dermatol. Ther.* 25 (2012) 99–111, <https://doi.org/10.1111/j.1529-8019.2012.01508.x>.
- [88] J.M. Albaun, L.E. Levesque, A.S. Gershon, G. Liu, S.M. Cadarette, Glucocorticoid-induced osteoporosis management among seniors, by year, sex, and indication, 1996–2012, *Osteoporos. Int.* 26 (2015) 2845–2852, <https://doi.org/10.1007/s00198-015-3200-4>.
- [89] A. Kuhn, E. Aberer, Z. Bata-Csorgo, M. Caproni, A. Dreher, C. Frances, R. Glaser, H.W. Klotgen, A. Landmann, B. Marinovic, F. Nyberg, R. Olteanu, A. Ranki, J. C. Szepletowski, B. Volc-Platzer, S2k guideline for treatment of cutaneous lupus erythematosus - guided by the European Dermatology Forum (EDF) in cooperation with the European Academy of Dermatology and Venereology (EADV), *J. Eur. Acad. Dermatol. Venereol.* 31 (2017) 389–404, <https://doi.org/10.1111/jdv.14053>.
- [90] J. Cortes-Hernandez, M. Torres-Salido, J. Castro-Marrero, M. Vilardell-Tarres, J. Ordi-Ros, Thalidomide in the treatment of refractory cutaneous lupus erythematosus: prognostic factors of clinical outcome, *Br. J. Dermatol.* 166 (2012) 616–623, <https://doi.org/10.1111/j.1365-2133.2011.10693.x>.
- [91] K.P. Kyriakis, G.J. Kontochristopoulos, D.N. Panteleos, Experience with low-dose thalidomide therapy in chronic discoid lupus erythematosus, *Int. J. Dermatol.* 39 (2000) 218–222, <https://doi.org/10.1046/j.1365-4362.2000.00953.x>.
- [92] J. Ordi-Ros, F. Cortes, E. Cucurull, M. Mauri, S. Bujan, M. Vilardell, Thalidomide in the treatment of cutaneous lupus refractory to conventional therapy, *J. Rheumatol.* 27 (2000) 1429–1433.
- [93] R.J. Stevens, C. Andujar, C.J. Edwards, P.R. Ames, A.R. Barwick, M. A. Khamashta, G.R. Hughes, Thalidomide in the treatment of the cutaneous manifestations of lupus erythematosus: experience in sixteen consecutive patients, *Br. J. Rheumatol.* 36 (1997) 353–359, <https://doi.org/10.1093/rheumatology/36.3.353>.
- [94] M.J. Cuadrado, Y. Karim, G. Sanna, E. Smith, M.A. Khamashta, G.R. Hughes, Thalidomide for the treatment of resistant cutaneous lupus: efficacy and safety of different therapeutic regimens, *Am. J. Med.* 118 (2005) 246–250, <https://doi.org/10.1016/j.amjmed.2004.04.030>.
- [95] J.L. Fairley, S. Oon, A.M. Saracino, M. Nikpour, Management of cutaneous manifestations of lupus erythematosus: a systematic review, *Semin. Arthritis Rheum.* 50 (2020) 95–127, <https://doi.org/10.1016/j.semarthrit.2019.07.010>.
- [96] J. Cortes-Hernandez, G. Avila, M. Vilardell-Tarres, J. Ordi-Ros, Efficacy and safety of lenalidomide for refractory cutaneous lupus erythematosus, *Arthritis Res. Ther.* 14 (2012) R265, <https://doi.org/10.1186/ar4111>.
- [97] S.A. Kindle, D.A. Wetter, M.D. Davis, M.R. Pittelkow, G.F. Sciallis, Lenalidomide treatment of cutaneous lupus erythematosus: the Mayo Clinic experience, *Int. J. Dermatol.* 55 (2016) e431–439, <https://doi.org/10.1111/ijd.13226>.
- [98] D. Gensburger, M. Kawashima, H. Marotte, J. Kanitakis, P. Miossec, Lupus erythematosus with leflunomide: induction or reactivation? *Ann. Rheum. Dis.* 64 (2005) 153–155, <https://doi.org/10.1136/ard.2003.019323>.
- [99] L.A. Drake, S.M. Dinehart, E.R. Farmer, R.W. Goltz, G.F. Graham, M. K. Hordinsky, C.W. Lewis, D.M. Pariser, J.W. Skouge, S.B. Webster, D. C. Whitaker, B. Butler, B.J. Lowery, R.D. Sontheimer, J.P. Callen, C. Camisa, T. T. Provost, D.L. Tuffanelli, Guidelines of care for cutaneous lupus erythematosus, *American Academy of Dermatology, J. Am. Acad. Dermatol.* 34 (1996) 830–836.

- [100] A.M. D'Erme, N. Milanese, E.M. Difonzo, T. Lotti, M. Gola, Treatment of refractory subacute cutaneous lupus erythematosus with oral isotretinoin: a valid therapeutic option, *Dermatol. Ther.* 25 (2012) 281–282, <https://doi.org/10.1111/j.1529-8019.2012.01461.x>.
- [101] J.K. Shornick, N. Formica, A.L. Parke, Isotretinoin for refractory lupus erythematosus, *J. Am. Acad. Dermatol.* 24 (1991) 49–52, [https://doi.org/10.1016/0190-9622\(91\)70008-p](https://doi.org/10.1016/0190-9622(91)70008-p).
- [102] D.J. Rubenstein, A.C. Huntley, Keratotic lupus erythematosus: treatment with isotretinoin, *J. Am. Acad. Dermatol.* 14 (1986) 910–914, [https://doi.org/10.1016/s0190-9622\(86\)70111-4](https://doi.org/10.1016/s0190-9622(86)70111-4).
- [103] N. Al-Mutairi, M. Rijhwani, O. Nour-Eldin, Hypertrophic lupus erythematosus treated successfully with acitretin as monotherapy, *J. Dermatol.* 32 (2005) 482–486, <https://doi.org/10.1111/j.1346-8138.2005.tb00785.x>.
- [104] T. Ruzicka, M. Meurer, T. Bieber, Efficiency of acitretin in the treatment of cutaneous lupus erythematosus, *Arch. Dermatol.* 124 (1988) 897–902.
- [105] T. de Risi-Pugliese, F. Cohen Aubart, J. Haroche, P. Moguelet, S. Grootenboer-Mignot, A. Mathian, S. Ingen-Housz-Oro, M. Hie, N. Wendremaire, F. Aucouturier, F. Lepelletier, M. Miyara, B. Bader-Meuiner, P. Remy, N. Fabien, C. Frances, S. Baréte, Z. Amoura, Clinical, histological, immunological presentations and outcomes of bullous systemic lupus erythematosus: 10 New cases and a literature review of 118 cases, *Semin. Arthritis Rheum.* 48 (2018) 83–89, <https://doi.org/10.1016/j.semarthrit.2017.11.003>.
- [106] E. Zampeli, H.M. Moutsopoulos, Dapsone: an old drug effective for subacute cutaneous lupus erythematosus, *Rheumatology* 58 (2019) 920–921, <https://doi.org/10.1093/rheumatology/key434>.
- [107] A.C. Garza-Mayers, M. McClurkin, G.P. Smith, Review of treatment for discoid lupus erythematosus, *Dermatol. Ther.* 29 (2016) 274–283, <https://doi.org/10.1111/dth.12358>.
- [108] P. Fabbri, C. Cardinali, B. Giomi, M. Caproni, Cutaneous lupus erythematosus: diagnosis and management, *Am. J. Clin. Dermatol.* 4 (2003) 449–465, <https://doi.org/10.2165/00128071-200304070-00002>.
- [109] M. Klebes, N. Wutte, E. Aberer, Dapsone as second-line treatment for cutaneous lupus erythematosus? A retrospective analysis of 34 patients and a review of the literature, *Dermatology* 232 (2016) 91–96, <https://doi.org/10.1159/000441054>.
- [110] H. Ujiie, T. Shimizu, M. Ito, K. Arita, H. Shimizu, Lupus erythematosus profundus successfully treated with dapsone: review of the literature, *Arch. Dermatol.* 142 (2006) 399–401, <https://doi.org/10.1001/archderm.142.3.399>.
- [111] F.R. Zhang, H. Liu, A. Irwanto, X.A. Fu, Y. Li, G.Q. Yu, Y.X. Yu, M.F. Chen, H. Q. Low, J.H. Li, F.F. Bao, J.N. Foo, J.X. Bei, X.M. Jia, J. Liu, H. Liang, N. Wang, G. Y. Niu, Z.Z. Wang, B.Q. Shi, H.Q. Tian, H.X. Liu, S.S. Ma, Y. Zhou, J.B. You, Q. Yang, C. Wang, T.S. Chu, D.C. Liu, X.L. Yu, Y.H. Sun, Y. Ning, Z.H. Wei, S. L. Chen, X.C. Chen, Z.X. Zhang, Y.X. Liu, S.L. Pulit, W.B. Wu, Z.Y. Zheng, R. D. Yang, H. Long, Z.S. Liu, J.Q. Wang, M. Li, L.H. Zhang, H. Wang, L.M. Wang, P. Xiao, J.L. Li, Z.M. Huang, J.X. Huang, Z. Li, J. Liu, L. Xiong, J. Yang, X. D. Wang, D.B. Yu, X.M. Lu, G.Z. Zhou, L.B. Yan, J.P. Shen, G.C. Zhang, Y.X. Zeng, P.I. de Bakker, S.M. Chen, J.J. Liu, HLA-B*13:01 and the dapsone hypersensitivity syndrome, *N. Engl. J. Med.* 369 (2013) 1620–1628, <https://doi.org/10.1056/NEJMoa1213096>.
- [112] M.N. Islam, M. Hossain, S.A. Haq, M.N. Alam, P.M. Ten Klooster, J.J. Rasker, Efficacy and safety of methotrexate in articular and cutaneous manifestations of systemic lupus erythematosus, *Int J Rheum Dis* 15 (2012) 62–68, <https://doi.org/10.1111/j.1756-185X.2011.01665.x>.
- [113] J. Wenzel, S. Brähler, R. Bauer, T. Bieber, T. Tüting, Efficacy and safety of methotrexate in recalcitrant cutaneous lupus erythematosus: results of a retrospective study in 43 patients, *Br. J. Dermatol.* 153 (2005) 157–162, <https://doi.org/10.1111/j.1365-2133.2005.06552.x>.
- [114] I.B. Boehm, G.A. Boehm, R. Bauer, Management of cutaneous lupus erythematosus with low-dose methotrexate: indication for modulation of inflammatory mechanisms, *Rheumatol. Int.* 18 (1998) 59–62, <https://doi.org/10.1007/s002960050058>.
- [115] J. Wenzel, S. Brähler, R. Bauer, T. Bieber, T. Tüting, Efficacy and safety of methotrexate in recalcitrant cutaneous lupus erythematosus: results of a retrospective study in 43 patients, *Br. J. Dermatol.* 153 (2005) 157–162, <https://doi.org/10.1111/j.1365-2133.2005.06552.x>.
- [116] A. Al-Dabagh, S.A. Davis, M.A. Kinney, K. Huang, S.R. Feldman, The effect of folic acid supplementation on methotrexate efficacy and toxicity in psoriasis patients and folic acid use by dermatologists in the USA, *Am. J. Clin. Dermatol.* 14 (2013) 155–161, <https://doi.org/10.1007/s40257-013-0017-9>.
- [117] J.S. Smolen, R. Landewe, J. Bijlsma, G. Burmester, K. Chatzidionysiou, M. Dougados, J. Nam, S. Ramiro, M. Voshaar, R. van Vollenhoven, D. Aletaha, M. Aringer, M. Boers, C.D. Buckley, F. Buttgerit, V. Bykerk, M. Cardiel, B. Combe, M. Cutolo, Y. van Eijk-Hustings, P. Emery, A. Finckh, C. Gabay, J. Gomez-Reino, L. Gossec, J.E. Gottenberg, J.M.W. Hazes, T. Huizinga, M. Jani, D. Karateev, M. Kouloumas, T. Kvien, Z. Li, X. Mariette, I. McInnes, E. Mysler, P. Nash, K. Pavelka, G. Poor, C. Richez, P. van Riel, A. Rubbert-Roth, K. Saag, J. da Silva, T. Stamm, T. Takeuchi, R. Westhovens, M. de Wit, D. van der Heijde, EULAR recommendations for the management of rheumatoid arthritis with synthetic and biological disease-modifying antirheumatic drugs: 2016 update, *Ann. Rheum. Dis.* 76 (2017) 960–977, <https://doi.org/10.1136/annrheumdis-2016-210715>.
- [118] B. Shea, M.V. Swinden, E.T. Ghogomu, Z. Ortiz, W. Katchamart, T. Rader, C. Bombardier, G.A. Wells, P. Tugwell, Folic acid and folic acid for reducing side effects in patients receiving methotrexate for rheumatoid arthritis, *J. Rheumatol.* 41 (2014) 1049–1060, <https://doi.org/10.3899/jrheum.130738>.
- [119] C.K. Li, K. Baker, T. Jones, E. Coulson, A. Roberts, F. Birrell, Safety and tolerability of subcutaneous methotrexate in routine clinical practice, *Arthritis Care Res.* (2020), <https://doi.org/10.1002/acr.24334>.
- [120] N.M. Hanjani, C.H. Nousari, Mycophenolate mofetil for the treatment of cutaneous lupus erythematosus with smoldering systemic involvement, *Arch. Dermatol.* 138 (2002) 1616–1618, <https://doi.org/10.1001/archderm.138.12.1616>.
- [121] B. Gammon, C. Hansen, M.I. Cosmer, Efficacy of mycophenolate mofetil in antimalarial-resistant cutaneous lupus erythematosus, *J. Am. Acad. Dermatol.* 65 (2011) 717–721, <https://doi.org/10.1016/j.jaad.2010.08.011>, e712.
- [122] A. Kreuter, N.S. Tomi, S.M. Weiner, M. Huger, P. Altmeyer, T. Gambichler, Mycophenolate sodium for subacute cutaneous lupus erythematosus resistant to standard therapy, *Br. J. Dermatol.* 156 (2007) 1321–1327, <https://doi.org/10.1111/j.1365-2133.2007.07826.x>.
- [123] R. Salle, F. Chasset, D. Kottler, C. Picard-Dahan, A. Jannic, N. Mekki, T. De Risi-Pugliese, J.B. Monfort, A. Barbaud, C. Frances, V. Descamps, Belimumab for refractory manifestations of cutaneous lupus: a multicenter, retrospective observational study of 16 patients, *J. Am. Acad. Dermatol.* 83 (2020) 1816–1819, <https://doi.org/10.1016/j.jaad.2020.05.058>.
- [124] F. Zhang, S.C. Bae, D. Bass, M. Chu, S. Egginton, D. Gordon, D.A. Roth, J. Zheng, Y. Tanaka, A pivotal phase III, randomised, placebo-controlled study of belimumab in patients with systemic lupus erythematosus located in China, Japan and South Korea, *Ann. Rheum. Dis.* 77 (2018) 355–363, <https://doi.org/10.1136/annrheumdis-2017-211631>.
- [125] L. Andreoli, G.K. Bertias, N. Agmon-Levin, S. Brown, R. Cervera, N. Costedoat-Chalumeau, A. Doria, R. Fischer-Betz, F. Forger, M.F. Moraes-Fontes, M. Khamashta, J. King, A. Lojaccono, F. Marchiori, P.L. Meroni, M. Mosca, M. Motta, M. Ostensen, C. Pamfil, L. Raio, M. Schneider, E. Svenungsson, M. Tektonidou, S. Yavuz, D. Boumpas, A. Tinca, EULAR recommendations for women's health and the management of family planning, assisted reproduction, pregnancy and menopause in patients with systemic lupus erythematosus and/or antiphospholipid syndrome, *Ann. Rheum. Dis.* 76 (2017) 476–485, <https://doi.org/10.1136/annrheumdis-2016-209770>.
- [126] R.A. Levy, V.S. Vilela, M.J. Cataldo, R.C. Ramos, J.L. Duarte, B.R. Tura, E. M. Albuquerque, N.R. Jesus, Hydroxychloroquine (HCQ) in lupus pregnancy: double-blind and placebo-controlled study, *Lupus* 10 (2001) 401–404, <https://doi.org/10.1191/096120301678646137>.
- [127] A.S. Al Arfaj, N. Khalil, Pregnancy outcome in 396 pregnancies in patients with SLE in Saudi Arabia, *Lupus* 19 (2010) 1665–1673, <https://doi.org/10.1177/0961203310378669>.
- [128] K. Palmsten, G. Bandoli, J. Watkins, G. Vazquez-Benitez, T.P. Gilmer, C. D. Chambers, Oral corticosteroids and risk of preterm birth in the California Medicaid program, *J. Allergy Clin Immunol Pract* 9 (2021) 375–384, <https://doi.org/10.1016/j.jaip.2020.07.047>, e375.
- [129] C.C. Chi, S.H. Wang, F. Wojnarowska, G. Kirtschig, E. Davies, C. Bennett, Safety of topical corticosteroids in pregnancy, *Cochrane Database Syst. Rev.* (2015) CD007346, <https://doi.org/10.1002/14651858.CD007346.pub3>.
- [130] N.A. Undre, F.J. Moloney, S. Ahmadi, P. Stevenson, G.M. Murphy, Skin and systemic pharmacokinetics of tacrolimus following topical application of tacrolimus ointment in adults with moderate to severe atopic dermatitis, *Br. J. Dermatol.* 160 (2009) 665–669, <https://doi.org/10.1111/j.1365-2133.2008.08974.x>.
- [131] L. Colla, D. Diena, M. Rossetti, A.M. Manzione, L. Marozio, C. Benedetto, L. Biancone, Immunosuppression in pregnant women with renal disease: review of the latest evidence in the biologics era, *J. Nephrol.* 31 (2018) 361–383, <https://doi.org/10.1007/s40620-018-0477-3>.
- [132] A.L. Williams, N.D. Pace, J.M. DeSesso, Teratogen update: topical use and third-generation retinoids, *Birth Defects Res* 112 (2020) 1105–1114, <https://doi.org/10.1002/bdr2.1745>.
- [133] W.A. Shroukh, D.T. Steinke, S.C. Willis, Risk management of teratogenic medicines: a systematic review, *Birth Defects Res* 112 (2020) 1755–1786, <https://doi.org/10.1002/bdr2.1799>.
- [134] A. Godron-Dubrasquet, J.B. Woillard, S. Decramer, M. Fila, V. Guignon, S. Tellier, D. Morin, M. Sordet, F. Saint-Marcoux, J. Harambat, Mycophenolic acid area under the concentration-time curve is associated with therapeutic response in childhood-onset lupus nephritis, *Pediatr. Nephrol.* (2020), <https://doi.org/10.1007/s00467-020-04733-x>.
- [135] D. Buonsenso, D. Serranti, P. Valentini, Management of central nervous system tuberculosis in children: light and shade, *Eur. Rev. Med. Pharmacol. Sci.* 14 (2010) 845–853.
- [136] C.S. Yang, C. Kim, R.J. Antaya, Review of thalidomide use in the pediatric population, *J. Am. Acad. Dermatol.* 72 (2015) 703–711, <https://doi.org/10.1016/j.jaad.2015.01.002>.
- [137] T. Aoki, T. Ishizawa, Y. Hozumi, K. Aso, S. Kondo, Chilblain lupus erythematosus of Hutchinson responding to surgical treatment: a report of two patients with anti-Ro/SS-A antibodies, *Br. J. Dermatol.* 134 (1996) 533–537.
- [138] N. di Meo, M. Schiavon, L. Quaranta, C. Fluehler, G. Trevisan, Medical and surgical treatment for discoid lupus erythematosus, *Acta Dermatovenerol. Croat.* 18 (2010) 163–165.
- [139] V. Le Guern, G. Guettrot-Imbert, N. Costedoat-Chalumeau, [The pre-pregnancy counseling], *Rev. Med. Interne* 36 (2015) 151–153, <https://doi.org/10.1016/j.revmed.2014.07.012>.
- [140] G. Guettrot-Imbert, N. Morel, V. Le Guern, G. Plu-Bureau, C. Frances, N. Costedoat-Chalumeau, Pregnancy and contraception in systemic and cutaneous lupus erythematosus, *Ann. Dermatol. Venereol.* 143 (2016) 590–600, <https://doi.org/10.1016/j.annder.2015.07.015>.

- [141] N. Morel, S. Georjin-Lavialle, K. Levesque, G. Guettrot-Imbert, V. Le Guern, J. Le Bidois, B. Bessières, C. Brouzes, D. Le Mercier, E. Villain, A. Maltret, N. Costedoat-Chalumeau, [Neonatal lupus syndrome: literature review], *Rev. Med. Interne* 36 (2015) 159–166, <https://doi.org/10.1016/j.revmed.2014.07.013>.
- [142] M. Aringer, K. Costenbader, D. Daikh, R. Brinks, M. Mosca, R. Ramsey-Goldman, J.S. Smolen, D. Wofsy, D.T. Boumpas, D.L. Kamen, D. Jayne, R. Cervera, N. Costedoat-Chalumeau, B. Diamond, D.D. Gladman, B. Hahn, F. Hiepe, S. Jacobsen, D. Khanna, K. Lerström, E. Massarotti, J. McCune, G. Ruiz-Irastorza, J. Sanchez-Guerrero, M. Schneider, M. Urowitz, G. Bertsias, B.F. Hoyer, N. Leuchten, C. Tani, S.K. Tedeschi, Z. Touma, G. Schmajuk, B. Anic, F. Assan, T. M. Chan, A.E. Clarke, M.K. Crow, I. Czirjak, A. Doria, W. Graninger, B. Haldakiss, S. Hasni, P.M. Izmirly, M. Jung, G. Kuzánovics, X. Mariette, I. Padjen, J. M. Pego-Reigosa, J. Romero-Díaz, I. Rúa-Figueroa Fernández, R. Seror, G. H. Stummvoll, Y. Tanaka, M.G. Tektonidou, C. Vasconcelos, E.M. Vital, D. J. Wallace, S. Yavuz, P.L. Meroni, M.J. Fritzler, R. Naden, T. Dömer, S.R. Johnson, European League against Rheumatism/American College of Rheumatology classification criteria for systemic lupus erythematosus, *Ann. Rheum. Dis.* 78 (2019) 1151–1159, <https://doi.org/10.1136/annrheumdis-2018-214819>.
- [143] C.S. Yee, D.A. Isenberg, A. Prabu, K. Sokoll, L.S. Teh, A. Rahman, I.N. Bruce, B. Griffiths, M. Akil, N. McHugh, D. D’Cruz, M.A. Khamashta, P. Maddison, A. Zoma, C. Gordon, BILAG-2004 index captures systemic lupus erythematosus disease activity better than SLEDAI-2000, *Ann. Rheum. Dis.* 67 (2008) 873–876, <https://doi.org/10.1136/ard.2007.070847>.
- [144] D.D. Gladman, D. Ibañez, M.B. Urowitz, Systemic lupus erythematosus disease activity index 2000, *J. Rheumatol.* 29 (2002) 288–291.

04. Guideline for the diagnosis, treatment and long-term management of cutaneous lupus erythematosus-4

ORIGINALITY REPORT

17%

SIMILARITY INDEX

14%

INTERNET SOURCES

9%

PUBLICATIONS

0%

STUDENT PAPERS

PRIMARY SOURCES

1	ia601702.us.archive.org Internet Source	1%
2	www.pubfacts.com Internet Source	1%
3	orbi.uliege.be Internet Source	1%
4	François Chasset, Camille Francès. "Current Concepts and Future Approaches in the Treatment of Cutaneous Lupus Erythematosus: A Comprehensive Review", Drugs, 2019 Publication	<1%
5	doaj.org Internet Source	<1%
6	Johanna Sigges, Cyrus Biazar, Aysche Landmann, Vincent Ruland et al. "Therapeutic strategies evaluated by the European Society of Cutaneous Lupus Erythematosus (EUSCLE) Core Set Questionnaire in more than 1000	<1%

patients with cutaneous lupus erythematosus", Autoimmunity Reviews, 2013

Publication

-
- 7 Annegret Kuhn, Aysche Landmann, Gisela Bonsmann. "Cutaneous Lupus Erythematosus", Elsevier BV, 2016
Publication <1 %
-
- 8 van Vollenhoven, Ronald F. "ADVANCES IN THERAPY FOR CUTANEOUS LUPUS ERYTHEMATOSUS", Clinical Therapy Research in the Inflammatory Diseases, 2015.
Publication <1 %
-
- 9 www.dovepress.com
Internet Source <1 %
-
- 10 "Lupus Erythematosus", European Handbook of Dermatological Treatments, 2015.
Publication <1 %
-
- 11 insights.ovid.com
Internet Source <1 %
-
- 12 link.springer.com
Internet Source <1 %
-
- 13 worldwidescience.org
Internet Source <1 %
-
- 14 L.G. Okon, V.P. Werth. "Cutaneous lupus erythematosus: Diagnosis and treatment", <1 %

Best Practice & Research Clinical Rheumatology, 2013

Publication

15	assets.researchsquare.com Internet Source	<1 %
16	neuro.unboundmedicine.com Internet Source	<1 %
17	www.nature.com Internet Source	<1 %
18	livrepository.liverpool.ac.uk Internet Source	<1 %
19	csd2018.meetingchina.org Internet Source	<1 %
20	dokumen.pub Internet Source	<1 %
21	cyberleninka.org Internet Source	<1 %
22	www.hindawi.com Internet Source	<1 %
23	campus.uni-muenster.de Internet Source	<1 %
24	repub.eur.nl Internet Source	<1 %
25	archderm.jamanetwork.com Internet Source	<1 %

26	Kuhn, A.. "Efficacy of tacrolimus 0.1% ointment in cutaneous lupus erythematosus: A multicenter, randomized, double-blind, vehicle-controlled trial", Journal of the American Academy of Dermatology, 201107 Publication	<1 %
27	www.guiasalud.es Internet Source	<1 %
28	www.scribd.com Internet Source	<1 %
29	f1000.com Internet Source	<1 %
30	www.rcd2012.com.ph Internet Source	<1 %
31	obgyn.onlinelibrary.wiley.com Internet Source	<1 %
32	www.dermatology.ca Internet Source	<1 %
33	www.isplad.org Internet Source	<1 %
34	www.siftdesk.org Internet Source	<1 %
35	Joshua Chang, Victoria P. Werth. "Therapeutic options for cutaneous lupus erythematosus:	<1 %

recent advances and future prospects",
Expert Review of Clinical Immunology, 2016

Publication

36	lib.bioinfo.pl Internet Source	<1 %
37	epdf.pub Internet Source	<1 %
38	medicaljournals.se Internet Source	<1 %
39	www.jove.com Internet Source	<1 %
40	www.techscience.com Internet Source	<1 %
41	jcadonline.com Internet Source	<1 %
42	www.forumortodontyczne.pl Internet Source	<1 %
43	www.uptodate.com Internet Source	<1 %
44	Victoria P. Werth. "Skin", Systemic Lupus Erythematosus, 2011 Publication	<1 %
45	www.nejm.org Internet Source	<1 %

46 J.L. Fairley, S. Oon, A.M. Saracino, M. Nikpour. <1 %
"Management of cutaneous manifestations of
lupus erythematosus: A systematic review",
Seminars in Arthritis and Rheumatism, 2020
Publication

47 Knight, Jason S., and Mariana J. Kaplan. <1 %
"Systemic Autoimmune Disease and
Premature Atherosclerosis", Encyclopedia of
Medical Immunology, 2014.
Publication

48 atm.amegroups.com <1 %
Internet Source

49 etheses.whiterose.ac.uk <1 %
Internet Source

50 www.omicsonline.org <1 %
Internet Source

51 www.slideshare.net <1 %
Internet Source

52 annals.org <1 %
Internet Source

53 www.termedia.pl <1 %
Internet Source

54 accounts.public.ce.basespace.illumina.com <1 %
Internet Source

55 idsa.confex.com
Internet Source

<1 %

56

indianheartjournal.com

Internet Source

<1 %

57

rd.springer.com

Internet Source

<1 %

58

www.pubmedcentral.nih.gov

Internet Source

<1 %

59

Benjamin F. Chong, Victoria P. Werth.
"Management of Cutaneous Lupus
Erythematosus", Elsevier BV, 2019

Publication

<1 %

60

nationaleczema.org

Internet Source

<1 %

61

pubs.rsc.org

Internet Source

<1 %

62

www.jrheum.com

Internet Source

<1 %

63

www.reumatologiaclinica.org

Internet Source

<1 %

64

Kuhn, A., F. Ochsendorf, and G. Bonsmann.
"Treatment of cutaneous lupus
erythematosus", Lupus, 2010.

Publication

<1 %

academic.oup.com

65	Internet Source	<1 %
66	emedicine.medscape.com Internet Source	<1 %
67	homeopathyamerica.net Internet Source	<1 %
68	ira.le.ac.uk Internet Source	<1 %
69	onlinelibrary.wiley.com Internet Source	<1 %
70	www.eadc2010.com Internet Source	<1 %
71	www.elsevier.es Internet Source	<1 %
72	www.ingentaconnect.com Internet Source	<1 %
73	M.J. Harries. "Management of primary cicatricial alopecias: options for treatment", British Journal of Dermatology, 5/16/2008 Publication	<1 %
74	Sabina Gall, Uta Kiltz, Tanja Kobylinski, Ioana Andreica et al. "Investigation of Patient Satisfaction with Education in a Biosimilar Multiswitch Scenario - A Comparison Between	<1 %

Rheumatologists and Nurse Specialists", Research Square Platform LLC, 2021

Publication

75	actasdermo.org Internet Source	<1 %
76	arthritis-research.com Internet Source	<1 %
77	care.diabetesjournals.org Internet Source	<1 %
78	docksci.com Internet Source	<1 %
79	documents.mx Internet Source	<1 %
80	drnelsonsveterinaryblog.com Internet Source	<1 %
81	effiloop.com Internet Source	<1 %
82	hdl.handle.net Internet Source	<1 %
83	ia801702.us.archive.org Internet Source	<1 %
84	journals.plos.org Internet Source	<1 %
85	journals.sagepub.com Internet Source	<1 %

86	lupus.bmj.com Internet Source	<1 %
87	njl-admin.nihr.ac.uk Internet Source	<1 %
88	repository.ubn.ru.nl Internet Source	<1 %
89	scripties.umcg.eldoc.ub.rug.nl Internet Source	<1 %
90	www.actasdermo.org Internet Source	<1 %
91	www.bmj.com Internet Source	<1 %
92	www.cepigene.ir Internet Source	<1 %
93	www.dovepress.com Internet Source	<1 %
94	www.fmshk.org Internet Source	<1 %
95	"Biologic and Systemic Agents in Dermatology", Springer Science and Business Media LLC, 2018 Publication	<1 %
96	Kristoffer A Zervides, Andreas Jern, Jessika Nystedt, Birgitta Gullstrand et al. "Serum	<1 %

S100A8/A9 Concentrations are Associated with Neuropsychiatric Involvement and Fatigue in Systemic Lupus Erythematosus: A Cross-Sectional Study", Research Square Platform LLC, 2021

Publication

97

Sang Cheng, Huihua Ding, Haiyan Xue, Min Xia, Zhiqiang Tu, Weiqi Zhang, Lanfang Cao.

"Performance of 2019 EULAR/ACR

Classification Criteria for Systemic Lupus

Erythematosus in Children and Adults : A

Retrospective Observational Study", Research

Square Platform LLC, 2021

Publication

<1 %

98

Sisi Chen, Liu Yang, Xia Ou, Jin-Yu Li, Cheng-Ting Zi, Hao Wang, Jiang-Miao Hu, Ye Liu. "A

new polysaccharide platform constructs self-adjuvant nanovaccines to enhance immune

responses", Research Square Platform LLC,

2022

Publication

<1 %

99

zenan wu, Guixing Xu, Jun Xiong, Zhengyun

Zuo, Qiongshan Xie, Xinyu Yu. "Moxibustion

therapy on Myofascial Pain Syndrome: an

evidence-based clinical practice guideline

protocol", Research Square, 2020

Publication

<1 %

Exclude quotes On

Exclude matches Off

Exclude bibliography On

04. Guideline for the diagnosis, treatment and long-term management of cutaneous lupus erythematosus-4

GRADEMARK REPORT

FINAL GRADE

/100

GENERAL COMMENTS

Instructor

PAGE 1

PAGE 2

PAGE 3

PAGE 4

PAGE 5

PAGE 6

PAGE 7

PAGE 8

PAGE 9

PAGE 10

PAGE 11

PAGE 12

PAGE 13

PAGE 14

PAGE 15

PAGE 16
