



Source details

Journal of Dermatological Treatment

Scopus coverage years: from 1989 to Present

Publisher: Taylor & Francis

ISSN: 0954-6634

Subject area: Medicine: Dermatology

Source type: Journal

CiteScore 2021

5.0



SJR 2021

0.737



SNIP 2021

1.104



[View all documents >](#)

[Set document alert](#)

[Save to source list](#) [Source Homepage](#)

[CiteScore](#) [CiteScore rank & trend](#) [Scopus content coverage](#)

Improved CiteScore methodology



CiteScore 2021 counts the citations received in 2018-2021 to articles, reviews, conference papers, book chapters and data papers published in 2018-2021, and divides this by the number of publications published in 2018-2021. [Learn more >](#)

CiteScore 2021

$$5.0 = \frac{3,037 \text{ Citations 2018 - 2021}}{607 \text{ Documents 2018 - 2021}}$$

Calculated on 05 May, 2022

CiteScoreTracker 2022

$$4.5 = \frac{3,570 \text{ Citations to date}}{802 \text{ Documents to date}}$$

Last updated on 05 October, 2022 • Updated monthly

CiteScore rank 2021

Category	Rank	Percentile
Medicine		
Dermatology	#23/126	82nd

[View CiteScore methodology >](#) [CiteScore FAQ >](#) [Add CiteScore to your site](#)

About Scopus

[What is Scopus](#)

[Content coverage](#)

[Scopus blog](#)

[Scopus API](#)

[Privacy matters](#)

Language

[日本語版を表示する](#)

[查看简体中文版本](#)

[查看繁體中文版本](#)

[Просмотр версии на русском языке](#)

Customer Service

[Help](#)

[Tutorials](#)

[Contact us](#)

ELSEVIER

[Terms and conditions ↗](#) [Privacy policy ↗](#)

Copyright © Elsevier B.V. ↗. All rights reserved. Scopus® is a registered trademark of Elsevier B.V.

We use cookies to help provide and enhance our service and tailor content. By continuing, you agree to the use of cookies ↗.





Advances in Civil Eng. Papers

Maximize the Impact, Reach & Visibility of Your Next Paper
Publishing With Us

Hindawi

Journal of Dermatological Treatment

COUNTRY

United Kingdom



Universities and research
institutions in United
Kingdom

SUBJECT AREA AND CATEGORY

Medicine
Dermatology

PUBLISHER

Informa Healthcare

H-INDEX

56

PUBLICATION TYPE

Journals

ISSN

09546634

COVERAGE

1989-2021

INFORMATION

[Homepage](#)

[How to publish in this
journal](#)

Alexander.Smith@tandf.co.uk

SCOPE

The journal aims to give dermatologists practical value through cutting-edge information on new treatments in all areas of dermatology. Accepted content benefits from rapid review and full-color illustrations. The journal's focus includes: Topical and systemic dermatological therapies, including novel biologicals; Dermatological phototherapy; Dermatological surgery and lasers; Skin pharmacology.



Join the conversation about this journal

Advances in Civil Eng. Papers

Maximize the Impact, Reach & Visibility of Your Next Paper by Publish With Us

Hindawi



FIND SIMILAR JOURNALS ?

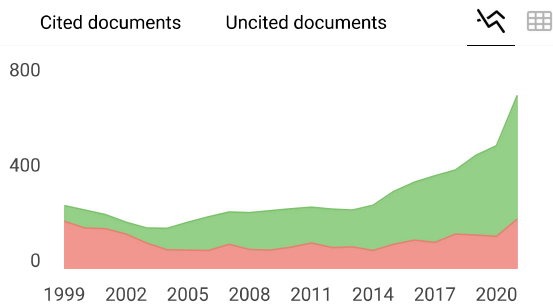
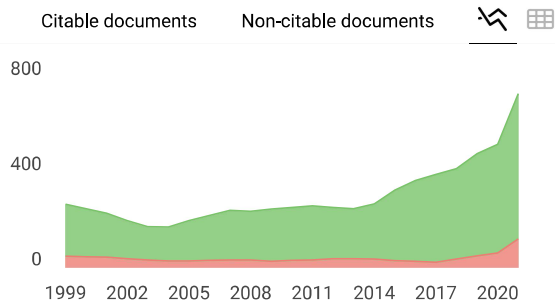
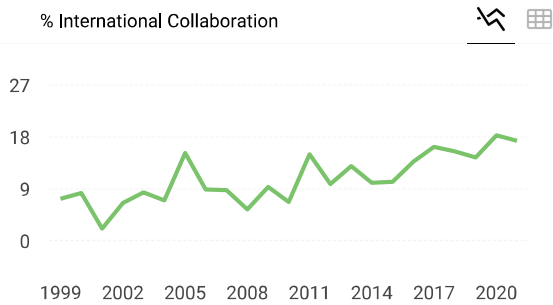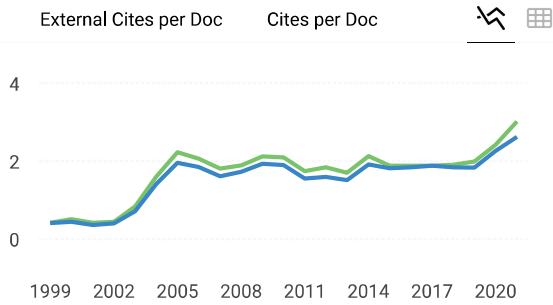
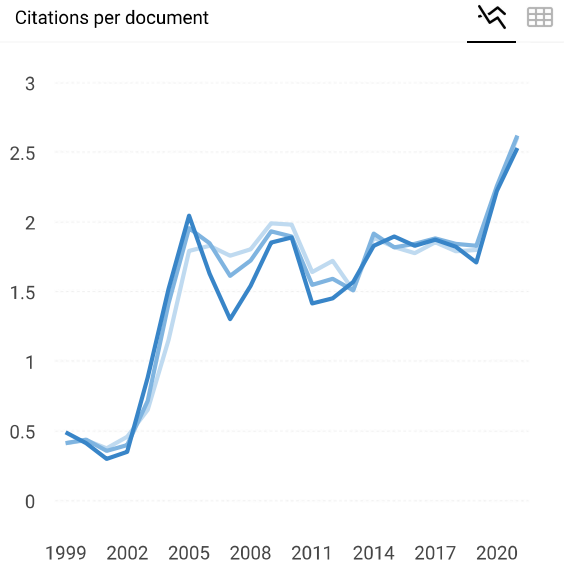
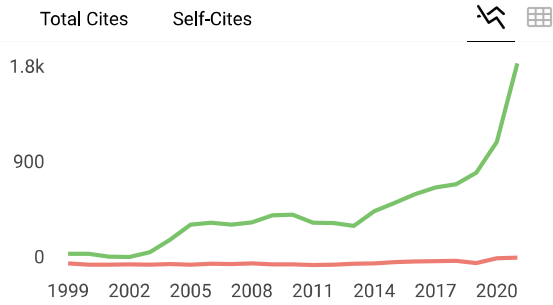
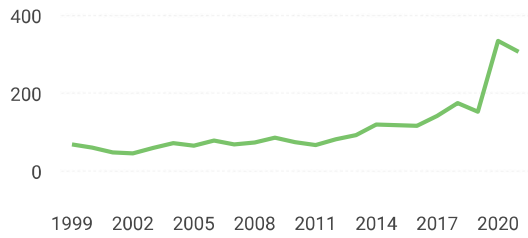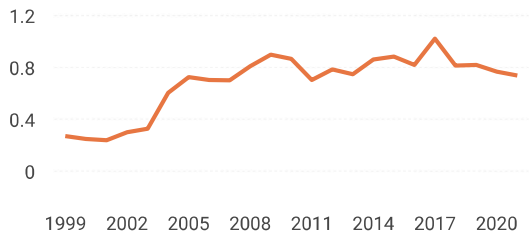
1 Dermatology and Therapy DEU 96% similarity	2 Journal of Cutaneous Medicine and Surgery USA 94% similarity	3 American Journal of Clinical Dermatology GBR 93% similarity	4 Journal of the Et Academy of Deri USA 91% similarity
--	--	---	--

Advances in Civil Eng. Papers

Maximize the Impact, Reach & Visibility of Your Next Paper by Publish With Us

Hindawi





Journal of Dermatological Treatment

Q1 Dermatology
best quartile

SJR 2021
0.74

powered by scimagojr.com

← Show this widget in your own website

Just copy the code below and paste within your html code:

```
<a href="https://www.scimag
```

SCImago Graphica

Explore, visually communicate and make



sense of data with our
**new data visualization
tool.**



Advances in Civil Eng. Papers

Maximize the Impact, Reach & Visibility of Your Next Paper by Publish With Us

Hindawi



Metrics based on Scopus® data as of April 2022



Loading comments...

Developed by:



Powered by:



Follow us on [@ScimagoJR](#)

Scimago Lab, Copyright 2007-2022. Data Source: Scopus®

EST MODUS IN REBUS

Horatio (Satire 1, 1, 106)

[Edit Cookie Consent](#)

Journal of Dermatological Treatment

Publish with us

[Submit an article](#) ▼

[About this journal](#) ▼

Explore

[Browse all articles & issues](#) ▼

 [Latest issue](#)

Subscribe

[Alerts & RSS feed](#) ▼



 [Log in](#)

| [Register](#)



Browse this journal

[▶ Latest articles](#)

[▶ Current issue](#)

[▶ List of issues](#)

[▶ Special issues](#)

[▶ Most read articles](#)

[▶ Most cited articles](#)

Journal of Dermatological Treatment

Sign in here to start your access to the latest two volumes for 14 days

Publish with us

Submit an article ▾

About this journal ▾

Explore

Browse all articles & issues ▾

Latest issue

Subscribe

Alerts & RSS feed ▾

See all volumes and issues

◀ 017	Vol 27, 2016	Vol 26, 2015	Vol ▶
-------	--------------	--------------	-------

◀ sue Issue Issue Issue ▶
4 3 2 1

☰ Browse by section (All) ▾ ⌵ Display order (Default) ▾

○ [Download citations](#) [Download PDFs](#) [Download issue](#)

Editorial

○ Editorial
Atopic dermatitis spectrum disorder: new conceptualization for the coming new therapeutic era ▶

Daniel C. Butler & John Koo

Pages: 743-744

Published online: 21 Nov 2018

653	0	0
Views	CrossRef citations	Altmetric



Oncology

Journal of Dermatological Treatment

option? >

Kamran Balichi, Mahshid Sadat Ansari, Mehdi Mirzajonour, Marziyam Daneshmandi

Publish with
us

Submit an
article ▾

108
Views

About this
journal ▾

2
CrossRef citations

Explore

Browse all articles &
issues ▾

Latest
issue

Subscribe

Alerts & RSS
feed ▾

0
Altmetric

- Article
**Healthcare resource utilization, costs of care, and treatment of
mycosis fungoides cutaneous T-cell lymphoma patterns in a large
managed care population: a retrospective US claims-based analysis** >

Yuen Tsang, Tao Gu, Gaurav Sharma, Susan Raspa, Bill Drake III & Hiangkiat Tan

Pages: 747-753

Published online: 07 May 2018

2097
Views

5
CrossRef citations

Altmetric



Psoriasis

- Review Article
Prevalence of genital psoriasis in patients with psoriasis >

Kim A. P. Meeuwis, Alison Potts Bleakman, Peter C. M. van de Kerkhof, Yves Dutronc, Carsten Hennes, Lori J. Kornberg & Alan Menter

Pages: 754-760

Published online: 28 Mar 2018

2795
Views

17
CrossRef citations

Altmetric



Journal of Dermatological Treatment

Views | CrossRef citations | Altmetric

Publish with
us

Submit an
article ▾

About this
journal ▾

Explore

Browse all articles &
issues ▾

 Latest
issue

Subscribe

Alerts & RSS
feed ▾

◡ [Evaluation of the effect of pulsed dye laser on chronic psoriatic plaque](#) >

Nagwa Mohammad Elwan, Shereen Farouk Gheida, Soha Abdalla Hawwam & Abeer Hussien Ahmed

Pages: 786-791

Published online: 07 May 2018

135 | 1
Views | CrossRef citations | Altmetric

Article

○ [Association between clinical factors and dose modification strategies in the treatment with ustekinumab for moderate-to-severe plaque psoriasis](#) >

Rosa M. Romero-Jimenez, Vicente Escudero-Vilaplana, Ofelia Baniandres Rodriguez, Estela García Martín, Ana Mateos Mayo & Maria Sanjurjo Saez

Pages: 792-796

Published online: 07 May 2018

355 | 8
Views | CrossRef citations | Altmetric

Article

○ [Psoriasis management in actual clinical practice: a 6-year retrospective study of 845 patients](#) >

Pinar Incel Uysal, Buket Sahin, Basak Yalcin, Afra Alkan & Selcen Yuksel

Pages: 797-801

Published online: 07 May 2018

Journal of Dermatological Treatment

Publish with
us

Submit an
article ▾

About this
journal ▾

Explore

Browse all articles &
issues ▾

 Latest
issue

Subscribe

Alerts & RSS
feed ▾

Mendi Pisingani, Sahar Dadkhanfar, Reza M. Kobati, Zohreh Kheradmand, Mohammad Shahidi-Dadras, Omid Zargari & David J. Elpern

Pages: 802-805

Published online: 07 May 2018

160	6	
Views	CrossRef citations	Altmetric

○ Article
[Effects of etanercept on the patient-perceived results \(PROs\) in patients with moderate-to-severe plaque psoriasis: systematic review of the literature and meta-analysis >](#)

Jose Manuel Carrascosa, Francisco Rebollo, Susana Gómez & Plablo De-la-Cueva

Pages: 806-811

Published online: 08 May 2018

291	5	
Views	CrossRef citations	Altmetric

Other inflammatory skin diseases

○ Letter
[Selective serotonin reuptake inhibitors for the treatment of chronic pruritus >](#)

Emily Boozalis, Raveena Khanna & Shawn G. Kwatra

Pages: 812-814

Published online: 12 Apr 2018

183	7	
-----	---	--

Journal of Dermatological Treatment

Publish with
us

Submit an
article ▼

About this
journal ▼

Explore

Browse all articles &
issues ▼

 Latest
issue

Subscribe

Alerts & RSS
feed ▼

Published online: 07 May 2018

421	11	
Views	CrossRef citations	Altmetric

Article



[Nail involvement in patients with moderate-to-severe alopecia areata treated with oral tofacitinib >](#)

Ji Su Lee, Chang-Hun Huh, Ohsang Kwon, Hyun-Sun Yoon, Soyun Cho & Hyun-sun Park

Pages: 819-822

Published online: 07 May 2018

397	5	
Views	CrossRef citations	Altmetric

Letter



[A note on improvement in dermatology life quality index \(DLQI\) among patients with hidradenitis suppurativa treated with adalimumab >](#)

Simon Francis Thomsen

Pages: 823-824

Published online: 07 May 2018

156	1	
Views	CrossRef citations	Altmetric

Journal of Dermatological Treatment

Brent L. Cao

Publish with
us

Submit an
article ▾

About this
journal ▾

Explore

Browse all articles &
issues ▾

 Latest
issue

Subscribe

Alerts & RSS
feed ▾

Views | CrossRef citations | Altmetric



Article

Serum prolactin level in chronic urticaria: Is bromocriptine inducing remission in chronic urticaria? >

Mohamed Soliman, Fathia M. Khattab, Howyda Mohamed Ebrahim & Mohamad Nasr

Pages: 826-830

Published online: 10 May 2018

112

Views

1

CrossRef citations

Altmetric

Pharmacology



Review Article

Interferon-beta injection site reactions in patients with multiple sclerosis >

Martina Maurelli, Roberto Bergamaschi, Ambra Antonini, Maria Concetta Fagnoli, Elisa Puma, Giulia Mallucci, Rocco Totaro & Giampiero Girolomoni

Pages: 831-834

Published online: 07 May 2018

330

Views

5

CrossRef citations

Altmetric

— Article >

Journal of Dermatological Treatment

TRIAMMISOLONE + VITAMIN C AND TRIAMMISOLONE + VITAMIN E ON CHRONIC
plantar ulcers in leprosy: a randomized control trial >

Publish with
us

Submit an
article ▾

About this
journal ▾

Explore

Browse all articles &
issues ▾

 Latest
issue

Subscribe

Alerts & RSS
feed ▾

Published online: 10 May 2018

303

Views

21

CrossRef citations

Altmetric

Review Article



**Clinical utility of marketing terms used for over-the-counter
dermatologic products >**

Emily Boozalis & Shivani Patel

Pages: 841-845

Published online: 08 May 2018

288

Views

1

CrossRef citations

Altmetric

Explore articles

Latest

Most read

Most cited

Trending

**Progressive mucinous histiocytosis treated successfully with thalidomide: a
rare case report >**

Reem Diab et al.

Case Report | Published online: 21 Oct 2022

Surgical experiences in pediatric pilomatricoma: punch incision and

Journal of Dermatological Treatment

Brief Report | Published online: 21 Oct 2022

Publish with
us

Submit an
article ▼

About this
journal ▼

Explore

Browse all articles &
issues ▼

 Latest
issue

Subscribe

Alerts & RSS
feed ▼

Review Article | Published online: 20 Oct 2022



[Are cyclosporine eye drops a suitable treatment in ocular rosacea? >](#)

Alvaro Prados-Carmona et al.

Published online: 19 Oct 2022

[View all latest articles >](#)

Journal of Dermatological Treatment

AUTHORS

R&D professionals

Publish with us

[Submit an article](#) ▼

[About this journal](#) ▼

[Opportunities](#)

[Reprints and e-prints](#)

[Advertising solutions](#)

[Accelerated publication](#)

[Corporate access solutions](#)

OVERVIEW

[Open journals](#)

Explore

[Browse all articles & issues](#) ▼

 [Latest issue](#)

Subscribe

[Alerts & RSS feed](#) ▼

[Help and information](#)

[Help and contact](#)

[Newsroom](#)

[All journals](#)

[Books](#)

Keep up to date

Register to receive personalised research and resources by email



[Sign me up](#)



Journal of Dermatological Treatment

Publish with us

[Submit an article](#) ▼

[About this journal](#) ▼

Explore

[Browse all articles & issues](#) ▼

 [Latest issue](#)

Subscribe

[Alerts & RSS feed](#) ▼



 [Log in](#)

| [Register](#)



Ready to submit?

Start a new manuscript submission or continue a submission in progress

[Go to submission site](#) 

Submission information

[▶ Instructions for authors](#)

[▶ Editorial policies](#) 

Editing services

[▶ Editing services site](#) 

About this journal

[▶ Journal metrics](#)

[▶ Aims & scope](#)

[▶ Journal information](#)

[▶ Editorial board](#)

[▶ News & call for papers](#)

[▶ Advertising information](#)

Journal of Dermatological Treatment

Peter Van de Kerkhof - *University Hospital, Nijmegen, Netherlands*

Publish with
us

Submit an
article ▾

About this
journal ▾

Explore

Browse all articles &
issues ▾

 Latest
issue

Subscribe

Alerts & RSS
feed ▾

Associate Editors

David de Berker - *Bristol, UK*

John Berth-Jones - *Coventry, UK*

Kenneth Gordon - *Maywood, USA*

Jason Reichenberg - *Austin, USA*

Marieke Seyger - *Nijmegen, the Netherlands*

Viewpoint Section Editor

Mohammad Reza Namazi - *Shiraz, Iran*

Editorial Board

Ali Alikhan - *Cincinnati, OH, USA*

Rajesh Balkrishnan - *Columbus, USA*

Jonathan Barker - *London, UK*

Paul R. Bergstresser - *Dallas, USA*

Ruggero Caputo - *Milan, Italy*

Enno Christophers - *Kiel, Germany*

Michael J. Cork - *Sheffield, UK*

William J. Cunliffe - *Leeds, UK*

Laura Doerfler - *Winston-Salem, USA*

Louis Dubertret - *Paris, France*

Charles Ellis - *Ann Arbor, USA*

Andrew Y. Finlay - *Cardiff, UK*

Rianne MJP Gerritsen - *Nijmegen, The Netherlands*

Brad P. Glick - *Miami, Florida*

Neal Goldman - *Winston-Salem, USA*

W Andrew D Griffiths - *London, UK*

Christopher EM Griffiths - *Manchester, UK*

Journal of Dermatological Treatment

Francisco Kerdel - *Miami, USA*

Publish with
us

[Submit an
article](#) ▼

[About this
journal](#) ▼

Explore

[Browse all articles &
issues](#) ▼

 [Latest
issue](#)

Subscribe

[Alerts & RSS
feed](#) ▼

Giuseppe Micali - *Catania, Italy*

Jean-Paul Ortonne - *Nice, France*

Rita Pichardo - *Winston-Salem, USA*

Jason Reichenberg - *Austin, USA*

Noah Scheinfeld - *New York, USA*

Hiroshi Shimizu - *Sapporo, Japan*

Eggert Stockfleth - *Berlin, Germany*

John D Stratigos - *Athens, Greece*

Arash Taheri - *Winston-Salem, USA*

Yong-Kwang Tay - *Singapore, Malaysia*

Antonella Tosti - *Bologna, Italy*

Gil Yosipovitch - *Winston-Salem, USA*

Christos Zouboulis - *Berlin, Germany*

Sample our 
Medicine, Dentistry, Nursing
& Allied Health Journals
>> [Sign in here](#) to start your access
to the latest two volumes for 14 days

Need help getting published?
Sign up to **Research Insights** for
weekly tips, tools, and advice → 

Journal of Dermatological Treatment

Request a

GOOD HEALTH

Publish with us

Submit an article ▼

About this journal ▼

Explore

Browse all articles & issues ▼

Latest issue

Subscribe

Alerts & RSS feed ▼

Improving reproducibility through diverse research outputs

REGISTER FOR THE WEBINAR

Journal of Dermatological Treatment

AUTHORS

R&D professionals

Publish with us

[Submit an article](#) ▼

[About this journal](#) ▼

[Opportunities](#)

[Reprints and e-prints](#)

[Advertising solutions](#)

[Accelerated publication](#)

[Corporate access solutions](#)

OVERVIEW

[Open journals](#)

Explore

[Browse all articles & issues](#) ▼

 [Latest issue](#)

[Help and information](#)

[Help and contact](#)

[Newsroom](#)

[All journals](#)

[Books](#)

Subscribe

[Alerts & RSS feed](#) ▼

Keep up to date

Register to receive personalised research and resources by email



[Sign me up](#)





The efficacy of topical human amniotic membrane-mesenchymal stem cell-conditioned medium (hAMMSC-CM) and a mixture of topical hAMMSC-CM + vitamin C and hAMMSC-CM + vitamin E on chronic plantar ulcers in leprosy: a randomized control trial

C. R. S Prakoeswa, F. R. Natallya, D. Harnindya, A. Thohiroh, R. N. Oktaviyanti, K. D. Pratiwi, M. A. Rubianti, B. Yogatri, P. I. Primasari, N. Herwanto, M. D. Alinda, B. H. Kusumaputra, L. Astari, M. Y. Listiawan, I. Agusni & F. A. Rantam

To cite this article: C. R. S Prakoeswa, F. R. Natallya, D. Harnindya, A. Thohiroh, R. N. Oktaviyanti, K. D. Pratiwi, M. A. Rubianti, B. Yogatri, P. I. Primasari, N. Herwanto, M. D. Alinda, B. H. Kusumaputra, L. Astari, M. Y. Listiawan, I. Agusni & F. A. Rantam (2018) The efficacy of topical human amniotic membrane-mesenchymal stem cell-conditioned medium (hAMMSC-CM) and a mixture of topical hAMMSC-CM+vitamin C and hAMMSC-CM+vitamin E on chronic plantar ulcers in leprosy: a randomized control trial, *Journal of Dermatological Treatment*, 29:8, 835-840, DOI: [10.1080/09546634.2018.1467541](https://doi.org/10.1080/09546634.2018.1467541)

To link to this article: <https://doi.org/10.1080/09546634.2018.1467541>



Accepted author version posted online: 19 Apr 2018.
Published online: 10 May 2018.



Submit your article to this journal [↗](#)

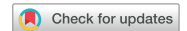

Article views: 38




View Crossmark data [↗](#)

ARTICLE



The efficacy of topical human amniotic membrane-mesenchymal stem cell-conditioned medium (hAMMSC-CM) and a mixture of topical hAMMSC-CM + vitamin C and hAMMSC-CM + vitamin E on chronic plantar ulcers in leprosy: a randomized control trial

C. R. S Prakoeswa^a , F. R. Natallya^a, D. Harnindya^a, A. Thohiroh^a, R. N. Oktaviyanti^a, K. D. Pratiwi^a, M. A. Rubianti^a, B. Yogatri^a, P. I. Primasari^a, N. Herwanto^a, M. D. Alinda^a, B. H. Kusumaputra^a, L. Astari^a, M. Y. Listiawan, I. Agusni^a and F. A. Rantam^{b,c}

^aDepartment of Dermatology-Venereology, Dr. Soetomo Teaching Hospital/School of Medicine, Universitas Airlangga, Surabaya, Indonesia;

^bStem Cell Research and Development Center, Universitas Airlangga, Surabaya, Indonesia; ^cVirology and Immunology Laboratory, Department of Microbiology, Faculty of Veterinary Medicine, Universitas Airlangga, Surabaya, Indonesia

ABSTRACT

Background: Healing of chronic plantar ulcers in leprosy (CPUL) typically takes a long time due to impaired neurological function, thereby reducing the levels of growth factors and cytokines. Cytokines can be found in metabolite products from amniotic membrane stem cells. Chronic ulcers are frequently characterized by high levels of reactive oxygen species. Vitamin E (α -tocopherol) is widely used in skin lesions, owing to its antioxidant and anti-inflammatory properties. Vitamin C also has antioxidant, anti-inflammatory, and collagen synthesis properties which are useful in wound healing. Herein, we compared the effects of topical human amniotic membrane-mesenchymal stem cell-conditioned medium (hAMMSC-CM) alone and with vitamins C and E on healing of CPUL.

Methods: In this randomized controlled trial, topical agents were applied every 3 days for up to 8 weeks. Ulcer size, side-effects, and possible complications were monitored weekly.

Results: Healing percentage increased each week in all groups. Mean difference in ulcer size was highest in the hAMMSC-CM + vitamin E group, implying better progress of wound healing. There were no side-effects or complications.

Conclusions: hAMMSC-CM + vitamin E is best for healing of CPUL.

ARTICLE HISTORY

Received 27 March 2018

Accepted 6 April 2018

KEYWORDS

hAMMSC-CM; vitamin E; vitamin C; chronic plantar ulcers in leprosy

Introduction

Ulcers are defined as loss of continuity of skin tissue up to the dermis or deeper (subcutis). Approximately 30% of patients with leprosy have peripheral nerve damage, and 10–20% of them have neuropathic ulcers due to peripheral nerve damage. Leprosy ulcers are present mostly in plantar pedis, particularly in areas with bony prominence. The plantar pedis is a part of the body that functions in walking; thus, the risk of experiencing trauma is greater in this area than in other body parts (1–3). Healing of plantar ulcers in leprosy is often difficult and time-consuming due to decreasing levels of growth factors and cytokines as a result of a prolonged inflammatory condition. The inflammatory condition can be caused by infection and ischemia due to persistent pressure on the wound from disruption of nerve functions. This causes obstruction of the wound-healing process and formation of a chronic ulcer (4–8).

Since the early twentieth century, amniotic membranes have been used to treat widespread injuries, burns, chronic and deep ulcers, and surgical wounds that are difficult to close. Studies on amniotic membrane stem cells for repair and regeneration of cells have shown good results. The production of growth factors and cytokines, which are required for tissue healing, is one of the mechanisms of stem cells in the tissue-healing process. Growth factors and cytokines can be found in the tissue medium of stem

cells in *in vitro* conditions through its metabolite products, and thus they can be a useful modality in the process of cell regeneration (9–14).

Previous research has proven that injuries that are difficult to heal in humans are associated with high levels of oxidative stress. Wounds or chronic ulcers often show increasing levels of reactive oxygen species (ROS) or free radicals that can delay the wound-healing process and inhibit formation of granulation tissue and epithelialization. Free radicals are formed in response to tissue damage and subsequently inhibit the recovery process by attacking DNA, membranes, proteins, and lipids from cells. Antioxidants are believed to repair wounds by reducing damage caused by free radicals released by neutrophils in the inflammatory phase of wound healing (15–17).

Prakoeswa et al. (18) compared the effects of topical human amniotic membrane-mesenchymal stem cell-conditioned medium (hAMMSC-CM) and the framycetin gauze dressing (FGD) applied every 3 days for up to 8 weeks on healing of chronic plantar ulcers in leprosy (CPUL). Ulcer healing was significantly better in the hAMMSC-CM group than in the FGD group clinically and statistically ($p < .005$ and $p < .005$) (18).

The role of vitamin C, a known antioxidant, in collagen synthesis is believed to be useful in wound healing. As an antioxidant, vitamin C neutralizes ROS found in chronic ulcers. Vitamin C also

directly stimulates collagen synthesis. Sodium ascorbyl phosphate (SAP) is a stable derivative of vitamin C (19,20).

Vitamin E is a non-enzymatic, natural antioxidant and the most important lipid soluble in human tissue that is absorbed well by the skin. Several studies have shown that vitamin E, particularly α -tocopherol, gives good results in the wound-healing process. α -Tocopherol may serve as an antioxidant, reducing ischemic damage due to reperfusion disorders, and may stimulate growth and stabilize granulation tissue, as well as re-epithelialization (21,22).

In light of the aforementioned facts, the present study investigated the effect of topical gel hAMMSC-CM only (group 1) and a mixture of hAMMSC-CM + vitamin C (group 2) and hAMMSC-CM + vitamin E (group 3) on healing of CPUL.

Materials and methods

Study design and patients

This experimental analytical randomized controlled clinical trial was performed using parallel designs in 22 subjects in each of the three treatment groups. Consecutive sampling was performed, i.e. we enrolled any patient with CPUL who met the criteria for admission samples at the Dermatology Venereology outpatient clinic, Dr Soetomo Teaching Hospital. The subjects were leprosy patients with CPUL of >6 weeks, an ulcer depth of <0.5 cm, and a maximum injury area of 9 cm² who did not consume systemic corticosteroids in the last 2 weeks. The subjects also had no history of diabetes mellitus, hemophilia, blood clotting physiological disorders, antiplatelet use, and hypersensitivity to transparent film dressings or adhesive plasters. This clinical study was approved by the ethical committee board of Dr. Soetomo Teaching Hospital Surabaya and was randomized with computerized and consecutive sampling.

Treatment intervention

Surgical debridement was performed in all groups before treatment to remove callus and necrotic tissue and return all ulcers to the same healing phase, i.e. the coagulation and inflammatory phase. The drug was applied every 3 days until the ulcer closed or for a maximum of 8 weeks. An extensive and deep ulcer measurement and evaluation of side effects and complications of both drugs were conducted weekly. Off-loading was not performed in any subject. Subjects were recommended only to reduce standing and walking activities.

Laboratory testing

Spectrophotometric examination was conducted using a spectrophotometer by measuring the absorbance at 280 nm to determine the total protein content per mL fluid of stem cell metabolite products and obtain the total protein content in hAMMSC-CM to be used at 5.05 mg/mL. The hAMMSC-CM stability test was conducted in the laboratory testing unit of the Faculty of Pharmacy Universitas Airlangga for 4 weeks. The test was performed to determine the total protein content in hAMMSC-CM, which was [1.38 ± 0.1]% w/w on day one and [1.25 ± 0.02]% w/w on day 30. α -Tocopherol and SAP stability tests also were performed to determine the levels of α -tocopherol in groups 2 and 3. The α -Tocopherol content was measured weekly using high-performance liquid chromatography for 4 weeks. The α -tocopherol and SAP contents were [8.76% ± 0.1]% w/w on day 1 and [9.55% ± 0.1]% w/w on day 30. The total protein and α -tocopherol contents of metabolites of stem cell products were relatively stable until week 4, and thus the product mix metabolite in groups 2 and 3 could be regenerated every 4 weeks, which were applied to the ulcer once in every 3 days for a maximum of 8 weeks or 14 applications.

Statistical analysis

All enrolled patients were evaluated. The nonparametric Mann–Whitney *U* test was used to determine significant differences between samples before and after treatment within the same group and between two groups. $p < .05$ indicated statistical significance. All statistical analyses were performed using SPSS version 22.0 software (SPSS, Inc., Chicago, IL, USA).

Results

The patients were divided almost equally between male and female sexes. The mean age of patients in all groups was 52.18 ± 1.33 years, mean ulcer duration was 1.41 ± 0.36 years, and mean ulcer size at baseline was 2.64 ± 0.50 cm² (Table 1). There were no dropouts in the study. All the patients who were included completed the study protocol.

The mean percentage of ulcer healing per week in groups 2 and 3 is shown in Figure 1. The healing percentage increased each week in all groups. At the end of the study, mean reduction in ulcer size and depth was 1.70 ± 1.05 cm² and 0.35 ± 0.14 cm², 2.01 ± 1.19 cm² and 0.25 ± 0.11 cm², and 2.84 ± 1.67 cm² and 0.27 ± 0.15 cm² in groups 1, 2, and 3, respectively (Table 2).

The clinical improvement in the ulcers at the end of the study is shown in Table 3. The numbers of patients in whom ulcers were improved (ulcer size was smaller at the end of the study compared with that at baseline), persisted (ulcer size remained

Table 1. Demographics of the patients and baseline characteristics.

Variable	Group 1 (n = 22)	Group 2 (n = 22)	Group 3 (n = 22)
Sex			
Male, n (%)	13 (59.1)	9 (40.9)	8 (63.6)
Female, n (%)	9 (40.9)	13 (59.1)	14 (36.4)
Age (years)			
21–50 years, n (%)	12 (54.5)	12 (54.5)	10 (45.4)
>50 years, n (%)	10 (45.5)	10 (45.5)	12 (54.6)
Occupation			
Requires long-standing/walking, n (%)	11 (50.0)	10 (45.5)	10 (45.5)
Does not require long-standing/walking, n (%)	11 (50.0)	12 (54.5)	12 (54.5)
Duration of ulcer (years)			
<1 year, n (%)	6 (27.3)	7 (31.8)	9 (40.9)
1–5 years, n (%)	15 (63.6)	15 (68.2)	13 (59.1)
>5 years, n (%)	1 (9.1)	0 (0)	0 (0)

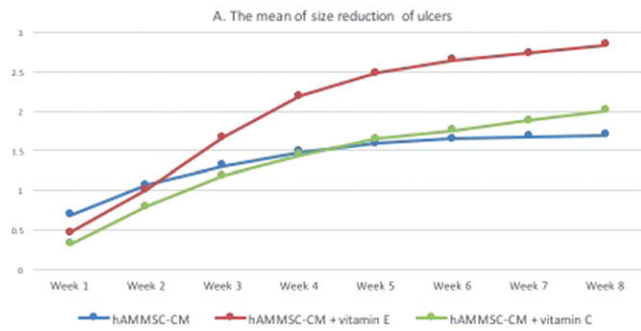


Figure 1. The mean percentage of size reduction in ulcers every week in the three groups hAMMSC-CM: human amniotic membrane-mesenchymal stem cell-conditioned medium.

Table 2. Percentage of reduction of ulcers.

	Group 1 (n = 22)	Group 2 C (n = 22)	Group 3 (n = 22)
The mean size of the ulcer ± SD			
Week I ± SD	0.69 ± 0.47	0.32 ± 0.47	0.47 ± 0.59
Week II ± SD	1.08 ± 0.59	0.79 ± 0.63	1.01 ± 0.69
Week III ± SD	1.31 ± 0.74	1.18 ± 0.75	1.67 ± 1.35
Week IV ± SD	1.48 ± 0.86	1.44 ± 0.92	2.19 ± 1.52
Week V ± SD	1.59 ± 0.94	1.65 ± 0.95	2.48 ± 1.59
Week VI ± SD	1.65 ± 0.97	1.75 ± 0.99	2.64 ± 1.64
Week VII ± SD	1.68 ± 1.03	1.88 ± 1.04	2.73 ± 1.67
Week VIII ± SD	1.70 ± 1.05	2.01 ± 1.19	2.84 ± 1.67
The mean depth of the ulcer ± SD			
Week I ± SD	0.15 ± 0.11	0.04 ± 0.05	0.05 ± 0.07
Week II ± SD	0.21 ± 0.14	0.09 ± 0.09	0.09 ± 0.08
Week III ± SD	0.26 ± 0.15	0.15 ± 0.11	0.14 ± 0.11
Week IV ± SD	0.30 ± 0.16	0.19 ± 0.10	0.18 ± 0.13
Week V ± SD	0.32 ± 0.15	0.21 ± 0.09	0.23 ± 0.14
Week VI ± SD	0.33 ± 0.15	0.24 ± 0.11	0.25 ± 0.14
Week VII ± SD	0.34 ± 0.15	0.24 ± 0.11	0.26 ± 0.14
Week VIII ± SD	0.35 ± 0.14	0.25 ± 0.11	0.27 ± 0.15

Table 3. Clinical improvement of the ulcers at the end of the study.

Improvement of ulcers at the end of the study	Group 1 (n = 22)	Group 2 (n = 22)	Group 3 (n = 22)
Improved, n (%)	21 (95.5)	22 (100)	22 (100)
Persisted, n (%)	1 (4.5)	0 (0)	0 (0)
Worsened, n (%)	0 (0)	0 (0)	0 (0)

the same at the end of the study), and worsened (ulcer size was larger at the end of the study) are shown in Figure 2. In this study, the percentage of improved ulcers was higher in groups 2 and 3 (22%) than in group 1 (21%). Clinical picture before and after application of gel in each group is shown in Figures 3, 4, and 5, respectively.

No adverse events were encountered in any group. During clinical examination, no patient had any clinical signs of allergic contact dermatitis or infection (no erythema of the skin around the ulcer, no swelling, no warmth on palpation, no odor, and no exudation).

The difference in the ulcer size before and after treatment in the three groups was compared using the Mann-Whitney U test. The results showed a significant difference among the three groups in ulcer size ($p < .005$) and depth ($p < .005$), with the best result occurring in group 3.

Discussion

Table 1 shows that the work risk and duration of ulcer formation were not different among the groups. At the end of the study, good clinical outcomes were obtained in all groups: 21 ulcers (98.5%) improved in group 1, 22 (100%) improved in group 3 with no worsening ulcers, and 22 (100%) improved in group 2. There was a trend for decreasing ulcer width and depth in groups 2 and 3 per week (Table 2). In the comparative test of the ulcer size among groups 1, 2, and 3, the mean width was significantly different ($p = .000$; $p = .000$; $p = .000$, respectively), but there was no

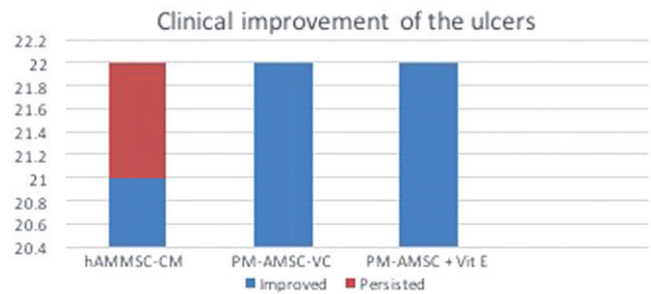


Figure 2. Clinical improvement of the ulcers at the end of the study.

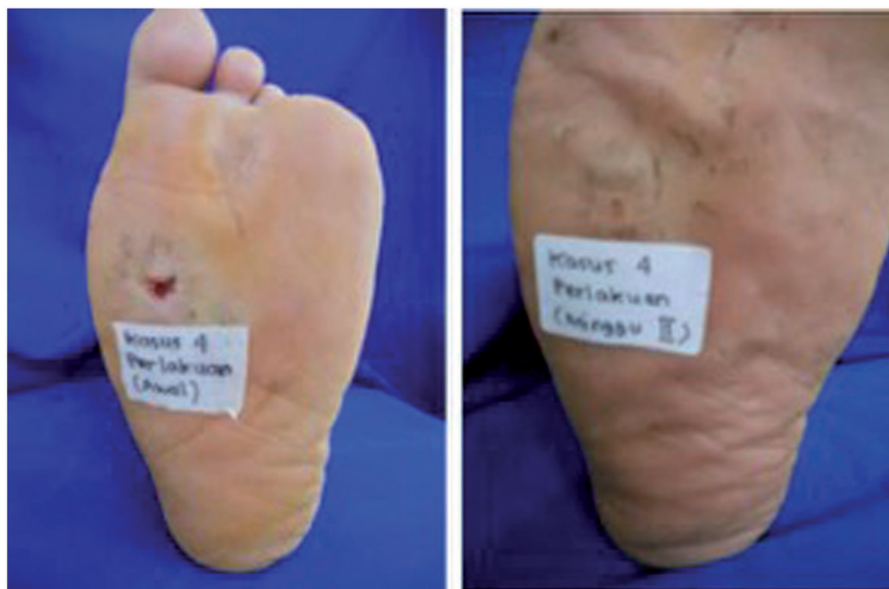

Figure 3. (A) Chronic ulcer before application in group 1. (B) Recovered ulcer at week 2 after gel application.

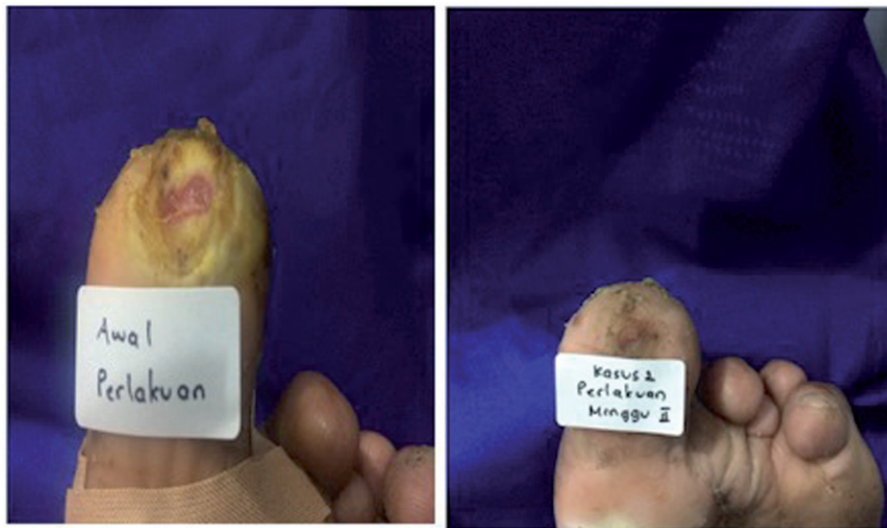

Figure 4. (A) Chronic ulcer before gel application in group 3. (B) Recovered ulcer at week 2 after gel application.

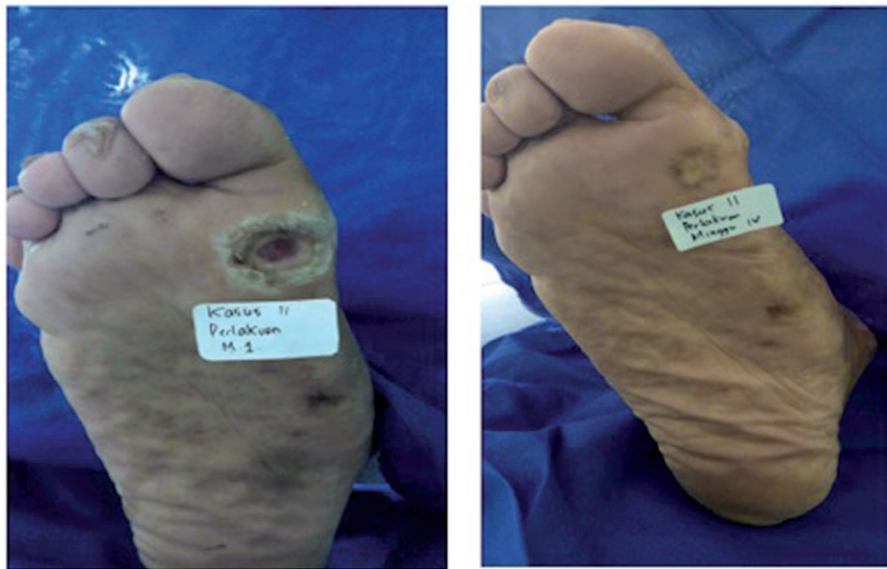

Figure 5. (A) Chronic ulcer before gel application in group 2. (B) Recovered ulcer at week 4 after gel application.

significant difference in mean depth from the beginning to the end of treatment. The results indicated that the mean weekly improvement in ulcer width up to the end of treatment was better in group 3 than in groups 1 and 2, whereas the mean depth improvement did not differ among the groups.

In dermatology, vitamin C is known as an antioxidant with a significant role in collagen synthesis. These functions are believed to be useful in wound healing. The antioxidant function of vitamin C is beneficial in neutralizing ROS present in chronic ulcers. Vitamin C also stimulates the collagen synthesis directly. SAP is a stable derivative of vitamin C. Although this derivative has the same function as that of vitamin C, it has better stability. The use of vitamin C and metabolite products simultaneously is expected to accelerate wound healing, with faster healing times, thereby resulting in less cost and increased quality of life of patients (19,20, 23–26).

To date, reports have discussed the effect of the mixture of hAMMSC-CM + vitamin E on the wound-healing process, but some studies have been conducted to determine the effect of growth factors and vitamin E separately on wound healing; all studies have shown satisfactory results (21,22).

A randomized controlled trial was conducted by Uchi et al. (9) to evaluate the efficacy of a topical fibroblast growth factor (bFGF) in 150 patients with chronic nonischemic diabetic ulcers. The subjects were divided into placebo ($n=51$), 0.001% bFGF ($n=49$), and 0.01% bFGF ($n=49$) groups and received treatment for a maximum of 8 weeks. At the end of the study, ulcers with a wound-healing area of $>75\%$ were found in 57.5%, 72.3%, and 82.2% of the patients, respectively, with a significant difference found between the 0.01% bFGF and placebo groups ($p=.025$) (9).

The results were in accordance with those of our study. The anti-inflammatory cytokines contained in the agents administered to groups 1–3 are thought to relieve tissue stress due to persistent pressure on the ulcers caused by work that requires much standing or walking. The levels of pro-inflammatory cytokines and increasing protease in chronic wounds cause the wound to remain in a prolonged inflammatory phase. A high protease enzyme will decrease the local growth factor production, and therefore, the wound will not enter the wound-healing proliferation phase (27,28).

A study analyzing the product of mesenchymal stem cell metabolites showed that many mediator substances, such as

growth factors, cytokines, and chemokines, that are essential for tissue repair can be found in the tissue medium of mesenchymal stem cell metabolites, particularly vascular endothelial growth factor, platelet-derived growth factor, basic fibroblast growth factor, epidermal growth factor, keratinocyte growth factor, and transforming growth factor- β (TGF- β). Applications of a topical metabolite stem cell product can overcome a prolonged inflammatory phase in chronic wounds because it contains anti-inflammatory cytokines and growth factors; thus, the inflammatory phase can be resolved, and the wound can enter the healing proliferation and remodeling phase (12,13).

Fiori et al. (10) compared the rate of ulcer healing in the fingers of patients with systemic sclerosis. One group received standard ulcer treatment plus vitamin E gel application, and one group only received standard care procedures. The healing time and resolution of pain were faster in the group receiving vitamin E gel compared with those in the control group ($p < .0001$) (10). Chronic ulcers showed increasing levels of ROS or free radicals, which could delay the wound-healing process and inhibit formation of granulation tissue and epithelialization. Vitamin E is an antioxidant that can reduce damage caused by free radicals released by neutrophils in the inflammatory phase of the wound-healing process (3,5). In addition to its antioxidant activity, vitamin E has anti-inflammatory and anti-aggregating properties and can cause vasodilation of small blood vessels. The level of vitamin E (α -tocopherol) in hAMMSC-CM + vitamin E gel is thought to reduce free radicals, reduce ischemic damage from reperfusion disorders, and stimulate growth and stabilization of granulation and re-epithelialization tissue that assisted in the ulcer-healing process in this study (22).

Table 2 shows the comparison of ulcer size before and after overall treatment in each group. There was a significant decrease in the ulcer width and depth: $1.70 \pm 1.05 \text{ cm}^2$, $p = .000$ in group 1, $2.84 \pm 1.67 \text{ cm}^2$, $p = .000$ in group 3, and $2.01 \pm 1.19 \text{ cm}^2$, $p = .000$ in group 2.

Reduced volume or depth of a wound was demonstrated by the proliferation of granulation tissue. Wound contraction was caused by granulation of the fibroblast/myofibroblast at the base of the wound. The degree of contraction and re-epithelialization in the chronic wound-healing process was highly dependent on the anatomic location and was not associated with the cause. Ligament retainers in loose tissue, such as the back, abdomen, or face, were more loose and rarer; thus, wound contraction had a major role in the healing process. Tightly adherent tissue, such as that in the palms, soles of the feet, or anterior tibial region, has a dense and firm skin ligament, and therefore the process of wound contraction was less important. The wound-healing process in these areas was more dependent on epithelialization. An ulcer on the plantar pedis has a larger surface epithelial area to be closed by re-epithelialization compared with the depth of the ulcer through formation of granulation tissue. This was because the wound on the sole of the foot did not contract, and thus there was only a small amount of granulation tissue underlying the ulcer surface. This caused no significant difference in the mean ulcer depth before and after treatment among all groups (24,25).

The present study has a few limitations. We did not conduct off-loading, i.e. reducing or removing the load on the legs. Off-loading can be conducted via bed rest or via the use of crutches, wheelchairs, walkers, and special footwear (16). The pressure on the plantar pedis in people with neuropathy should be distributed evenly to avoid high pressure in certain areas that may interfere with or inhibit healing of plantar ulcers. Subjects were recommended only to reduce standing or walking activities, but this was very difficult to implement because most subjects had to work to fulfill their daily needs. Another limitation was that there was no subject grouping based on the location of the ulcer and

anatomical structure. Because ulcer healing is influenced by the amount of pressure obtained during standing and walking, the location of the ulcer and its anatomical structure has an important role. Ulcers located on the protrusion of the bone (the soles of the front legs, the soles of the hind legs) experience higher pressure than those on the middle palm when standing or walking.

Conclusions

The hAMMSC-CM + vitamin E gel clinically and statistically decreased the mean ulcer width more significantly than hAMMSC-CM only and hAMMSC-CM + vitamin C, but there was no difference in the mean ulcer depth in all groups. All gels have been proven to decrease the size of chronic plantar of leprosy ulcers by increasing the mean healing of the ulcer width and depth every week until week 8, but the process was larger and faster in group 3. There were no complications or side-effects due to gels in any subject. Further experimental analytic research in randomized controlled clinical trials should be conducted to compare effects of the gel on healing of CPUL with off-loading in the form of a foot board specifically designed to help reduce stress and repetitive mechanical stress, which can affect the healing process. In addition, further studies should apply additional criteria in selecting a good match between the groups (matching) according to the location of the ulcer and anatomical structure to reduce bias.

Disclosure statement

No potential conflict of interest was reported by the authors.

Funding

This work was supported by Minister of Education and Technology Research, Indonesia [597/UN3.14/LT/2017].

ORCID

C. R. S Prakoeswa  <http://orcid.org/0000-0001-5325-2963>

References

1. Srinivasan H. Management of ulcers in neurologically impaired feet in leprosy affected persons. Surgical reconstruction and rehabilitation in leprosy and other neuropathies. 2004;15:193–226.
2. Dzikrina AM, Purnami SW. Modeling leprosy prevalence rate and the factors that influence in East Java with the approach of geographically weighted regression (GWR). J Sci Arts. 2013;2:2337–3520.
3. Robson M. The role of growth factors in the healing of chronic wounds. Wound Repair Regen. 1997;5:12–17.
4. Guo S, DiPietro LA. Factors affecting wound healing. J Dent Res. 2010;89:219–229.
5. Suryanarayan S, Budamakuntia L, Khadri SIS, et al. Efficacy of autologous platelet-rich plasma in the treatment of chronic nonhealing leg ulcers. Plast Aesthet Res. 2014;1:65–69.
6. Skardal A, Mack D, Kapetanovic E, et al. Bioprinted amniotic fluid-derived stem cells large Accelerate healing of skin wounds. Stem Cells. Transl Med. 2012;1:792–802.
7. Hendrijantini N, Kresnoadi U, Salim S, et al. Study biocompatibility and osteogenic differentiation potential of human

- umbilical cord mesenchymal stem cells (hucmscs) with gelatin solvent. *JBISE*. 2015;8:420–428.
8. Hatano K. Prevention and management of impairments and disabilities. In: Makino M, Matsuoka M, Goto M, et al. editors. *Leprosy-Science working towards dignity*. 1st ed. Kanagawa: Tokai University Press; 2011. p. 174–185.
 9. Rennie K, Gruslin A, Hengstschlager M, et al. Application of amniotic membrane and fluid in stem cell biology and regenerative medicine. *Stem Cells Int*. 2012;2012:721538.
 10. Jayaraman P, Nathan P, Vasanthan P, et al. Stem cell conditioned medium: a new approach to skin wound healing management. *Cell Biol Int*. 2013;37:1122–1128.
 11. Falanga V, Satori I. Mechanisms of wound repair, wound healing, and wound dressing. In: Goldsmith LA, Katz SI, Gilchrist BA, et al. editors. *Fitzpatrick's Dermatology in General Medicine*, 8th edition. New York: The McGraw-Hill Companies; 2008. p. 2984–2996.
 12. Diaz-Prado S, Lopez EM, Gomez TH, et al. Isolation and characterization of mesenchymal stem cells from human amniotic membrane. *Tissue Eng Part C Methods*. 2011;17:49–59.
 13. Ennis WJ, Sui A, Bartholomew A. Stem cells and healing: impact on inflammation. *Adv Wound Care (New Rochelle)*. 2013;2:369–378.
 14. Gregory C, Gunn W, Peister A, et al. An alizarin red-based assay of mineralization by adherent cells in culture: comparison with cetylpyridinium chloride extraction. *Anal Biochem*. 2005;329:77–84.
 15. Havlik RJ. Vitamin E and wound healing. Plastic surgery educational committee the data foundation. *Plast Reconstr Surg*. 1997;100:1901–1902.
 16. Kouroupis D, Churchman S, English A, et al. Assessment of umbilical cord tissue as a source of mesenchymal stem cell/endothelial cell mixtures for bone regeneration. *Regen Med*. 2013;8:569–581.
 17. Barreto JG, Salgado CG. Clinic-epidemiological evaluation of ulcers in patients with leprosy sequelae and the effect of low level laser therapy on wound healing: a randomized clinical trial. *BMC Infect Dis*. 2010;237:1–9.
 18. Prakoeswa CRS. Efficacy of topical human amniotic membrane mesenchymal stem cell-conditioned medium (hAMMSC-CM) on the healing of chronic plantar ulcers in leprosy: a controlled prospective clinical trial Forthcoming.
 19. Telang PS. Vitamin C in dermatology. *Indian Dermatol Online J*. 2013;4:143–146.
 20. Moro O. Biological activities of stable ascorbic acid derivative, 2-O-a-D-glucopyrasonyl-L-ascorbic acid (AA-2G) in cosmetics. Shiseido Research Center. *J Appl Cosmetol*. 1999;18:154–163.
 21. Thiele J, Ekanayake-Mudiyanselage S. Vitamin E in human skin: organ-specific physiology and consideration for its use in dermatology. *Mol Aspects Med*. 2007;28:646.
 22. Fiori G, Galluccio F, Braschi F, et al. Vitamin E gel Reduces the time of healing of digital ulcers in systemic sclerosis. *Clin Exp Rheumatol*. 2009;27:51–54.
 23. Maxson S, Lopez EA, Yoo D, et al. Concise review: the role of mesenchymal stem cells in wound repair. *Stem Cells Transl Med*. 2012;1:142–149.
 24. Levinson H. A Paradigm of fibroblast activation and dermal wound contraction to guide the development of therapies for chronic wounds and pathologic scars. *Adv Wound Care (New Rochelle)*. 2013;2:149–159.
 25. Wu SC, Crews RT, Armstrong DG. The pivotal role of offloading in the management of neuropathic foot ulceration. *Curr Diab Rep*. 2005;5:423.
 26. Singh P, Singh P. Role of topical ascorbic acid in management of refractory corneal ulcer. *IOSR J Pharm*. 2012;2:1–4.
 27. Sarpooshi HM, Vaheb M, Tabarayee Y, et al. The effects of topical vitamin C solution on the necrotic tissue volume of burn wounds. *JNMS*. 2016;3:11–17.
 28. Fite A, Dykhuizen R, Litterick A, et al. Effects of Ascorbic acid, glutathione, thiocyanate, and iodide on antimicrobial activity of acidified nitrite. *Antimicrob Agents Chemother*. 2004;48:655–665.