

# Effect of Probiotic on Repair of Ethanol-induced Gastric Mucosal Erosion in Wistar Rats

*by Alpha Fardah A*

---

**Submission date:** 15-Oct-2022 05:35PM (UTC+0800)

**Submission ID:** 1925946636

**File name:** Jurnal\_ke\_6\_-\_Volume3-Issue3-May-Jun-No.269-363-367.pdf (271.52K)

**Word count:** 3256

**Character count:** 17258

## Effect of Probiotic on Repair of Ethanol-induced Gastric Mucosal Erosion in Wistar Rats

Dedy Setiawan\*, Alpha Fardah Attiyah, Reza Gunadi Ranuh, Andy Dharma, Subijanto Marto Sudarmo

Department of Child Health, Medical Faculty Airlangga University  
Dr. Soetomo General Hospital, Surabaya, 60286, Indonesia

E-mail : [dedydr81@gmail.com](mailto:dedydr81@gmail.com); [alpha-f-a@fk.unair.ac.id](mailto:alpha-f-a@fk.unair.ac.id);  
[rezagunadi@gmail.com](mailto:rezagunadi@gmail.com); [andarma@gmail.com](mailto:andarma@gmail.com)

\*Corresponding author details: Dedy Setiawan; [dedydr81@gmail.com](mailto:dedydr81@gmail.com)

### ABSTRACT

**Background:** Probiotics can increase mucus secretion as a mechanism to improve barrier function and pathogen exclusion. Several Lactobacillus species can increase mucin expression in human intestinal cells. Lactobacillus Plantarum IS-10506 is a probiotic native to Indonesia derived from curd, fermented milk from Sumatra. Research with Lactobacillus Plantarum IS-10506 showed a protective effect as well as a therapeutic effect on intestinal mucosal damage to the ileum. **Objective:** Analyzing the effect of probiotic Lactobacillus Plantarum IS-10506 on the acceleration of ethanol-induced gastric mucosal erosion regeneration. **Method:** Experimental research used 48 rats that were fasted and divided into 3 groups those are K1 group control group, group K2 which was treated with ethanol 43%, and group K3 which was treated with ethanol and probiotic Lactobacillus Plantarum IS-10506. Each group was divided into 4 subgroups based on the day of the sacrifice those are days 1, 3, 5, and 7. The treatment of the test animals is done in 7 days. Epithelial defect was measured by using histopathologic scoring by Roger's **Results:** The score of Epithelial defect Group K2 was significantly different compared to group K1 ( $p=0.036$ ), and K3 ( $p=0.007$ ). The gastric mucosal repair was completed in day 7 in the probiotic group. **Conclusion:** Probiotic Lactobacillus Plantarum IS-10506 accelerate mucosal repair in ethanol induced gastric mucosal injury

**Keywords:** Lactobacillus Plantarum IS-10506; ethanol; gastric mucosal repair

### INTRODUCTION

Gastric mucosal erosion is mucosal damage that is limited to the mucosal layer without involving the muscularis mucosa.<sup>1</sup> Erosion of the gastric mucosa is provoked by an imbalance between aggressive and defensive factors in the digestive tract.<sup>2</sup> Activation of defense factors and repair of gastric mucosa such as bicarbonate mucus layer, prostaglandins, growth factors for epithelial regeneration and microcirculation, are important factors to overcome gastric mucosal damage. Of these factors, mucus is the first layer of defense of the gastric mucosa, and is known to play a major role against aggressive factors. Mucin is part of the dynamic mucosal defense system of the gastrointestinal tract. Three of these genes are expressed in the normal gastric mucosa, namely MUC1 and MUC5AC expressed in the superficial foveolar epithelium and MUC6 in the neck cells of the fundal mucosa and antral-type gland cells in the cardia and antrum.<sup>3-5</sup> Probiotics can increase mucus secretion as a mechanism to improve barrier function and pathogen exclusion. Several Lactobacillus species can increase mucin expression in human intestinal cells. Lactobacillus Plantarum IS-10506 is a probiotic native to Indonesia derived from curd, fermented milk from Sumatra. Research with Lactobacillus Plantarum IS-10506 showed a protective effect as well as a therapeutic effect on intestinal mucosal damage to the ileum. Previous studies have described the mechanism of activation, proliferation and differentiation of intestinal stem cells by

the probiotic Lactobacillus Plantarum IS-10506 to accelerate the regeneration of intestinal mucosa damaged by Escherichia coli Lipopolysaccharide O55:B55.<sup>6</sup> The gastric mucosa has a mucosal renewal mechanism similar to that of the intestinal mucosa. With many studies proving that probiotics have the effect of regenerating the damaged gastric mucosa and also the ability of Lactobacillus spp which was found to survive on the gastric mucosa, it is assumed that Lactobacillus spp has the ability to accelerate the regeneration of the gastric mucosa.<sup>7</sup> Based on these assumptions, it is necessary to conduct research to see the effect of the probiotic Lactobacillus Plantarum on the repair of the gastric mucosa.

### MATERIALS AND METHODS

The type of research used is experimental. The sample and treatment are expected to be controlled, and measurable, and the effect of the treatment can be more reliable. The study design was designed to prove that the administration of the probiotic Lactobacillus Plantarum IS-10506 accelerates the regeneration of damaged mucosa after administration of ethanol. The research design is The Paired Randomized Post Test Only Control Group Design. The research sample used Wistar male white rats aged 12 weeks with a bodyweight of 180-200 grams which were divided into four groups randomly.

All rats were acclimatized for 7 days by feeding and drinking *ad libitum*. The room is set with a temperature of 25-30 °C, a humidity of 50-60% and a light-dark cycle of 12 hours each. The 48 male Wistar rats were grouped into 3 groups, Group 1, a control group containing 4 rats, group 2 ethanol 43% and group 3 ethanol and probiotic. Each group was divided into 4 subgroups based on the day of sacrifice, days 1, 3, 5, and 7.

The treatment for each rat in each group was carried out as planned. The K2 group was given ethanol per probe and the K3 was given the probiotic *Lactobacillus Plantarum* IS 10506 and ethanol per probe. Provision of probiotics at a dose of  $2.86 \times 10^{10}$  CFU/day was carried out individually every day in the K3 group.<sup>6</sup> The K1 group was given a placebo using sterile water per probe for 14 days. Ethanol at a dose of 5ml/kg BW was administered once on the 1st day of the study. After observation and treatment, four subjects were sacrificed on day 1, then 4 subjects were sacrificed on days 3, 5, and 7. The unit of analysis examined in this study was the antrum-stomach of Wistar rats. The gastric mucosa was examined by HE C staining. Microscopically, mucosal damage was scored using the Rogers method.

**Assessment of microscopic observations.**

Microscopic observations were made based on the area of the mucosal lesion and the depth of the ulcer in the mucosa area. The level of damage was assessed based on the HAI (Histology Activity Index) method according to Rogers, (2012) which was modified with the following criteria: inflammation, epithelial defects, oxyntic atrophy/degeneration, submucosal edema, and hemorrhage. Each criterion has a score range of 0-4 (0=no abnormality, 1 = abnormality <25% of the entire field of view, 2 = abnormality of 25%-50% of the entire field of view, 3 = abnormality of 50% - 75% of the entire field of view, 4 = abnormality > 75% of the entire field of view).<sup>7</sup>

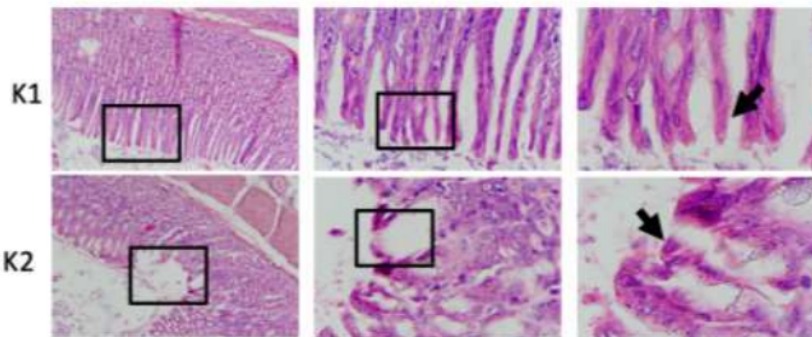
This examination uses an ordinary Nikon E100 a light microscope that is equipped with a 12-megapixel Optilab Advance Plus digital camera and Image Raster image processing software. The samples were observed in 5 fields of view in each group using a microscope with 100x and 400x magnification by 2 observers without knowing the sample group (blinded observer). Data showing the level of damage to the gastric mucosa were obtained using a semi-quantitative method based on the average score that appeared. The results of observations from 2 blinded observers are presented in the form of an average. The data were tested for normality using the Shapiro-Wilk test. The data distribution is not normal then use a non-parametric test using the non-parametric Kruskal-Wallis test.

**RESULTS**

Microscopic assessment of gastric mucosal damage was carried out based on the sum of the percentage values of the lesion area and the value of the epithelial defect. Damage to the gastric mucosa can be in the form of erosion. Erosion is a state of dissolution of the epithelial layer of the gastric mucosa. The data of microscopic damage to the gastric mucosa are presented in the mean form. The mean difference test between treatment groups with the Kruskal Wallis test showed that there were significant differences in several treatment groups with a p-value = 0.041 (p <0.05). The microscopic picture of mucosal damage can be seen in Figure 1 and the average value of mucosal damage can be seen in Table 1. The results showed that there were significant differences in epithelial damage scores between the control group and the ethanol treatment group. It can be seen in table 2 that the gastric mucosal damage in the ethanol treatment group was significant when compared to the control group on all necropsy days, indicating damage that lasted until the 7th day.

**TABLE 1:** The average value of gastric mucosal damage in group based on day of sacrifice

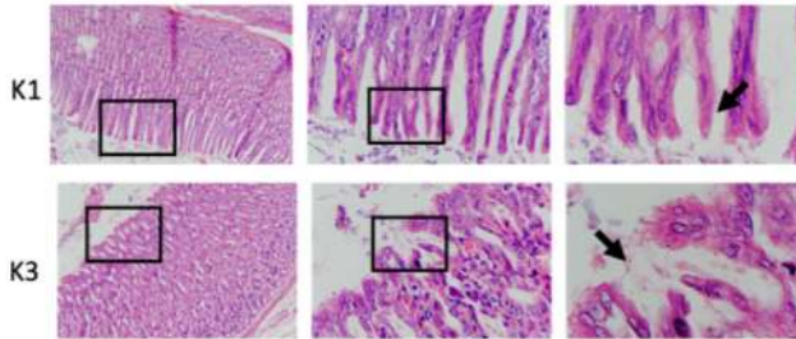
Group	Day of Sacrifice	Epitel defect score (mean±SD)
K1 (Control)	Day 1	0.00 ± 0.00
	Day 3	0.00 ± 0.00
	Day 5	0.00 ± 0.00
	Day 7	0.00 ± 0.00
K2 (Ethanol)	Day 1	4.00 ± 0.00
	Day 3	3.33 ± 0.33
	Day 5	2.67 ± 0.33
	Day 7	2.00 ± 0.00
K3 (Ethanol + Probiotik)	Day 1	3.00 ± 0.57
	Day 3	2.33 ± 0.33
	Day 5	1.67 ± 0.33
	Day 7	0.67 ± 0.33



**FIGURE 1:** Comparison of epithelial images between ethanol groups and control (Hematoxylin-Eosin stain: 100x, 400x and 1000x magnification)

**TABLE 2:** Comparison of epithelial damage between control group (K1) and ethanol group (K2)

Parameter	Day of sacrifice	K1	K2	p
		Mean (SD)	Mean (SD)	
epitel defect	day-1	0.00 ± 0.00	4.00 ± 0.00	p=0,025
	day-3	0.00 ± 0.00	3.33 ± 0.33	p=0,025
	day-5	0.00 ± 0.00	2.67 ± 0.33	p=0,037
	day-7	0.00 ± 0.00	2.00 ± 0.00	p=0,034



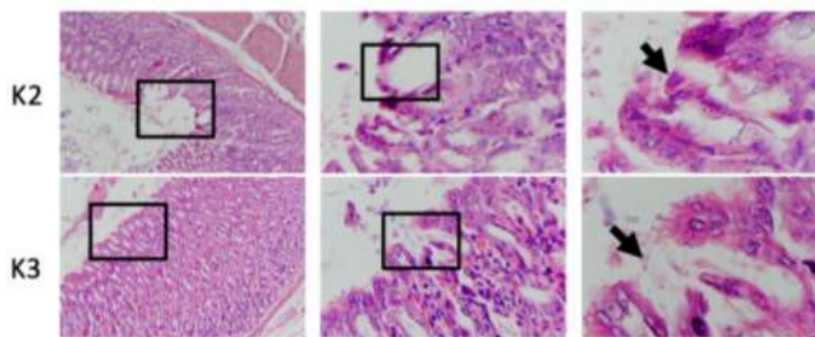
**FIGURE 2:** Comparison of epithelial images between control groups and probiotic group (Hematoxylin-Eosin stain: 100x, 400x and 1000x magnification)

**TABLE 3:** Comparison of epithelial damage between control group (K1) and ethanol group (K3)

Parameter	Day of sacrifice	K1	K3	p
		Mean (SD)	Mean (SD)	
epitel defect	day-1	0.00 ± 0.00	3.00 ± 0.57	p=0.034
	day-3	0.00 ± 0.00	2.33 ± 0.33	p=0.034
	day-5	0.00 ± 0.00	1.67 ± 0.33	p=0.034
	day-7	0.00 ± 0.00	0.67 ± 0.33	p=0.114

In table 3 it can be seen that the level of gastric mucosal damage in the probiotic ethanol group there was a significant difference when compared to the control group on days 1,3 and 5 but did not differ on day 7, this indicates

that the administration of probiotics after exposure to ethanol accelerated the improvement of gastric mucosal damage on day 7th.



**FIGURE 3:** Comparison of epithelial images between ethanol groups and probiotic group (Hematoxylin-Eosin stain: 100x, 400x and 1000x magnification)



TABLE 4: Comparison of epithelial damage between control group (K2) and ethanol group (K3)

Parameter	Day of sacrifice	K2	K3	p
		Mean (SD)	Mean (SD)	
epitel defect	day-1	4.00 ± 0.00 <sup>a</sup>	3.00 ± 0.57	p=1,0
	day-3	3.33 ± 0.33 <sup>b</sup>	2.33 ± 0.33 <sup>a</sup>	p=0,034
	day-5	2.67 ± 0.33 <sup>c</sup>	1.67 ± 0.33 <sup>b</sup>	p=0,184
	day-7	2.00 ± 0.00 <sup>d</sup>	0.67 ± 0.33 <sup>c</sup>	p=0,487
		pa,c= 0,122 pa,d= 0,034	pa,c= 0,043 pb,c= 0,099	

In table 4 it can be seen that the group that was given probiotics after exposure showed lighter gastric mucosal damage and faster healing when compared to the group given ethanol exposure alone, healing in the K3 group started on day 3 after exposure. While in K2 the repair of epithelial damage occurred on day 7 (p = 0.034) but had not healed completely yet like the control group.

#### DISCUSSION

In the ethanol treatment group, the score of gastric mucosal epithelial damage was higher than the control group and on the microscopic picture, it was seen that the epithelial damage was wider in the group given ethanol. This shows that ethanol is indeed a strong gastric destroying factor. Ethanol can cause damage to the gastric mucosal barrier so that it allows back diffusion of Hydrochloric Acid (HCL) which causes tissue damage in the stomach, tissue damage will stimulate inflammatory mediators, one of which is histamine which will stimulate more HCL secretion and increase protein permeability. Mucosa becomes edematous and protein will decrease. The capillary mucosa is damaged, causing interstitial hemorrhage and bleeding.<sup>8</sup>

In the group given probiotics after exposure to ethanol, the damage was significantly different when compared to the group given ethanol only, this indicates that probiotics have a therapeutic effect on mucosal damage induced by ethanol. The repair process of gastric epithelial damage in both groups went the same way, but in the ethanol group until the 7th day, it still did not return to normal. Research on the role of probiotics in healing gastric mucosal damage has been reported mainly in rats. This study was based on the use of individual probiotic strains, such as *Lactobacillus rhamnosus* GG 9, *Lactobacillus gasseri* OLL271610, *Lactobacillus acidophilus* 11, *Bifidobacterium animalis* VKL/VKB12, or mixed probiotic strains, such as VSL#3.<sup>13</sup>

The effect of probiotics on gastric ulcers is associated with several mechanisms. The first mechanism is through the protection of the gastric mucosal layer. In a normal stomach, mucosal integrity is maintained by three main layers, the first being the preepithelial layer made of a mucus-bicarbonate-phospholipid layer which lies between the gastric lumen and the epithelium. The second layer is the epithelium which is characterized by a) sheets of surface epithelial cells that are continuously connected by tight junctions and produce different secretory products including trefoil factors, prostaglandins, and heat shock proteins, and b) continuous cell renewal achieved by stem cell proliferation. progenitor and is regulated by different mechanisms involving growth factors, prostaglandins, gastrin and the anti-apoptotic protein surviving. The third layer is subepithelial consisting of a) microcirculation through the capillaries which is maintained by the formation of prostaglandins, nitric oxide and hydrogen sulfide which protect endothelial cells from injury and prevent platelet

and leukocyte aggregation, and b) sensory innervation that regulates mucosal blood flow.<sup>14</sup>

The next mechanism of probiotics in protecting the gastric mucosa is through the production of prostaglandins, growth factors<sup>9</sup> and anti-inflammatory cytokines. Prostaglandins are involved in the ulcer healing process by inhibiting acid secretion, stimulating the production of mucus, bicarbonate and phospholipids, increasing blood flow and accelerating epithelial recovery<sup>15</sup>. Therefore, prostaglandins are also considered as targets for the prophylactic effect of probiotics in gastric ulcers.<sup>10-11</sup> Ethanol-induced gastric mucosal lesions in rats were prevented by pre-treatment with the probiotic strain *Lactobacillus rhamnosus* GG through upregulation of prostaglandin E2.<sup>11</sup> The effectiveness of the probiotic strain *Escherichia coli* Nissle 1917 in preventing stress ulcers in rats has also been reported. This effect is achieved through induction of mucosal anti-inflammatory cytokines, synthesis of gastric mucosal protective factors (ghrelin and heat shock protein 70), enhancement of gastric microcirculation, and involvement of prostaglandins and nitric oxide.<sup>16</sup>

In this study, it was found that the group given probiotics showed lighter gastric mucosal damage and faster gastric mucosal repair than the ethanol exposure group that was left to repair naturally. A number of studies have reported that probiotics not only inhibit the development of acute gastric mucosal lesions, but also accelerate the healing process of gastric ulcers.<sup>10,11,14</sup> Gastric wall regeneration is associated with increased stem cell proliferation and increased production of protective factors such as mucus, and restoration of aggressive factors produced by acid and pepsin-secreting cells. Therefore, the protective and therapeutic effect of probiotics against gastric erosion involves modulating not only dividing stem cells but also derivatives of gastric secretory cells.<sup>17</sup>

#### CONCLUSION

This study shows that probiotic *Lactobacillus Plantarum* IS-10506 enhances the acceleration of microscopic repair of ethanol-induced gastric mucosal damage.

#### REFERENCES

- [1] Yardley JH dan TR. Hendrix.1995. Gastritis, duodenitis, and associated ulcerative lesions. In Yamada T, Alpers DH, Owyang C, Powell DW & Silverstein FE (eds) Textbook of Gastroenterology. Philadelphia, Lippincott: 1456-1493.
- [2] Saverio SD, Bassi M, Smereiri N, M Masetti, F Ferrara, C Fabri, L. Ansaloni, S. Gherzi, M. Serenari, F. Coccolini, N. Naidoo, M. Sartelli, G. Tugnoli, F. Catena, V. Cennamo, E. Jovine. 2014. Diagnosis and treatment of perforated or bleeding peptic ulcers: WSES position paper. World Journal of Emergent Surgery. 9:1.

- [3] Audie JP, A. Janin dan N. Porchet. 1993. Expression of human mucin genes in respiratory, digestive, and reproductive tracts ascertained by in situ hybridization. *Journal of Histochemistry and Cytochemistry*. 41:1479-1485
- [4] Carrato C., C. Balague C., C. de Bolos., E.Gonzalez, G. Gambus, J. Planas, J.Perini, D.Andreu, and F.X.Real. 1994. Differential apomucin expression in normal and neoplastic human gastrointestinal tissues. *Gastroenterology*. 107: 160-172
- [5] de Bolos C., M. Garrido M. and F.X. Real. 1995. MUC6 apomucin shows a distinct normal tissue distribution that correlates with Lewis antigen expression in the human stomach. *Gastroenterology*. 109: 723-734.
- [6] Athiyyah A.F., R.Ranuh, A. Darma., P.R Vitria., W.Riawan, I.A Surono., dan S.M.Sudarmo 2019. Effect of the probiotic *Lactobacillus Plantarum* IS-10506 on accelerating the regeneration of the intestinal mucosa structure examined by scanning electron microscope. *Carpathian Journal of Food Science and Technology*, Special issue. 10: 11-18
- [7] Rogers, A. B. (2012). Histologic Scoring of Gastritis and Gastric Cancer in Mouse Models. *Methods in Molecular Biology*, 189-203. doi:10.1007/978-1-62703-005-2\_22
- [8] Niv Y., dan M.Banic. 2014. Gastric Barrier Function and Toxic Damage. *Digestive Diseases*. 32: 235-42.
- [9] Lam E.K., L. Yu L, H.P. Wong, WK. Wu, VY. Shin, EK. Tai, WH. So, PC. Woo CH. Cho. 2007. Probiotic *Lactobacillus rhamnosus* GG enhances gastric ulcer healing in rats. *European Journal of Pharmacology*. 565: 171-179
- [10] Uchida M. and K. Kurakazu . 2004. Yogurt containing *Lactobacillus gasseri* OLL2716 exerts gastroprotective action against acute gastric lesion and antral ulcer in rats. *Journal of Pharmacological Sciences*. 96: 84-90.
- [11] Singh PK. and IP. Kaur. 2012. Synbiotic (probiotic and ginger extract) loaded floating beads: A novel therapeutic option in an experimental paradigm of gastric ulcer. *The Journal of Pharmacy and Pharmacology*. 64: 207-217.
- [12] Spivak ML., LM. Lazarenko, TM. Falalieieva, OV. Virchenko, KS. Neporada. 2013. Prophylactic effect of probiotic strains *Bifidobacterium animalis* VKL and VKB on stress-induced lesions in the gastric mucosa of rats. *Fiziol Zh*. 59: 23-30.
- [13] Dharmani P., C. De Simone and K. Chadee. 2013. The probiotic mixture VSL#3 accelerates gastric ulcer healing by stimulating vascular endothelial growth factor. *PLoS One* 8: 58671.
- [14] Laine L., K. Takeuchi, dan A. Tarnawski. 2008. Gastric Mucosal Defense and Cytoprotection: Bench to Bedside. *Gastroenterology*. 135: 41-60.
- [15] Takeuchi K, Komoike Y, Takeeda M, Ukawa H. 2002. Gastric mucosal ulcerogenic responses following barrier disruption in knockout mice lacking prostaglandin EP1 receptors. *Aliment Pharmacol Ther*. 16: 74-82.
- [16] Konturek P.C., Z. Sliwoski, J. Koziel, A. Ptak-Belowska, G. Burnet, T. Brzozowski. 2009. Probiotic *Escherichia coli* Nissle 1917 Attenuates Acute Gastric Lesions Induced by Stress. *J. Physiol. Pharmacol*. 60: 41-48
- [17] Farah A., G. Khoder, S. Sugathan, P. Saseedharan, A. Menhali, and S. M. Karam. 2021. Modulation of Stem Cell Progeny by Probiotics during Regeneration of Gastric Mucosal Erosions. *Biology*. 596: 1-22

# Effect of Probiotic on Repair of Ethanol-induced Gastric Mucosal Erosion in Wistar Rats

## ORIGINALITY REPORT

17%

SIMILARITY INDEX

14%

INTERNET SOURCES

8%

PUBLICATIONS

0%

STUDENT PAPERS

## PRIMARY SOURCES

1	<a href="http://juke.kedokteran.unila.ac.id">juke.kedokteran.unila.ac.id</a> Internet Source	1%
2	<a href="http://www.mdpi.com">www.mdpi.com</a> Internet Source	1%
3	<a href="http://medicaljournals.se">medicaljournals.se</a> Internet Source	1%
4	<a href="http://mts.intechopen.com">mts.intechopen.com</a> Internet Source	1%
5	<a href="http://www.medicaljournals.se">www.medicaljournals.se</a> Internet Source	1%
6	<a href="http://archive.org">archive.org</a> Internet Source	1%
7	<a href="http://www.atmph-specialissues.org">www.atmph-specialissues.org</a> Internet Source	1%
8	<a href="http://karnaval.com">karnaval.com</a> Internet Source	1%
9	Hye Seung Lee. "MUC1, MUC2, MUC5AC, and MUC6 expressions in gastric carcinomas",	1%

## Cancer, 09/15/2001

Publication

10

[www.himalayahealthcare.com](http://www.himalayahealthcare.com)

Internet Source

1 %

11

Kazuyo Sakanoi. "Temporal and spatial structures of flickering aurora derived from high-speed imaging photometer observations at Syowa Station in the Antarctic", Journal of Geophysical Research, 2004

Publication

1 %

12

Nabendu Debnath, Ashok Kumar Yadav. "Chapter 9 Indigenous Probiotic Lactobacillus Strains to Combat Gastric Pathogen Helicobacter pylori: Microbial Interference Therapy", Springer Science and Business Media LLC, 2021

Publication

1 %

13

[gsconlinepress.com](http://gsconlinepress.com)

Internet Source

1 %

14

[researchoutput.csu.edu.au](http://researchoutput.csu.edu.au)

Internet Source

<1 %

15

[oamjms.eu](http://oamjms.eu)

Internet Source

<1 %

16

[www.scielo.br](http://www.scielo.br)

Internet Source

<1 %



17 Noraziah Nordin, Suzy Munir Salama, Shahram Golbabapour, Maryam Hajrezaie et al. "Anti-Ulcerogenic Effect of Methanolic Extracts from *Enicosanthellum pulchrum* (King) Heusden against Ethanol-Induced Acute Gastric Lesion in Animal Models", PLoS ONE, 2014  
Publication

---

18 [academic.oup.com](http://academic.oup.com)  
Internet Source

---

19 [es.scribd.com](http://es.scribd.com)  
Internet Source

---

20 [media.proquest.com](http://media.proquest.com)  
Internet Source

---

21 [wjgnet.com](http://wjgnet.com)  
Internet Source

---

22 Brancati, Serena B., Zoltán S. Zádori, József Németh, and Klára Gyires. "Substance P induces gastric mucosal protection at supraspinal level via increasing the level of endomorphin-2 in rats", Brain Research Bulletin, 2013.  
Publication

---

23 Ham, Maggie, Yasutada Akiba, Koji Takeuchi, Marshall H Montrose, and Jonathan D. Kaunitz. "Gastroduodenal Mucosal Defense",

# Physiology of the Gastrointestinal Tract Two Volume Set, 2012.

Publication

24

Martin Kunes, Jaroslav Kvetina. "Probiotics",  
Elsevier BV, 2016

Publication

<1 %

25

[arccjournals.com](http://arccjournals.com)

Internet Source

<1 %

26

[eprints.um.edu.my](http://eprints.um.edu.my)

Internet Source

<1 %

27

Akyurek, N.. "Expression of MUC1 and MUC2  
Mucins in Gastric Carcinomas: Their  
Relationship with Clinicopathologic  
Parameters and Prognosis", Pathology -  
Research and Practice, 2002

Publication

<1 %

28

Emily K.Y. Lam, Emily K.K. Tai, Marcel W.L.  
Koo, Helen P.S. Wong et al. "Enhancement of  
gastric mucosal integrity by Lactobacillus  
rhamnosus GG", Life Sciences, 2007

Publication

<1 %

29

Matteo Fornai, Luca Antonioli, Rocchina  
Colucci, Marco Tuccori, Corrado Blandizzi.  
"Chapter 7 Pathophysiology of Gastric Ulcer  
Development and Healing: Molecular  
Mechanisms and Novel Therapeutic Options",  
IntechOpen, 2011

Publication

<1 %

---

Exclude quotes      Off

Exclude matches      Off

Exclude bibliography      On

# Effect of Probiotic on Repair of Ethanol-induced Gastric Mucosal Erosion in Wistar Rats

---

GRADEMARK REPORT

---

FINAL GRADE

**/0**

GENERAL COMMENTS

**Instructor**

---

PAGE 1

---

PAGE 2

---

PAGE 3

---

PAGE 4

---

PAGE 5

---