

Nerve growth factor and S100B: Molecular marker of neuroregeneration after injection of freeze-Dried platelet rich plasma

by Desiana Radithia

Submission date: 19-Jan-2023 12:32PM (UTC+0800)

Submission ID: 1995190197

File name: 1-s2.0-S2212426822000835-main.pdf (2.87M)

Word count: 5088

Character count: 26042



Contents lists available at ScienceDirect

Journal of Oral Biology and Craniofacial Research

journal homepage: www.elsevier.com/locate/jobcr



Nerve growth factor and S100B: Molecular marker of neuroregeneration after injection of freeze-Dried platelet rich plasma

Rahmi, Desiana Radithia, Bagus Soebadi, Adiastruti Endah Parmadiati, Saka Winias*

Department of Oral Medicine, Faculty of Dental Medicine, Universitas Airlangga, Surabaya, Indonesia

ARTICLE INFO

Keywords:

Freeze-dried platelet rich plasma
Nerve growth factor
S100B
Neuroregeneration
Crush injury

ABSTRACT

Introduction: Chronic orofacial pain is associated with nerve tissues damage. Pharmacological therapy has limited therapeutic results because it is generally only symptomatic treatment. Neuroregeneration is a process which is needed to repair damaged of nerve tissue through healing or regrowth of nerve tissue. The survival of nerve cells need neurotrophic factors including Nerve Growth Factor (NGF) and S100B. High platelet concentrations in Platelet Rich Plasma contain of many trophic factors which play an important role in peripheral nerve regeneration following nerve injury. The aim of the present study is to analyze the increased expression of NGF and S100B following injection of Freeze-Dried Platelet Rich Plasma (FD-PRP) on axonotmesis injury.

Methods: Fifty-four male wistar rats aged 3 months randomly divided into 3 groups; negative control group (without nerve injury and without FD-PRP injection), positive control group (nerve injury but without FD-PRP injection) and treatment group (nerve injury and FD-PRP injection). Axonotmesis nerve injury created by clamping the infraorbital nerve for 15 s. Application of FD-PRP by injection technique. Examination of NGF and S100B expression was obtained by immunohistochemistry examination with monoclonal antibodies (anti-NGF and anti-S100B). Samples were taken on the 14th day and 21st day.

Results: Treatment group showed significant increase on both NGF and S100B compare to positive control ($p = 0,000$ and $p = 0,000$, respectively).

Conclusion: FD-PRP injection is effective in inducing neuroregeneration by increasing NGF and S100B expression.

26 1. Introduction

Orofacial pain is pain that occurs around the face and neck area. This pain can occur episodically, can also occur continuously and can be acute or chronic. Nociceptive pain is acute pain and is not accompanied by minimal nerve damage or nerve tissue damage. While neuropathic pain is pain that comes from nerve tissue damage that generally goes on chronically.^{1–3} Orofacial pain is estimated to occur in about 23% of the general population, where 7%–11% experience chronic pain.¹ The results of international epidemiological studies indicate if orofacial pain is experienced by about 10% of the adult population, especially women.⁴ Chronic ongoing pain will cause emotional, psychological and social disorders which will ultimately affect the quality of life of patients.^{1,5}

Neuropathic pain which is chronic pain can accompany several diseases such as *diabetic peripheral neuropathy*, *HIV-associated neuropathy*, *chemotherapy-induced peripheral neuropathy* (CIPN), *Post herpetic neuralgia*

(PHN) and trigeminal neuralgia.⁶ Neuropathic pain is a form of chronic pain that is very challenging to treat. During this pharmacological therapy to cope with neuropathic pain has many limitations on the results of therapy, where the drugs given are generally only symptomatic.^{7,8} Only about 50% of patients who receive neuropathic pain treatment feel that the pain decreases but does not disappear completely, besides that often the side effects of the drug cannot be tolerated by the patient, so the most rational approach to neuropathic pain therapy is based on the mechanism of neuropathic pain.⁹

Neuroregeneration is a process needed for the treatment of neuropathic pain, in which nerve tissue repair occurs through regrowth or healing of nerve tissue, cells, or cell products. To survive nerve cells need neurotrophic factors.^{10,11} These neurotrophic factors include *Nerve Growth Factor* (NGF) and S100B. Neural networks are able to produce these neurotrophic factors, but sometimes they cannot be produced quickly or cannot be produced in sufficient quantities.¹² Exogenous

* Corresponding author. Department of Oral Medicine, Faculty of Dental Medicine, Universitas Airlangga, Jl. Prof. Dr. Moestopo No. 47 Surabaya, East Java, 60132, Indonesia.

E-mail addresses: rahmikg28@gmail.com (Rahmi), deisy.radithia@fkg.unair.ac.id (D. Radithia), b.soebadi@gmail.com (B. Soebadi), adiastuti-e-p@fkg.unair.ac.id (A.E. Parmadiati), saka.winias@fkg.unair.ac.id (S. Winias).

<https://doi.org/10.1016/j.jobcr.2022.07.006>

Received 19 July 2020; Received in revised form 28 March 2022; Accepted 16 July 2022

Available online 19 July 2022

2212-4268/© 2022 Published by Elsevier B.V. on behalf of Craniofacial Research Foundation.

neurotrophic factor supplies will maintain an environment conducive to nerve regeneration, prevent nerve cell damage and will promote nerve regeneration.¹³

One technique that can be used in supplying exogenous neurotrophic factors is by administering *Platelet Rich Plasma* (PRP)¹⁴⁻¹⁶ High platelet concentrations in PRP contain many neurotrophic factors that play a major role in peripheral nerve regeneration after nerve injury.^{17,18}

2. Materials and methods

This study obtained ethical approval from the Institutional Research Ethics Commission with certificate number: 048/HRECC.FODM/II/2019. The research conducted was an experimental laboratory study with the research design is *Post Test Only Control Group Design*.

Fifty-four male Wistar rats aged 3 months, kept for a week to adapt in a cage that has been placed in a room with enough air and light to keep it moist, away from noise and not directly exposed to the sun. Wistar rats are fed with protein, carbohydrates, crude fiber, energy and water. Wistar rats are further divided into 3 groups namely; K1 group as negative control (without nerve injury and without FD-PRP injection) known as A group in day 14 and D group in day 21, K2 group as positive control group (nerve injury but without FD-PRP injection) known as B group in day 14 and E group in day 21 and PRP group as treatment group (nerve injury and in FD-PRP injection) known as C group in day 14 and F group in day 21, where each group is divided into groups that will be observed on the 14th day and 21st day.

Freeze-Dried Platelet Rich Plasma is made at the Bank Tissue of Dr. Soetomo General Hospital from the heart of 20 wistar rats were centrifuged twice. The first centrifugation is at 4000 rpm for 10 min, to separate red blood cells from plasma while the second centrifugation is done at 4000 rpm for 10 min to remove platelet-rich plasma (1/3 the bottom of the tube) and a little platelet (2/3 the top of the tube). The 1/3 section under the tube is a *Platelet Rich Plasma* (PRP). Platelet concentrates were dissolved in PBS, collected and incubated at room temperature (30 °C) and centrifuged to remove platelet clots, calibrated and frozen at -83 °C for subsequent use. The PRP was then frozen for 12 h in -83 °C freezer before being lyophilized for 8-12 h. Allogenic PRP is lyophilized using the freeze-drying procedure, which involves freezing the PRP and then drying it using the sublimation drying technique.³⁷

Axonotmesis nerve injury that can induce neuropathic pain is done in the positive control group and the treatment group through infraorbital nerve clamping techniques using arterial clamps that are held for 15 s. This technique is based on the results of preliminary experiments that modify the technique.¹⁹⁻²³ This form of axonotmesis nerve injury will allow the nerve tissue to heal effectively through the regeneration process without involving surgery.²⁴

On the first day after *crushing* the infraorbital nerve (24 h post traumatic) an injection of FD-PRP gel was carried out, by adding *Carboxymethyl cellulose* (CMC 1%) to the FD-PRP with a ratio of 1: 1 so that the injection preparation was obtained with a 50% FD-PRP concentration in a volume of 1 mL with needle 23 G. The injection preparations were injected into each treatment group on the 14th day and 21st day. The 14th day observation group and the 21st day group were each terminated based on the day of observation. The infraorbital nerve tissue is then processed until a preparation to be stained is obtained. The immunohistochemistry perform on paraffin-embedded tissue section. NGF and S100B expression were observed by immunohistochemical examination using anti-NGF antibodies (*SANTA CRUZ*)³ while S100B expression was observed by using anti-S100B antibodies (*SIGMA-ALDRICH*)[®]. NGF and S100B expressions were observed using a Nikon Eclipse E100light microscope which was[®] 400× magnification then calculated by modifying the method from Van de Schepop HAM. Research data were analyzed using ANOVA. ANOVA results that show the significant influence of FD-PRP on the expression of NGF and S100B, then further tests will be carried out further with the Fisher's Least Significant Difference (LSD).

3. Results

On immunohistochemical examination using anti-NGF monoclonal antibodies, a positive result is indicated by the brownish color on the result of painting. Furthermore, the brown area was observed using a Nikon Eclipse E100 light microscope with a magnification of 400×. In order to guarantee representation and reduce yield errors, observations are needed in a number of approximately 20 visual fields with a magnification of 1000×. The results of observations of NGF expression in the treatment can be seen in Fig. 1. The results show that the FD-PRP group as a treatment group that suffered a nerve injury and were given an injection of FD-PRP resulted in a greater increase in expression when compared to the K1 and K2 groups as a group that was not injected with FD-PRP.

From the analysis of the test statistical data *Kolmogorov-Smirnov*, the significance value of NGF expression was $p = 0.515$ ($p > 0.05$), so it can be concluded if the data of this study were normally distributed. Homogeneity test data was carried out with the *Levene test* in which the value of $p = 0.025$ ($p < 0.05$), which indicates if the variants of the groups are not the same or there are significant differences (very varied) In cases where the results of the *Levene test*, the results show significant probability means the variance is not the same (different), this is not fatal to ANOVA and the analysis can still be continued as long as the group has the same sample size (proportionally). In this study, the overall number of samples in each group is the same, namely 9 samples in each group. ANOVA test results obtained NGF expression p value = 0,000 ($p < 0.05$), so it is obtained if there is a significant influence of the administration of FD-PRP on NGF expression (Table 1). The treatment group that has a significant difference from the other treatment groups can be seen from *LSD post hoc test*. The PRP group or treatment group that was injected with FD-RP days 14 and 21 overall had an increase compared to the K1 and K2 groups both on the 14th day and 21st day. The K2 groups on the 14th and 21st days were the group with nerve injuries however PRP was not injected, it also appeared to have increased expression but was lower when compared to the PRP group on day 14 and day 21. The mean NGF expression in the 21st day PRP group was seen to decrease. However, this decrease was not significant $p = 0.919$.

On immunohistochemical examination using anti-S100B monoclonal antibodies, the expression of S100B was seen as a brownish color on the results of painting. The brown area was then observed using a Nikon Eclipse E100 light microscope at 400× magnification. In order to guarantee representation and reduce yield errors, observations are needed in a number of approximately 20 visual fields with a magnification of 1000×. The results of observations of S100B expression in the treatment can be seen in Fig. 2. The results showed that the PRP group as the treatment group that suffered sarfa injury and FD-PRP injections resulted in a greater increase in expression when compared to the K1 and K2 groups as the group not injected with FD-PRP.

The results of statistical analysis *Kolmogorov-Smirnov* on the S100B expression obtained significance value $p = 0.698$ ($p > 0.05$), so it was concluded if the data of this study were also normally distributed. Homogeneity test data was performed with the *Levene test* in which the value of obtained $p = 0.177$ ($p > 0.05$) was, which indicates if the variants of the groups are the same or there are no significant differences. ANOVA test results obtained S100B expression p value = 0,000 ($p < 0.05$), so it is obtained if there is a significant influence of the administration of FD-PRP on S100B expression (Table 2). The treatment group that has a significant difference from the other treatment groups can be seen from *LSD post hoc test*. The results showed that the PRP group had greater S100B expression when compared to the K1 group and the K2 group. In the PRP group as the treatment group that suffered nerve injury and injected FD-PRP seen a significant decrease in S100B expression on day 21 when compared with the PRP group on day 14, where $p = 0.005$.

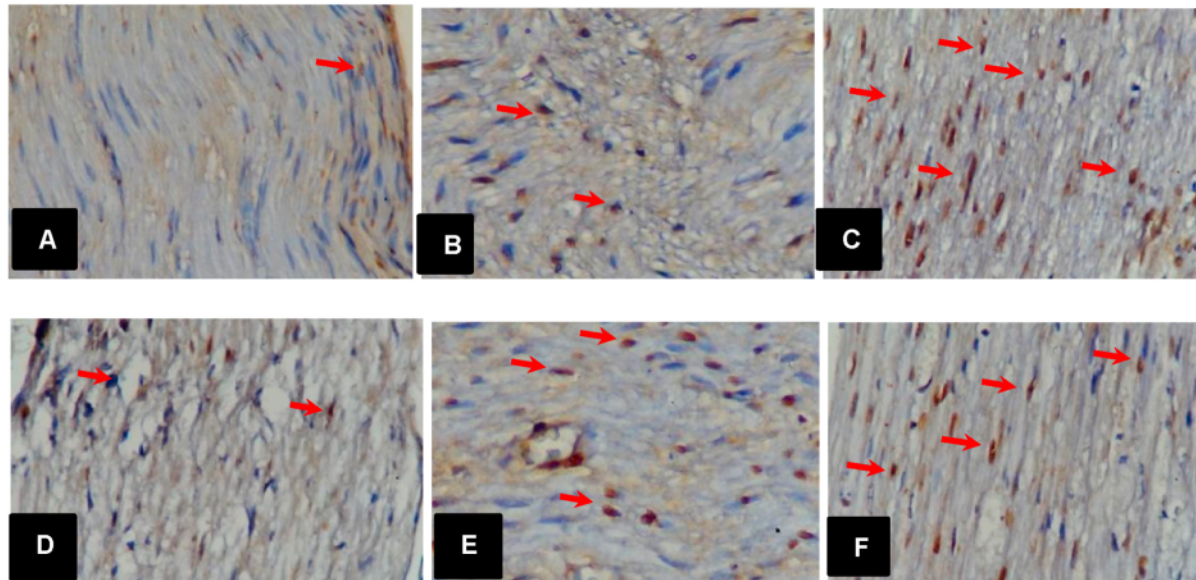


Fig. 1. Expression of NGF in infra orbital nerves by immunohistochemistry staining using anti-NGF antibodies and observations using a 400× magnification light microscope. The NGF expression is designated by the red arrow. (A) 14 days K1 group, (B) 14 days K2 group, (C) 14 days PRP group, (D) 21 days K1 group, (E) 21 days K2 group, and (F) 21 days PRP group.

Table 1
Statistical analysis data expression of NGF.

	Group	Mean ± SD	One-way ANOVA test	LSD test		
				A	B	C
Day 14	A	7,00 ± 0,816	0,000	-	0.007*	0.000*
	B	5,43 ± 0,976		-	-	0.000*
	C	10,71 ± 1,113		-	-	-
Day 21	D	5,71 ± 0,488	0,000	D	E	F
	E	7,57 ± 0,976		-	-	0.004*
	F	9,14 ± 1,069		-	-	-

* = there is a significant difference (p < 0.05).

4. Discussion

The infraorbital nerve of the wistar rat is a sensory nerve and is a branching of the trigeminal nerve.²⁵⁻²⁷ Research conducted by Moldovan M et al. in 2006, shows that there is no difference in growth capacity in the neuroregeneration process both in the sensory nerve and in the motor nerve.²⁸ The infraorbital nerves in the facial area are easy to access so that they will provide convenience when carrying out experimental procedures. Axonotmesis injury in experimental animals resulted from mechanical trauma in the form of infraorbital nerve clamping using *artery clamp* for 15 s.¹⁹⁻²³ This nerve damage will cause interference with nerve axons and myelin layers, but some or all mesenchymal structures such as perineurium are still intact.^{24,29,30} This form of axonotmesis nerve injury will allow injured nerve tissue to heal effectively through the regeneration process without involving surgery.²⁴

Clinical applications of PRP are generally autologous (from the same individual), but in this study the PRP used was an allogenic PRP, that is, a PRP taken from different wistar rats. From studies comparing the effectiveness between autologous PRP and allogenic PRP obtained if there is no potential difference between the two.³¹ Zhang ZY in 2013 promoted that if allogenic PRP in gel form would not increase the immune response, so allogenic PRP could be an alternative choice when

autologous PRP was not available or autologous PRP was inadequate.³² The administration of PRP was carried out by injection technique based on a study conducted by Ma in 2013, which found that if administering *growth factors* directly to an area injured by a nerve, it would protect nerve cells from death and would significantly increase the process of nerve regeneration.³³

The results indicate if the addition of exogenous neurotropic factors derived from FD-PRP will increase NGF expression. Schwann cells play an important role in the process of nerve regeneration where the schwann cells will make repairs themselves through the process of degeneration of axons and clearing myelin debris, promoting the regrowth of axons which will eventually regenerate axons through the process of remyelination.³⁴ In the degeneration process, Schwann cells will produce a variety of neurotropic factors, one of which is NGF released by Schwann cells and subsequently diffused diffusely in areas undergoing axon regeneration.³⁵ The process of nerve repair that takes place earlier and the supply of exogenous neurotropic factors and from schwann cells will be able to maintain an environment conducive to nerve regeneration and increase positive changes in nerve cells.¹³ The mean NGF expression in the 21st day treatment group (PRP group) was seen to decrease. But this decrease was not significant (p = 0.919). Ma et al. Stated that exogenous NGF *in vivo* would degrade rapidly. NGF is also known to be very sensitive to temperature, pH and other factors, so exogenous NGF activity in peripheral nerve regeneration is generally relatively short.³³ The rapid proliferation and viability of Schwann cells will support a faster regeneration process by providing bioactive substrates for axonal migration and the release of molecules that will regulate axon development.³⁶ K2 groups days 14 and 21 which were groups with nerve injuries but were not injected with PRP, also appeared to have increased expression but were lower when compared to the PRP groups on days 14 and 21 days. Immediately after the occurrence of nerve injury, schwann cells and macrophages will produce and secrete a number of neurotropic factors, but the improvement will not last long and is only temporary, especially in chronic nerve injuries.^{13,37,38} K1 groups in the 14th day and 21st day which were the normal group showed the lowest mean increase in NGF expression. NGF has a low concentration of healthy nerves, its expression will experience a

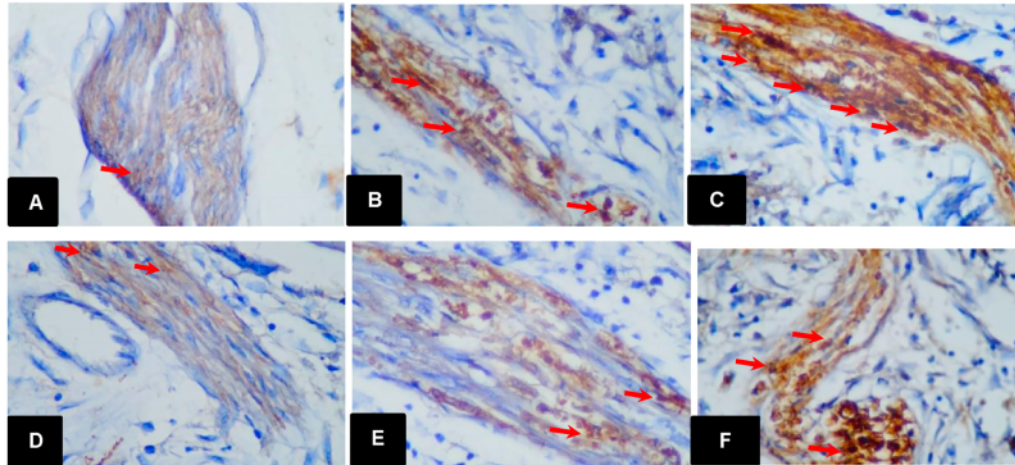


Fig. 2. S100B expression in infra orbital nerves by immunohistochemistry staining using anti-S100B antibodies and observation using a 400× magnification light microscope. The S100B expression is pointed out by a red arrow. (A) 14 days K1 group, (B) 14 days K2 group, (C) 14 days PRP group, (D) 21 days K1 group, (E) 21 days K2 group, and (F) 21 days PRP group.

Table 2
Statistical analysis data expression of S100 expression.

Day	Group	Mean ± SD	One-way ANOVA test	LSD test		
				A	B	C
14	A	7,00 ± 0,816	0,000	-	0,007*	0,000*
	B	5,43 ± 0,976		-	-	0,000*
	C	10,71 ± 1,113		-	-	-
21	D	5,71 ± 0,488	0,000	D	E	F
	E	7,57 ± 0,976		-	0,001*	0,000*
	F	9,14 ± 1,069		-	-	0,004*

* = there is a significant difference (p < 0.05).

significant increase after nerve injury.²³

From this study it was seen that the addition of exogenous neurotrophic factors in the area of nerve injury had increased S100B expression. In acute peripheral nerve injury, S100B will be released from Schwann cells in the area of nerve injury that will activate the Receptor for Advanced Glycation End (RAGE) on infiltration macrophages as well as on activated Schwann cells. Further infiltration macrophages will release beneficial effects through cleansing of debris cells, as well as dead neutrophils. Macrophages will also release cytokines and neurotrophic factors. Meanwhile, schwann cells that have been activated in the area of nerve injury also release cytokines and neurotrophic factors which are very important factors for repairing injured nerves.^{39,40,41} The effect of S100B is very dependent on its concentration. Neurotrophic factor is one of the factors that can regulate S100B expression in the form of increased expression.³⁹ K2 groups 14th and 21st days which are a group with nerve injuries that were not injected with PRP, appeared to have an increase in S100B expression that was higher than K1 14 and 21 days groups, but had lower S100B expression values when compared to PRP 14 and 21 days. S100B concentrations will be normal under physiological conditions but when a nerve injury occurs it will increase locally, which will release a number of tropic effects on the peripheral nervous system.⁴⁰

In the PRP group, it was seen that PRP 21st day experienced a significant decrease in S100B expression on PRP 14th day (p = 0.005). In inflammatory conditions, PRP has an anti-inflammatory effect.⁴² S100B is a neurotrophic protein found in Schwann cells, where when a nerve injury occurs, the Schwann cells will be activated and carry out an

immune reaction in the form of the production of S100B protein in large quantities. S100B is a very important protein in recruiting macrophages which in turn will produce pro-inflammatory cytokines.⁴³⁻⁴⁵ The inflammatory process is an absolute process for the occurrence of the degeneration process which is subsequently followed by the regeneration process. During the inflammatory process, a number of pro-inflammatory cytokines show increased expression in a variety of cells, including schwann cells.

One of the pro-inflammatory cytokines produced by Schwann cells is IL-1β.^{44,46} IL-1β is secreted by Schwann cells after stimulation by S100B.⁴⁴ Thioredoxin interacting protein (TXNIP) is a protein found in Schwann cells. TXNIP has an important role for the receptor for advanced glycation end (RAGE) along with its ligand (protein S100B) in inducing IL-1β expression and secretion. RAGE and S100B themselves are also secreted by Schwann cells. The study of Sbai Q et al. in 2010 reported that when a nerve injury occurs, an increase in transient TXNIP expression will subsequently experience decreased expression and downregulation on the 15th day after a nerve injury.⁴⁴ This condition will give effect to the production of pro-inflammatory cytokines especially IL-1β, so that the inflammatory process soon ends. This is in line with the results of this study, which can be seen if the addition of PRP initially showed an increase in expression on the 14th day and subsequently decreased S100B expression significantly on the 21st day, so that from this study it was seen that the addition of PRP was likely to further shorten the process acute inflammation which is part of the process of nerve tissue degeneration so that the process of nerve regeneration can begin immediately.

15
Declaration of competing interest

The authors declare no conflict of interest.

Acknowledgement

13
This research funding supported by Faculty of Dental Medicine Universitas Airlangga Surabaya.

References

1 Glick M. *Burket's Oral Medicine*. twelfth ed. Shelton: Connecticut : People's Medical Publishing House - USA; 2015:309-310.

2. Gilkey SJ, Plaza-Villegas F. Evaluation and management of orofacial pain. *Am. Acad. Phy. Assist.* 2017;3. May 5.
3. Ghurye S, McMillan R. Orofacial pain - an update on diagnosis and management. *Br Dent J.* 2017;27:2017. October.
4. Shetty A, Leena J, Nagaraj T, Abraham M. Epidemiology of orofacial pain : a retrospective study. *J. Adv. Clinic. Res. Insight.* 2015;2(1). Jan-Feb 2015.
5. Skelebar D, Skelebar I, Cesarik M, barada A, Maletic A. Neuropathic orofacial pain – diagnostic and therapeutic challenges, 2015 *Period Biol.* 2015;117(2):231–237, 2015.
6. Brooks KG, Kessler T. Treatments for neuropathic pain. *The Pharmaceutical J. Clinic Pharm.* 2017, 1 Dec 2017.
7. Jaggi AS, Jain V, Singh N. Animal models of neuropathic pain. *Fund Clin Pharmacol.* 2009;25:1–2 (2011).
8. Nascimento OJM, Pessoa BL, Orsini M, et al. Neuropathic pain treatment: still a challenge. *Neurol Int.* 2016;8:6322. <https://doi.org/10.4081/ni.2016.6322>.
9. Purwata TE, Widyadharma PE, Wijayanti IAS. *Management of Neuropathic Pain in Elderly Focus on Pregabalin.* 4th Bali Neurology Update; 2016.
10. Aloe L, Rocco ML, Bianchi P, Manni L. Nerve growth factor : from the early discoveries to the potential clinical use. *J Transl Med.* 2012;10:239.
11. Kuffler DP. Promoting axon regeneration & neurological recovery following traumatic peripheral nerve injuries. *Int J Neurorehabil.* 2014;2:148. <https://doi.org/10.4172/2376-0281.1000148>.
12. Wood RL, Karlinsey KS, Thompson AD, et al. Baseline effects of lysophosphatidylcholine and nerve growth factor in a rat model of sciatic nerve regeneration after crush injury. *Neural Regen Res.* 2018;13:846–853.
13. Liu Y, Wang H. Peripheral nerve injury induced changes in the spinal cord and strategies to counteract/enhance the changes to promote nerve regeneration. *Neural Regen Res.* 2020;15:189–198, 2020.
14. Zheng C, Zhu Q, Liu X, et al. Effect of platelet-rich plasma (PRP) concentration on proliferation, neurotrophic function and migration of Schwann cells in vitro. *J tiss eng regener med.* 2016;10(5):428–436. <https://doi.org/10.1002/term.1756>.
15. Kucuk L, Gunay H, Erbas O, Kucuk U, Atamaz F, Coskunol E. Effects of platelet-rich plasma on nerve regeneration in a rat model. *Acta Orthop Cederatol Turc.* 2014;48(4): 449–454, 2014.
16. Kuffler DP. Promoting axon regeneration & neurological recovery following traumatic peripheral nerve injuries. *Int J Neurorehabil.* 2014;2:148. <https://doi.org/10.4172/2376-0281.1000148>.
17. Yu W, Wang J, Yin J. Platelet – rich plasma : a promising product for treatment of peripheral nerve regeneration after nerve injury. *Int J Neurosci.* 2011;121:176–180.
18. Lichtenfels M, Colomé L, Sebben AD, Braga-Silva J. *Effect of Platelet Rich Plasma and Platelet Rich Fibrin on Sciatic Nerve Regeneration in a Rat Model.* VC. Wiley Periodicals, Inc . *Microsurgery*; 2013. <https://doi.org/10.1002/micr>.
19. Bauder AR, Ferguson TA. Reproducible mouse sciatic nerve crush and subsequent assessment of regeneration by whole mount muscle analysis. *JoVE.* 2012;(60):3606, 2012.
20. Altun I, Kurutas EB. Vitamin B complex and vitamin B 12 levels after peripheral nerve injury. *Neural Regenerat Res.* 2016;11:5. May 2016.
21. Zou Y, Xu F, Tang Z, et al. Distinct calcitonin gene-related peptide expression pattern in primary afferents contribute to different neuropathic symptoms following chronic constriction or crush injuries to the rat sciatic nerve. *Mol Pain.* 2016, 2016; 1744806916681 566.
22. Ramli NA, Wong TW. Sodium carboxymethylcellulose scaffolds and their physicochemical effects on partial thickness wound healing. *Int J Pharm.* 2011;403: 73–82.
23. Alvites R, Caseiro AR, Pedrosa SS, et al. Peripheral nerve injury and axonotmesis: state of the art and recent advances. *Neurology.* 2018. <https://doi.org/10.1080/2331205X.2018.1466404>. Review Article.
24. Seddighi A, Nikouei A, Seddighi AS, et al. *Peripheral Nerve Injury: A Review Article*; 2016. www.journals.sbu.ac.ir/neuroscience.
25. Pozza DH, Castro-Lopes JM, Neto FL, Avelino A. Spared nerve injury model to study orofacial pain. *Indian J Med Res.* 2016;143:297–302, 2016.
26. Hossain MZ, Unno S, Ando H, Masuda Y, Kitagawa J. Neuro–glia crosstalk and neuropathic pain: involvement in the modulation of motor activity in the orofacial region. *Int J Mol Sci.* Oct. 2017;18(10):2051. <https://doi.org/10.3390/ijms18102051>.
27. Stemkowski PL, Smith PA. An overview of animal models for neuropathic pain. *Comput Bus: Kkaviitha Stage.* 2017;4:33.
28. Moldovan M, Sørensen J, Krarup C. Comparison of the fastest regenerating motor and sensory myelinated axons in the same peripheral nerve. In: *Published by Oxford University Press on behalf of the Guarantors of Brain.* 129. 2006:2471–2483.
29. Mahadewa TGB. *Saraf Perifer Masalah Dan Penanganannya.* Jakarta : PT Indeks. Jakarta Barat: Permata Puri Media; 2013:27–29.
30. Menorca RMG, Fussell TS, Elfar JC. Peripheral nerve trauma: mechanisms of injury and recovery. *Hand Clin.* 2013;29(3):317–330.
31. Creeper F, Ivanovski S. *Effect of Autologous and Allogenic Platelet-Rich Plasma on Human Gingival Fibroblast Function.* 2012. <https://doi.org/10.1111/j.1601-0825.2011.01897.x>.
32. Zhang N, Wu YP, Qian SJ, Teng C, Chen S, Li H. Research progress in the mechanism of effect of PRP in bone deficiency healing. *Sci World J : Apr.* 2013;4, 134582, 2013.
33. Ma S, Peng C, Wu S, Wu D, Gao C. Sciatic nerve regeneration using a nerve growth factor-containing fibrin glue membrane. *Neural Regen Res.* 2013;8(36):3416–3422. Dec 25.
34. Kima S, Maynardb JC, Stricklanda A, Burlingameb AL, Milbrandta J. Schwann cell O-GlcNAcylation promotes peripheral nerve remyelination via attenuation of the AP-1 transcription factor JUN. *Proc Natl Acad Sci USA.* 2018;115(31):8019–8024. July.
35. Yu W, Wang J, Yin J. Platelet – rich plasma : a promising product for treatment of peripheral nerve regeneration after nerve injury. *Int J Neurosci.* 2011;121:176–180.
36. Zheng C, Zhu Q, Liu X, et al. Effect of platelet-rich plasma (PRP) concentration on proliferation, neurotrophic function and migration of Schwann cells in vitro. *J. Tiss. Eng. Regenerat. Med.* 2013;10(5):428–436.
37. Ferguson TA, Son YJ. Extrinsic and intrinsic determinants of nerve regeneration. *J Tissue Eng.* 2011;2(1), 2041731411418392.
38. Namgung U. The role of schwann cell-axon interaction in peripheral nerve regeneration. *Cells Tissues Organs.* 2015;6–12.
39. Donato R, Sorci G, Riuzzi F, et al. S100B's double life : intracellular regulator and extracellular signal. *Biochim Biophys Acta.* 2009;1793:1008–1022 (2009).
40. Sorci G, Riuzzi F, Arcuri C, et al. S100B protein in tissue development, repair and regeneration. *World J Biol Chem*; 2013. <https://www.ncbi.nlm.nih.gov/pmc/articles/PMC3622753/#>.
41. Fujiwara S, Hoshikawa S, Ueno T, et al. SOX10 transactivates S100B to suppress schwann cell proliferation and to promote myelination. *PLoS One.* 2014. <https://doi.org/10.1371/journal.pone.0115400>.
42. Akeda K, Yamada J, Linn ET, Sudo A, Masuda K. Platelet-rich plasma in the management of chronic low back pain: a critical review. *J Pain Res.* 2019;12: 753–767.
43. Hu A, Yordan T, Kati C, et al. The role of S100B protein, neuron-specific enolase, and glial fibrillary acidic protein in the evaluation of hypoxic brain injury in acute carbon monoxide poisoning. *Hum Exp Toxicol.* 2014;33(11):1113–1120.
44. Sbai O, Devi TS, Melone MA, et al. RAGE-TXNIP axis is required for S100B-promoted Schwann cell migration, fibronectin expression and cytokine secretion. *J Cell Sci.* 2010;15(Pt 24):4332–4339, 123.
45. Dubovy P. Wallerian degeneration and peripheral nerve conditions for both axonal regeneration and neuropathic pain induction. *Ann Anat.* 2011;193:267–275. <https://doi.org/10.1016/j.aanat.2011.02.011> (2011).
46. Yokoyama S. Inflammatory cytokines in degeneration, regeneration and maintenance of sciatic nerve. *The Sciatic Nerve: Blocks, Injuries and Regeneration.* 2017.

Nerve growth factor and S100B: Molecular marker of neuroregeneration after injection of freeze-Dried platelet rich plasma

ORIGINALITY REPORT

16%

SIMILARITY INDEX

12%

INTERNET SOURCES

11%

PUBLICATIONS

0%

STUDENT PAPERS

PRIMARY SOURCES

1	acikerisim.afsu.edu.tr Internet Source	2%
2	cdj.cumhuriyet.edu.tr Internet Source	1%
3	"Clinical/disease sites: Other tumour sites", Radiotherapy and Oncology, 201009 Publication	1%
4	Jenny Sunariani, Christian Khoswanto, Wahyuning Ratih Irmalia. "Difference of brain- derived neurotrophic factor expression and pyramid cell count during mastication of food with varying hardness", Journal of Applied Oral Science, 2019 Publication	1%
5	Sorci, Guglielmo. "S100B protein in tissue development, repair and regeneration", World Journal of Biological Chemistry, 2013. Publication	1%

6	Internet Source	1 %
7	Mario P. Mensana, Alexander P. Nugraha, Diah S. Ernawati. "Oral manifestations in pediatric HIV infection in developing countries based on published research between 2009-2019", HIV & AIDS Review, 2020 Publication	1 %
8	cegh.net Internet Source	1 %
9	www.pharmaceutical-journal.com Internet Source	1 %
10	heanoti.com Internet Source	<1 %
11	Nirawati Pribadi, Retno Pudji Rahayu, Kun Ismiyatin, Cindy Ramadhan Putri, Meircurius Dwi Condro Surboyo. "The Effect of Lipoteichoic Acid from Lactobacillus plantarum on Dental Pulp Inflammation", European Journal of Dentistry, 2021 Publication	<1 %
12	ijses.com Internet Source	<1 %
13	www.thieme-connect.com Internet Source	<1 %

14

Internet Source

<1 %

15

publicatio.bibl.u-szeged.hu

Internet Source

<1 %

16

Iswinarno Doso Saputro, Sitti Rizaliyana, Dhitta Aliefia Noverta. "The effect of allogenic freeze-dried platelet-rich plasma in increasing the number of fibroblasts and neovascularization in wound healing", *Annals of Medicine and Surgery*, 2022

Publication

<1 %

17

repository.unsoed.ac.id

Internet Source

<1 %

18

docplayer.net

Internet Source

<1 %

19

Alaa M. El driny, Ahmed A. Salama, Osama S. El-Shal, Maha M. Mohamed. "The effect of twice and four activations per day of periodontal distractor on pain intensity and pulp vitality of maxillary canine", *Research Square Platform LLC*, 2022

Publication

<1 %

20

Jinghui Huang, Xueyu Hu, Lei Lu, Zhengxu Ye, Quanyu Zhang, Zhuojing Luo. "Electrical regulation of Schwann cells using conductive polypyrrole/chitosan polymers", *Journal of Biomedical Materials Research Part A*, 2009

<1 %

21

journals.plos.org

Internet Source

<1 %

22

medpharmareports.com

Internet Source

<1 %

23

Björn Bluhm, Björn Laffer, Daniela Hirnet, Matthias Rothermundt, Oliver Ambree, Christian Lohr. "Normal Cerebellar Development in S100B-Deficient Mice", *The Cerebellum*, 2014

Publication

<1 %

24

Rantaro Kamimura, Mohammad Z. Hossain, Shumpei Unno, Hiroshi Ando et al. "Inhibition of 2-arachydonoylglycerol degradation attenuates orofacial neuropathic pain in trigeminal nerve-injured mice", *Journal of Oral Science*, 2018

Publication

<1 %

25

cwww.intechopen.com

Internet Source

<1 %

26

mdpi-res.com

Internet Source

<1 %

27

neuroviisas.med.uni-rostock.de

Internet Source

<1 %

28

worldwidescience.org

Internet Source

<1 %

29

www.imrpress.com

Internet Source

<1 %

30

www.mdpi.com

Internet Source

<1 %

31

Letícia Rodrigues, Márcio Ferreira Dutra, Jocemar Ilha, Regina Biasibetti et al.

"Treadmill training restores spatial cognitive deficits and neurochemical alterations in the hippocampus of rats submitted to an intracerebroventricular administration of streptozotocin", *Journal of Neural Transmission*, 2010

Publication

<1 %

32

Qin, Jie, Lin Wang, Yue Sun, Xiaolin Sun, Chaoju Wen, Mahdi Shahmoradi, and Yanmin Zhou. "Concentrated growth factor increases Schwann cell proliferation and neurotrophic factor secretion and promotes functional nerve recovery in vivo", *International Journal of Molecular Medicine*, 2015.

Publication

<1 %

33

pt.scribd.com

Internet Source

<1 %

34

pure.rug.nl

Internet Source

<1 %

35

www.hindawi.com

Internet Source

<1 %

36

www.nature.com

Internet Source

<1 %

37

www.ncbi.nlm.nih.gov

Internet Source

<1 %

38

"Advanced Acupuncture Research: From Bench to Bedside", Springer Science and Business Media LLC, 2022

Publication

<1 %

39

"Bio-orthopaedics", Springer Science and Business Media LLC, 2017

Publication

<1 %

40

Lei Zhang, Wen Yang, Hongjian Xie, Hui Wang, Jian Wang, Qiangfei Su, Xiaolin Li, Yu Song, Guobin Wang, Lin Wang, Zheng Wang. "Sericin Nerve Guidance Conduit Delivering Therapeutically Repurposed Clobetasol for Functional and Structural Regeneration of Transected Peripheral Nerves", ACS Biomaterials Science & Engineering, 2019

Publication

<1 %

41

Ucy Nur Hamida Al Abrori, Nurina Febriyanti Ayuningtyas, Diah Savitri Ernawati, Hening Tuti Hendarti et al. "Oral Candidiasis in Immunosuppressed Wistar Rats (*Rattus norvegicus*) Post Dexamethasone Injection at

<1 %

7.2 mg/kg and 16 mg/kg Doses", Brazilian Dental Science, 2020

Publication

Exclude quotes Off

Exclude matches Off

Exclude bibliography On

Nerve growth factor and S100B: Molecular marker of neuroregeneration after injection of freeze-Dried platelet rich plasma

GRADEMARK REPORT

FINAL GRADE

/0

GENERAL COMMENTS

Instructor

PAGE 1

PAGE 2

PAGE 3

PAGE 4

PAGE 5
