



Source details

International Journal of Surgery Case Reports

Scopus coverage years: from 2010 to Present

Publisher: Elsevier

ISSN: 2210-2612

Subject area: Medicine: Surgery

Source type: Journal

[View all documents >](#)

[Set document alert](#)

[Save to source list](#) [Source Homepage](#)

CiteScore 2021

0.9



SJR 2021

0.198



SNIP 2021

0.691



[CiteScore](#) [CiteScore rank & trend](#) [Scopus content coverage](#)

i Improved CiteScore methodology ✕

CiteScore 2021 counts the citations received in 2018-2021 to articles, reviews, conference papers, book chapters and data papers published in 2018-2021, and divides this by the number of publications published in 2018-2021. [Learn more >](#)

CiteScore 2021 ▼

$$0.9 = \frac{3,130 \text{ Citations 2018 - 2021}}{3,573 \text{ Documents 2018 - 2021}}$$

Calculated on 05 May, 2022

CiteScoreTracker 2022 ⓘ

$$0.8 = \frac{2,812 \text{ Citations to date}}{3,699 \text{ Documents to date}}$$

Last updated on 05 August, 2022 • Updated monthly

CiteScore rank 2021 ⓘ

Category	Rank	Percentile
Medicine		
Surgery	#316/469	32nd

[View CiteScore methodology >](#) [CiteScore FAQ >](#) [Add CiteScore to your site](#)

About Scopus

[What is Scopus](#)
[Content coverage](#)
[Scopus blog](#)
[Scopus API](#)
[Privacy matters](#)

Language

[日本語版を表示する](#)
[查看简体中文版本](#)
[查看繁體中文版本](#)
[Просмотр версии на русском языке](#)

Customer Service

[Help](#)
[Tutorials](#)
[Contact us](#)


ELSEVIER

[Terms and conditions](#) ↗ [Privacy policy](#) ↗

Copyright © [Elsevier B.V](#) ↗. All rights reserved. Scopus® is a registered trademark of Elsevier B.V.


We use cookies to help provide and enhance our service and tailor content. By continuing, you agree to the [use of cookies](#) ↗.



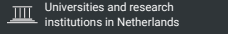
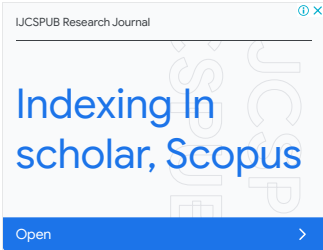



Indexing In scholar, Scopus

[Open](#)

 IJCS PUB Research Journal


International Journal of Surgery Case Reports

COUNTRY	SUBJECT AREA AND CATEGORY	PUBLISHER	H-INDEX
<p>Netherlands</p> <p></p>	<p>Medicine</p> <p>└ Surgery</p> <div data-bbox="555 768 879 1016">  </div>	Elsevier BV	23
PUBLICATION TYPE	ISSN	COVERAGE	INFORMATION
Journals	22102612	2010-2021	<p>Homepage</p> <p>How to publish in this journal</p>



SCOPE

International Journal of Surgery Case Reports is an open access, broad scope journal covering all surgical specialities. It is dedicated to publishing case reports and case series. Articles must be authentic, ethical, educational and clinically interesting to an international audience of surgeons, trainees and researchers in all surgical subspecialties, as well as clinicians in related fields. All case reports and case series submitted need to comply with the relevant reporting criteria. The journal is published monthly and focuses on rapid submission to decision times. [...] The journal covers the following areas of surgery: -Cardiothoracic surgery- General surgery- Neurosurgery- Oral and maxillofacial surgery- Otolaryngology (ENT)- Paediatric surgery- Plastic surgery- Trauma and orthopaedic surgery- Urology- Vascular surgery

 Join the conversation about this journal

Indexing In scholar, Scopus

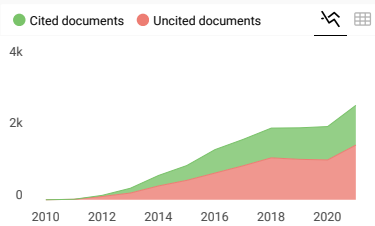
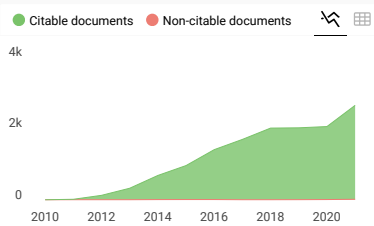
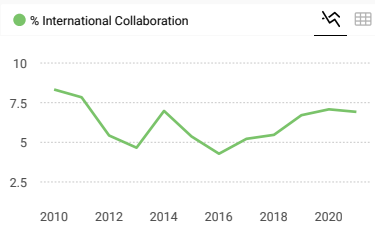
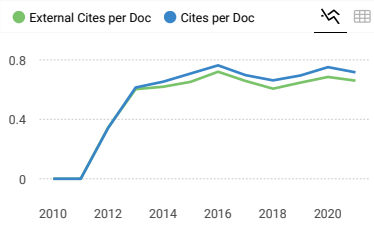
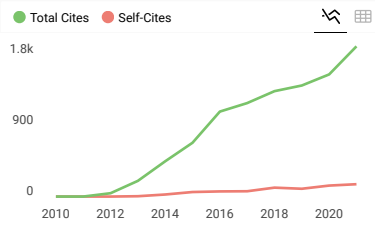
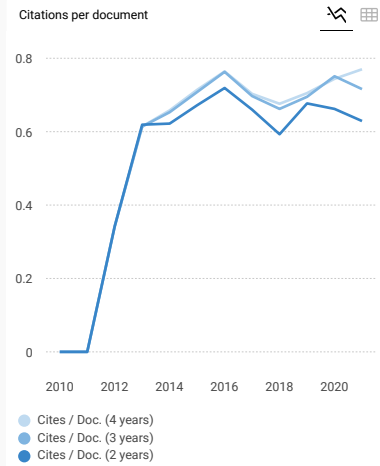
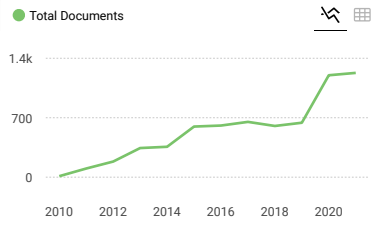
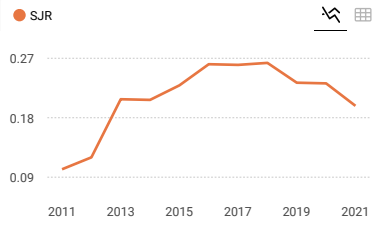
IJCSPUB Research Journal

Open

Quartiles

FIND SIMILAR JOURNALS

<p>1 Annals of Medicine and Surgery NLD</p> <p style="font-size: 24px; color: green; font-weight: bold;">67%</p> <p>similarity</p>	<p>2 International Journal of Surgery NLD</p> <p style="font-size: 24px; color: green; font-weight: bold;">55%</p> <p>similarity</p>	<p>3 International Journal of Surgery Open GBR</p> <p style="font-size: 24px; color: green; font-weight: bold;">50%</p> <p>similarity</p>	<p>4 BMC Surgery GBR</p> <p style="font-size: 24px; color: green; font-weight: bold;">34%</p> <p>similarity</p>	<p>5 Indian Journal of Surgery IND</p> <p style="font-size: 24px; color: green; font-weight: bold;">33%</p> <p>similarity</p>
---	---	--	--	--



International Journal of Surgery Case Reports

Q3 Surgery

SJR 2021

Show this widget in your own website

Just copy the code below and paste within your html code:

SCImago Graphica

Explore, visually communicate and make sense of data with our new data visualization

U.Z
powered by scimagojr.com

tool.

Metrics based on Scopus® data as of April 2022

**Dharmendra** 2 years ago

Want to publish a case report i this journal, si please tell me about the process.
Thanks

reply

**Melanie Ortiz** 2 years ago

SCImago Team

Dear Dharmendra, thank you very much for your comment, we suggest you look for author's instructions/submission guidelines in the journal's website. Best Regards, SCImago Team

**Jayalakshmi** 2 years ago

I would like to know the charge for publishing the report

reply

**Melanie Ortiz** 2 years ago

SCImago Team

Dear Jayalakshmi,
thank you for contacting us.
We are sorry to tell you that SCImago Journal & Country Rank is not a journal. SJR is a portal with scientometric indicators of journals indexed in Elsevier/Scopus.
Unfortunately, we cannot help you with your request, we suggest you visit the journal's homepage (See fees/charges, if there are any) or contact the journal's editorial staff , so they could inform you more deeply.
Best Regards, SCImago Team

Leave a comment

Name

Email

(will not be published)

The users of Scimago Journal & Country Rank have the possibility to dialogue through comments linked to a specific journal. The purpose is to have a forum in which general doubts about the processes of publication in the



ISSN 2210-2612

INTERNATIONAL JOURNAL OF SURGERY CASE REPORTS

Advancing surgery through shared experience



ERUDITIO • DILIGENTIA • FIDES

EST. 2003

Volume 97

August 2022

Download full issue

Previous vol/issue

Next vol/issue

Receive an update when the latest issues in this journal are published

Sign in to set up alerts

Open access

Editorial Board

Article 107501

Download PDF

Correspondence

Correspondence Open access

An intrauterine balloon for puerperal uterine inversion is not only for hemostasis but also for prophylaxis against reinversion: A letter to the editor

Shigeki Matsubara

Article 107397

Download PDF

Case Reports

Case report Open access

FEEDBACK

Case report  Open access

Infected urachal cyst in an adult, report of two observations

P.M. Faye, M.L. Gueye, O. Thiam, A. Niasse, ... M. Cisse

Article 107394

[Download PDF](#)  Article preview Case report  Open access

Synchronous breast cancer and non-Hodgkin lymphoma: A case report

Salman Ardi Syamsu, Rino Setiady, Nilam Smaradania, Prihantono, ... Muhammad Faruk

Article 107398

[Download PDF](#)  Article preview Case report  Open access

A rare case report of tricornora penile fracture associated with urethral disruption

Gede Wirya Kusuma Duarsa, Muhlis Yusuf, Yudhistira Pradnyan Kloping, Ilham Akbar Rahman, Soetojo

Article 107351

[Download PDF](#)  Article preview Case report  Open access

A complete second branchial fistula in a four years old child

Bashayer Salem Alsaedi, Ahmad Rasheed Alrasheedi, Imtiyaz Nawaz Bhat

Article 107365

[Download PDF](#)  Article preview Case report  Open access

Successful use of stereotactic navigation in posterior spinal fusion T10-S2 with bilateral iliac screw fixation in a patient with prior spinal surgeries and osteoporosis: A case report

Nolan J. Brown, Shane Shahrestani, Joshua S. Kurtz, Ryan S. Beyer, ... Joseph Osorio

Article 107380

[Download PDF](#)  Article preview Case report  Open access

Massive retroperitoneal cyst impersonating ovarian tumor: A case report

Hidar Alibrahim, Amany Al Ali, Haidara Bohsas, Safaa Mohamed Alsharief Ahmed, ... Sarya Swed

Article 107393

[Download PDF](#)  Article preview 

Case report ● Open access

Mesenteric cyst manifested as obesity, gastroesophageal reflux, urinary incontinence, and abdominal mass during pregnancy—Case report and literature review

Francisco Aguilar-Espinosa, Rodolfo Salcedo-Vargas, Hiram Alfonso Galván-Bizarro, Carlos Rubén Rodríguez-Ramos, Erika Diana Barba-Jaramillo

Article 107366

[Download PDF](#) Article preview 

Case report ● Open access

Treatment of bone defects with bovine hydroxyapatite xenograft and platelet rich fibrin (PRF) to accelerate bone healing

Ahmad Taufik S, Adnanto Wiweco, Didit Yudhanto, Mohammad Rizki, ... Rohadi Muhammad Rosyidi

Article 107370

[Download PDF](#) Article preview 

Case report ● Open access

A rare case of appendiceal tip complete attachment to a sigmoid diverticulum: An appendiceal phlegmon case report

Farzad Vaghef Davari, Arezou Hashem Zadeh

Article 107379

[Download PDF](#) Article preview 

Case report ● Open access

Laparoscopic total gastrectomy performed for juvenile polyposis of the stomach: A case report

Misato Ito, Hisashi Onozawa, Masaru Saito, Hirofumi Ami, ... Kono Koji

Article 107368

[Download PDF](#) Article preview 

Case report ● Open access

Multispecialty surgical management of large clavicular tumor: A case report

Mohammad Aladaileh, Tom Moran, Austin Duffy, Karen Redmond, David O'Briain

Article 107375

[Download PDF](#) Article preview 

Case report ● Open access

Recurrent lumbar intraspinal epidermoid cyst presenting as lower back pain, a case report

Fajr M.A. Sarhan, Ahmed Mahmoud Daqour, Zahra Hosam Abu-Harb, Asaad Al-Darawish, Fidaa Zakaria Ganaim

Article 107420

FEEDBACK 

Huda Fajar Arianto, Muhammad Bayu Zuhari Hutagaung, Tulus Abdul Bari
Article 107410

 [Download PDF](#) [Article preview](#) 

Case report  Open access

Deep anterior lamellar limbo-keratoplasty for bilateral limbal stem cell deficiency with corneal scarring in chemical injury sequelae: Two case reports

Neha Jain, Anahita Kate, Sayan Basu

Article 107409

 [Download PDF](#) [Article preview](#) 

Case report  Open access

Long-term results of sclerotherapy for cervical-thoracic-mediastinal lymphatic and venous malformations: A case report

Quan-Feng LUO

Article 107411

 [Download PDF](#) [Article preview](#) 

Case report  Open access

Bilateral ovarian mucinous carcinoma (stage III) with omental involvement and incidental hydronephrosis: A rare case report

Diptee Poudel, Kshitiz Acharya, Navin Poudel, Ashmita Adhikari, ... Suvana Maskey

Article 107415

 [Download PDF](#) [Article preview](#) 

Case report  Open access

Gangrenous Meckel's diverticulum with small bowel obstruction mimicking complicated appendicitis: 'Case report'

Gosa Bejiga, Zubeyri Ahmed

Article 107419

 [Download PDF](#) [Article preview](#) 

Case report  Open access

Diagnostic approach and management of bilateral pneumothorax due to silicosis in Indonesian male: A rare case

Risa Natalia Siburian, Kristin Purnama Dewi, Winariani Koesoemoprodjo

Article 107407

 [Download PDF](#) [Article preview](#) 

Case report  Open access

Case report  Open access

The evaluation of the effect of performing guided lid surgery with enucleation of a cystic lesion; a case report

Aly Khaled Hussein Abdelazez, Hossam El-Dien Hany, Mohamed Ehab Gamal El Din, Mahmoud Medhat Mostafa El Mereg, ...

Mohammed Daa Zein El Abdien

Article 107385

 [Download PDF](#) Article preview Case report Open access

Laparoscopic jejunostomy for enteral nutrition in gastric cancer patients: A report of two cases: A case report

Hiroshi Tsuchiya, Itaru Yasufuku, Naoki Okumura, Nobuhisa Matsuhashi, Takao Takahashi

Article 107388

 [Download PDF](#) Article preview Case report Open access

A Very rare case report of male invasive micropapillary breast carcinoma in China and review of literature

Qin Ou, Ying-dong Li, Jun Chen, Lin-lin Yuan, Wenfang Li

Article 107408

 [Download PDF](#) Article preview Case report Open access

Thyroid angiosarcoma: A case report and review of literature

L. Benbella, I. Elouarith, H.E.L. Ouazzani, Z. Bernoussi, ... F. Zouaidia

Article 107358

 [Download PDF](#) Article preview Case report Open access

Intraparenchymal fiberoptic intracranial pressure monitoring and decompressive craniectomy in meningioma case with critical intracranial pressure: A case report during COVID-19 pandemic

Tedy Apriawan, Rizki Meizikri, Endra Wibisono Harmawan, Heru Kustono

Article 107364

 [Download PDF](#) Article preview Case report Open access

Duodenal perforation due to migrated biliary stent: Case report

Prarthana Pachhai, Rabi Khadka, Narendra Maharjan, Deepak Sharma, ... Ramesh Singh Bhandari

Article 107354

 [Download PDF](#) Article preview 

Case report ● Open access

Long-term survival after sequential local treatments for oligometastatic esophageal squamous cell carcinoma: A case report

Tiuri E. Kroese, Peter S.N. van Rossum, Sylvia van der Horst, Stella Mook, ... Richard van Hilleberg
Article 107423[Download PDF](#) Article preview 

Case report ● Open access

Botryoid rhabdomyosarcoma of the uterine cervix: Report case

R.E.L. Qasseh, F. Bouyalik, S. Majidi, M. Moutahir, ... M. El Keroumi
Article 107389[Download PDF](#) Article preview 

Case report ● Open access

Perirenal cystic lymphangioma mimicking a renal cyst in an elderly patient: Case report

A. Lahfidi, W.M. Traore, K. Imrani, C. Ayadi, ... N. Moatassim Billah
Article 107403[Download PDF](#) Article preview 

Case report ● Open access

Idiopathic lymphatic mesenteric cyst of the proximal jejunum: A case report of an unusual clinical presentation

Michele Ghielmetti, Kerstin J. Neuschütz, Anna Hirschmann, Katharina Marston, ... Marco von Strauss und Torney
Article 107402[Download PDF](#) Article preview 

Case report ● Open access

Combined transcranial and transnasal endoscopic approach in transnasal-penetrating intracranial injury: A rare case report

Djoko Widodo, Fajar Perkasa, Rais Al-'Abqary, Kevin Jonathan Sjukur, Muhammad Faruk
Article 107422[Download PDF](#) Article preview 

Case report ● Open access

Localized retroperitoneal Rosai-Dorfman-Destombes disease as a cause of fever of unknown origin in adults. Case report and review of the literature

Georgi Popivanov, Magdalena Baymakova, Pavel Bochev, Dimitar Penchev, ... Ventsislav Mutafchiyski
Article 107414

Aavishkar Raj Kergiri, Sarmanendra Mishra, Adarsh Gurung, Archana Acharya, ... Ajinshi Ghimire

Article 107434

[Download PDF](#) Article preview Case report  Open access

Conjunctival myxoma masquerading as conjunctival lymphoma: A case report

Majed Alkharashi, Hind M. Alkatan, Ahmed A. Alhumidi, Wael Otaif

Article 107441

[Download PDF](#) Article preview Case report  Open access

One anastomosis gastric bypass with fundoplication of remnant stomach for weight regain prevention: Case report

O. Ospanov, K. Nadirov, V. Koikov, N. Zharov

Article 107431

[Download PDF](#) Article preview Case report  Open access

Ectopic thyroid carcinoma in the mandible with normally located goiterous thyroid gland: A case report

Mohamed Osama Mohamed Ali, Noon Idris Abdelrahman Mohamed, Ahmed Abdelfattah Eltomelhussein Ahmed, Najdelddin Adam Ibrahim Adam, ... Abdalla Abdelmutaleb Bakhit Elkhedir

Article 107433

[Download PDF](#) Article preview Case report  Open accessTriple-valve replacement for *Rhizobium radiobacter* endocarditis with septic shock in an adult with ventricular septal defect. A case report

Andrei George Iosifescu, Ioana Marinică, Alexandru Popescu, Alina Teodora Timișescu, ... Vlad Anton Iliescu

Article 107401

[Download PDF](#) Article preview Case report  Open access

Case report of an angiosarcoma of the abdominal wall during liraglutide injections: A coincidence?

Eric Bergeron, Meriame Dami, Xuan Vien Do, Chantal Vallee, Jonathan Noujaim

Article 107444

[Download PDF](#) Article preview Case report  Open access

Case report ● Open access

Giant omental lipoma, a rare etiology of right-iliac fossa pain in adult: A surgical case report

Athary Saleem, Jumana Alfadhli, Abrar Alawadhi, Maher Hassan, Khaled Alshammari

Article 107428

[Download PDF](#) Article preview 

Case report ● Open access

Traumatic fracture of the polyethylene tibial post and cone in a posterior-stabilized total knee arthroplasty: A case report

Abdulaziz Alkherajji, Sultana Borai, Rheema Alfadhil, Fawzi Aljassir

Article 107437

[Download PDF](#) Article preview 

Case report ● Open access

Dumbbell-shaped meningioma of Meckel's cave mimicking trigeminal schwannoma: A case report

Chun-Pi Chang, Cheng-Siu Chang, Meng-Yin Yang, Chiung-Chyi Shen

Article 107369

[Download PDF](#) Article preview 

Case report ● Open access

A rare case of obstructed labor due to sever uterine prolapse; a case report and literature review

Elham Askary, Shaghayegh Moradi Alamdarloo, Zinat Karimi, Anushe Karimzade

Article 107344

[Download PDF](#) Article preview 

Case report ● Open access

Von Hippel-Lindau disease: A case report

Durga Neupane, Alok Dahal, Nimesh Lageju, Lokesh Shekher Jaiswal, ... Srista Manandhar

Article 107417

[Download PDF](#) Article preview 

Case report ● Open access

Jejunal diverticulitis: A new case report and a review of the literature

Elmontassar Belleh Zafouri, Imen Ben Ismail, Marwen Sghaier, Saber Rebi, Ayoub Zoghlami

Article 107395

[Download PDF](#) Article preview 

Case report  Open accessOdontogenic brain abscess due to *Anaerococcus prevotii* infections: A case report and review article

Suharyadi Sasmanto, Eddy Bagus Wasito

Article 107450

 [Download PDF](#) Article preview Case report  Open access

Ectopic ACTH syndrome complicated by hypercortisolism-associated urolithiasis. A case report

Emilio de León-Castorena, Dulce María López-Sotomayor, Luis Edwin Gaona-Garza, Mario Alberto Treviño-Aguillón, Alejandro Talamas-Mendoza

Article 107449

 [Download PDF](#) Article preview Case report  Open accessInfectious hematogenous lumbar spondylodiscitis caused by *Actinotignum schaalii* in a 74-year-old man: A case report

Ekkehard F. Röpke, Martin Chwoika, Tim Treber, Jens Meyer, Christoph Paasch

Article 107453

 [Download PDF](#) Article preview Case report  Open access

Case report: A rare case of pure tibio-talar dislocation without malleolar clamp fracture in a young athlete: Long-term functional results and recent reviews of the literature

Walid Bouziane, Mouncef Amahtil, Mohammed Benhamou, Jawad Amghar, ... Abdelkrim Daoudi

Article 107396

 [Download PDF](#) Article preview Case report  Open access

Extraction of sphenochoanal polyp with functional endoscopic sinus surgery approach: A rare case and review article

Bunga Aline Ditha, Budi Sutikno

Article 107429

 [Download PDF](#) Article preview Case report  Open access

Acute appendicitis secondary to metastatic breast cancer. 12 Years after first primary tumor diagnosis. A case report

Victoria G. Hughes, Pedro Osácar, Darío Ramallo

Article 107452

 [Download PDF](#) Article preview 

Case report ● *Open access*

Leiomyosarcoma of the small bowel: A case report and literature review

Mahdi Bouassida, Hazem Beji, Mohamed Fadhel Chtourou, Saloua Nechi, ... Hassen Touinsi

Article 107456

 [Download PDF](#) Article preview 

Case report ● *Open access*

Cervical vasovagal shock: A rare complication of incomplete abortion case report

Willbroad Kyejo, Brenda Moshi, Vicky Kapesi, Gregory Ntiyakunze, ... Munawar Kaguta

Article 107455

 [Download PDF](#) Article preview 

Case report ● *Open access*

Minor lobulation of the testis, mimicking polyorchidism when inflamed, discussion of a rare case: A case report

Mohammad Hadi Gharib, Reza Zahedpasha

Article 107448

 [Download PDF](#) Article preview 

Case report ● *Open access*

Perforated ileum as the initial presentation of Crohn's disease, a case report

Robel Tadesse, Biniyam Ewnte, Kale'ab Tesfaye

Article 107305

 [Download PDF](#) Article preview 

Case report ● *Open access*

Human papillomavirus-related carcinoma with adenoid cystic-like features of the sinonasal tract: Case report and literature review

Zephania Saitabau Abraham, Caroline Philip Ngimba, Atuganile Edward Malango, Alita Mrema, ... Edda Vuhahula

Article 107462

 [Download PDF](#) Article preview 

Case report ● *Open access*

Case Report-Right atrial myxoma with total anomalous pulmonary venous connection in neonate

Shantanu Gomase, Sachin Kuthe, Manish Sonkusale

Arisa Kurita, Masayuki Yoshida, Takeshi Murata, Akihiko Yoshida, ... Shin Takayama
Article 107435

 [Download PDF](#) Article preview 

Case report  *Open access*

Granulomatosis with polyangiitis presenting with intestinal obstruction: A case report

Reem Alawna, Tala Jalamneh, Maram Massad, Noor Alawna, ... Fadi Abu Alrub
Article 107446

 [Download PDF](#) Article preview 

Case report  *Open access*

Mesenteric textiloma early discovery in a 31-year-old female: A case report

Jeannot Baanitse Munihire, Moise Muhindo Valimugighe, Nyundo W. Martin
Article 107439

 [Download PDF](#) Article preview 

Case report  *Open access*

Unconstrained one-stage total knee arthroplasty PS design in patient with secondary osteoarthritis due to granulomatous infection with medial femoral condyle defect: A case report

Nur Rahmansyah, Dicky Mulyadi, Raden Moechammad Satrio Nugroho Magetsari, Aditya Fuad Robby Triangga
Article 107469

 [Download PDF](#) Article preview 

Case report  *Open access*

Gallbladder volvulus with gangrenous cholecystitis – A case report

Clarisse S. Muenyi, Nia N. Zalamea, Priya Dhindsa, Mark P. Miller, Denis A. Foretia
Article 107468

 [Download PDF](#) Article preview 

Case report  *Open access*

Giant retroperitoneal liposarcoma: A case report

Yusuf Rachman, Yosua Hardja
Article 107465

 [Download PDF](#) Article preview 

Case report  *Open access*

Case report  Open access

Giant fibrovascular polyps of the esophagus. Trans oral versus surgical approach. Case report and systematic literature review

Valentina Ferri, Emilio Vicente, Yolanda Quijano, Hipolito Duran, ... Riccardo Caruso
Article 107412

 [Download PDF](#) Article preview 

Case report  Open access

Acute pancreatitis secondary to spontaneous intramural duodenal hematoma: A case report and a review of the literature

Wissal Skhiri, Marwa Moussaoui, Jamal Saad, Mohamed Maatouk, ... Ines Mazhoud
Article 107424

 [Download PDF](#) Article preview 

Case report  Open access

Unusual ascites post laparoscopic cholecystectomy in old patient: Case report and review of the literature

Othman Alfryyan, Sharifah A. Othman, Norah Alabdulwahab, Nasser Amer, ... Shadi Alshammary
Article 107426

 [Download PDF](#) Article preview 

Case report  Open access

Esophageal extraskeletal neoplasm Ewing's sarcoma: Case report

Hina Khalid, Niaz Hussain, Rafay Shamshad
Article 107399

 [Download PDF](#) Article preview 

Case report  Open access

A rare incidence of primary Synovial Spindle Cell Sarcoma in a 46-year-old male, successfully managed by surgical intervention-A Case Report

Omar Hariri, Omar Al Laham, Zein Ibrahim Basha, Hisham Hamzeh
Article 107442

 [Download PDF](#) Article preview 

Case report  Open access

Bilateral tubal ectopic gestation: Complication in a patient with previous ectopic pregnancy, rare case report

Willbroad Kyejo, Davis Rubagumya, Zainab Fidaali, Ahmed Jusabani, ... Shweta Jaiswal
Article 107470

 [Download PDF](#) Article preview 

Case report ● *Open access*

Multiple inflammatory polyps resulted from Meckel's diverticulitis presenting with chronic abdominal pain: A case report

Ruo-Lan Wang, Zheng-Yi Song, Lin-Hai Li, Lin-Na Yu

Article 107392

 [Download PDF](#) Article preview 

Case report ● *Open access*

Generalized peritonitis secondary to spontaneous rupture of the urinary bladder in a diabetic patient: A case report

Foolad Eghbali, Hesam Mosavari, Ahmad Madankan, Vahid Hariri, ... Mansour Bhaqdoust

Article 107458

 [Download PDF](#) Article preview 

Case report ● *Open access*

Ileocolic intussusception caused by giant submucosal colonic lipoma: A rare case report

Nahyeon Park, Jung Cheol Kuk, Eung Jin Shin, Su Sie Chin, Dae Ro Lim

Article 107451

 [Download PDF](#) Article preview 

Case report ● *Open access*

An extensive squamous cell carcinoma of the auricle: From curative to reconstructive treatment. A case report

Sara Halily, Karmouch Mohamed Amine, Youssef Oukessou, Sami Rouadi, ... Mohammed Mahtar

Article 107413

 [Download PDF](#) Article preview 

Case report ● *Open access*

Robot-assisted laparoscopic hysterectomy for early-stage endometrial cancer with massive uterine leiomyomas: A case report

Akiyo Kakibuchi, Fumitake Ito, Tetsuya Kokabu, Hiroyuki Okimura, ... Taisuke Mori

Article 107473

 [Download PDF](#) Article preview 

Case report ● *Open access*

Case report  Open access

Acute kidney injury leading to the diagnosis of sporadic testicular Burkitt's lymphoma: A case report

Sanda Mrabet, Yosr Chaabouni, Mohamed Ben Hmida

Article 107471

 [Download PDF](#) Article preview Case report  Open access

Langerhans cell histiocytosis of the rib in an adult: A case report and review of the literature

Shengliang Zhao, Chao Luo, Bo Tang, Liang Chen, ... Hua Li

Article 107432

 [Download PDF](#) Article preview Case report  Open access

A case of primary mediastinal seminoma with superior vena cava syndrome and large intracardiac thrombus

Vicky Reinold Christofel Rampengan, Arief Bakhtiar

Article 107478

 [Download PDF](#) Article preview Case report  Open access

The role of shoulder arthroplasty after chronic brucellosis of glenohumeral joint septic arthritis. A case report and literature reviews

Banca Chernchujit, Surasak Srimongkolpitak, Jutatip Kintarak, Yodsawee Pornmeechai

Article 107467

 [Download PDF](#) Article preview Case report  Open access

Bowel obstruction secondary to gallstone ileus within a strangulated inguinal hernia: Report of a rare diagnosis

Mojtaba Ahmadinejad, Mohammad Hadi Bahri, Armin Tajik, Nooshin Taherzadeh-ghahfarokhi, Javad Zebarjadi Bagherpour

Article 107445

 [Download PDF](#) Article preview Case report  Open access

Hidden appendix: A case report and literature review of perforated acute appendicitis masquerading as acute cholecystitis

E Ashwini, M Varun, PS Saravanan, Sunil Julian, P Sandeep

Article 107480

Kohji Furusawa, Masanori Toshimitsu, Hiroyoshi Matsukawa, Kuniomi Oji, ... Akimasa Tamura

Article 107463

[Download PDF](#) Article preview Case report  Open access

Wide-awake local anesthesia for open rotator cuff repair: A case report

Farsad Biglari, Amir Sabaghzadeh, Adel Ebrahimpour, Mehrdad Sadighi, ... Meisam Jafari Kafiabadi

Article 107494

[Download PDF](#) Article preview 

Case Series

Mini review  Open access

Reconstruction of intraarticular distal radius malunion with 3D printed guide and arthroscopic assisted intraarticular osteotomy

Oryza Satria, Irsan Abubakar, Syahdi Farqani, Irfan Kurnia Pratama

Article 107391

[Download PDF](#) Article preview Mini review  Open access

Osteoclast-like stromal giant cells in invasive ductal breast cancer: A case series

Giustina Angellotti, Giovanni Tomasicchio, Alda Elena Montanaro, Michele Telgrafo, ... Clelia Punzo

Article 107421

[Download PDF](#) Article preview Mini review  Open access

Case series of diagnosis and surgery challenges in parathyroid carcinoma

Diani Kartini, Ahmad Kurnia, Erwin Danil Yulian, Sonar Soni Panigoro, ... Jessica Wardana

Article 107390

[Download PDF](#) Article preview Mini review  Open access

Laparoscopic subtotal reconstituting cholecystectomy in type II & III Mirizzi syndrome: Case series of 5 patients

Gerardo Chávez Saavedra, Dante Ríos Segovia, Raúl Hernandez Centeno, Nicolas Joaquín Fernández Pérez

Article 107425

[Download PDF](#) Article preview 

Mini review ● Open access

Lessons learned from five patients of persistent Mullerian duct syndrome: A case series

Shehryar Ahmed Khan Niazi, Muhammad Umer Mukhtar, Rameez Hassan, Qasim Mehmood
Article 107459

[Download PDF](#) Article preview ▾

Mini review ● Open access

Diagnosis and Management of oro-antral fistula: Case series and review

Asma Azzouzi, Lamiae Hallab, Saliha Chbicheb
Article 107436

[Download PDF](#) Article preview ▾

Mini review ● Open access

Case series of high-grade soft tissue sarcoma of the lower limb with delayed diagnosis: Experience at a tertiary hospital in northern Tanzania

Jay Lodhia, Gregory Goodluck, Joylene Tendai, Ellyagape Urassa, ... Alex Mremi
Article 107475

[Download PDF](#) Article preview ▾

Mini review ● Open access

Radiofrequency ablation for benign thyroid nodule treatment: New solution in our center

Monica Bellynda, Muhammad Rizki Kamil, Kristanto Yuli Yarso
Article 107418

[Download PDF](#) Article preview ▾



Copyright © 2022 Elsevier B.V. or its licensors or contributors.
ScienceDirect® is a registered trademark of Elsevier B.V.



ISSN: 2210-2612

Copyright © 2022 IJS Publishing Group Ltd. Published by Elsevier Ltd. All rights reserved



ELSEVIER



International Journal of Surgery Case Reports

Editor-in-Chief

Professor David Rosin, Barbados, West Indies

Managing and Executive Editor

Dr Riaz Agha, London, UK

Assistant Managing Editor

Maliha Agha, London, UK

Senior Editors

Professor Hasan Alam, Michigan, USA
Professor Raafat Afifi, Cairo, Egypt
Dr Juan Barret, Barcelona, Spain
Mr Ben Challacombe, London, UK
Dr Xiaoping Chen, Wuhan, China

Dr Burcin Ekser, Indianapolis, USA
Professor Joseph W Y Lau, Shatin, Hong Kong
Dr Oliver Muensterer, New York, USA
Dr Selwyn Rogers, Galveston, Texas
Professor Jamsheer Talati, Karachi, Pakistan

Dr Mangesh Thorat, London, UK
Professor Fu Chan Wei, Tapei, Taiwan
Professor Rudy Leon De Wilde, Oldenburg, Germany

Associate Editors

Professor Roberto Coppola, Rome, Italy
Dr Veerappan Kasivisvanathan, London, UK
Dr Richard Keijzer, Winnipeg, Canada, USA
Dr Boris Kirshtein, Beer Sheva, Israel

Professor James McCaul, London, UK
Miss Emma McGlone, London, UK
Dr Dattatraya Muzumdar, Mumbai, India
Professor Andy Petroianu, Minas Gerais, Brazil

Mr Shahzad Raja, London, UK
Dr Kandiah Raveedran, Ipoh, Malaysia
Dr Daniel Yeh, Boston, USA

Assistant Editors

Dr Rafid Al-Mahfoudh, Oxford, UK
Dr Hussein Atta, Boston, USA
Dr Mohammad Bashashati, Texas, USA
Professor Somprakus Basu, Varanasi, India
Mr Andrew Beamish, Cardiff, UK
Dr Anthony Charles, North Carolina, USA
Dr Amitava Das, Hyderabad, India
Dr Brian Davis, Texas, USA
Dr Susana Adriana Esquivel, Córdoba, Mexico
Professor Sheng Feng, Shanghai, China

Dr Juan Gomez Rivas, Madrid, Spain
Dr Satoshi Ieiri, Kagoshima City, Japan
Dr Haytham Kaafarani, Massachusetts, USA
Dr Yogeesh Kamat, Karnataka, India
Mr Omar Khan, London, UK
Prof. Tsuyoshi Konishi, Osaka, Japan
Dr Vito A Mannacio, Naples, Italy
Dr Todd Manning, Oxford, UK
Dr Zubing Mei, Shanghai, China
Dr Umesh Metkar, Beth, Israel

Dr Indraneil Mukherjee, Staten Island, USA
Dr Enyi Ofo, Adelaide, South Australia
Dr Lena Perger, Albuquerque, USA
Professor Prathamesh S Pai, Mumbai, India
Dr Alfredas Smailys, Kaunas, Lithuania
Prof. Peter Hyunsuk Suh, Seoul, South Korea
Dr Dieter Weber, Perth, Australia
Dr John Wee, Boston, USA
Dr Honggyi Zhu, Shanghai, China

Statistical Editors

Dr Derek Cooper, London, UK
Professor Nora Donaldson, London, UK
Professor Mary W Gray, Washington DC, USA

Society Representative

Deniz Balci, Representative of the International Society of Liver Surgeons
Rhiannon Harries, President, Association of Surgeons in Training
Gene F. Coppa, President of the New York Surgical Society
Xiao-ping Chen, President of the Chinese Chapter of International Hepato-Pancreato-Biliary Association

Social Media Editor

Dr Riaz Agha, London, UK

Assistant Commissioning Editors

Ahmed Al-Jabir, London, UK
Zaid Alsafi, London, UK
Thomas Franchi, Sheffield, UK
Christos Iosifides, London, UK

Ahmed Kerwan, London, UK
Mehdi Khan, London, UK
Ginimol Matthew, London, UK
Maria Nicola, London, UK

Niamh O'Neill, London, UK
Catrin Sohrabi, London, UK

Executive Committee

Professor David Albala, New York, USA
Sir Graeme Catto, London, UK
Professor David Cooper, Pittsburgh, USA
Lord Ara Darzi, London, UK
Professor Harold Ellis, London, UK
Ather Enam, Karachi, Pakistan

Sir Barry Jackson, London, UK
Professor Arthur Li Kwok-Cheung, Wanchai, Hong Kong
Professor C H Leong, Central, Hong Kong
Lord Ian McColl, London, UK

John Norcini, Philadelphia, USA
Professor Susan Standing, London, UK
Lord Robert Winston, London, UK
Sir Magdi Yacoub, London, UK

Editorial Board

Raj Badwe
Mumbai, India
Michael Boscoe
Middlesex, UK
Rapheal Bueno
Boston, USA
Kris Chatamra
Bangkok, Thailand
Paul Coulthard
Manchester, UK
Anil d'Cruz
Mumbai, India
Mahesh Desai
Mumbai, India
Juan Gomez Rivas
Spain, Madrid

David W. Green
London, UK
Iraj Harirchi
Tehran, Iran
Doris Henne-Bruns
Ulm, Germany
Delawir Kahn
Cape Town, South Africa
Xiaoxi Lin
Shanghai, China
Ashok Mahapatra
New Delhi, India
Todd Manning
Melbourne, Australia
Indraneel Mittra
Mumbai, India

Vijay Naraynsingh
West Indies
Fabio Nicoli
London, UK
Anibal R. Núñez De Pierro
Buenos Aires, Argentina
Reuben Orda
Tel Aviv, Israel
Vladimir Semiglazov
St. Petersburg, Russia
Tejinder Singh
Ludhiana, India
Barbara L. Smith
Boston, USA
James Tatum
California, USA

Thehnton Udwardia
Mumbai, India
Martin R. Weiser
New York, USA
Yixin Zhang
Shanghai, China
Jun Zhong
Shanghai, China
Zhao-Fan Xia
Shanghai, China

Elsevier

Executive Publisher

Ash Allan, Oxford, UK

Administrative Editor

Josie Hutchins, Oxford, UK

Marketing Manager

Jayne Dawkins, Philadelphia, USA

Journal Manager

Tamsyn Hopkins, Exeter, UK

Senior Business Development Executive (Reprints)

Emma Steel, London, UK

Advertising Sales Manager

Robert Bayliss, London, UK

Account Manager (Supplements)

Evelina Euren, Amsterdam, the Netherlands

Project Manager Supplements & E-business

Mónica Hernández-Sesma, Amsterdam, the Netherlands



Case report

A rare case report of tricorpora penile fracture associated with urethral disruption

Gede Wirya Kusuma Duarsa^a, Muhlis Yusuf^{b,*}, Yudhistira Pradnyan Kloping^b, Ilham Akbar Rahman^b, Soetojo^b^a Department of Urology, Faculty of Medicine, Universitas Udayana, Sanglah General Hospital, Bali, Indonesia^b Department of Urology, Faculty of Medicine, Universitas Airlangga, Dr. Soetomo General-Academic Hospital, Surabaya, East Java, Indonesia

ARTICLE INFO

Keywords:

Penile fracture
 Urethral disruption
 Tricorpora rupture
 End-to-end anastomosis urethroplasty
 Penile degloving
 Sexual health

ABSTRACT

Penile fracture is defined as a tear of tunica albuginea that covers the corpus cavernosum during an erection. It is a rare finding that both the corpora cavernosum and corpora spongiosum are involved in penile fracture. Herewith, we reported a rare case of 44 years old presented with penile fracture during woman on top sex position with both corpora cavernosum and corpus spongiosum rupture with urethral disruption. On clinical examination, the penis was swollen, and there was a sudden loss of erection and ecchymosis. Cystoscopy examination revealed urethral rupture. Emergent surgical repair was then performed. During emergency surgery, we found a defect of 3 cm in bicorporal cavernosa with urethral and corpus spongiosum disruption. The penis was degloved, and debridement with water-tight suturing of tunica albuginea was performed to repair the tear in corpora cavernosa. End-to-end anastomosis urethroplasty with spatulation was also performed to repair the urethra. After 21 days following surgery, erectile function was good and no difficulties in voiding function as shown in uroflowmetry result with Qmax >15 mL/s. The patient had a favorable recovery. This was a rare case report, and with early and prompt surgical intervention, this case could result in a good outcome in preserving erectile function and voiding function.

1. Introduction and importance

Penile fracture is the condition of surgical emergency that occurs due to trauma to the erect penis [1]. Most of the patients did not seek medical treatment due to embarrassment; therefore, most of cases were in delayed treatment [2]. Penile trauma occurs as a result of tears in tunica albuginea, corpora cavernosa, or corpus spongiosum [3]. Sexual intercourse was the most common cause of trauma in the erect penis. When the penis slips out of the vagina during vigorous sexual intercourse, the penis may hit the symphysis pubis or perineum, resulting in penile fracture [1]. Clinical manifestations most commonly were a cracking or popping sound followed by immediate detumescence. The penis could also show signs of rapid swelling, extensive ecchymosis, severe pain, and marked deformity [4]. History taking, physical examination and imaging are the modalities that can be used in the diagnosis of this condition. Early detection and early surgical treatment are essential for optimal outcome [5]. The tears in corpora cavernosa are

most commonly unilateral. Therefore, it was a rare finding if both corpora cavernosa were involved in a penile fracture, found in only around 5–14 % of cases [6]. Furthermore, the incidence of urethral rupture has been reported at approximately 10–20 % in all penile fracture cases [7]. Combined with these two, the incidence of both bilateral corpora cavernosa rupture, and corpus spongiosum rupture associated with urethral disruption was only 9–20 % from all penile fracture cases [8]. This work has been reported in line with the SCARE and PROCESS criteria [9,10]. We report one of the rare cases of penile fracture involving the tricorpora which are both corpora cavernosa, and corpus spongiosum with urethral disruption.

2. Case presentation

A 44 years old male presented to an emergency department with a swollen penis since 3 h ago. The penis was swollen after the patient had vigorous sexual intercourse with his wife so-called “woman on top” sex

* Corresponding author at: Department of Urology, Faculty of Medicine, Universitas Airlangga, Dr. Soetomo General-Academic Hospital, Surabaya, East Java, Indonesia.

E-mail address: dr.muhlis Yusuf@gmail.com (M. Yusuf).

<https://doi.org/10.1016/j.ijscr.2022.107351>

Received 24 April 2022; Received in revised form 22 June 2022; Accepted 22 June 2022

Available online 25 June 2022

2210-2612/© 2022 The Authors. Published by Elsevier Ltd on behalf of IJS Publishing Group Ltd. This is an open access article under the CC BY license (<http://creativecommons.org/licenses/by/4.0/>).

position. There was a crack sound followed by swelling afterward. He suddenly felt severe pain, followed by immediate loss of erection. Blood was discharged from the tip of his penis. There was no previous history of diabetes mellitus, hypertension, or previous history of surgery. He denied any sexual disorder and history of PDE-5 inhibitor use. On physical examination, his penis was swollen showing the signs of ecchymosis (Fig. 1). Urethral bleeding was visualized. He had voiding difficulties which highly suggested urethral injury. Laboratory finding was normal.

The patient was immediately scheduled for an operative procedure. Suspected urethral disruption with its localization was evaluated prior to surgical repair using cystoscopy, and eventually revealed urethral rupture (Fig. 2A). An incision was performed in the coronal sulcus to deglove the penis. The rupture of tunica albuginea was found extending into corpora cavernosa (Fig. 2B). End-to-end anastomosis was performed in the urethra using vicryl 4-0 with interrupted sutures. Debridement with water-tight suturing of the tunica albuginea was performed to repair the tear in corpora cavernosa. Erection test was then performed with the result showing that there was no leakage. Penile reconstruction was performed with skin suturing to the glans penis. After the procedure, the penis was covered with a bandage. The intraoperative finding was presented in Fig. 2.

An uneventful post-operative period following surgery was found. After 21 days of the follow-up period, uroflowmetry and urethrography examination revealed a normal result. Erectile function was normal with a normal erection hardness score of 4. No deformity in penile curvature was seen, and no difficulty in voiding function was revealed, as shown in the uroflowmetry result with Qmax >15 mL/s. The patient did not complain of any pain during sexual intercourse. Fig. 3 shows the post-operative follow-up 21 days after surgery.

3. Clinical discussion

This is a rare case of penile fracture involving the tricorpora which are both corpora cavernosa, and corpus spongiosum with urethral disruption. This case report demonstrated appropriate management with a rare presentation of penile fracture involving the tricorpora. The penis is consisted of erectile tissue, which was arranged in columnar order. There were two dorsolateral corpora cavernosa and one ventral corpora spongiosum, each was coated by the tunica albuginea. The urethra runs through along the corpora spongiosum and forms the glans penis at its tip. The ventral corpora spongiosum was coated by Buck's fascia [3,4]. Trauma to the flaccid penis does not result in any damage because the location is protected. The tunica albuginea possesses a thickness of 2 mm. However if the penis is in the erect state, the penis is filled with blood, and the thickness of tunica albuginea reduces to 0.25–0.5 mm. This leads to susceptibility to traumatic injury [3]. Several

activities were reported to cause the penile fracture, including vigorous sexual intercourse, a blow to the penis, and dangerous manipulation to achieve tumescence [3]. Various sexual positions often cause injury to the penis. The most common vigorous sexual position was doggy style. A previous study reported that doggy style accounted for double fractures in 67 patients (10 %). Another study also reported that penile fracture usually occurs if the woman is in a superior position. It is due to the entire body weight lands on the erect penis or when the erect penis hits the woman's perineum [1].

The diagnosis of penile fracture was based on history taking and physical examination, in which 90 % of the symptoms were sudden cracking or snapping sound, immediate pain, and a significant subcutaneous hematoma [11]. Blood discharge from the meatus and voiding difficulty should raise awareness of urethral injury. In relation to our case, the patient experienced a snapping sound during vigorous sexual intercourse [12]. They performed "woman on top" sexual position during their sexual intercourse. Vigorous sexual intercourse was one of the main causes of penile fracture. High energy trauma during this sexual position injured the corpora cavernosa and caused urethral disruption. A previous study reported that urethral rupture only accounts for 3 % of penile trauma [13]. Most commonly tear of the tunica albuginea was unilateral. However, bilateral ruptures can occur in 5–14 % of cases [6]. In relation to our case, our patient had both corpora cavernosa injuries with urethral disruption. The possible explanation of urethral disruption with both corporal tears was the extensions of a ventral tear along the midline to involve the corpus spongiosum.

Retrograde urethrography (RUG) should be considered in this case because it is inexpensive, easy to perform, and highly accurate [14]. However, urethrography is of low yield if the patient has no hematuria, blood at the meatus, and no voiding symptoms. The diagnosis of a penile fracture can be through only the clinical presentation. However, in several unclear/atypical cases, ultrasound (US) and MRI can be used to detect disruption of tunica albuginea [15]. The use of cavernosography could also be useful in acute fracture of the penis in the hope to evaluate the extent of injury in corpus cavernosum depending in certain circumstances which the exact nature of the damage is not clear clinically [16]. However, in our case, the clinical picture was apparent. The condition was emergent suggesting urethral rupture as shown with the presence of urinary retention. Therefore, we performed an endoscopic cystoscopy procedure to directly evaluate the urethra. Cystoscopy performed at the time of exploration is the most sensitive means to assess for urethral injury. It is in accordance with the report from Ciamack Kamdar, et al. in 2008, which suggested that cystoscopy in the operating room is recommended instead of a retrograde urethrogram if a urethral injury is suspected [17]. Consequently, intraoperative cystoscopy is an appropriate method of urethral evaluation for this patient.

Compared to conservative treatment, surgical treatment has

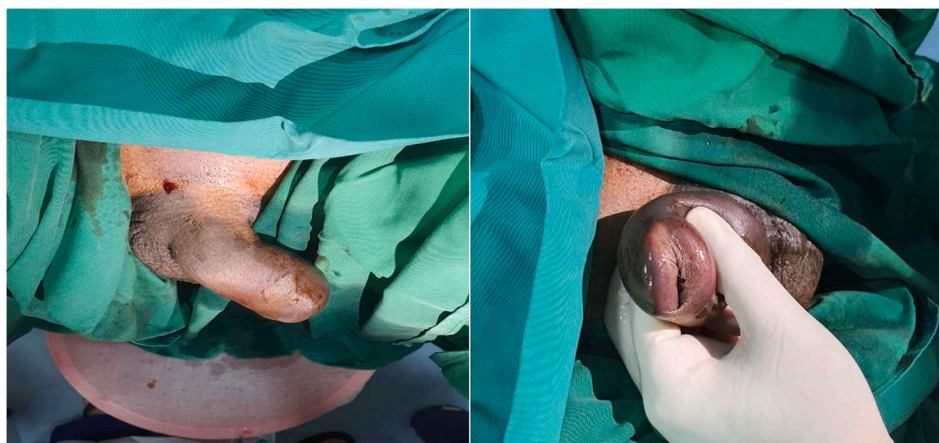

Fig. 1. Clinical signs of penile fracture.

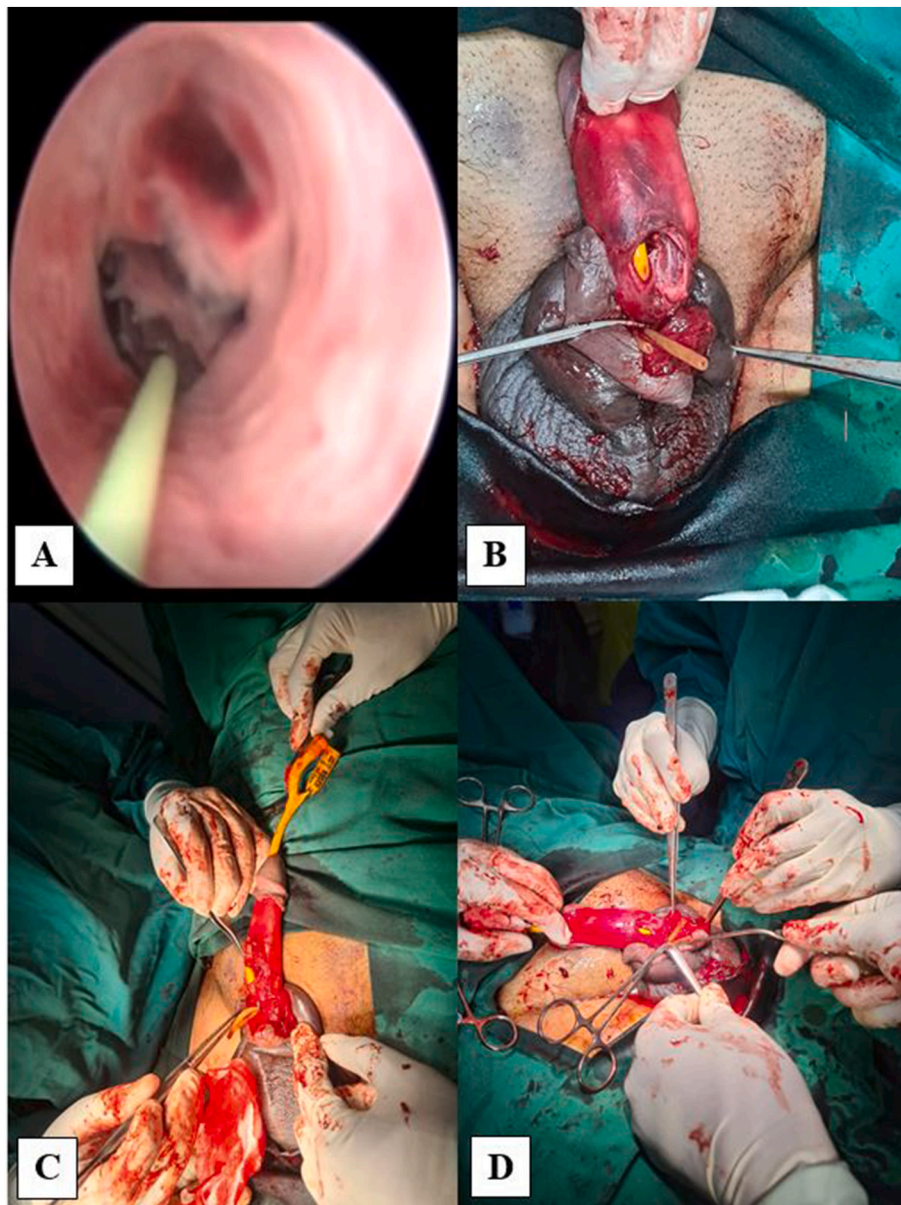


Fig. 2. Intraoperative finding. (A) Cystoscopy examination showing urethral disruption, (B) defect of 3 cm in bicorpora cavernosa and spongiosa, (C–D) urethral and corpus repair.

produced better outcome and shorter hospital stays with less complication rate. Surgical intervention with the closure of the tunica albuginea can ensure the lowest rate of negative long-term sequelae and has a favorable effect on the psychological wellbeing of the patient. A previous study reported the comparison of surgical and conservative management with 50 % and 4 %, respectively [14]. Related to our case, debridement with the closure of the tunica albuginea using water-tight suturing was performed to repair the tear in corpora cavernosa. A circumferential incision was performed in the coronal sulcus, which enables complete degloving of the penis.

The importance of penile degloving, in this case, was for a comprehensive search to check any missed injuries [18]. This technique was also described previously in which circumferential incision proximal to the coronal sulcus establishes complete degloving of the penis [19]. Urgent surgical intervention, in this case, was undertaken to repair the corporal tears and urethral injury. This was approved by the previous study, which suggested that surgical treatment for penile fracture and urethral injury should be taken as soon as possible to produce fewer

complications and optimize outcomes [6,20].

4. Conclusion

Penile fracture is one of the emergency conditions in urology. Bilateral rupture of corpora cavernosa with urethral disruption is an uncommon case. The diagnosis of penile fracture was based on clinical presentation. The classic symptoms were snapping or cracking sounds, followed by immediate detumescence and severe pain. Prompt surgical treatment involving penile degloving and surgical repair resulted in a promising outcome.

Ethical approval

Ethical approval has been acquired in this study.

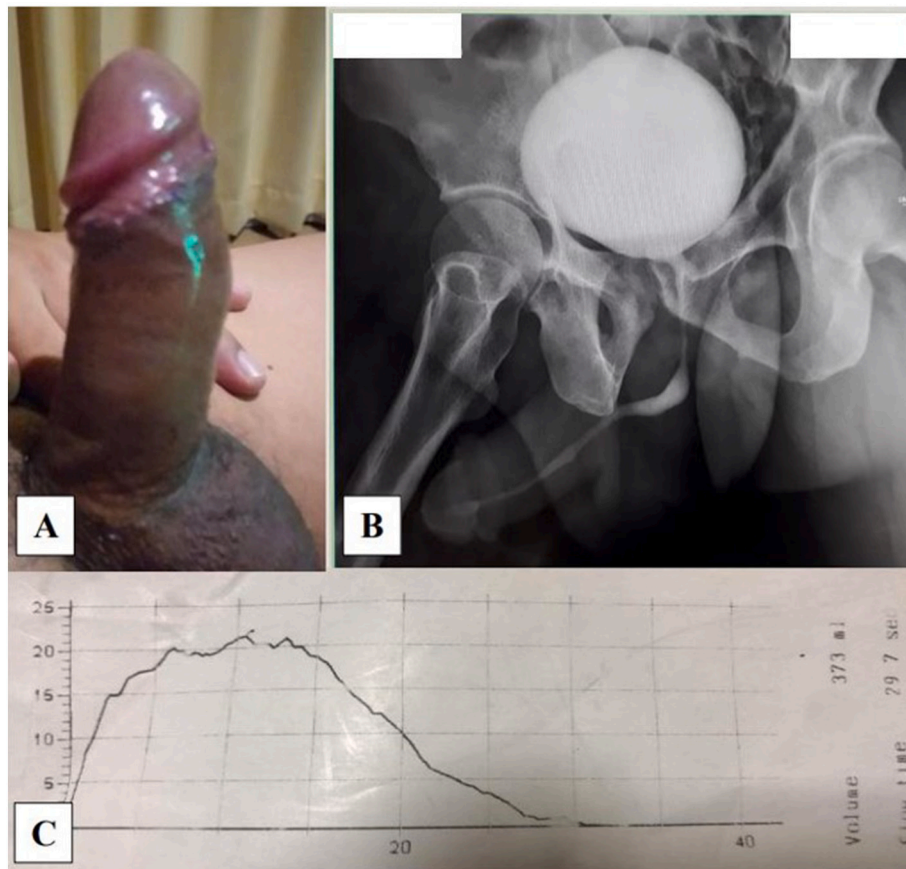


Fig. 3. Post-operative day 21 following surgery (A) Erectile function of the penis with EHS score 4, (B) urethrography, and (C) uroflowmetry test with the result of 22.

Sources of funding

No funding was granted in this study.

Informed consent

Written informed consent was obtained from the patient for publication of this case report and accompanying images. A copy of the written consent is available for review by the Editor-in-Chief of this journal on request.

Author contributions

Conceptualization – GWK, MY, IAR; Data curation – GWK, MY, STJ; Materials – GWK, MY; Formal Analysis – GWK, MY, IAR, STJ; Investigation – GWK, MY, IAR; Methodology – MY, IAR; Supervision – GWK; Writing original draft – GWK, MY, IAR; Writing, review and editing – GWK, STJ.

Registration of research studies

Not applicable.

Guarantor

Gede Wirya Kusuma Duarsa.

Declaration of competing interest

No conflict of interest in this study.

Acknowledgements

None.

Provenance and peer review

Not commissioned, externally peer-reviewed.

References

- [1] A.F. Fergany, K.W. Angermeier, D.K. Montague, Review of Cleveland Clinic experience with penile fracture, *Urology* 54 (2) (1999) 352–355.
- [2] S.V.K. Reddy, A.B. Shaik, K. Sreenivas, Penile injuries: a 10-year experience, *Can. Urol. Assoc. J.* 8 (9–10) (2014) E626.
- [3] K. Sg, D.S. Kulkarni, Ultrasound evaluation of penile fractures, *Biomed. Imaging Interv. J.* 7 (4) (2011) 27–29.
- [4] Z. Kozacioglu, T. Degirmenci, M. Arslan, M.B. Yuksel, B. Gunlusoy, S. Minareci, Long-term significance of the number of hours until surgical repair of penile fractures, *Urol. Int.* 87 (1) (2011) 75–79.
- [5] T.A. Nasser, T. Mostafa, Delayed surgical repair of penile fracture under local anesthesia, *J. Sex. Med.* 5 (10) (2008) 2464–2469.
- [6] A. El-Assmy, H.S. El-Tholoth, T. Mohsen, I.I. El Housseiny, Long-term outcome of surgical treatment of penile fracture complicated by urethral rupture, *J. Sex. Med.* 7 (11) (2010) 3784–3788.
- [7] E.B. Bertero, R.S.M. Campos, D. Mattos Jr., Penile fracture with urethral injury, *Braz. J. Urol.* 26 (3) (2000) 295–297.
- [8] I.I. El Housseiny, H.S. El-Tholoth, T. Mohsen, I.A. Hekal, A. El-Assmy, Penile fracture: long-term outcome of immediate surgical intervention, *Urology* 75 (1) (2010) 108–111.
- [9] R.A. Agha, M.R. Borrelli, R. Farwana, K. Koshy, A.J. Fowler, D.P. Orgill, et al., The SCARE 2018 statement: updating consensus Surgical CAse REport (SCARE) guidelines, *Int. J. Surg.* 60 (2018 Dec) 132–136.
- [10] R.A. Agha, M.R. Borrelli, R. Farwana, K. Koshy, A.J. Fowler, D.P. Orgill, et al., The PROCESS 2018 statement: updating consensus Preferred Reporting Of CAse Series in Surgery (PROCESS) guidelines, *Int. J. Surg.* 60 (2018) 279–282.
- [11] M. Fode, Quantification of surgical delay in penile fractures, *Eur. Urol. Focus* 4 (1) (2018) 111–112.

- [12] A. Chahal, S. Gupta, C. Das, Penile fracture, *Case Rep.* 2016 (2016), bcr2016215385.
- [13] J. Zargooshi, Penile fracture in Kermanshah, Iran: report of 172 cases, *J. Urol.* 164 (2) (2000) 364–366.
- [14] G. Bozzini, M. Albersen, J.R. Otero, M. Margreiter, E.G. Cruz, A. Mueller, et al., Delaying surgical treatment of penile fracture results in poor functional outcomes: results from a large retrospective multicenter European study, *Eur. Urol. Focus* 4 (1) (2018) 106–110.
- [15] C. Yan, B. Liang, H. Huang, B. Liang, Z. Zhou, L. Wang, et al., CT-guided minimally-invasive penile fracture repair, *Int. Braz. J. Urol.* 45 (2019) 183–186.
- [16] R.J. Pliskow, R.J. P, R.K. O, Corpus cavernosography in acute “fracture” of the penis, 1979.
- [17] C. Kamdar, U.M.M. Mooppan, H. Kim, F.A. Gulmi, Penile fracture: preoperative evaluation and surgical technique for optimal patient outcome, *BJU Int.* 102 (11) (2008) 1640–1644.
- [18] F. Mercado-Olivares, J.A. Grandez-Urbina, G. Farfan-Daza, J. Pacheco-Saúne, L. Nuñez-Bragayrac, Case report: double penile fracture, *F1000Research* 7 (2018).
- [19] I. Galanakis, K. Adamos, E. Spyropoulos, S. Mavrikos, Delayed successful surgical repair of penile fracture: a case report, *Curr. Urol.* 12 (2) (2018) 111–112.
- [20] A.A. Raheem, H. El-Tatawy, A. Eissa, A.H. Elbahnasy, M. Elbendary, Urinary and sexual functions after surgical treatment of penile fracture concomitant with complete urethral disruption, *Arch. Ital.Urol.Androl.* 86 (1) (2014) 15–19.