



**KOMISI ETIK PENELITIAN
FAKULTAS KEDOKTERAN HEWAN UNIVERSITAS AIRLANGGA
*Animal Care and Use Committee (ACUC)***

**KETERANGAN KELAIKAN ETIK
“ ETHICAL CLEARANCE ”**

No : 1.KE.107.06.2019

**KOMISI ETIK PENELITIAN (ANIMAL CARE AND USE COMMITTEE)
FAKULTAS KEDOKTERAN HEWAN UNIVERSITAS AIRLANGGA SURABAYA,
TELAH MEMPELAJARI SECARA SEKSAMA RANCANGAN PENELITIAN YANG
DIUSULKAN, MAKA DENGAN INI MENYATAKAN BAHWA :**

- PENELITIAN BERJUDUL** : Potensi Ekstrak Rumput Kebar (*Biophytum
petersianum*) Dalam Mencegah Penurunan Fungsi
Otak Anak Mencit (*Mus musculus*) Masa Laktasi yang
Terpapar Karbofuran
- PENELITI UTAMA** : Epy Muhammad Luqman
- UNIT/LEMBAGA/TEMPAT
PENELITIAN** : Departemen Anatomi Veteriner
Fakultas Kedokteran Hewan Universitas Airlangga
- DINYATAKAN** : LAIK ETIK

Surabaya, 27 Juni 2019

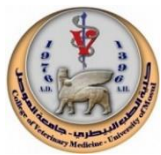Mengetahui,
Dekan FKH-Unair



Prof. Dr. Pudji Sianto, M.Kes.,Drh.
NIP. 195601051986011001

Ketua,

Dr. Nusdianto Triakoso, M.P.,Drh.
NIP. 196805051997021001



The potential of Kebar grass extract on histopathological changes in kidneys of mice offspring from the parent exposed to carbofuran during the lactation period

E.S. Priyatna¹ , M. Mafrucati¹ , H. Plumeriastuti¹ , W. Widjiati¹ , V.F. Hendrawan² 
and E.M. Luqman¹ 

¹Department of Veterinary Science, Faculty of Veterinary Medicine, Universitas Airlangga, Surabaya, ²Department of Animal Reproduction, Faculty of Veterinary Medicine, Universitas Brawijaya, Malang, Indonesia

Article information

Article history:

Received February 18, 2022

Accepted June 11, 2022

Available online June 12, 2022

Keywords:

Carbofuran

Lactation

Kidney

Kebar grass extract

Pesticide stress

Correspondence:

E.P. Luqman

epy-m-l@fkh.unair.ac.id

Abstract

This research aims to know the potential of kebar grass extract (*Biophytum petersianum*) in reducing the impact of kidney damage in mice offspring during the lactation period from parents exposed to carbofuran. Carbofuran, kebar grass extract, and vitamin C are exposed orally postnatal day 1st until the 14th postnatal day after delivery. Forty-two mice adults in the lactation period were randomly into seven groups. This group consisted of K (aquadest control), P1 (carbofuran ¼ LD₅₀ 0.0125 mg/day), P2 (carbofuran 1/8 LD₅₀ 0.00625 mg/day), P3 (kebar grass extract 3.375 mg + carbofuran ¼ LD₅₀), P4 (kebar grass extract 3.375 mg + carbofuran 1/8LD₅₀), P5 (vitamin C 0.2 cc + carbofuran ¼ LD₅₀), and P6 (vitamin C 0.2 cc + carbofuran 1/8 LD₅₀). On the 15th day of experimental, offspring were randomly selected and dissected, and the kidney was taken to make a histopathology sample. This study shows that carbofuran caused increased tubular degeneration, necrosis, and inflammation. Kebar grass extract could decrease tubular degeneration, necrosis, and inflammation. Kebar grass extract was more effective than vitamin C in reducing kidney damage in mice offspring during the lactation period from parents exposed to carbofuran.

DOI: [10.33899/ijvs.2022.133065.2170](https://doi.org/10.33899/ijvs.2022.133065.2170), ©Authors, 2022, College of Veterinary Medicine, University of Mosul.

This is an open access article under the CC BY 4.0 license (<http://creativecommons.org/licenses/by/4.0/>).

Introduction

Insecticides in agriculture are used to increase the quality and productivity of agricultural products. Using insecticides as a pest control has side effects on the environment (1). WHO estimates that there are 1-5 million cases of poisoning each year in agricultural work. In 2012 it was found that 700 farmers in Magelang District, Indonesia, were poisoned (0.8% severe; 8.1% moderate; 66.9% mild; and 24.28% normal). Carbofuran is often used and causes poisoning in humans and animals. Carbofuran was accumulated and found in meat, milk, fat tissue, placenta, agricultural products, fetuses, and umbilicus (2). In Blora Indonesia showed that the residual carbofuran in meat samples reached

169.17 ppb and 349.17 ppb in beef serum; the result exceeds the maximum residual limit (BMR) value (3). Improper use of carbofuran causes damage and malfunctions of body organs. Chronic poisoning disorders are found in the kidneys, liver, heart, and central nervous system. Other research shows that the damage in the kidneys of mice, such as tubular degeneration, tubular necrosis, and inflammatory cell infiltration, has similarly increased with the increase of the dose of carbofuran exposed the parent during lactation (4). Damage to the renal tubules of mice is related to the reaction of carbofuran compounds in the parent milk, the chemicals in the parent body will enter the capillaries, enter the milk, and be sucked by the child (5). Changes in the kidneys' structure are caused by the process of reabsorption

and excretion of these chemicals. Cell damage due to exposure to carbofuran is related to the formation of free radicals in the form of Reactive Oxygen Species (ROS) (1). ROS in particular (OH^*) can cause damage to DNA, lipids, and proteins. Excess ROS in tissue can cause oxidative stress (6). The ROS increase was marked by an increase in malondialdehyde (MDA) in the adult rat brain. Increased ROS can also decrease the brain's superoxide dismutase (SOD) and catalase (CAT) activity (7,8). Decreased catalase activity can reduce protection against free radicals in response to carbofuran (8). Damage from excess free radicals in the body requires external antioxidants to neutralize free radicals. Antioxidants are chemical compounds that can inhibit damage caused by the oxidation process (8). Flavonoids are a group of phenolic compounds which are good antioxidants and can be found in fruits and vegetables (9). Phenolic compounds as antioxidants have mechanisms as reducers, free radical scavengers, and metal binders and prevent the formation of singlet oxygen (9). One of the plants that contain flavonoids is Kebar grass (*Biophytum petersianum*). Kebar grass is an herbal plant that wildly grows in Papua, Indonesia (10). Other compounds contained in the Kebar grass are vitamin A and vitamin E, which works to destroy ROS compounds. Vitamin E is a fat-soluble antioxidant that can reduce lipid free radicals faster than oxygen (10).

The content of Kebar grass is expected to prevent damage due to exposure to carbofuran. Research on giving Kebar grass extract to the histopathological picture of the kidneys of mice needs to be done considering that kidney damage occurs such as degeneration, necrosis, and inflammatory cell infiltration due to the parent being exposed to carbofuran. This study aimed to determine the potential of the Kebar grass extract to decrease the histopathological picture of the kidneys of mice (*Mus musculus*) whose parents were given carbofuran during the lactation period orally. This research is expected to provide information on the potential of the Kebar grass extract on the histopathological picture of mice kidneys during lactation that was exposed to carbofuran in the mice parent.

Materials and methods

This study used a Completely Randomized Design (CRD) with seven treatments and six repetitions. The experimental animals consist of mice mother and offspring (*Mus musculus*) lactating aged 0-14 days. The study was carried out in the Animal Cage and Department of Veterinary Pathology of the Faculty of Veterinary Medicine for making kidney histology preparations.

Ethical approve

All experimental procedures were performed according to the guidelines for the care and use of animals as

established by the Animal Welfare and Experimentation Ethics Committee, Faculty of Veterinary Medicine, Universitas Airlangga, with register number: 1.KE.107.06.2019 (June 27 2019).

Research materials and tools

The materials used in this study: mother mice (*Mus musculus*), Kebar grass (*Biophytum petersianum* Klotzsch), CMC Na, 70% ethanol, carbofuran (2,3-Dihydro-2,2-dimethyl-1-7-benzofuranol N-methylcarbamate 98%) from Aldrich Chemistry with Bellsatin Registry number 1428746, Product of USA. Pellet feed for mice, *aqua dest* as a carbofuran solvent, vitamin C, drinking water, husk as a base of the cage, ether, 10% formalin, and alcohol. The apparatus used in this study consists of plastic cages, wire mesh for experimental animal cages, drinking containers, sonde needles, test tubes, and a syringe of 3 ml. The tools used for the termination of mice are the anesthetic jar, surgical scissors, scalpel, tweezers, and small pot bottles. Equipment for kidney histology preparations includes object glass, cover glass, automatic tissue processor, water bath, hot plate, microtome, and blade kidney histology examination using Olympus® CX-41.

Preparation of materials

This research uses dried Kebar grass. The extract of Kebar grass was made at the Pharmacognosy and Phytochemical Laboratory of the Faculty of Pharmacy, Airlangga University. The dried grass is boiled in distilled water. Three hundred fifty grams of *Simplicia* of Kebar grass mashed are macerated in a tube for 3x24 hours with 70% ethanol solvent ratio 1:10, then filtered, and the dregs are macerated two times again with the same treatment. A rotary evaporator evaporates the macerate at a temperature of 30-40°C to form a thick extract. The extract was put in a bottle and stored in the refrigerator (11).

Methods

The pregnant mice were divided into seven groups, namely C, P1, P2, P3, P4, P5, and P6. The experimental animals were placed in plastic cages covered with wire and given husks as a base. Mice were fed pellets and drank equates through *ad libitum* every day during the study. Determination of the dosage of Kebar grass used in this study (11). Kebar grass provides an effective antioxidant effect to prevent oxidative stress by 0.135mg/g BW/day. With an average body weight of 25 grams of mice, the dosage used is $0.135\text{mg} \times 25\text{g} = 3.375\text{mg}/25\text{g}/\text{day}$.

The carbofuran dose used the LD50 fraction for 14 days, namely $\frac{1}{4}$ LD 50 (0.0125 mg/25g mice/day) and $\frac{1}{8}$ LD50 (0.00625 mg/25mg mice/day) (7). Mice were given oral treatment during the lactation period from the first to the 14th day with Kebar grass, vitamin C, and carbofuran using 1 ml tuberculin. The treatments were described as follows: C in

the control group, P1 given carbofuran 1/4 LD50 (0.0125 mg/day), P2 was given carbofuran 1/8 LD50 (0.00625 mg/day), P3 was given Kebar grass extract 3,375 mg + carbofuran 1/4 LD50 (0.0125 mg/day), P4 was given Kebar grass extract 3,375 mg + carbofuran 1/8 LD50 (0.00625 mg/day), P5 was given vitamin C 5mg + carbofuran 1/4 LD50 (0.0125 mg/day), P6 was given vitamin C 5mg + carbofuran 1/8 LD50 (0.00625 mg/day). On the 15th day of treatment, the researcher performed surgery for kidney retrieval and made histological preparations. The kidneys were put into a pot containing a 10% buffered formalin solution. Then histopathology was made using HE staining.

The observation of the kidneys using a light microscope with a magnification of 100x and 400x in the kidney tubules with five different fields of view. Furthermore, the assessment is carried out by scoring the changes in the kidneys. Changes during practical include degeneration, tubular cell necrosis, and inflammatory cell infiltration (Table 1) (12).

Statistical analysis

The scoring changes in kidney preparations are analyzed with the SPSS version 23 using the Kruskal Wallis test followed by the Mann Whitney test at $P < 0.05$.

Table 1: Scoring kidney histopathology

Score	Tubular cell degeneration
0	There is no tubular cell degeneration
1	There was tubular cell degeneration <25% of all fields view
3	There was tubular cell degeneration in 26-50% of all fields view
5	There was tubular cell degeneration >50% of all fields view
Score	Tubular cell necrosis
0	There is no tubular cell necrosis
1	There was tubular cell necrosis <25% of all fields view
3	There was tubular cell necrosis in 26-50% of all fields view
5	There was tubular cell necrosis >50% of all fields view
Score	Inflammatory cell infiltration
0	There is no inflammatory cell infiltration
1	There was inflammatory cell infiltration <25% of all fields view
3	There was inflammatory cell infiltration in 26-50% of all fields view
5	There was inflammatory cell infiltration >50% of all fields view

Results

Degeneration

The researcher made observations regarding microscopic degeneration of the kidney preparations of the mice with HE staining. Degeneration is characterized by cell cytoplasm swelling and cloudiness due to vacuoles. The results of degeneration observations can be seen in Table 2. The statistical analysis results based on Table 2 showed a

significant difference between the K treatment group and the P1, P2, P3, P4, P5, and P6 groups. There was a significant difference between the P1 treatment and the P2, P3, P4, P5, and the P6 treatments. In addition to a significant difference between P2 and P3, P4, P5, and P6. There is a significant difference between P3 and P4, P5, and P6. There is a significant difference between the P4, P5, and P6 groups, and there was a significant difference between P5 and P6 (Figure 1).

Table 2: Scoring results in kidney damage in mice offspring

Treatment	Degeneration	Necrosis	Inflammatory Infiltration
C (control)	0.00 ^a ±0.00	0.00 ^a ±0.00	0.00 ^a ±0.00
T1 (carbofuran 1/4 LD ₅₀)	4.73 ^g ±0.23	4.73 ^g ±0.46	4.60 ^g ± 0.00
T2 (carbofuran 1/8 LD ₅₀)	3.93 ^f ±0.23	3.80 ^f ±0.00	3.66 ^f ±0.23
T3 (carbofuran 1/4 LD ₅₀ + Kebar grass extract 3.375 mg)	1.40 ^c ±0.00	1.33 ^c ±0.11	1.33 ^c ±0.11
T4 (carbofuran 1/8 LD ₅₀ + Kebar grass extract 3.375 mg)	0.80 ^b ±0.20	0.86 ^b ±0.11	0.86 ^b ±0.11
T5 (carbofuran 1/4 LD ₅₀ + vitamin C)	2.86 ^e ±0.23	3.00 ^e ±0.40	3.00 ^e ±0.00
T6 (carbofuran 1/8 LD ₅₀ + vitamin C)	2.06 ^d ±0.23	2.06 ^d ±0.23	1.93 ^d ±0.23

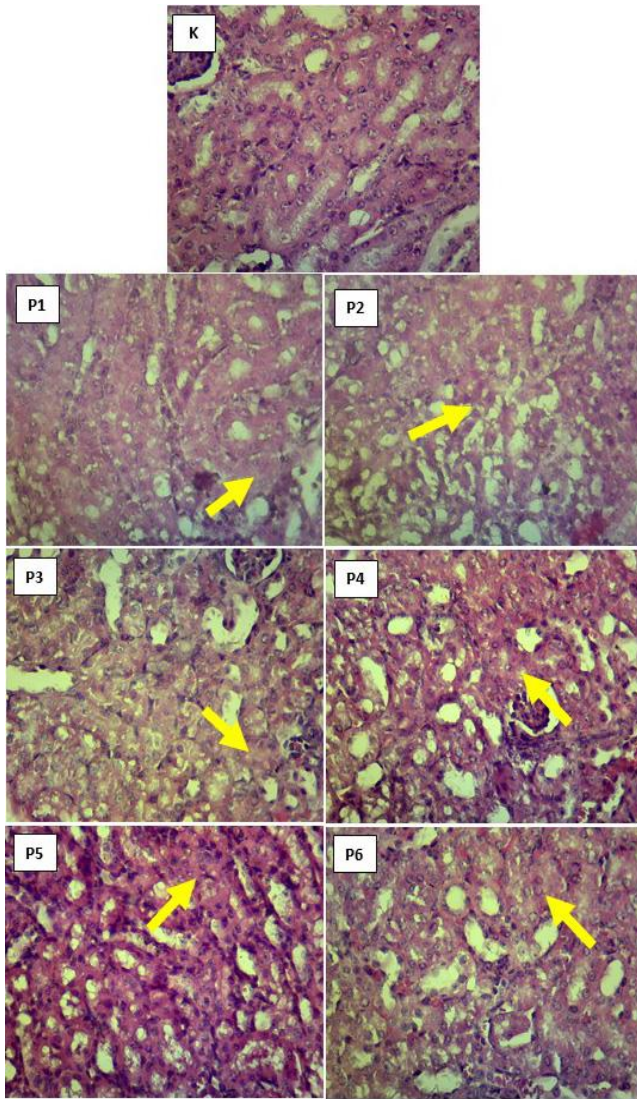


Figure 1: Microscopic picture of tubular degeneration in the kidney mice. Arrows indicate degeneration (arrow). HE staining (scale bar = 40 μ m).

Necrosis

Assessment of necrosis was carried out by microscopic observation of the kidney preparations of the mice (*Mus musculus*) stained with HE staining. Observations were made using a 400x magnification microscope. There is necrosis in the presence of pyknosis, karyorrhexis, and karyolysis. The results of necrosis observations can be seen in table 2. The statistical analysis results based on table 2 showed a significant difference between the C treatment group and the P1, P2, P3, P4, P5, and P6 groups. There was a significant difference between the P1 treatment and the P2, P3, P4, P5, and P6 treatments. There is a significant difference between P2 and P3, P4, P5, and P6. There is a significant difference

between P3 and P4, P5, and P6. There was a significant difference between the P4 and P5, and P6 groups, and there was a significant difference between P5 and P6 (Figure 2).

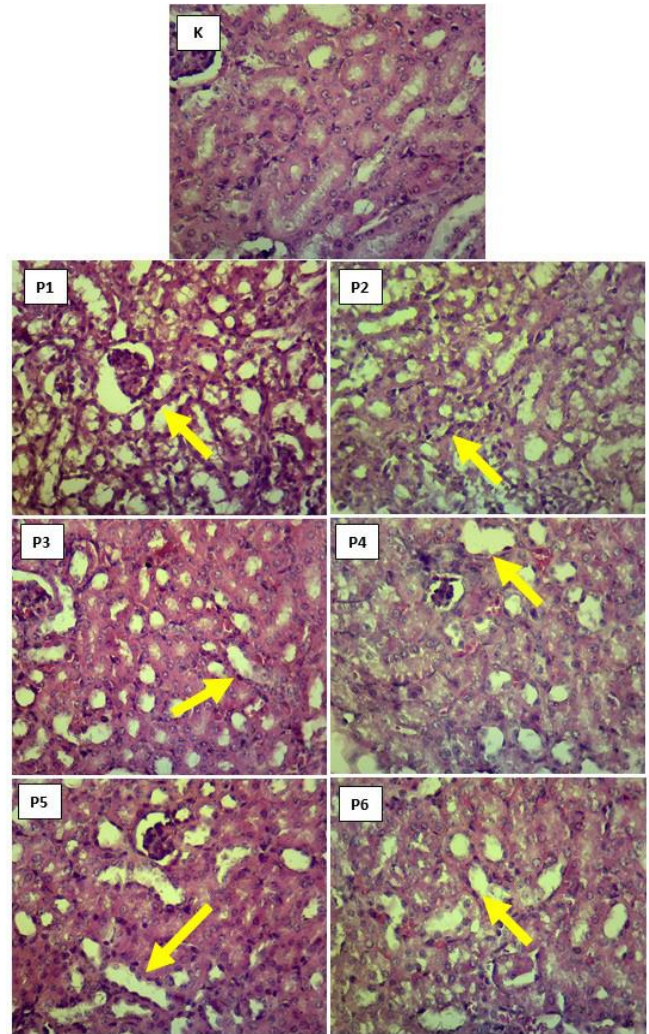


Figure 2: Microscopic picture of tubular necrosis in the kidney mice. Arrows indicate necrosis (arrow). HE staining (scale bar = 40 μ m).

Inflammatory cell infiltration

The assessment of inflammatory cell infiltration was carried out by microscopic observation of the kidney preparations of the mice (*Mus musculus*) stained with HE staining. Observations were made using a microscope with a magnification of 400x in the interstitial renal tubules. The presence of inflammatory cell infiltration is seen in the interstitial renal tubules. The results of inflammatory cell infiltration observations can be seen in table 2. The statistical analysis results based on table 2 showed a significant difference between the C treatment group and the P1, P2, P3,

P4, P5, and P6 groups. There was a significant difference between the P1 treatment and the P2, P3, P4, P5, and P6 treatments. There is a significant difference between P2 and P3, P4, P5, and P6. There is a significant difference between P3 and P4, P5, and P6. There was a significant difference between the P4 and P5, and P6 groups, and there was a significant difference between P5 and P6 (Figure 3).

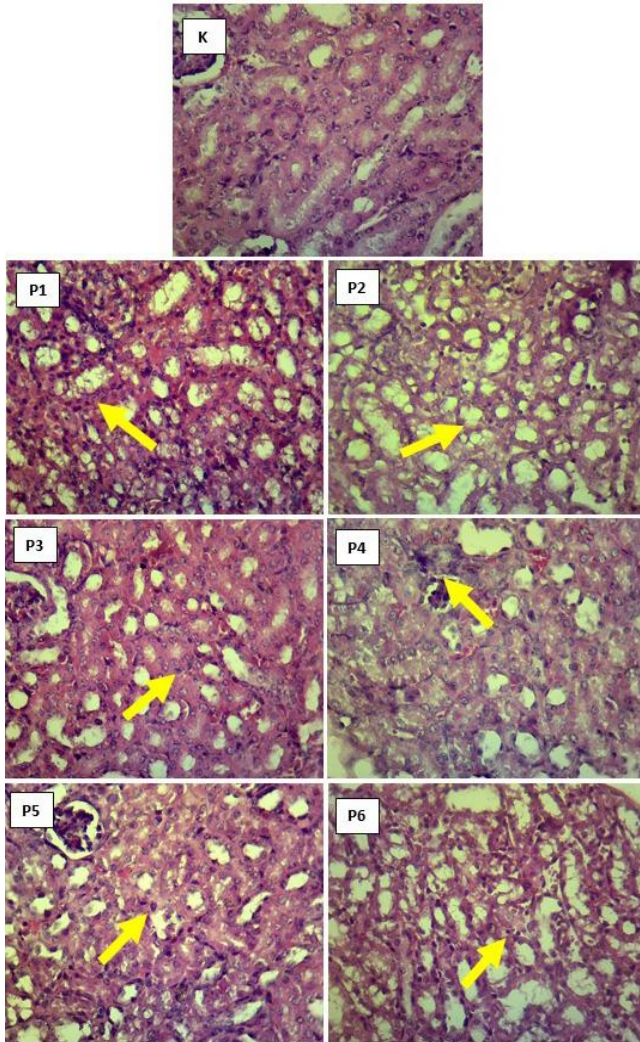


Figure 3: Microscopic picture of inflammatory cell infiltration in the kidney mice. Arrows indicate inflammatory cell infiltration (arrow). HE staining (scale bar = 40 μ m).

Discussion

Carbofuran is metabolized in the body by cytochrome P450 to produce a systemic 3-hydroxy carbofuran which causes an increase in the toxic activity (13). Toxic manifestations are attributed to the carbamate group resulting in the presence of ROS and the formation of free radicals

(14). ROS increase can decrease superoxide dismutase (SOD) and catalase (CAT) activity in the brain. Decreased catalase activity can reduce protection against free radicals in response to carbofuran (8). Excess ROS in tissues can cause oxidative stress due to ROS imbalance with antioxidant compounds in the body (6). Research by Luqman *et al.* (7) shows that exposure to carbofuran to the parent during lactation causes an increase in the MDA levels in the brains of breastfed mice. Carbofuran is a broad-spectrum insecticide with lipophilic characteristics and can enter parent breast milk (15). The lipophilic nature of carbofuran will form lipid peroxidation in the kidneys after binding with lipids from membra kidney cells. Phospholipids, the main elements of the plasma membrane, are subject to lipid peroxidation, increase free radical production, and cause oxidative stress and cell membrane damage (16). Damage to the cell membrane causes a shift in cell load, changes in osmotic pressure, the appearance of swelling, and cell death. The kidneys are a critical target for xenobiotic compounds in the body, thus becoming a chemical excretion pathway and allowing for nephrotoxic effects (17).

Kebar grass, as an antioxidant, contains flavonoids which are useful for preventing cell damage due to oxidative stress. Flavonoids have a direct or indirect mechanism of action as antioxidants. Antioxidants directly donating hydrogen ions can neutralize the toxic effects of free radicals. Flavonoids as antioxidants can indirectly increase endogenous antioxidant gene expression. One of the increases in gene expression is the activation of nuclear factor erythroid two related factor 2 (Nrf2), which then increases genes that function in the synthesis of endogenous antioxidant enzymes, such as the SOD gene (18). The vitamin A and vitamin E content in Kebar grass also function actively as antioxidants. Vitamin A reacts with free radicals and makes free radicals stable (15). Vitamin E can inhibit oxidation reactions by binding to vitamin E radicals due to breaking free radicals into free vitamin E, which can function again as antioxidants (19).

One kidney damage caused by toxic compounds is to show a picture in the form of degeneration in tubular cells. Degeneration is when cells lose their standard structure due to influences inside and outside the cell. Metabolic disorders characterize degeneration. Carbofuran can disrupt metabolic reactions resulting in ATP reduction, energy for cells, and changes in cell membranes. This affects the cation pump, increasing water and ions permeability (20). At the cell membrane level, cells will release metabolic energy to pump sodium ions out of the cell to maintain a stable internal environment. Toxic compounds that disrupt the energy in cells or cell membranes result in cells being unable to pump sodium ions. There is an increase in sodium concentration ions in the cell, followed by the entry of water into the cell, and there is swelling of the cell, and the cytoplasm looks cloudy. In this study, there is an increase in degeneration in line with the increase in carbofuran dose presented. The P1

and P2 groups showed a significant difference ($P < 0.05$). Cell swelling or degeneration is a reversible injury and the first manifestation that occurs due to the inability of cells to maintain ion and fluid homeostasis. If the toxic compounds are removed, cells can return to normal. These changes are a mild disturbance from normal conditions (21).

In the P3 and P4 groups, giving the Kebar grass extract before the parent was exposed to carbofuran decreased the picture of renal tubular degeneration. The antioxidant content in flavonoids and vitamin E in the extract of Kebar grass can reduce kidney damage because it can prevent and inhibit the toxic effects of carbofuran on the kidneys. This result is also consistent with the research conducted by Rabiah *et al.* (22), giving vitamin E as an antioxidant can maintain the integrity of cell membranes and provide protection against cell damage in the kidneys. Vitamin E can be a hydrogen ion donor that can convert peroxy radicals into less effective tocopherol radicals so that the fatty acid chains cannot be broken. The content of flavonoids can also increase the regeneration process, provide a competitive substrate for unsaturated lipids, and repair damaged cell membranes faster decrease degeneration. Giving vitamin C to groups P5 and P6 reduced renal degeneration due to exposure to carbofuran. Vitamin C is an antioxidant that can reduce free radicals by inhibiting lipid peroxidation and preventing cell damage from occurring (23).

Necrosis is a continuation of degeneration that has passed the point of no return and irreversible damage due to the failure of cells to maintain their balance. Damaged cell membranes result in a shift in cell load, changes in osmotic pressure, swelling, and cell death. The toxic activity due to carbofuran due to ROS can induce oxidative damage by increasing lipid peroxidation. Increased ROS is one of the free radicals that result in toxicity and cell death. The levels of antioxidants in the body are not sufficient to compensate for free radicals. The cells will experience necrosis (24).

High concentrations of toxic compounds in the body can cause reactions with all cell components, thereby suppressing cell function, resulting in cell death and organ damage. Damage in cells is because of the toxic coagulation of proteins in the protoplasm and nucleus. The microscopic image shows a change in the nucleus that loses chromatin, becomes wrinkled, no longer vascular, the nucleus becomes solid, dark in color, divided into fragments, and the core is no longer colored. Groups P1 and P2 showed an increase in necrosis due to exposure to carbofuran. Necrosis increased with increasing carbofuran dose. The necrosis in the tubules is due to the toxic carbofuran compound in the bloodstream. Carbofuran is absorbed by the glomerulus and then goes to the tubule. After arriving at the tubule, it will be metabolized into the water more efficiently, then it is easier to enter the cell and affects the metabolism of mitochondria. The longer the kidneys are exposed to toxic compounds, the greater the amount of kidney tissue experiencing necrosis.

The extract of the Kebar grass given to the P3 and P4 groups gave a decrease in renal necrosis in mice. The decrease in necrosis in the P3 group was smaller than that of the P4 group. This is because the dose of carbofuran exposed at P4 was less than the P3 group. The decrease in kidney necrosis is due to the antioxidant content present in the extract of Kebar grass, such as flavonoids, vitamin A and vitamin E. Vitamin E as an antioxidant can break the chains in the membrane, which can prevent cell damage due to lipid peroxidation and inhibit the occurrence of free radicals (25). Flavonoids also have the potential to prevent lipid peroxidation at the initiation stage with the radical scavenger, and the propagation reaction is prevented by the peroxy-radical scavenger (26). Giving vitamin C to groups P5 and P6 showed decreased renal necrosis in mice and significantly differed. Ascorbic acid is an exogenous antioxidant that can reduce free radicals, inhibit lipid peroxidation, and prevent cell damage (23).

Groups P1 and P2 showed an increase in inflammatory cell infiltration in the interstitial lumen of the renal tubules of mice in proportion to the dose of carbofuran exposure given to the parent. Inflammatory cells are the body's response to tissue damage caused by pathogenic agents, dead cells, irritants, foreign bodies, physical injuries, burns, radiation, or toxic compounds. Inflammatory cells are avascular reactions in the delivery of fluids, solutes, and cells from the blood circulation to the interstitial tissue in injury or necrosis. Necrosis stimulates an inflammatory response by secreting inflammatory cytokines IL-6 to activate NF κ B, p38, and MAPK (27).

Groups P3 and P4 gave a significant difference and decreased the infiltration of inflammatory cells in the interstitial lumen of the renal tubules of mice. The P4 group had a more significant decrease in inflammatory cell infiltration than the P3 group because the carbofuran dose given to P4 was less than P3. The content of Kebar grass can also repair damaged kidney cells so that inflammatory cells have decreased. Antioxidants in Kebar grass, such as flavonoids, can bind Cu and Fe metal ions to form ROS (25). Binding metal ions can reduce oxidative damage to cells and prevent inflammatory cell infiltration. Groups P5 and P6 with vitamin C administration decreased inflammatory cell infiltration and gave a significant difference. The provision of vitamin C as an antioxidant can neutralize and protect from the effects of free radicals and improve cells' functional structure due to exposure to free radicals (26).

Conclusion

The administration of Kebar grass extract on mice during the lactation period which was exposed carbofuran orally to the parent, could reduce the histopathology of the mice offspring's kidneys. Giving Kebar grass extract can have a better effect than giving vitamin C in reducing kidney

damage in mice offspring, such as degeneration, necrosis, and inflammatory cell infiltration.

Acknowledgments

The authors express sincere thanks to the Ministry of Research, Technology and Higher Education of the Republic of Indonesia for funding research and the Dean Faculty of Veterinary Medicine for providing all necessary facilities and funds for conducting research work.

Conflict of interest

The authors declare that there are no conflicts of interest regarding the publication of this manuscript.

References

1. Jaiswal SK, Siddiqi NJ, Sharma B. Carbofuran induced oxidative stress in rat heart: Ameliorative effect of vitamin C. *ISRN Oxid Med*. 2013;11:1-10. DOI: [10.1155/2013/824102](https://doi.org/10.1155/2013/824102)
2. Keegan J, Michelle W, Martin D, Steven C, Regina S, Aniello A, Christopher, E, David B, Ambrose F, Richard O. Benzimidazole carbamate metabolites in milk: detection by surface plasmon resonance-biosensor, using a modified QuEChERS (quick, easy, cheap, effective, rugged and safe) method for extraction. *Anal Chim Acta*. 2009;10;654(2):111-119. DOI: [10.1016/j.aca.2009.09.028](https://doi.org/10.1016/j.aca.2009.09.028)
3. Indrianingsih H. Effect of carbamate insecticide on animal health and its products. *Wartazoa J*. 2008;18(2):101-114. [\[available at\]](#)
4. Purnomo E, Luqman EM, Ratnani H, Plumeriastuti H, Mafruchati M, Dhamayanti Y. The increasing damage in tubular cell of infant mice's kidneys from carbofuran exposure during its mothers' lactation period. *Int J Pharm Res*. 2020;12(4):17-24. DOI: [10.31838/ijpr/2020.12.04.004](https://doi.org/10.31838/ijpr/2020.12.04.004)
5. Rekha SR, Hamid S. Histopathological effects of pesticide-cholopyrifos on kidney in albino rats. *Int J Med Sci*. 2013;1(4):465-475. DOI: [10.5455/2320-6012.ijrms20131131](https://doi.org/10.5455/2320-6012.ijrms20131131)
6. Goodyear-Brunch C, Pierce JD. Oxidative stress in critically ill patients. *Am J Crit Care*. 2002;11(6):543-551. DOI: [10.4067/s0034-98872006000500015](https://doi.org/10.4067/s0034-98872006000500015)
7. Luqman EM, Widjiati, Yustinasari LR. Brain cells death on infant mice (Mus Musculus) caused by carbofuran exposure during the lactation period. *Kafkas Univ Vet Fak Derg*. 2018;24(6):845-852. DOI: [10.9775/kvfd.2018.20045](https://doi.org/10.9775/kvfd.2018.20045)
8. Luqman EM, Sudiana, IK, Darmanto W, Achmad AB, Widjiati. mouse (Mus musculus) embryonic cerebral cortex cell death caused by carbofuran insecticide exposure. *J Vet Res*. 2019;63(3):413-421. DOI: [10.2478/jvetres-2019-0040](https://doi.org/10.2478/jvetres-2019-0040)
9. Kumara N, Goelb N. Phenolic acids: natural, versatile molecules with promising therapeutic applications. *Biotechnol Rep*. 2019;24:e00370. DOI: [10.1016/j.btre.2019.e00370](https://doi.org/10.1016/j.btre.2019.e00370)
10. Sembiring B, Darwati I. Identification of the chemical components of Kebar grass (*Biophytum petersianum*) accession from Papua and Java. *Bullittro*. 2014;25(1):37-44. DOI: [10.21082/bullittro.v25n1.2014.37-44](https://doi.org/10.21082/bullittro.v25n1.2014.37-44)
11. Labib MF, Widjiati, Hernawati T, Luqman EM, Kurnijasanti R, Suprayogi TW. Kebar grass (*Biophytum petersianum* K.) The effect in maintaining mice (*Mus musculus*) sperm quality exposed to dioxin. *Int J Res Pharm Sci*. 2020;11(3):4977-4981. DOI: [10.26452/ijrps.v11i3.2817](https://doi.org/10.26452/ijrps.v11i3.2817)
12. Racusen LC, Solez K, Colvin R, Bonsib SM, Castro MC, Cavallo T, Croker BP, Demetri AJ, Drachenberg CB, Fogo A. The banff97 working classification of renal allograft pathology. *Kidney Int*. 1999;55(2):713-723. DOI: [10.1046/j.1523-1755.1999.00299.x](https://doi.org/10.1046/j.1523-1755.1999.00299.x)
13. Usmani AK, Ernest H, and Rose L. In vitro metabolism of carbofuran by human, mouse, and rat cytochrome P450 and interactions with chlorpyrifos, testosterone, and estradiol. *Chem Biol Interact*. 2004;150(3):221-232. DOI: [10.1016/j.cbi.2004.09.015](https://doi.org/10.1016/j.cbi.2004.09.015)
14. Eraslan G, Kanbur M, Silici. Effect of carbaryl on some biochemical changes in rats: the ameliorative effect of bee pollen. *Food Chem Toxicol*. 2009;47(1):86-91. DOI: [10.1016/j.fct.2008.10.013](https://doi.org/10.1016/j.fct.2008.10.013)
15. Sharma RK, Sharma B. In-vitro carbofuran induced genotoxicity in human lymphocyte and its mitigation by vitamin C and E. *Dis Markers*. 2012;32(3):153-163. DOI: [10.3233/DMA-2011-0870](https://doi.org/10.3233/DMA-2011-0870)
16. Sipos P, Szentmihalyi K, Feher E, Abaza M, Szilagyi M, and Blazovics A. Some effects of lead contamination on liver and gallbladder bile. *Acta Biol Szeged*. 2003;47(1):139-142. [\[available at\]](#)
17. Kaur B, A Khera, R Sandhir. Attenuation of cellular antioxidant defense mechanisms in kidney of rats intoxicated with carbofuran. *J Biochem Mol Toxicol*. 2012;26 (10):393-398. DOI: [10.1002/jbt.21433](https://doi.org/10.1002/jbt.21433)
18. Ma Q. Role of Nrf2 in oxidative stress and toxicity. *Annu Rev Pharmacol Toxicol*. 2013;53:401-426. DOI: [10.1146/annurev-pharmtox-011112-140320](https://doi.org/10.1146/annurev-pharmtox-011112-140320)
19. Pavlovic V, Cekic S, Rankovic G, Stoiljkovic N. Antioxidant and pro-oxidant effect of ascorbic acid. *Acta Med Median*. 2005;44:65-69. [\[available at\]](#)
20. Kay AR. How cells can control their size by pumping ions. *Front Cell Dev Biol*. 2017;8(5):1-12. DOI: [10.3389/fcell.2017.00041](https://doi.org/10.3389/fcell.2017.00041)
21. Miller MA, Zachary JF. Mechanisms and morphology of cellular injury, adaptation, and death. NY: CRC press; 2017. 2-43 p. DOI: [10.1016/B978-0-323-35775-3.00001-1](https://doi.org/10.1016/B978-0-323-35775-3.00001-1)
22. Rabiah ES, Berata IK, Samsuri. Histopathological description of white rats kidney administered with dexamethasone and vitamin E. *Indones Med Veterinus*. 2015;4(3):249-256. DOI: [10.24843/bulvet.2018.v10.i01.p03](https://doi.org/10.24843/bulvet.2018.v10.i01.p03)
23. Yimcharoen M, Kittikunnathum S, Suknikorn C, Nak-On W, Yeethong P, Anthony TG, Bunpo P. Effects of ascorbic acid supplementation on oxidative stress markers in healthy women following a single bout of exercise. *J Int Soc Sports Nutr*. 2019;16(1):2-11. DOI: [10.1186/s12970-019-0269-8](https://doi.org/10.1186/s12970-019-0269-8)
24. Ayala A, MF Munoz, S Arguelles. Lipid peroxidation: production, metabolism, and signaling mechanism of malondialdehyde and 4-Hydroxy-2-Nonenal. *Oxid Med Cell Longev*. 2014;34:1-31. DOI: [10.1155/2014/360438](https://doi.org/10.1155/2014/360438)
25. Sharma P, Jha AB, Dubey RS, Pessaraki M. Reactive oxygen species, oxidative damage, and antioxidative defense mechanism in plants under stressful conditions. *J Bot*. 2012;12:1-26. DOI: [10.1155/2012/217037](https://doi.org/10.1155/2012/217037)
26. Lobo V, Patil A, Phatak A, Chandra N. Free radicals, antioxidants, and functional foods: Impact on human health. *Pharmacogn Rev*. 2010;4(8):118-126. DOI: [10.4103/0973-7847.70902](https://doi.org/10.4103/0973-7847.70902)
27. Vanlangenakker N, Vandenberghe T, Dimitri K, Nele F, Vandabeele P. Molecular mechanism and pathophysiology of necrotic cell death. *Curr Mol Med*. 2008;8(3):207-220. DOI: [10.2174/156652408784221306](https://doi.org/10.2174/156652408784221306)

الفئران خلال فترة الرضاعة في الامهات المعرضات للكاربوفوران. الكاربوفوران، ومستخلص عشب الكبار، وفيتامين س استخدمت عن طريق الفم من اليوم الأول بعد الولادة وحتى اليوم الرابع عشر بعد الولادة. تم تقسيم ٤٢ فأراً بالغاً في فترة الرضاعة بشكل عشوائي إلى سبع مجموعات. تضمنت المجموعات ما يلي، K (مجموعة السيطرة) ، P1 (كاربوفوران ¼ LD50 0.0125 ملغم / يوم) ، P2 (كاربوفوران ¼ LD50 0.00625 ملغم / يوم) ، P3 (مستخلص عشب الكبار ٣,٣٧٥ ملغم + كاربوفوران ¼ LD50) ، P4 (كبار مستخلص العشب ٣,٣٧٥ ملغم + كاربوفوران ¼ LD50) ، P5 (فيتامين س ٠,٢ مل + كاربوفوران ¼ LD50) ، P6 (فيتامين س ٠,٢ مل + كاربوفوران ¼ LD50). في اليوم الخامس عشر من التجربة ، تم اختيار صغار الفئران بشكل عشوائي وتم تشريحها ، وأخذت الكلية لعمل عينات الفحص النسيجي. اظهر هذه الدراسة أن الكاربوفوران تسبب في زيادة التتسكس الأنبوبي والنخر والالتهاب. وأن عشب الكبار من الممكن ان يقلل من التتسكس الأنبوبي والنخر والالتهاب. ايضاً كان مستخلص عشب الكبار أكثر فعالية من فيتامين س في الحد من تلف الكلى في صغار الفئران خلال فترة الرضاعة من الامهات التي تعرضت للكاربوفوران.

تأثير مستخلص عشب الكبار على التغيرات النسيجية المرضية في كلية صغار الفئران من خلال الامهات التي تعرضت للكاربوفوران خلال فترة الرضاعة

إرنستين سيسكا براياتنا^١، ماسلشاح مفروكاتي^١، هاني بلوميرياستوتي^١، وجاتي وجاتي^١، فيسكي فتري هندراوان^٢، إبي محمد لقمان^١

^١ قسم العلوم البيطرية، كلية الطب البيطري، جامعة إيرلانغا، سورابايا،
^٢ قسم تكاثر الحيوانات، كلية الطب البيطري، جامعة براويجايا، مالانغ،
إندونيسيا

الخلاصة

يهدف هذا البحث إلى معرفة إمكانات مستخلص عشب الكبار (Biophytum petersianum) في الحد من تأثير تلف الكلى في صغار