

# Potency of Kebar Grass (*Biophytum petersianum*) Extract to Histopathological of Mice (*Mus musculus*) Duodenum at Lactation Period Exposed to Carbofuran

*by* Epy Muhammad Luqman

---

**Submission date:** 20-Dec-2022 12:00PM (UTC+0800)

**Submission ID:** 1984845120

**File name:** s\_Biophytum\_petersianum\_Extract\_to\_Histopathological\_of\_Mice.pdf (1.53M)

**Word count:** 4631

**Character count:** 24654



## Potency of Kebar Grass (*Biophytum petersianum*) Extract to Histopathological of Mice (*Mus musculus*) Duodenum at Lactation Period Exposed to Carbofuran

Muchammad Manhum Mawarid<sup>1</sup>, Maslichah Mafruchati<sup>1</sup>, Tri Wahyu Suprayogi<sup>1</sup>, Widjiati<sup>1</sup>, Viski Fitri Hendrawan<sup>2</sup> and Epy Muhammad Luqman<sup>1\*</sup>

<sup>1</sup>Department of Veterinary Science, Faculty of Veterinary Medicine, Universitas Airlangga Jl Mulyorejo Surabaya, 60115 Indonesia

<sup>2</sup>Department of Animal Reproduction Faculty of Veterinary Medicine, Universitas Brawijaya, Malang 65151, Jawa Timur, Indonesia.

**Corresponding author:** Epy Muhammad Luqman, Department of Veterinary Science, Faculty of Veterinary Medicine, Universitas Airlangga Jl Mulyorejo Surabaya, 60115 Indonesia, Tel: +62315992785; E-mail: epy-m-l@fkh.unair.ac.id

### Abstract

This research was aimed to find out the effect of the Kebar grass extract on a decrease in villi damage in the duodenum of mice at lactation period due to exposure to carbofuran such as congestion, edema, and neutrophil infiltration. This research used forty-two mice at lactation period, divided into seven treatment groups, each group consisting of six mice. The treatment groups consisted of C (aquadest); T1 carbofuran 0.0125 mg (1/4 LD<sub>50</sub>); T2 carbofuran 0.00625 mg (1/8 LD<sub>50</sub>); T3 Kebar grass extract 3.375 mg + carbofuran 1/4 LD<sub>50</sub>; T4 Kebar grass extract 3.375 mg + carbofuran 1/8 LD<sub>50</sub>; T5 vitamin C 5 mg + carbofuran 1/4 LD<sub>50</sub>; and T6 vitamin C 5 mg + carbofuran 1/8 LD<sub>50</sub>. All groups were treated for 14 days and on day 15 all mice were slaughtered for histopathological observation on their duodenum. The data were analyzed using the Kruskal-Wallis test and the Mann-Whitney test with a significance of  $p < 0.05$ . The results showed that carbofuran administration could increase congestion, edema, and neutrophil infiltration ( $p < 0.05$ ). The administration of Kebar grass extract was proven to reduce congestion, edema, and neutrophil infiltration and a decrease in congestion, edema, and neutrophil infiltration was better when it was administered Kebar grass extract compared to vitamin C ( $p < 0.05$ ).

**Keywords:** Kebar grass extract, Carbofuran, Lactation period, Duodenum, Pesticide stress

### INTRODUCTION

Carbamate insecticides are commonly used to get rid of pests attacking crops or fruits particularly carbofuran [1]. Residue on agricultural crops impact on health of humans and livestock's, which is not the main target of using insecticide. The results of a research [2] found carbofuran residue in animal feed such as hay, corns, and rice (value of 12–102 ppb), which can cause residue in the meat as much as 110–269 ppb and in the cattle serum as much as 167–721 ppb. Carbofuran exposure can cause free radicals in the form of Reactive Oxygen Species (ROS), which will impact on the death of cells in the body including intestinal epithelial cells [3]. ROS can cause membrane lipid peroxidation so fatty acid chains in cell membranes are broken and then it causes injury in cells [4]. Exposure to toxic substances can cause inflammation in intestinal lamina propria so it will cause villi damage, congestion, oedema, neutrophilic infiltration [5]. Malonaldehyde (MDA) and SOD are used as indicator to lipid peroxidation and necrosis [6,7]. The presence of antioxidant compounds and an increase in ROS, which is imbalanced will lead to oxidative stress and cause the damage on DNA, lipid, and protein [8].

Kebar Grass (*Biophytum petersianum*) is a plant containing flavonoids and wildly grows in Papua, Indonesia [9]. Phenolic

compounds serve as antioxidants, which have mechanism to reduce and capture free radicals [10]. Vitamin E as lipid antioxidants is able to extinguish free radicals and functions as membrane stabilizer [11]. Vitamin A as antioxidants works by weakening peroxy radicals and inhibiting lipid oxidation [12].

Mothers have hyperphagia at lactation period, which causes unstable condition of the mothers. The change in intestinal mucosa leads to an increase in the number of mucosal epithelial cells, which causes the change in villi condition [13]. Females that are at lactation period are more susceptible than females that are not at lactation period due to higher stress level, which triggers susceptibility to toxic substances [14]. The intestine can also be the main tract or portal in which a substance undesired by the body such as toxic substances,

**Received:** March 21, 2022; **Revised:** April 01, 2022; **Accepted:** April 14, 2022

**Citation:** Mawarid MM, Mafruchati M, Suprayogi TW, Widjiati, Hendrawan VF, et al. (2022) Potency of Kebar Grass (*Biophytum petersianum*) Extract to Histopathological of Mice (*Mus musculus*) Duodenum at Lactation Period Exposed to Carbofuran. J Vet Marine Res, 1(1): 1-9.

**Copyright:** ©2022 Mawarid MM, Mafruchati M, Suprayogi TW, Widjiati, Hendrawan VF, et al. This is an open-access article distributed under the terms of the Creative Commons Attribution License, which permits unrestricted use, distribution, and reproduction in any medium, provided the original author and source are credited.

like insecticides and drugs enters the body [15,16]. Insecticides can cause necrosis, which leads to hypermotility and malabsorption due to a decrease in the number of erythrocyte cells [17]. Entry of toxic substances can cause free radicals to increase endothelial permeability and intestinal mucosa so it leads to infiltration of inflammatory cells in intestinal mucosa [18,19]. Cell membrane permeability increases so that absorption is impaired and leads to a clinical symptom that is diarrhea [20].

This research was carried out to find out the potency of Kebar grass extract, which contains antioxidants to prevent free radicals in order to decrease histopathological damage of the mice's duodenum. Several indicators on the level of duodenum damage were observed: epithelial damage, congestion, edema, and infiltrasi neutrophil.

## MATERIALS AND METHODS

The experimental design in this research used a completely randomized design (CRD) using 42 pregnant mice divided into seven groups with six replications. This research was approved by the Research Ethics Commission of the Faculty of Veterinary Medicine, Universitas Airlangga (L.KE.107.06.2019).

### Materials

The experimental animals used in this research were female mice (*Mus musculus*) weighing 20-30 grams from the Center for Veterinaria Farm Surabaya Indonesia. Kebar grass (*Phytum petersianum* Klotzsch), CMC Na, Ethanol 70%, carbofuran (2,3- Dihydro-2,2-dimethyl-7-benzofuranol N-methylcarbamate 98%) from Aldrich Chemistry with Bell stain Registry number 1428746 Product of USA, feed pellets for mice, aquadest, vitamin C, drinking water, husks as the base of the cage, ether, formalin 10%, and alcohol were also used.

### Methods

A total of 42 pregnant mice were divided into seven groups: C, T1, T2, T3, T4, T5, and T6. Each group consisted of six replications. The mice were placed in plastic cages covered with wire and using husks as a base. The mice were fed on pellets and drank aquadest water *ad libitum* every day during the research.

### Kebar Grass Extract Preparation

The dried Kebar grass was first boiled in aquadest. 350 grams simplicial of mashed Kebar grass was macerated in a tube for 3x24 hours with 70% ethanol solvent with a ratio of 1:10. Next, it was filtered and the pulp was re-macerated twice with the same treatment. The macerated pulp was evaporated using a rotary evaporator at a temperature of 30-40°C to form a thick extract. The extract was put in a bottle and stored in the refrigerator.

### Dose Determination

Determination on the Kebar grass dose used was 0.135 mg/g BW/day [21] and the average body weight of the mice used was 25 grams, so the dose used was  $0.135 \text{ mg} \times 25 \text{ g} = 3.375 \text{ mg}/25\text{g/day}$ . The doses of Carbofuran administered using the LD<sub>50</sub> fraction for mice treated for 14 days were 1/4 LD<sub>50</sub> (0.0125mg/25g mouse/day) and 1/8 LD<sub>50</sub> (0.00625mg/25mg mouse/day) [6,22].

### Treatment

Carbofuran, Kebar grass extract, and vitamin C were administered to the mice from the first day of lactation to the 14<sup>th</sup> day orally using 1 ml tuberculin. The seven groups were divided into: C (control), T1 administered carbofuran 1/4 LD<sub>50</sub> (0.0125 mg/day), T2 administered carbofuran 1/8 LD<sub>50</sub> (0.00625 mg/day), T3 administered carbofuran 1/4 LD<sub>50</sub> (0.0125 mg/day) + Kebar grass extract 3.375 mg, T4 administered carbofuran 1/8 LD<sub>50</sub> (0.00625 mg/day) + Kebar grass extract 3.375 mg, T5 administered carbofuran 1/4 LD<sub>50</sub> (0.0125 mg/day) + vitamin C 5 mg, T6 administered carbofuran 1/8 LD<sub>50</sub> (0.00625 mg/day) + vitamin C 5 mg. On the 15<sup>th</sup> day, the mice were slaughtered to take their duodenum and histological preparation carried out using HE staining.

### Observation on Histological Preparation

Microscopic observation on the duodenum was carried out using a 400X magnification microscope by observing five different angles from each slide. The damage observed included epithelial damage, congestion, edema and neutrophil infiltration in duodenal epithelial cells of the mice according to [5] (Table 1).

Table 1. Scoring of intestinal damage.

Score	Epithelial damage	Congestion and edema	Neutrophil infiltration
0	Nothing	Nothing	Nothing
1	Damage on the tip of villi	Red blood cells are rarely found in venules	PMN cells rarely exist
2	Damage on half of villi	Red blood cells are found in half of venules	PMN cells exist outside blood vessels (there are approximately 5 cells in each blood vessel)
3	Total damage on villi	Red blood cells are found in more than half of venules	PMN cells up to dilamina propria and epithelium exist

Source: [5]



### Data analysis

The scoring results on the changes that occurred in duodenal preparations were then analyzed using the Kruskal Wallis test followed by the Mann Whitney test with the application of SPSS (Statistical Package for the Social Sciences).

### RESULTS

Damage to the villi is indicated by the tip of the villi having erosion and rupture (Table 2 & Figure 1). The results of statistical analysis showed that there was a significant difference ( $p < 0.05$ ) between group C with groups T1, T2, T3, T5, and T6. There was a significant difference ( $p < 0.05$ ) between group T1 with groups T3, T4, T5, and T6. There was a significant difference ( $p < 0.05$ ) between group T2 with groups T3, T4 and T6. There was a significant difference ( $p < 0.05$ ) between group T4 with groups T5 and T6 (Table 2).

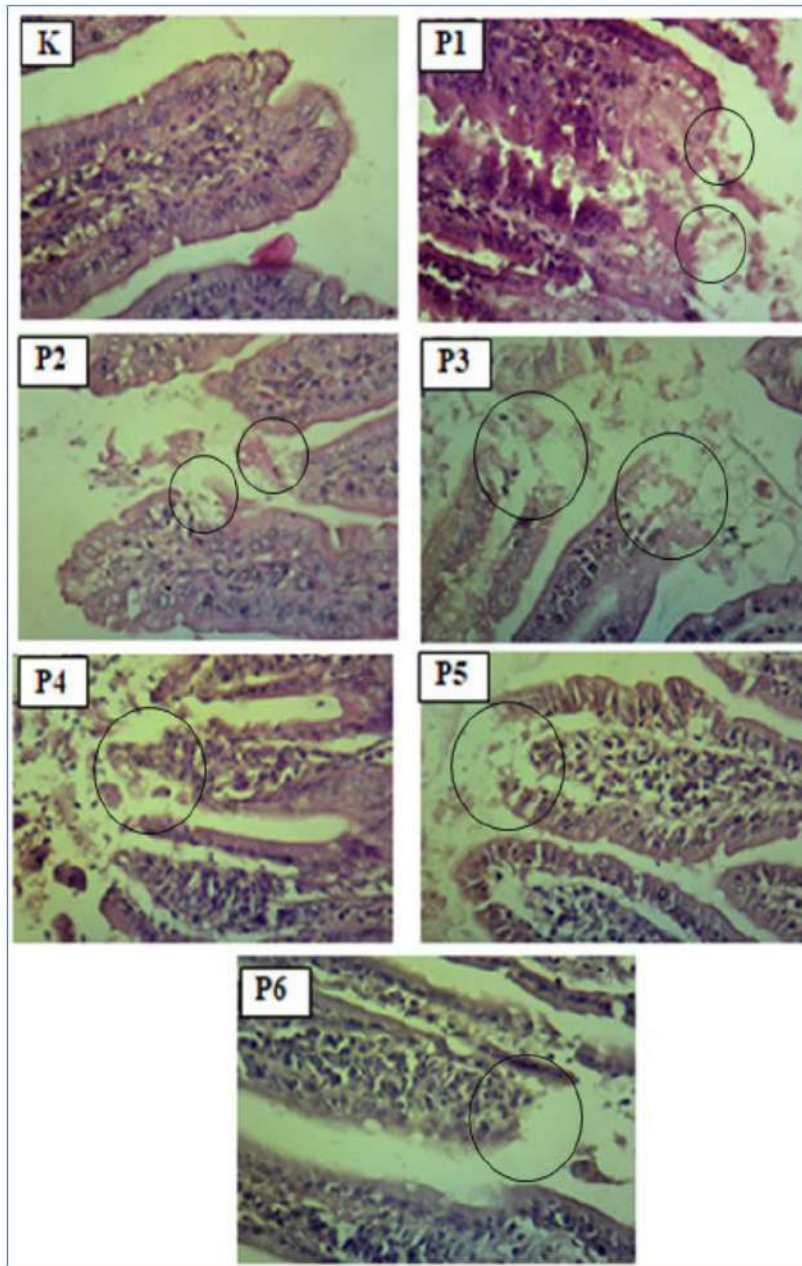
Congestion is known from the accumulation of erythrocytes in the lumen of the blood vessels, whereas edema is characterized by the presence of white spaces in the mucosal lining of the intestine (Table 2 & Figure 3). The results of statistical analysis showed that there was a significant difference ( $p < 0.05$ ) between group C with groups T1, T2, T3, T4, T5, and T6. There was a significant difference ( $p < 0.05$ ) between groups T1 and T2 with groups T3, T4 and T6. There was a significant difference ( $p < 0.05$ ) between groups T3 and T4 with group T5 (Table 2 & Figure 2).

Neutrophil infiltration is characterized by the presence of neutrophil cells around the intestinal mucosal tissue (Table 2 & Figure 3). The results of statistical analysis showed that there was a significant difference ( $p < 0.05$ ) between group C with groups T1, T2, T3, T4, T5, and T6. There was a significant difference ( $p < 0.05$ ) between group T1 and T2 with groups T3, T4, T5, and T6. There was a significant difference ( $p < 0.05$ ) between group T3 and T4 with groups T5 and T6.

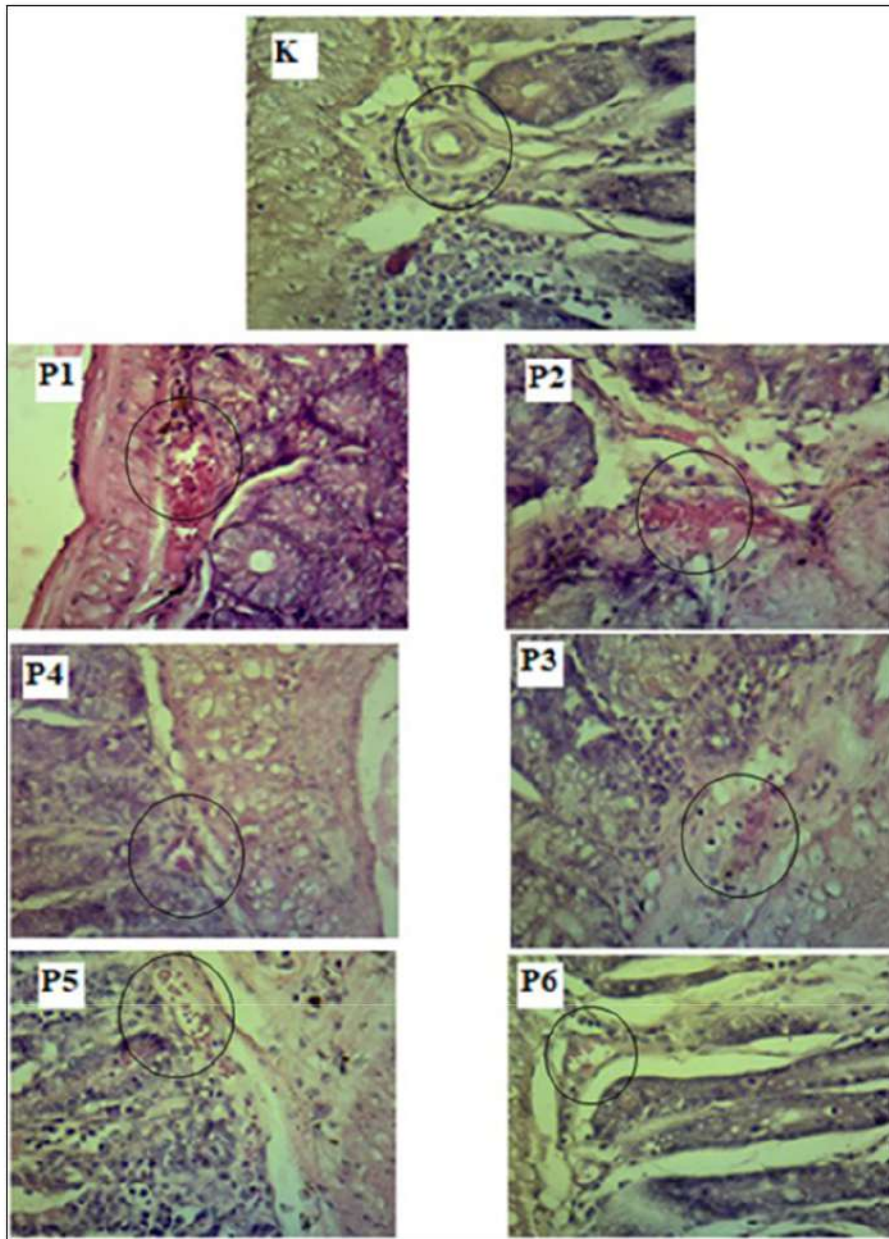
**Table 2.** Mean of villi damage, congestion edema, and neutrophil infiltration on the duodenum of mice (*Mus musculus*) at lactation period administered Kebar grass (*Biorhynchus petersianum* Klotzsch) extract and vitamin C after being exposed to carbofuran.

Treatment	Villi Damage (Mean $\pm$ SD)	Congestion Edema (Mean $\pm$ SD)	Neutrophil Infiltration (Mean $\pm$ SD)
C (control)	0.000 <sup>a</sup> $\pm$ 0.000	0.000 <sup>a</sup> $\pm$ 0.000	0.000 <sup>a</sup> $\pm$ 0.000
T1 (carbofuran 1/4 LD <sub>50</sub> )	2.000 <sup>b</sup> $\pm$ 0.200	2.467 <sup>d</sup> $\pm$ 0.416	2.933 <sup>d</sup> $\pm$ 0.116
T2 (carbofuran 1/8 LD <sub>50</sub> )	1.800 <sup>c</sup> $\pm$ 0.721	2.133 <sup>cd</sup> $\pm$ 0.116	2.800 <sup>d</sup> $\pm$ 0.200
T3 (carbofuran 1/4 LD <sub>50</sub> +Kebar grass extract 3.375 mg)	0.867 <sup>bc</sup> $\pm$ 0.116	1.067 <sup>b</sup> $\pm$ 0.231	1.400 <sup>b</sup> $\pm$ 0.529
T4 (carbofuran 1/8 LD <sub>50</sub> +Kebar grass extract 3.375 mg)	0.400 <sup>ab</sup> $\pm$ 0.200	0.933 <sup>b</sup> $\pm$ 0.611	1.333 <sup>b</sup> $\pm$ 0.306
T5 (carbofuran 1/4 LD <sub>50</sub> + vitamin C)	1.333 <sup>cd</sup> $\pm$ 0.231	1.867 <sup>cd</sup> $\pm$ 0.306	2.267 <sup>c</sup> $\pm$ 0.116
T6 (carbofuran 1/8 LD <sub>50</sub> + vitamin C)	1.200 <sup>c</sup> $\pm$ 0.734	1.600 <sup>bc</sup> $\pm$ 0.529	2.200 <sup>c</sup> $\pm$ 0.400

Note: Notation a, b, c, d and e (superscript) in the same column shows a significant difference ( $p < 0.05$ ).

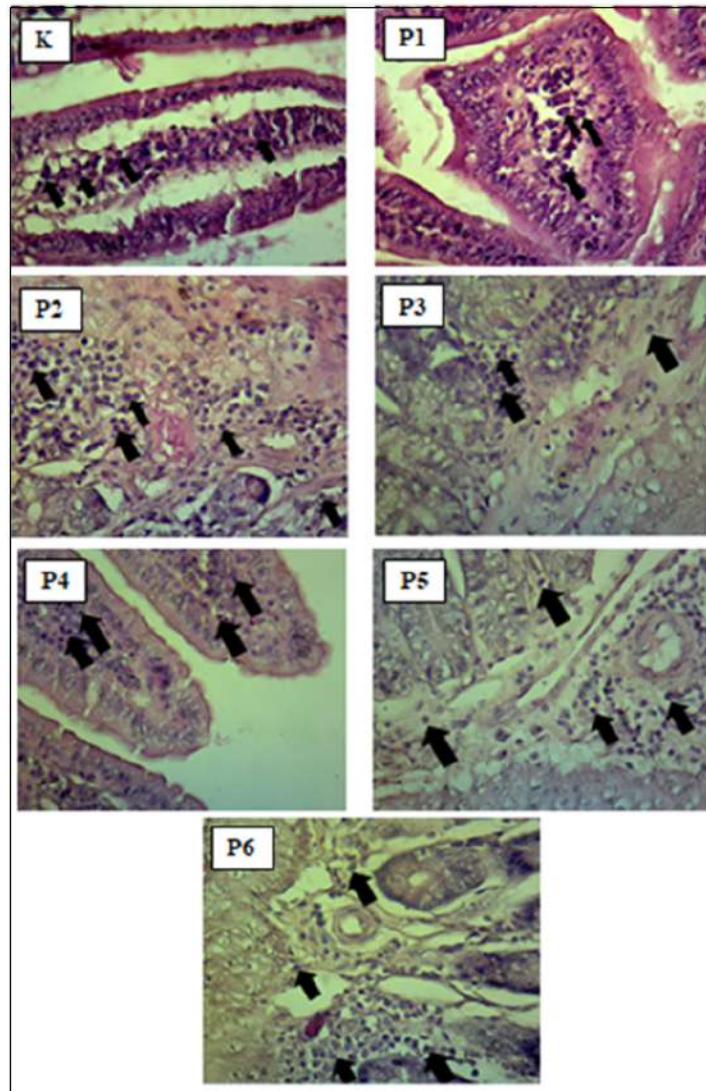


**Figure 1.** Villi damage in the duodenum of the mice (*Mus musculus*). Black circle shows villi damage of duodenum.



**Figure 2.** Congestion and edema in the duodenum of the mice (*Mus musculus*). Black circle shows congestion and edema of duodenum.





**Figure 3.** Neutrophil infiltration in the duodenum of the mice (*Mus musculus*). Arrow shows neutrophil infiltration of duodenum.

**DISCUSSION**

Carbofuran acts as a systemic poison with extreme toxicity to the stomach [23]. Carbofuran can enter the body through several ways that are absorption through the skin, inhalation and orally [24]. Oral exposure to carbofuran can irritate the digestive tract and can cause oxidative stress [25]. Carbofuran is metabolized by the body by cytochrome P<sub>450</sub> to 3-hydroxy

carbofuran, which can increase its toxic activity [26]. Oxidative stress is an imbalance between free radicals and antioxidants that is triggered by two common conditions, which are deficiency of antioxidants and excess production of free radicals [27]. Flavonoids in Kebar grass were non-enzymatic antioxidants that also protect cell membranes against oxidation from free radicals. Kebar grass also contains vitamin A and vitamin E. Vitamin A works by reacting with

free radicals and causing them to stabilize [28]. Vitamin E functions to protect poly-unsaturated fatty acids and other cell membrane components from free radical oxidation by breaking the lipid peroxide chain. Examination on Clinical chemistry and histopathology is one of the methods used to detect the specific effects of chemical exposure [29,30].

**Villi Damage:** The damage is thought to have occurred as a result of exposure to toxic substances [31]. Villi damage was not found at the control group (C). Carbofuran administration at T1 and T2 was able to increase the villi damage in proportion to the increase in the dose administered (Table 2). Inflammatory cell activity occurs when the body is exposed to toxic antigens such as carbofuran, so a non-specific immune response that functions against these antigens at the site of the damage. In addition, the imbalance due to oxidative stress can result in malfunctioned endothelial [32].

Groups T3 and T4 showed that villi damage in the mice's duodenum could be reduced (Table 2). The decrease in villi damage was due to vitamin A, vitamin E and flavonoids contained in Kebar grass, which was better at responding to the toxic substances of T1 and T2. Flavonoids function as primary antioxidants because they serve as free radical acceptors, so that they can inhibit free radical chain reactions in lipid oxidation, which can prevent membrane damage [33].

Groups T5 and T6 also showed a reduction in villi damage due to exposure to carbofuran (Table 2). The reduction in villi damage was better at responding to the toxic substances of T1 and T2. Vitamin C has a strong ability to reduce and acts as an antioxidant in reacting with hydroxyl [34]. Vitamin C is easily oxidized by atmospheric oxygen or by the enzyme ascorbate oxidase. However, vitamin C is a very powerful antioxidant and can prevent the oxidation process in food and in the body system [35].

#### Congestion and Edema

In the control group (C) congestion and edema were not found. T1 and T2 could increase congestion and edema in proportion to the increase in dose administered (Table 2). Congestion is a pathological reaction as a manifestation of inflammation due to injury. Congestion changes occur due to vascular hydrostatic pressure and osmotic pressure. Osmotic pressure is the pressure caused by proteins in plasma [36]. Edema is an indication of hydrostatic pressure or an error in imbalanced blood osmotic pressure, increased capillary permeability, lymph, and obstruction. This condition can be caused by toxic chemicals, viruses, bacteria and parasitic diseases [37].

Groups T3 and T4 showed that congestion and edema could be reduced (Table 2). The reduction in congestion and edema was due to vitamin A, vitamin E and flavonoids contained in Kebar grass which was better in responding to the toxic substances of T1 and T2. Antioxidant compounds work by inhibiting the oxidation rate of other molecules or neutralizing free radicals [38]. Groups T5 and T6 showed that vitamin C

was able to reduce congestion and edema due to exposure to carbofuran (Table 2). The reduction in congestion and edema was better at responding to the toxic substances of carbofuran at T2 to T1. Vitamin C can act as a co-antioxidant by regenerating  $\alpha$ -tocopherol radicals [39]. Another characteristic that makes vitamin C an ideal antioxidant is the low reactivity of ascorbyl radicals formed when ascorbic acid reacts with ROS. Ascorbyl radical is not a strong oxidizing agent and reducing agent, so it reacts slowly with oxygen. This cycle produces a strong defense system against free radicals or other oxidant compounds [40].

#### Neutrophil Infiltration

Neutrophils are one type of white blood cell markers of inflammation or infection. Neutrophils will work when there is a signal from cytokine hormones that indicate the location of inflammation in the body, resulting in an increase in the number of neutrophils in the peripheral blood [41]. In the control group (C) there was no increase in neutrophil infiltration. T1 and T2 could increase neutrophil infiltration in proportion to the increase in dose administered (Table 2). T3 and T4 groups showed that the amount of neutrophil infiltration in the duodenum of mice could be reduced (Table 2). The decrease in neutrophil infiltration was due to vitamin A, vitamin E and flavonoids contained in Kebar grass, which was better in responding to the toxic substance of T1 and T2. Antioxidants in flavonoids can reduce inhibition of nitric oxide, prevents leucocyte from adhering to blood vessel walls and interacting with other enzyme systems such as COX-1 and COX-2 [42]. These stimuli can be cytokines, bacterial lipopolysaccharides, inflammation or other pathological conditions [43]. Cyclooxygenase-1 (COX-1) plays a role in normal physiological functions such as mucus secretion to protect the digestive mucosa [44]. Groups T5 and T6 showed the potency of vitamin C in reducing the amount of neutrophil infiltration due to exposure to carbofuran (Table 2). The reduction in the number of neutrophilic infiltrations was better at responding to the toxic substances of T2 to T1.

The results of this study indicate that administration of Kebar grass extract as an antioxidant is better at reducing the level of villi damage, congestion, edema, and neutrophil infiltration in duodenum of the mice at lactation period compared to vitamin C.

#### CONCLUSION

Carbofuran administration can cause an increase in the amount of villi damage, congestion, edema, and neutrophil infiltration in proportion with the increase in dose administered. The administration of Kebar grass (*Biophytum petersianum* Klotzch) extract has a better effect on reducing the amount of villi damage, congestion, edema, and neutrophil infiltration compared to vitamin C ( $p < 0.05$ ). Based on the results of the research, it shows that Kebar grass extract is more effective when carbofuran is administered at a dose of 0.00625 mg compared to a dose of 0.0125 mg.



5 therefore, it is necessary to conduct further research to increase the dose of Kebar grass extract.

## 2 ACKNOWLEDGEMENT

The authors express sincere thanks to the Ministry of Research, Technology and Higher Education of the Republic of Indonesia for funding the research, and the Dean of Faculty of Veterinary Medicine Universitas Airlangga for providing all necessary facilities and funds in conducting this research work.

## 2 ACKNOWLEDGEMENT(S)/FUNDING

The Ministry of Research, Technology and Higher Education of the Republic of Indonesia and the Dean of Faculty of Veterinary Medicine Universitas Airlangga.

## 23 CONFLICT OF INTEREST

The authors declare no conflict of interest.

## REFERENCES

1. Wispriyono B, Yanuar A, Fitria L (2013) The safety level of consumption of carbamate residues in fruits and vegetables according to post-column analysis of high-performance liquid chromatography. *J Kesehatan Masyarakat Nasional* 7(7): 317-332.
2. Indraningsih (2008) The Effect of Using Carbamate Insecticides on the Health of Livestock and Their Products. *Wartazoa* 18(2): 101-114.
3. Yang B, Weiyang Z, Zhenzhen H, Fangming L, Ling Z, et al. (2014) Involvement of oxidative stress and inflammation in liver injury caused by perfluorooctanoic acid exposure in Mice. *BioMed Res Int* 2014: 409837.
4. Arimbi, Ajik A, Darsono R, Plumeriastuti H, Thomas VW, et al. (2015) *Veterinary General Pathology Textbook*, 2<sup>nd</sup> edn. Surabaya. Airlangga University. pp: 7-33.
5. Charalabos P, Ignazio C, Lamont JT, Jaffer A, Keane JC, et al. (1994) CP-96,345, a substance P antagonist, inhibits rat intestinal responses to *Clostridium difficile* toxin A but not cholera toxin. *Proc Natl Acad Sci U S A* 9: 947-951.
6. Luqman EM, Widjiati W, Yustinasari LR (2018) Brain Cells Death on Infant Mice (*Mus musculus*) Caused by Carbofuran Exposure During the Lactation Period. *Kafkas Univ Vet Fak Derg* 24(6): 845-852.
7. Luqman EM, Sudiana IK, Darmanto W, Achmad AB (2019) Mouse (*Mus musculus*) embryonic cerebral cortex cell death caused by carbofuran insecticide exposure. *J Vet Res* 63(3): 413-421.
8. Goodyear-Bruch C, Pierce JD (2002) Oxidative Stress in Critically Ill Patients. *Am J Crit Care* 11(6): 543-551.
9. Sembiring B, Darwati I (2014) Identification of the chemical components of accession of Kebar grass (*Biophytum petersianum*) from Papua and Java. *Bulletin Penelitian Tanaman Rempah dan Obat* 25(1): 37-44.
10. Sayuti K, Rina Y (2015) *Natural and Synthetic Antioxidants*. Andalas University Press: Padang.
11. Cadenas E, Packer L (2001) *Handbook of Antioxidants*. New York: CRC Press, pp: 8.
12. Mokgope LB (2006) *Cowpea Seed Coats and Their Extracts: Phenolic Composition and Use as Antioxidants in Sunflower Oil*. South Africa: Department of Food Science. University of Pretoria.
13. Lichtenberger LM, Tier JS (1979) Changes in gastrin levels, food intake, and duodenal mucosal growth during lactation. *Am J Physiol* 237(1): E98-E105.
14. Mansour SA, Mossa AH (2010) Adverse Effect of Lactation Exposure to Chlorpyrifos in Suckling Rats. *Hum Exp Toxicol* 29(2): 77-92.
15. Lin JH, Chiba M, Baillie TA (1999) Is the Role of the Small Intestine in First-pass Metabolism Over emphasized? *Pharmacol Rev* 51(2): 135-158.
16. Chin AM, David RH, Megan A, Jason RS (2017) Morphogenesis and maturation of embryonic and postnatal intestine. *Semin Cell Dev Biol* 66: 81-93.
17. Yanti EZ, Hermadi HA, Rejeki PS, Dhamayanti Y, Widjiati, et al. (2020). The Increasing Inflammatory Cells, Degeneration and Duodenal Necrosis on Infant Mice from Carbofuran Exposed Mothers. *J Int Dent Med Res* 13(2): 785-790.
18. Vliet AV, Aalt B (1992) Role of reactive oxygen species in intestinal disease. *Free Radic. Biol. Med* 12: 499-513.
19. Shirpoor A, Hanieh B, Mohamadhasan KA, Behrouz I, Haleh B (2016) Protective effect of vitamin E against ethanol-induced small intestine damage in rats. *Biomed Pharmacother* 78: 150-155.
20. Purnama MTE, Plumeriastuti H, Widjaja NMR (2013) The Effect of Borax to Duodenal Histopathological Changes in Rats (*Rattus norvegicus*). [Thesis]. Fakultas Kedokteran Hewan. Universitas Airlangga.
21. Labib MF, Widjiati, Hemawati T, Luqman EM, Kurnijasanti R, et al. (2020) Kebar grass (*Biophytum petersianum* K.) The effect in maintaining mice (*Mus musculus*) sperm quality exposed to dioxin. *Int J Res Pharm Sci* 11(3): 4977-4981.
22. Luqman EM, Hestianah EP, Tehupuring BC, Yustinasari LR (2020) Interaction between autophagy, apoptosis and necrosis of infant mice (*Mus musculus*) brain cells from its carbofuran exposed mothers during lactation periods. *Acta Vet Bmo* 89(2): 195-200.

23. Chairul, Sofnie M (2013) Testing of Herbicide 2,4-D Release Controlled Formulation Against Rice Weeds. Dalam: Semiloka Nasional Himpunan Kimia Indonesia. Jakarta.
24. Pamungkas OS (2016) The dangers of pesticide exposure to human health. Bioedukasi 14(1): 27-31.
25. Gupta VK, Pathak A, Siddiqi NJ, Sharma B (2016) Carbofuran modulating functions of acetylcholinesterase from rat brain *in vitro*. J Adv Biol 2016: 1-7.
26. Gupta RC (1994) Carbofuran toxicity. J Toxicol Environ Health 43: 383-418.
27. Pavlovic V, Cekic S, Rankovic G, Stoilkovic N (2005) Antioxidant and Pro-oxidant Effect of Ascorbic Acid. Acta Med Medianae 44(1): 65-69.
28. Sayuti K, Rina Y (2015) Natural and Synthetic Antioxidants. Andalas University Press: Padang.
29. Travlos GS, Morris RW, Elwell MR, Duke A, Rosenblum S, et al. (1996) Frequency and relationships of clinical chemistry and liver and kidney histopathology findings in 13-week toxicity studies in rats. Toxicology 107: 17-19.
30. Crissman JW, Goodman DG, Hildebrandt PK, Maronpot RR, Prater DA, et al. (2004) Best Practices Guideline: Toxicologic Histopathology. J Toxicol Pathol 32(1): 126-131.
31. Asri A (2015) Histopathological Overview of Dui-Dui Fish Intestines (*Dermogenys megarrhamphus*) in Matano Lake, East Luwu, South Sulawesi Contaminated with Heavy Metal Nickel (Ni) and Iron (Fe). [Thesis]. Fakultas Kedokteran Hewan Fakultas Kedokteran Universitas Hasanuddin. Makassar.
32. Wahyuni OP, Padaga CM, Wuragil DK (2012) Duodenal Histopathology and Expression of Inducible Nitric Oxide Synthase (iNOS) in Rats (*Rattus norvegicus*) Hypercholesterolemia with Goat Milk Yogurt Therapy. [Thesis]. Program Studi Kedokteran Hewan Universitas Brawijaya.
33. Hudson BJB (1990) Food Antioxidant. Elsevier Applied Science. London.
34. Sunita A (2009) Basic Principles of Nutrition. Jakarta: PT Gramedia Pustaka Utama.
35. Tejasari (2005) Food Nutritional Value. Yogyakarta: Graha Ilmu.
36. Arimbi, Azmijah A, Darsono R, Plumeriastuti H, Widiyatno TV, et al. (2013) Textbook of Veterinary Pathology: Cell and Tissue Response to Hemodynamic Pathways and Disorders. Fakultas Kedokteran Hewan Universitas Airlangga. Surabaya. pp: 10-60.
37. Hibiya T, Fumio T (1995) An Atlas of Fish Histology: Normal and Pathological Features. 2<sup>nd</sup> edn. Japan. Kodansha Ltd.
38. Fajriah S, Darmawan A, Sundowo A, Artanti (2007) Isolation of Antioxidant Compounds from Ethyl Acetate Extract of Benalu Leaf (*Dendrophthoe petandra* L. Miq) Growing in Lobby Hosts. J Kimia Indonesia 2(1): 17-20.
39. Hendra BW, Junaidi L (2011) Mechanism of Action and Function in the Human Body. J Agro-Based Indust 28(2): 44-55.
40. Packer L, Traber MG, Kraemer K, Frei (2002). The Antioxidant Vitamins C and E: Vitamins C and E for Health. J Am Oil Chem Soc.
41. Hoffbrand AV, Pettit JE, Moss PAH (2005). Capita selecta hematology; 4<sup>th</sup> edn. Jakarta: Kedokteran EGC.
42. Okasha MAM, Abubakar MS, Bako IG (2008) Study of Effect of Aqueous Hibiscus sabdariffa Linn Seed Extract on Serum Prolactin Level of Lactating Female Albino Rats. Euro J Sci Res 22(4): 575-583.
43. Gilroy DW, Colville-Nash PR, Willis D, Chivers J (1999). Inducible cyclooxygenase may have anti-inflammatory properties, London: Department of Experimental Pathology, St. Bartholomew's & Royal London School of Medicine and Dentistry.
44. Robbins SL, Vnay K, Ramzi C (2015). Robbins and Cotran Pathologic Basis of Disease. 8edth ed. Philadelphia: Elsevier Saunders.

# Potency of Kebar Grass (*Biophytum petersianum*) Extract to Histopathological of Mice (*Mus musculus*) Duodenum at Lactation Period Exposed to Carbofuran

## ORIGINALITY REPORT

18%

SIMILARITY INDEX

16%

INTERNET SOURCES

12%

PUBLICATIONS

3%

STUDENT PAPERS

## PRIMARY SOURCES

1	<a href="http://www.scielo.br">www.scielo.br</a> Internet Source	3%
2	<a href="http://vetdergikafkas.org">vetdergikafkas.org</a> Internet Source	2%
3	<a href="http://repo.lib.tokushima-u.ac.jp">repo.lib.tokushima-u.ac.jp</a> Internet Source	1%
4	<a href="http://www.longdom.org">www.longdom.org</a> Internet Source	1%
5	<a href="http://www.atlantis-press.com">www.atlantis-press.com</a> Internet Source	1%
6	<a href="http://www.jurnal.unsyiah.ac.id">www.jurnal.unsyiah.ac.id</a> Internet Source	1%
7	Jin Young Lee. "Effects of transcription factor activator protein-1 on interleukin-8 expression and enteritis in response to <i>Clostridium difficile</i> toxin A", <i>Journal of Molecular Medicine</i> , 12/2007 Publication	1%



8	<a href="http://f1000research.com">f1000research.com</a> Internet Source	1 %
9	<a href="http://kesehatanti.blogspot.com">kesehatanti.blogspot.com</a> Internet Source	1 %
10	<a href="http://jabonline.a2hosted.com">jabonline.a2hosted.com</a> Internet Source	1 %
11	<a href="http://lppm-unissula.com">lppm-unissula.com</a> Internet Source	<1 %
12	<a href="http://www.e3s-conferences.org">www.e3s-conferences.org</a> Internet Source	<1 %
13	<a href="http://www.frontiersin.org">www.frontiersin.org</a> Internet Source	<1 %
14	<a href="http://repository.unair.ac.id">repository.unair.ac.id</a> Internet Source	<1 %
15	<a href="http://www.hindawi.com">www.hindawi.com</a> Internet Source	<1 %
16	<a href="http://www.rspublication.com">www.rspublication.com</a> Internet Source	<1 %
17	Raquel Aparecida Moreira, Adrislaine da Silva Mansano, Odete Rocha. "The toxicity of carbofuran to the freshwater rotifer, <i>Philodina roseola</i> ", <i>Ecotoxicology</i> , 2015 Publication	<1 %
18	<a href="http://pharmacia.pensoft.net">pharmacia.pensoft.net</a> Internet Source	<1 %

19 "Optimization of Estrogenic Activities of Kebar Grassextract (Biophytum Petersianum) on White Female Mice (Mus musculus)", International Journal of Recent Technology and Engineering, 2019  
Publication <1 %

---

20 José Luis Silencio Barrita, Sara Montaña Benavides, Santiago Sánchez. "Chapter 6 Antioxidants and Natural Compounds in Mexican Foods", IntechOpen, 2015  
Publication <1 %

---

21 [www.myfoodresearch.com](http://www.myfoodresearch.com)  
Internet Source <1 %

---

22 Jos Luis Silencio Barrita, Mara del Socorro Santiago Snchez. "Chapter 17 Antioxidant Role of Ascorbic Acid and His Protective Effects on Chronic Diseases", IntechOpen, 2013  
Publication <1 %

---

23 Submitted to Universitas Airlangga  
Student Paper <1 %

---

24 [oamjms.eu](http://oamjms.eu)  
Internet Source <1 %

---

25 Achmad Ilham Fanany Al Isyrofie, Muhammad Kashif, Angger Krisna Aji, Nur Aidatuzzahro et al. "Odor clustering using a gas sensor array system of chicken meat based on

temperature variations and storage time",  
Sensing and Bio-Sensing Research, 2022

Publication

---

26

Yanyan Zhai, Erik Damgaard Christensen.  
"CFD investigation of flow in scour protection  
around a mono-pile with the volume-  
averaged k- $\omega$  model", Journal of Offshore  
Mechanics and Arctic Engineering, 2022

Publication

---

27

[acikbilim.yok.gov.tr](http://acikbilim.yok.gov.tr)

Internet Source

---

28

[rrpharmacology.ru](http://rrpharmacology.ru)

Internet Source

---

29

Hongcai Zhang, Jooyeoun Jung, Yanyun Zhao.  
"Preparation, characterization and evaluation  
of antibacterial activity of catechins and  
catechins–Zn complex loaded  $\beta$ -chitosan  
nanoparticles of different particle sizes",  
Carbohydrate Polymers, 2016

Publication

---

30

[informaticsjournals.com](http://informaticsjournals.com)

Internet Source

---

31

Mantyh, C.. "Substance P activation of enteric  
neurons in response to intraluminal  
*Clostridium difficile* toxin A in the rat ileum",  
Gastroenterology, 199611

Publication

---

<1 %

<1 %

<1 %

<1 %

<1 %

<1 %



32

Blanca Grases-Pintó, Mar Abril-Gil, Maria J. Rodríguez-Lagunas, Margarida Castell, Francisco J. Pérez-Cano, Àngels Franch. "Leptin and adiponectin supplementation modifies mesenteric lymph node lymphocyte composition and functionality in suckling rats", British Journal of Nutrition, 2018

Publication

<1 %

33

[hdl.handle.net](https://hdl.handle.net)

Internet Source

<1 %

Exclude quotes Off

Exclude matches Off

Exclude bibliography On

# Potency of Kebar Grass (*Biophytum petersianum*) Extract to Histopathological of Mice (*Mus musculus*) Duodenum at Lactation Period Exposed to Carbofuran

---

GRADEMARK REPORT

---

FINAL GRADE

**/0**

GENERAL COMMENTS

**Instructor**

---

PAGE 1

---

PAGE 2

---

PAGE 3

---

PAGE 4

---

PAGE 5

---

PAGE 6

---

PAGE 7

---

PAGE 8

---

PAGE 9

---