

Acknowledgment of manuscript submission (ID: IJSCIA0296)

External

Inbox



Editor IJSCIA <ijsciaeditor@gmail.com>

Thu, Mar 24, 2022,
12:51 PM

to me

Dear author,

Thank you for sending us your manuscript entitled: "**The Potential of Kebar Grass (Biophytum Petersianum Klotzsch) on Mice (Mus musculus) During Lactation Period on Liver Histopathological were Exposed by Carbofuran**".

We endeavor to let you know its status in the next few days (typically 1-4 days).

Best regards

Editor-in-Chief
International Journal of Scientific Advances (IJSCIA)



Editor IJSCIA <ijsciaeditor@gmail.com>

Sun, Mar 27, 2022,
9:11 AM

to me

Dear author,

Thank you for giving us the opportunity to consider your work. Reviewers are recommending that your manuscript should be accepted. The following are their comments:

Reviewer #1: The study on the functional effects of kebar grass extract in a mice study is interesting due to its rich constituents. I recommend this paper.

Reviewer #2: The authors have greatly contributed to the research on the reduction of carbofuran effects in individuals through this animal trial. This is forthcoming and commendable.

Editorial: The title should be clearer. As an example, "The Potential of Kebar Grass (*Biophytum petersianum* Klotzsch) on Liver Histopathology of Lactating Mice (*Mus musculus*) Exposed to Carbofuran".

Thank you for your fine contribution.

You now have the following actions to perform:

1. Should you need to make final checks on your manuscript, do so and revert back to us for processing.
2. Pay the article processing fee using the invoice link or code herewith attached: <https://www.paypal.com/invoice/p/#YB4X5SAS7TP6SZHL>

Do not forget to immediately send the proof to us (ijsciaeditor@gmail.com).

Your article would be published online in the current issue once this has been done.

Warm regards

epy muhammad luqman <epy-m-l@fkh.unair.ac.id>

Sun, Mar 27, 2022,
3:47 PM

to Editor

Editor-in-Chief
International Journal of Scientific Advances (IJSCIA)

I have paid the article processing fee (attached) for manuscript submission (ID: IJSCIA0296) entitled "The Potential of Kebar Grass (*Biophytum Petersianum* Klotzsch) on Mice (*Mus musculus*) During Lactation Period on Liver Histopathological were Exposed by Carbofuran".

There is no change in the contents of my manuscript, I agree with the change in title on the advice of the editor, namely: The Potential of Kebar Grass (*Biophytum petersianum* Klotzsch) on The Liver Histopathology of Lactating Mice (*Mus musculus*) Exposed to Carbofuran".

Thank You

--

Dr. Epy Muhammad Luqman
Badan Kerjasama dan Manajemen Pengembangan
Universitas Airlangga
mobile : +628123090594

Your article is now online!

External

Inbox



Editor IJSCIA <ijsciaeditor@gmail.com>

Mon, Mar 28, 2022,
12:57 PM

to me

Dear author,

Your article is now published online!

You may find the published article on the journal's website Or via this link: [The Potential of Kebar Grass \(*Biophytum petersianum* Klotzsch\) on the Liver Histopathology of Lactating Mice \(*Mus musculus*\) Exposed to Carbofuran](#)

The DOI will become active shortly within the next 30 days.

Authors are encouraged to share their articles in the public domain.

Thank you and warm regards

Editor-in-Chief

International Journal of Scientific Advances (IJSCIA)

The Potential of Kebar Grass (*Biophytum petersianum* Klotzsch) on the Liver Histopathology of Lactating Mice (*Mus musculus*) Exposed to Carbofuran

Muhammad Andika Aulia Rakhman¹, Sri Hidanah¹, Widjiati¹,
Thomas Valentinus Widiyatno¹, Ratna Damayanti¹,
Viski Fitri Hendrawan², Epy Muhammad Luqman^{1*}

¹Department of Veterinary Science Faculty of Veterinary Medicine Universitas Airlangga
Kampus C Unair Jalan Mulyorejo, Surabaya-60115 Indonesia

²Department of Animal Reproduction Faculty of Veterinary Medicine,
Universitas Brawijaya, Malang 65151, Indonesia

*Corresponding author details: Epy Muhammad Luqman; epy-m-l@fkh.unair.ac.id

ABSTRACT

This study aims to determine the potential of Kebar grass extract in reducing the impact of liver damage in mice (*Mus musculus*) during lactation exposed to carbofuran. The 42 lactation mice (*Mus musculus*) used in the study were divided into seven groups, each group consisting of six mice. Carbofuran, chewed grass, and vitamin C are exposed orally on days 1 to 14 after birth. This group consisted of C (aquadest control), P1 (carbofuran 0.0125 mg/day), P2 (carbofuran 0.00625 mg/day), P3 (carbofuran 0.0125 mg/day+extract of kebar grass 3.375 mg 0.2 ml), P4 (carbofuran 0.00625 mg/day+extract of kebar grass 3.375 mg 0.2 ml), P5 (carbofuran 0.0125 mg/day+vitamin C 5 mg 0.2 cc), and P6 (carbofuran 0.00625 mg/day+vitamin C 5 mg 0.2 cc). On the 15th day after birth, mice were sacrificed and their liver organs taken for microscopic examination with hematoxylin-eosin staining. The results of this study indicate that the liver histopathology of mice suffered damage characterized by an increase in the number of inflammation cell, degeneration, and necrosis in line with the carbofuran dose given during the lactation period (P1 and P2). The administration of kebar grass extract (P3 and P4) is more effective than vitamin C (P5 and P6) in reducing the amount of inflammation cell, degeneration, and hepatocyte necrosis caused by carbofuran administration in lactation mice. This can be seen in the amount of liver damage in group P3 and P4 mice less than the amount of liver damage in group P5 and P6.

Keywords: carbofuran; kebar grass; lactation; liver; pesticide stress

INTRODUCTION

Pesticides are widely used to control plant-disturbing organisms such as cabbage, spinach and carrots ¹. Excessive exposure to insecticides can result in disturbed soil fertility. In addition, agricultural product residues will have an impact on human and animal health ². Carbofuran is a type of carbamate insecticide that often causes poisoning in non-target organisms such as plants, animals and humans ³. Excessive use of carbofuran can result in a reduction in the number of individuals, barriers to metabolic activity, behavioral barriers, and reproduction ⁴. The target of organ damage due to the effects of carbofuran are the brain, liver, muscles and heart ⁵. The liver is the largest glandular organ that has a role in detoxifying the metabolic waste materials of food, drugs, and toxic substances that enter the body ⁶. Toxic substances carried in the bloodstream can cause damage to hepatocytes around the central vein which will first experience necrosis. The formation of reactive oxygen species (ROS) and lipid peroxidation due to ROS can cause hepatocyte death ⁷.

Carbofuran given orally has been shown to stimulate ROS which causes oxidative stress in the body if the doses are

given too much ⁸. This imbalance between prooxidants and antioxidants is called oxidative stress. This usually occurs due to lack of antioxidants and excess production of free radicals ⁹. Hepatocytes are the main tissue that is targeted for an increase in the concentration of free radicals because the liver is the site of the metabolic process of xenobiotic compounds that will induce hepatocyte death. Carbofuran causes ROS, causing degeneration and necrosis damage and inflammation cell in the liver ¹⁰.

Lactation period is the period that occurs when a mother has given birth to a child. Giving carbofuran to the parent of the lactation period is considered to show more significant results compared to the parent who is not in the lactation period. This is due to the parent in the lactation period more susceptible to certain chemical compounds than the parent not in the lactation period ¹¹.

Kebar grass (*Biophytum petersianum* Klotzsch) is a plant belonging to the family group Oxalidaceae found in Kebar District, West Papua. Kebar grass usually grows naturally and is spread almost throughout the Kebar District ¹². Kebar grass contains flavonoids, retinol, and tocopherol.

Kebar grass contains flavonoids which have the function of primary antioxidants because they are free radical acceptors so they can inhibit free radical chain reactions in lipid oxidation that can prevent membrane damage. Polyphenol compounds such as flavonoids work by converting H_2O_2 to H_2O and O_2 ¹³. The content of retinol or vitamin A in kebar grass functions as an antioxidant. Beta carotene works by reacting with free radicals and causing free radicals to become stable. Beta carotene or retinol in collaboration with vitamin E (tocopherol) contained in kebar grass and vitamin C (ascorbic acid). Vitamin C which is transformed into radicals is stabilized by the natural antioxidant glutathione¹⁴. The content of vitamin E in the resistant grass prevents free radicals by giving H atoms from hydroxyl groups to peroxy lipid radicals. Radicals formed from alpha-tocopherol will be stabilized through electron delocalization in the aromatic ring¹⁵.

To investigate to the potential of kebar grass extract (*Biophytum petersianum* Klotzsch) in reducing the impact of damage to the liver of mice (*Mus musculus*) during lactation exposed to carbofuran. The data obtained is expected to provide additional reference results and proof about the potential of kebar grass extract in reducing liver damage in mice during lactation exposed to carbofuran orally. In addition, the data obtained can also be used in providing information to the public about the dangers posed by excessive use of carbofuran, especially in the parent during the lactation period.

METHODS

The research procedure was conducted by testing the code of ethics of experimental animals with the number 1.KE.107.06.2019 at the Faculty of Veterinary Medicine, Universitas Airlangga. This study used a Completely Randomized Design with seven treatment groups and six repetitions. The experimental animal used was lactation mice (*Mus musculus*). This research was conducted at the Animal Cage in the Faculty of Veterinary Medicine, Airlangga University. Mice are placed in plastic cages covered with wire and given husks as a base. Mice were fed pellets and drinking distilled water ad libitum every day during the study. Materials used in this study were mice (*Mus musculus*) lactation period, kebar grass (*Biophytum petersianum* Klotzsch), CMC Na, Ethanol 70%, carbofuran (2,3-Dihydro-2,2-dimethyl-7-benzofuranol N-methylcarbamate 98%) from Aldrich Chemistry with Bellstain Registry number 1428746, Product of USA. Pellet feed for mice, aquadest as a carbofuran solvent, vitamin C, drinking water, husk as a base of the cage, ether, 10% formalin, alcohol. The tools used in this study were plastic cages and wire mesh for experimental animal cages, drinking containers, sonde needles, test tubes, and 3 ml syringe. Equipment used for the termination of mice is anesthetic jars, surgical scissors, scalpels, tweezers, and small pot bottles. Equipment for making liver histology preparations include glass objects, glass cover, automatic tissue processor, water bath, hot plate, microtome, and blade. Liver histology examination using an Olympus® CX-41 camera and microscope.

The sample used in this study was the liver of the lactation period which was exposed to carbofuran. The number of samples used was 42 mice during lactation period. The mice used were divided into seven groups namely C, P1, P2, P3, P4, P5, and P6. Each group consisted of six replications. Mice were given carbofuran, kebar grass, vitamin C orally using 1 ml tuberculin on the first day after giving birth until the 14th day. C: aquadest control group (0.5 ml/head/day), P1: carbofuran 1/4 LD₅₀ (0.0125 mg/day), P2: carbofuran 1/8 LD₅₀ (0.00625 mg/day), P3: carbofuran 1/4 LD₅₀ (0.0125 mg/day) + extract of kebar grass 3.375 mg in 0.2 ml, P4: carbofuran 1/8 LD₅₀ (0.00625 mg/day) + extract of kebar grass 3.375 mg in 0.2 ml, P5: 1/4 LD₅₀ carbofuran (0.0125 mg/day) + vitamin C 5 mg in 0.2 cc, and P6: carbofuran 1/8 LD₅₀ (0.00625 mg/day) + vitamin C 5 mg in 0.2 cc. All groups were given treatment for 14 days. On the 15th day, mice were sacrificed for liver organ harvesting and histopathological preparation.

Mice are sacrificed by euthanasia. Mice were put into a jar that was given ether. Furthermore, abdominal cavity surgery is performed to remove the liver. Organs are placed into small pots containing 10% formalin buffer solution, then making histopathological preparations using HE staining. Each mouse was made one liver preparation and each preparation was observed in five microscopic fields of view, namely in the four corners and the middle part of the preparation with a X 400 magnification.

Data analysis

Histopathological preparations of the liver were scored with degrees of liver damage with a score range of 0-5, depending on the extent of change and the degree of liver damage. The method used in granting this score uses the Knodell score method¹⁶. The results of scoring changes that occur in liver preparations are then analyzed using the Kruskal Wallis test followed by the Mann Whitney test with the *Statistical Product and Service Solution* (SPSS) application.

RESULTS AND DISCUSSION

Microscopic observation of the liver histology preparations of mice (*Mus musculus*) lactation exposed to carbofuran then given kebar grass which is then compared with lactation during mice given carbofuran and ascorbic acid or vitamin C. The results of scoring on mice's liver tissue showed degeneration, necrosis, and inflammation cell.

Degeneration

Degeneration observations were carried out microscopically using histopathological preparations with HE staining from the liver of mice (*Mus musculus*) during lactation. The observation was carried out using a microscope with a X 400 magnification. The presence of degeneration is marked by the size of the cytoplasm of cells that are enlarged and cytoplasm that is cloudy because there are vacuoles (Table 2).

TABLE 1: Liver Damage Scoring

Rate of Change	Score	Information
Inflammation Cells	0	No inflammation cell
	1	Inflammation cells occurs < 25% of all fields view
	3	Inflammation cells occurs > 25%-50% of all fields view
	5	Inflammation of inflammatory cells occurs > 50% of all fields view
Degeneration	0	No degeneration cell
	1	Degeneration cells occurs < 25% of all fields view
	3	Degeneration cells occurs > 25% -50% of all field of view
	5	Degeneration cells occurs > 50% of all fields of view
Necrosis	0	No necrosis cells
	1	Necrosis cells occurs < 25% of all fields view
	3	Necrosis cells occurs > 25% -50% of all fields view
	5	Necrosis cells occurs > 50% of all fields view

Source ¹⁷

The results of the statistical analysis in Table 2 show that there are significant differences ($p < 0.05$) between the C group and the P1, P2, P3, P4, P5, and P6 groups. There were significant differences ($p < 0.05$) between groups P1 and groups P2, P3, P4, P5, and P6.

There were significant differences ($p < 0.05$) between groups P2 with groups P3, P4, P5, and P6. There were significant differences ($p < 0.05$) between groups P3 and groups P4, P5, and P6. There was a significant difference ($p < 0.05$) between groups P4 and groups P5 and P6.

TABLE 2: The scoring results of liver damage in mice exposed to lactation carbofuran

Treatment	Degeneration Score (Mean±SD)	Necrosis Score (Mean±SD)	Inflammatory Cell Score (Mean±SD)
C	0.00±0.00 ^a	0.00±0.00 ^a	0.00±0.00 ^a
P1	4.73±0.23 ^f	4.87±0.23 ^f	4.20±0.00 ^f
P2	3.93±0.23 ^e	3.93±0.23 ^e	3.80±0.00 ^e
P3	1.27±0.23 ^c	2.06±0.46 ^c	0.80±0.20 ^c
P4	0.80±0.00 ^b	1.27±0.12 ^b	0.40±0.00 ^b
P5	2.73±0.61 ^d	3.40±0.80 ^{de}	2.73±0.92 ^{de}
P6	2.06±1.23 ^d	3.13±0.23 ^d	2.20±0.40 ^d

Note: C (aquadest control group), P1 (Carbofuran 1/4 LD₅₀ 0.0125 mg/day), P2 (carbofuran 1/8 LD₅₀ 0.00625 mg/day), P3 (extract of kebar grass 3,375 mg + carbofuran 1/4 LD₅₀ 0.0125 mg/day), P4 (extract of kebar grass 3,375 mg + carbofuran 1/8 LD₅₀ 0.00625 mg/day), P5 (vitamin C 5 mg + carbofuran 1/4 LD₅₀ 0.0125 mg/day), P6 (vitamin C 5 mg + carbofuran 1/8 LD₅₀ 0.00625 mg/day).

In this study administration of carbofuran with doses of 1/4 LD₅₀ and 1/8 LD₅₀ in lactation mice gave a significant difference ($p < 0.05$) and could increase hepatocyte degeneration in proportion to the increase in carbofuran dose given to lactation mice (Table 2). Carbofuran can cause toxic effects that cause ROS. Excessive amounts of ROS can result in the formation of hydroxyl radicals that are very reactive and harmful to the body. Hydroxyl radicals disrupt the normal function of cells by causing reversible lesions in the form of degeneration. An increase in ROS in excessive amounts is very dangerous to the body and can cause the formation of hydroxyl radicals that are very reactive ¹⁸.

In this study the administration of kebar grass to the lactation mice that were previously given carbofuran with doses of 1/4 LD₅₀ and 1/8 LD₅₀ can provide a significant difference ($p < 0.05$) and can reduce the degeneration of mouse hepatocytes (Table 2). The rate of decrease in hepatocyte degeneration of mice produced by flavonoids is better for mice exposed using carbofuran at a dose of 1/8 LD₅₀ compared to mice exposed using carbofuran at a dose of 1/4 LD₅₀ due to lower toxicity. Charged grass contains flavonoids and is classified as a non-enzymatic antioxidant. The antioxidant effect of flavonoids enhances the regeneration process by destroying free radicals, providing competitive substrates for unsaturated lipids in the membrane and accelerating the repair mechanism of

damaged cell membranes so that the amount of hepatocyte degeneration decreases¹⁹.

In this study the administration of ascorbic acid or vitamin C to the lactation mice that were previously given carbofuran at a dose of 1/4 LD₅₀ and 1/8 LD₅₀ can reduce degeneration of mouse hepatocytes even though there were no significant differences (Table 2). The rate of decrease in hepatocyte degeneration of mice produced by ascorbic acid is better for mice exposed using carbofuran at a dose of 1/8 LD₅₀ compared to mice exposed using carbofuran at a dose of 1/4 LD₅₀ due to lower toxicity. Ascorbic acid or vitamin C acts as an antioxidant causing a decrease in the amount of hepatocyte degeneration. Ascorbic acid can stabilize free radicals by completing the lack of electrons possessed by free radicals. Ascorbic acid protects the substrate by substitution in the oxidation process and inhibits a chain reaction from the formation of free radicals that can cause oxidative stress ²⁰.

Necrosis

Observation of necrosis was carried out microscopically using histopathological preparations with HE staining of the liver of mice (*Mus musculus*) during lactation. The observation was carried out using a microscope with a X 400 magnification. observation of necrosis is seen by the presence of nuclei that undergo picnosis, karyorrhexis and karyolysis (Table 2).

The results of the statistical analysis in Table 2 show that there are significant differences ($p < 0.05$) between the C group and the P1, P2, P3, P4, P5, and P6 groups. There were significant differences ($p < 0.05$) between groups P1 and groups P2, P3, P4, P5, and P6. There was a significant difference ($p < 0.05$) between P2 groups and P3, P4, and P6 groups. There were significant differences ($p < 0.05$) between groups P3 and groups P4, P5, and P6. There was a significant difference ($p < 0.05$) between groups P4 and groups P5 and P6.

In this study the administration of carbofuran with a dose of $1/4 LD_{50}$ and $1/8 LD_{50}$ in the lactation mice gave a significant difference ($p < 0.05$) and can increase hepatocyte necrosis in proportion to the increase in carbofuran dose given to the lactation mice (Table 2). Necrosis is an advanced stage of degeneration that has passed the point of no return. Necrosis is cell damage that causes tissue cell death while the individual is still alive²¹. Pathogenically the occurrence of necrosis is a continuation of degeneration which has reached the point of no return²². The level of toxicity of a compound in the body is caused by the period of exposure, method and dosage, and the level of immunity between individuals²³.

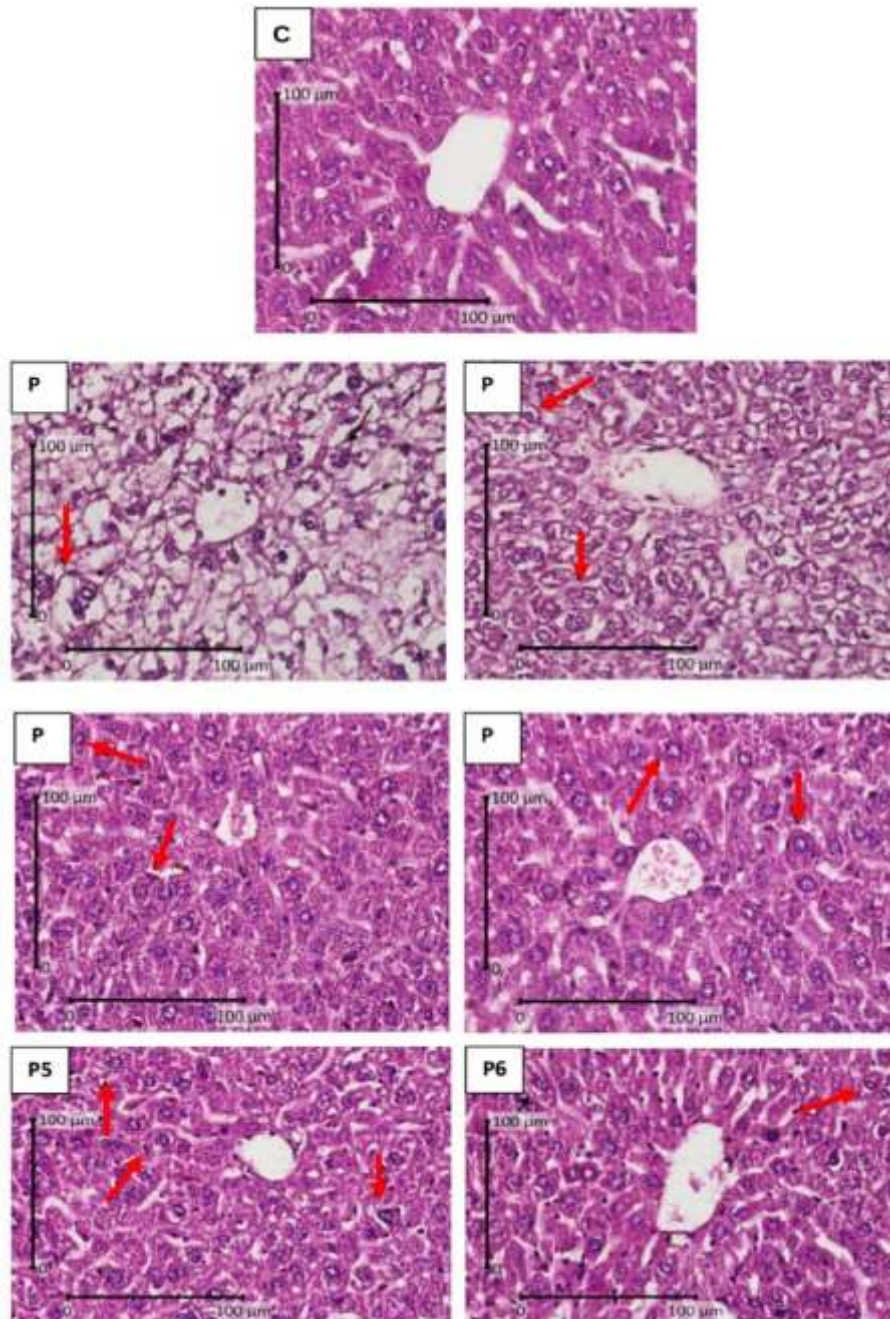


FIGURE 1: Comparison of microscopic features of lactating hepatocyte degeneration of mice (*Mus musculus*) during lactation with H.E staining, X 400. Arrows indicate cell degeneration (\rightarrow).

In this study the administration of kebar grass to lactation mice that were previously given carbofuran at doses of $1/4 LD_{50}$ and $1/8 LD_{50}$ can provide a significant difference ($p < 0.05$) and can reduce mice hepatocyte necrosis (Table 2). The reduced level of hepatocyte necrosis of mice produced by flavonoids is better for mice exposed using carbofuran at a dose of $1/8 LD_{50}$ compared to mice exposed using carbofuran at a dose of $1/4 LD_{50}$ due to lower toxicity.

It is suspected that administration of kebar grass extract can restore hepatocyte function so that an increase in the number of cell necrosis can be prevented. There is a decrease in the number of hepatocyte necrosis due to the presence of flavonoid content in kebar grass that works by suppressing the formation of free radicals or ROS through inhibition of enzymes, metal ion chelating involved in the production of free radicals and reducing free radicals (free radicals scavengers)²⁴.

In this study the administration of ascorbic acid or vitamin C to the lactation mice that were previously given carbofuran at a dose of 1/4 LD₅₀ and 1/8 LD₅₀ can reduce mice hepatocyte necrosis even though there were no significant differences (Table 2). Decreased levels of mice hepatocyte necrosis produced by ascorbic acid are better for mice exposed using carbofuran at a dose of 1/8 LD₅₀ compared to mice exposed using carbofuran at a dose of 1/4 LD₅₀ due to lower toxicity. Ascorbic acid or vitamin C acts as an antioxidant that causes a decrease in the number of hepatocyte necrosis. Ascorbic acid or vitamin C works by donating electrons so that it can prevent the formation of other compounds from the oxidation process by releasing a carbon chain ²⁵.

Inflammation cells

Observation of inflammation cell was carried out microscopically using histopathological preparations with HE staining from the liver of mice (*Mus musculus*) during lactation. The observation was carried out using a microscope with a X 400 magnification. Observation of inflammation cell was seen in the porta or Kiernan triangles (Table 2).

The results of the statistical analysis in Table 2 show that there are significant differences ($p < 0.05$) between the C group and the P1, P2, P3, P4, P5, and P6 groups. There were significant differences ($p < 0.05$) between groups P1 and groups P2, P3, P4, P5, and P6. There was a significant difference ($p < 0.05$) between P2 groups and P3, P4, and P6 groups. There were significant differences ($p < 0.05$) between groups P3 and groups P4, P5 and P6. There was a significant difference ($p < 0.05$) between groups P4 and groups P5 and P6.

In this study the administration of carbofuran with a dose of 1/4 LD₅₀ and 1/8 LD₅₀ in the lactation mice gave a significant difference ($p < 0.05$) and can increase inflammation cell in the liver in proportion to the increase in carbofuran dose given to the lactation mice (Table 2). The presence of inflammatory cells in the tissue is also a response to injury by carbofuran in the form of membrane damage and necrosis. These events due to oxidative stress can cause cellular protein damage and cause necrosis ²⁶. Inflammation cell is the body's defensive reaction to all forms that attack the body ²⁷.

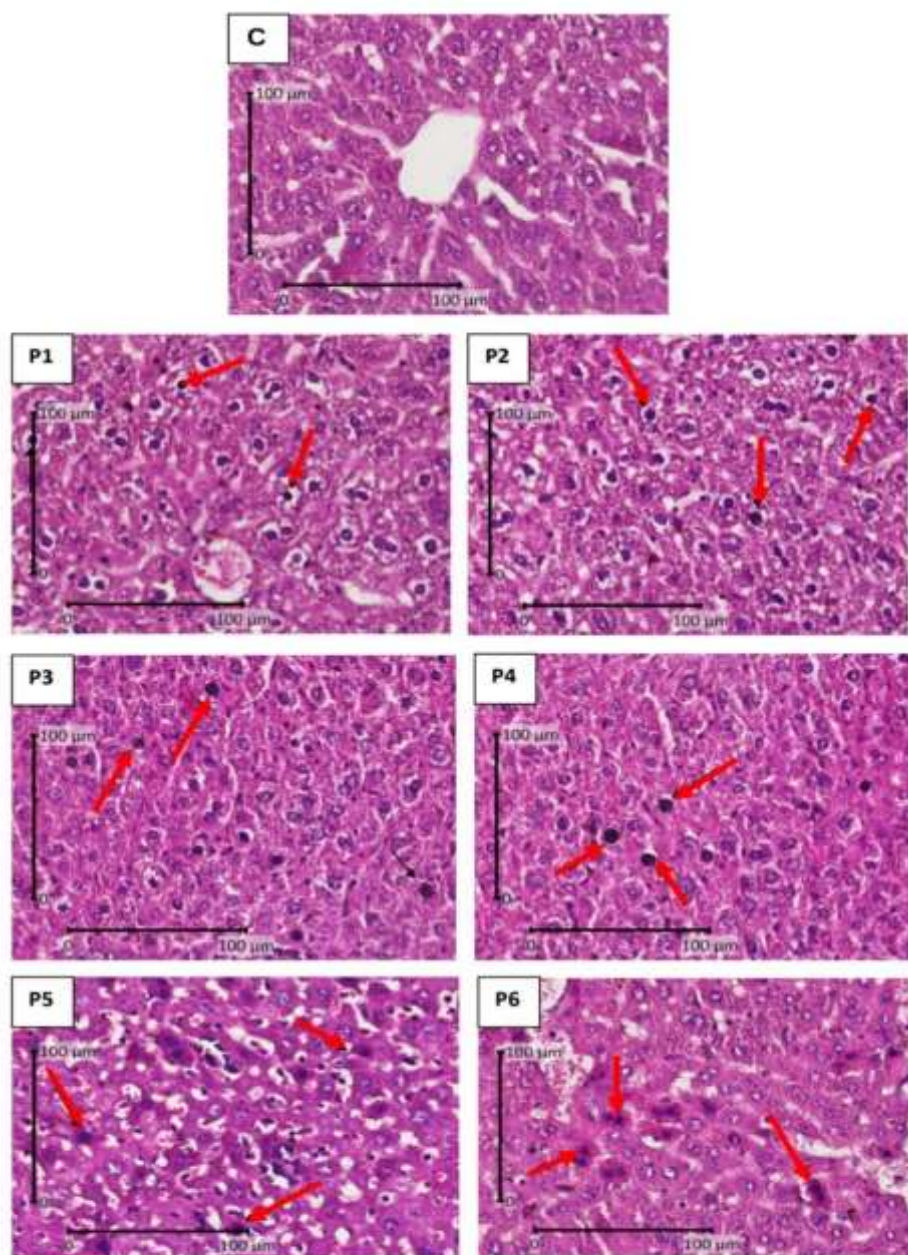


FIGURE 2: Comparison of microscopic images of mice hepatocyte necrosis (*Mus musculus*) during lactation with H.E staining, X 400. Arrows indicate cell necrosis (→).

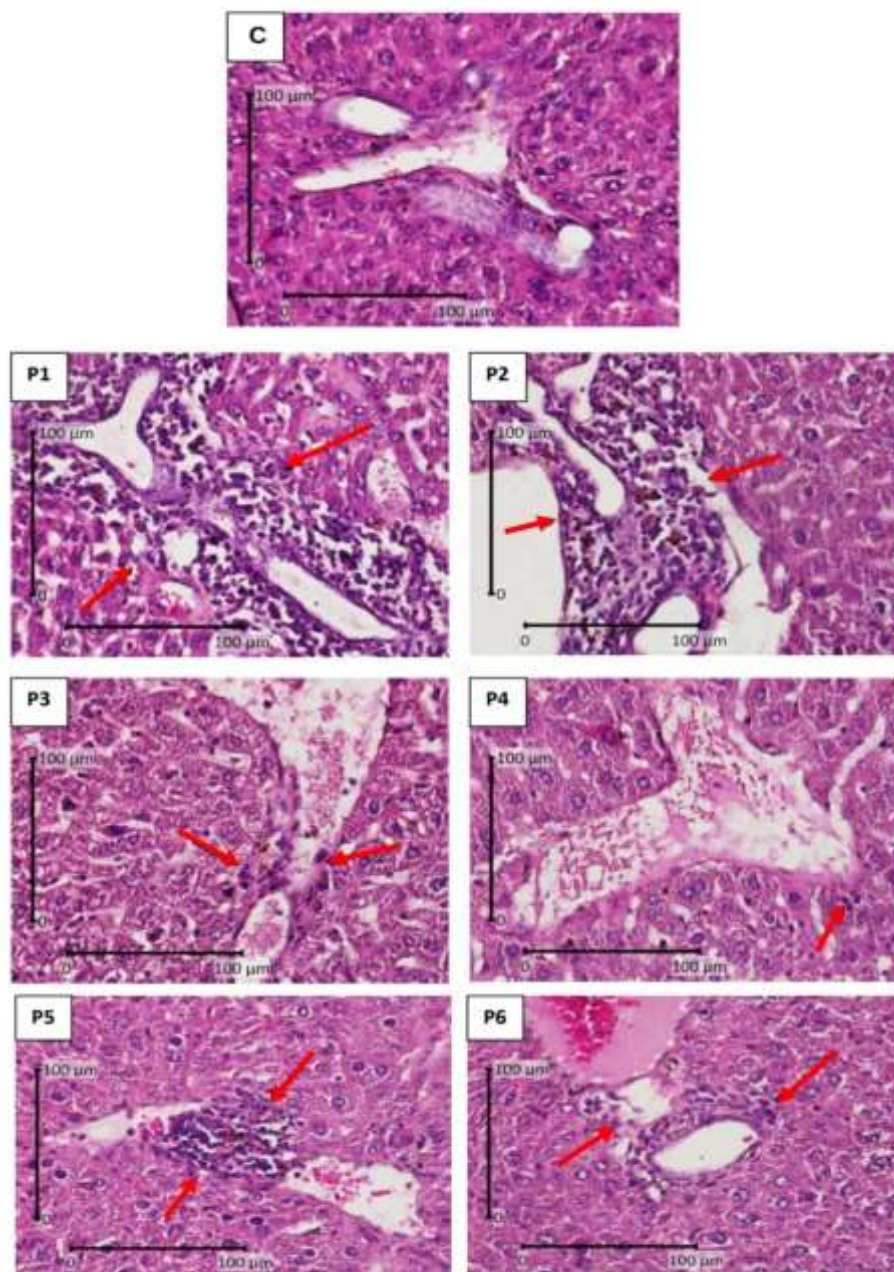


FIGURE 3: Comparison of microscopic images of inflammation cell in the liver of lactation mice (*Mus musculus*) with H.E staining, X 400. Arrows indicate inflammation cells (→).

In this study the administration of kebar grass to lactation mice that were previously given carbofuran at doses of $1/4 LD_{50}$ and $1/8 LD_{50}$ can provide a significant difference ($p < 0.05$) and can reduce inflammation cell in the liver of mice (Table 2). The level of reduction in inflammation cell in the liver of mice produced by retinol and tocopherol was better for mice exposed using carbofuran at a dose of $1/8 LD_{50}$ compared to mice exposed using carbofuran with a dose of $1/4 LD_{50}$ due to lower toxicity. There is a decrease in the amount of inflammation cell in the liver due to the presence of retinol and tocopherol content in the kebar grass. Retinol or vitamin A as an antioxidant works by reacting with free radicals and free radicals become stable. Tocopherol or vitamin E as a non-enzymatic antioxidant that collaborates with oxygen to destroy Reactive Oxygen Species ^{14, 15}.

In this study the administration of ascorbic acid or vitamin C to lactation mice that were previously given carbofuran at doses of $1/4 LD_{50}$ and $1/8 LD_{50}$ can reduce inflammation cell in the liver of mice, although there were no significant differences (Table 2). The level of reduction in inflammation cell in the liver of mice produced by ascorbic acid is better for mice exposed using carbofuran at a dose

of $1/8 LD_{50}$ compared to mice exposed using carbofuran at a dose of $1/4 LD_{50}$ due to lower toxicity. Ascorbic acid or vitamin C acts as an antioxidant that causes a reduction in the amount of inflammation cell in the liver. Ascorbic acid or vitamin C functions as an antioxidant because it effectively captures free radicals, especially ROS or reactive oxygen compounds ²⁸.

The administration of kebar grass extract is considered better than the administration of ascorbic acid or vitamins in treating degeneration, necrosis, and inflammation cells in mice during the lactation period caused by carbofuran with a dose of $1/4 LD_{50}$ or $1/8 LD_{50}$. This is due to the presence of flavonoids, retinol and tocopherol in kebar grass. Polyphenol compounds such as flavonoids can inhibit oxidation reactions through radical scavenging mechanisms by donating an unpaired electron in free radicals so that the number of free radicals is reduced ¹⁶. Retinol or vitamin A as an antioxidant works by reacting with free radicals and free radicals become stable. Tocopherol or vitamin E has properties that are easily oxidized so that they can protect other compounds from oxidation. As an antioxidant tocopherol can fight destructive oxygen, lipid peroxide, and free radicals and stop free radical chain reactions ²⁹.

CONCLUSION

The administration of kebar grass extract is better in dealing with degeneration, necrosis, and inflammation cells in mice during lactation caused by administering carbofuran at a dose of 1/4 LD₅₀ or 1/8 LD₅₀ compared with the provision of vitamin C. The content of flavonoids, retinol, tocopherol, vitamins A and vitamin E in kebar grass can inhibit oxidation reactions.

REFERENCES

- [1] Bale JS, van Lenteren JC, and Bigler F. Biological control and sustainable food production. *Philos Trans R Soc B: Biol Sci.* 2008; 363(1492): 761-776. doi: 10.1098/rstb.2007.2182
- [2] Jaiswal SK, Siddiqi NJ, Sharma B. Carbofuran Induced Oxidative Stress in Rat Heart: Ameliorative Effect of Vitamin C. *ISRN oxid med.* 2013; 1-10. doi: 10.1155/2013/824102
- [3] Indraningsih. The Effect of Using Carbamate Insecticides on the Health of Livestock and Their Products. *Wartazoa J.* 2008; 8(2): 101-114.
- [4] Tannock J, Wessel CL. Determination of carbofuran residue and metabolites in plant material. *Pestic Sci.* 1981; 12: 228-234. doi: 10.1002/ps.2780120217
- [5] Kaur M, Shandir R. Comparative effect of acute and chronic karbofuran exposure on oxidative stress and drug metabolizing enzymes in liver. *Drug Chem Toxicol* 2006. 29: 415-421. doi: 10.1080/01480540600837969
- [6] Hodges RE, Minich DM. Modulation of Metabolic Detoxification Pathways Using Foods and Food-Derived Components: A Scientific Review with Clinical Application. *J Nutr Metab.* 2015; 2015: 760689. doi: 10.1155/2015/760689
- [7] Cichoż-Lach H, Michalak A. Oxidative stress as a crucial factor in liver diseases. *World J Gastroenterol.* 2014 Jul 7; 20(25): 8082-8091. doi: 10.3748/wjg.v20.i25.8082
- [8] Chew BP, Park JS. Carotenoid Action on the Immune Response. *J Nutr* 2004; 134: 257-261. doi: 10.1093/jn/134.1.257S.
- [9] Brambilla DC, Mancuso MR, Bosco SP, Cantarella G, Lempereur L, Benedetto GD, Pezzino S, Benardini R. The role of antioxidant supplement in immune system, neoplastic, and neurodegenerative disorders: a point of view for an assessment of the risk/benefit profile. *Nutr J.* 2008; 7: 29- 38. doi: 10.1186/1475-2891-7-29
- [10] Mansour T, Haikal M, Mossa AH, Refaie AA. Toxic Effect of Five Insecticides on Their Mixture on Male Albino Rats. *J Egypt Soc Toxicol* 2008; 39: 85-94.
- [11] Asrianti A, Widjiati, Legowo D, Maslachah L, Arimbi, Luqman EM. The Effect of Carbofuran Exposure on Mice During Lactation Period Against on Histopathology Description of The Heart of Mice (*Mus Musculus*) Offspring. *Int J Pharm Res* 2020; 12(4): 4646-4653. doi: 10.31838/ijpr/2020.12.04.327
- [12] Santoso B, Kilmakossu A, Sambodo P. Effects of saponin from *Biophytum petersianum* Klotzsch on ruminal fermentation, microbial protein synthesis and nitrogen utilization in goats. *Anim Feed Sci Technol.* 2007; 137: 58-68. doi: 10.1016/j.anifeeds.2006.10.005
- [13] Kurutas EB. The importance of antioxidants which play the role in cellular response against oxidative/nitrosative stress: current state. *Nutr J* 2016; 15: 71. doi: 10.1186/s12937-016-0186-5.
- [14] Traber MG, Stevens JF. Vitamins C and E: Beneficial effects from a mechanistic perspective. *Free Radic Biol Med* 2011; 51(5): 1000-1013. doi: 10.1016/j.freeradbiomed.2011.05.017
- [15] Petersen RC. Free-radicals and advanced chemistries involved in cell membrane organization influence oxygen diffusion and pathology treatment. *AIMS Biophys.* 2017; 4(2): 240-283. doi: 10.3934/biophy.2017.2.240
- [16] Knodell RG, Ishak KG, Black WC, Chen TS, Craig R, Kaplowitz N, Kiernan G. Formulation and application of a numerical scoring system for assessing histological activity in asymptomatic chronic active hepatitis. *Hepatology* 1981; 1: 431-435. doi: 10.1002/hep.1840010511.
- [17] Brunt ME. Grading and Staging the Histopathological Lesions Chronic Hepatitis: The Knodell Histology Activity Index and Beyond. *Hepatology* 2000; 31(1): 241-246. doi: 10.1002/hep.510310136
- [18] Lobo V, Patil A, Phatak A, Chandra N. Free Radical, Antioxidants, and Functional foods: Impact on Human Health. *Pharmacogn Rev* 2010; 4(8): 118-126. doi: 10.4103/0973-7847.70902
- [19] Pham-Huy LA, He H, Pham-Huy C. Free Radicals, Antioxidants in Disease and Health. *Int J Biomed Sci* 2008 Jun; 4(2): 89-96. PMID: PMC3614697
- [20] Christijanti W, Nur RU, Iswara A. The Effect of Giving Antioxidant Vitamins C and E on the Quality of White Rat Spermatozoa Exposed to Allethrin. *J Biol Educ.* 2010. 2(1): 18-26. <https://doi.org/10.15294/biosaintifika.v2i1.1148>
- [21] Fink SL, Cookson BT. Apoptosis, Pyroptosis, and Necrosis: Mechanistic Description of Dead and Dying Eukaryotic Cells. *Infect Immun* 2005; 73(4): 1907-1916. doi: 10.1128/IAI.73.4.1907-1916.2005
- [22] Miller MA, Zachary JF. Mechanisms and Morphology of Cellular Injury, Adaptation, and Death. *Vet Bas Pathol Vet Dis* 2017; 2-43. e19. doi: 10.1016/B978-0-323-35775-3.00001-1
- [23] Nicholson LB. The immune system. *Essays Biochem.* 2016 Oct 31; 60(3): 275-301. doi: 10.1042/EBC20160017
- [24] Cherrak SA, Mokhtari-Soulimane N, Berroukeche F, Bensenane B, Cherbonnel A, Merzouk H, and Elhabiri M. *In Vitro* Antioxidant versus Metal Ion Chelating Properties of Flavonoids: A Structure-Activity Investigation. *PLoS One.* 2016; 11(10): e0165575. doi: 10.1371/journal.pone.0165575
- [25] Padayatty SJ, Katz A, Wang Y, Eck P, Kwon O, Lee JH, Chen S, Corpe C, Dutta A, Dutta SK, Levine M. Vitamin C as an antioxidant: evaluation of its role in disease prevention. *J Am Coll Nutr* 2003; 22(1):18-35. doi: 10.1080/07315724.2003.10719272
- [26] Ryter SW, Kim HP, Hoetzel A, Park JW, Nakahira K, Wang X, Choi AMK. Mechanisms of cell death in oxidative stress. *Antioxid Redox Signal* 2007; 9(1):49-89. doi: 10.1089/ars.2007.9.49

- [27] Yang B, Weiyang Z, Zhenzhen H, Fangming L, Ling Z, Shulong Y, Haibing K, Lei W, Jie W, Jinglei W, Ting Z, Dalei Z. Involvement of oxidative stress and inflammation in liver injury caused by perfluorooctanoic acid exposure in Mice. *Biomed Res Int*. 2014; 1-7. doi: 10.1155/2014/409837
- [28] Frei B. Reactive Oxygen Species and Antioxidant Vitamins: Mechanisms of Action. *Am J Med* 1994. 26;97(3A):5S-13S. doi: 10.1016/0002-9343(94)90292-5
- [29] Blokhina O, Virolainen E and Fagerstedt KV. Antioxidants, Oxidative Damage and Oxygen Deprivation Stress: a Review. *Ann Bot* 2003; 91(2): 179-194. doi: 10.1093/aob/mcf118.