

Quantitative and Qualitative Analysis of Sexual Dimorphism in Aditus Orbitae of Kacang Goat (*Capra aegragus hircus*)

by Epy Muhammad Luqman

Submission date: 20-Dec-2022 02:54PM (UTC+0800)

Submission ID: 1984914020

File name: C-30_Quantitative_and_Qualitative_Analysis_of_Sexual.pdf (588.29K)

Word count: 5595

Character count: 27909

Quantitative and Qualitative Analysis of Sexual Dimorphism in *Aditus Orbitae* of Kacang Goat (*Capra aegragus hircus*)

⁸ Suharsono, S., Eliyani, H., Hendarti, G. A., Widjiati, W.,
Luqman E. M.

Department of Veterinary Science, Faculty of Veterinary Medicine, Universitas Airlangga, Surabaya, Indonesia. Kampus C Unair Jalan Mulyorejo, Surabaya-60115 Indonesia

With 2 tables and 2 figures.

Received March, Accepted June, 2022

Abstract

The study aimed to analyze the *aditus orbitae* of Kacang goats as object of sexual dimorphism in different sexes. The sample size was 20 Kacang goat skulls, consists of 10 female and 10 male goats. Measurements were taken on skull length (SL), width of the *zygomatic process of frontal bone* (WZF), width of the *frontal process of zygomatic bone* (WFZ), the length of the caudal of the orbit rim (LCRO) and the greatest distance (width) of the *aditus orbitae* (OW). The Data was analyzed using two ways, quantitatively and qualitatively. The quantitatively done to analyze the correlation between variables and the possible differences among variables of different sexes. The results showed that WZF, WFZ and OW variables were positively correlated with skull length (SL) ($p < 0.05$), except the length of caudal rim of the orbit (LCRO). ZF and Orbital width were significant between sexes ($p < 0.05$),

furthermore both of WFZ and LCRO, have similarly in size ($p > 0.05$). LCRO/SL and LCRO/OW ratio, however, also both of zygomatic process (ZF) and orbital (OW) width, those were could be used for estimating of sexual dimorphism ($p < 0.05$). The *aditus orbitae* shape show significant sexual dimorphism, wherein in female are ellipsoid and larger while in male rectangular and relatively smaller. The present study concludes that by quantitative combining with qualitative techniques could be used for identifying the sexes estimation of *aditus orbitae* of Kacang goat.

Keywords: *Aditus orbitae*. The Kacang goat; scientific research; sexual dimorphism

Introduction

The morphometrical and morphological techniques may be useful to determine quantitatively and quali-

tatively the bone structures to establish the differences between sex. The pelvic and femur bones are the most accurate skeletal elements to use for assignment in determining sex in human, this is because the anatomy of reproductive function affects the development of pelvic bones (Miyakawa, et al., 2016; Csanády, et al., 2019; Ali, et al., 2020). Despite the congruence between the function of the pelvic and femur bone, the study preferred femur bone as the choice for sexual dimorphism research (Belhaoues, et al., 2016; Kanchan, et al., 2021). In human, sexual dimorphism can also be identified through the bones of the upper limbs (Tomczyk et al., 2017; Atamtürk, et al., 2019; Hunter, et al., 2019). Identification of sex determination using bones such as pelvis, femur and upper limbs is called identification of sexual dimorphism by postcranial bones as objects

The skull is chosen as an object of research, it is because of this semi rigid, hard and massive structure to make them to identify individuals, especially in archaeological context. In the sexual dimorphism study, the skull is still the main focus to identify through the anatomy structure. This bone is composed of two parts: the cranial and facial bones in addition to the mandible. The consideration of the cranium as a research object because the morphologic patterns of cranial variation, is more homogeneous than postcranial bone

(Plavcan, 2012; Zichello, et al., 2018; Kasimatis, et al., 2020). Research using dogs or sheep, has been reported that there are differences in cranium size and measurement between sexes (Elledge, et al., 2008; Casanova, et al., 2020; Abbazabadi, et al., 2020).

The parameter measure of *aditus orbitae*, is a common study that are interested to distinguish into sexual dimorphism. Bones sharing in formation the circumference of *aditus orbitae*, is the lacrimal and *zygomatic* bones forming the cranial border, the *dorsal* border is formed by the frontal and then downward to the caudal of orbit, followed by zygomatic arch on ventral part of the orbital bony rim (Choudhary, et al., 2018). In goats, frontal bone sutured with the zygomatic bone joining a slight prominent of the processes forming a shape as caudal part of orbit bony rim.

Aditus orbitae research generally uses more quantitative approaches. Complex patterns of shape and form, should be estimated in morphometric using statistical relationship analysis. The translation and reconstructed a complexity shapes into measurement, can be used as powerful tools to visualize the same size, measurement and shape of individual or group difference in anatomy structure (Mitteroecker, et al., 2013). The *aditus orbitae* shape and forms, should not only be reached by qualitative described but also by quantitative as well. In general, a rounded orbit and a

circular or quadrangular *aditus orbitae* shape was common. The quantitative approach that has been done to measure the complexity object, composed of element such as width, length and height. It is worthy to mention that if the orbital measurements and size is neglected, the result obtained will be biased to compare the difference between individuals or groups. The expectancy by combining qualitative with quantitative analysis in this study, demonstrated the more effective information about sexual dimorphism of *aditus orbitae* of Kacang goat.

In Indonesia, Kacang Goat breed, have the largest population compared to other livestock according to statistic data until 2021 (Dataku Application, 2021). As a local breed, Kacang goats are very useful for diverse purpose of meat and leather product. The animals are characterized by short hair with fleece is a single variant of coat color, white, black or brown, hanging short ears, has horn, and bearded on the male (Insan and Isaac, 2020).

Materials and Methods

Material

The research specimen were the skulls of adult Kacang goats aged 2-3 years, ¹¹ were collected from Division of Veterinary Anatomy, Faculty of Veterinary Medicine Universi-

tas Airlangga Surabaya Indonesia¹⁵. The study was conducted on 20 skulls, (10 males and 10 females). The measurements were taken to a millimeter scale using a sliding caliper with a precision of 0.01 mm.

Method Research

Research methods are carried out in two ways, quantitatively and qualitatively. Quantitative variables taken in the skull and orbit of kacang goat, were described below and revealed in ¹⁹ (1). The skull length (SL), width of zygomatic process of frontal bone (WZF) and frontal process of the zygomatic bone (WFZ), the length of caudal part of rima orbitae (LCRO) and the width of the *aditus orbitae* (OW).

The skull length (SL) is measured from maximum length of the skull from ¹⁸ tubercula externa of occipital bone to the the rostral tip of the incisive bones. WZF, the maximum width of the base of zygomatic process, before upward dorsally; WFZ, the maximum width of most height of frontal process before downward to the caudal of rima orbitae. LCRO was done by measuring the height of inner caudal of rima orbitae that is the distance ⁷ from the top point of zygomatic process ¹⁰ the frontal bone (ZF) till the base point of frontal process of the zygomatic bone (FZ). The measurement was also carried out at the greatest distance (width) of the *aditus orbitae* (OW); as measured from the point of the zygomatico-frontal suture

where ZF joining with the FZ, towards the farthest point of the rostral margin of the *aditus orbitae*.

Presentation and Analysis of Data

The various orbital measurement data were recorded and subjected to statistical analysis. The quantitative result, are arranged in a table and expressed as mean and standard deviations ($\bar{X} \pm sd \text{ mm}$), whereas the qualitative shape and form are presented in a descriptive interpretation.

The relationship between variable were analyzed by correlation Pearson with a probability of less than five percent ($p < 0.05$) was considered significant. If more than two variables correlated to each other, further, the *aditus orbitae* data were analyzed using by unpaired-student's t test of WZF, WFZ, LCRO and OW, and followed by the General Linear Model Repeated Measure (GLMRM) of those ratio data. The ratio of WZF, WFZ, LCRO and OW against to skull length (SL) and especially LCRO also against to OW were examined between sexes by GLMRM.

Ratio scale used SL to present as relative value, it is that skull length represents of elongated growth that definitely different between female and male related by gender characteristic. Similar assumption was also applied to orbital wider (OW) as relative value of LCRO. In addition, LCRO also needs to be discussed in that contribution as the vertical structure determines the shape and form of the cau-

dal corner and the lowest point of the ventral order of the margin *aditus orbitae*. All collected data were statistically tested. These analyses were performed with the use of SPSS software version 20.

Results

Quantitative Analysis

Skull length (SL) is positively correlated ($p < 0.01$) with the width of zygomatic process (WZF), frontal process (WFZ) and with *aditus orbitae* width (OW). Among the variables only WZF and WFZ are correlated to each other ($p < 0.05$). This study showed that the length of the caudal bony rim (LCRO), does not correlate with SL and the other variables of *aditus orbitae* ($p > 0.05$) (as indicated in the Table 1).

The results of statistical analysis reflected between sexes, found that the measurement of SL, WZF and OW on female were wider than on male goats ($p < 0.05$), furthermore both of WFZ and LCRO measurement, have similarly between both gender ($p > 0.05$).

Even though, if the analysis occurs in relative values, showed that WZF/SL ratio was consistent in difference ($p < 0.05$) between female and male. But it was important to note, if the LCRO in female as compare in male was determined as 23.67 ± 1.75 vs 24.48 ± 2.20 mm, was no significant ($p > 0.05$), otherwise the result in ratio scale showed that there were statisti-

cally significant in level of $p < 0.05$. It is known, both in LCRO/SL ratio of male was 0.13 ± 0.01 vs female at 0.11 ± 0.01 (as indicated in the Table 2) and also of LCRO/OW ratio scale, wherein male was 0.76 ± 0.059 larger more than female at 0.71 ± 0.045 .

¹In goat populations, one of the two sexes may have a larger or smaller orbital size than the other. Such variability means that animals cannot be universally characterized by gender, because shape is not only completely influenced by the measurement, then supposed the difference in shape will not change the ratio scale value (Salvagno and Albarella, 2017). In this study, there were several differences of orbital variables among female and male. The morphometrical results shown may not be consistent, as the development of skull and orbital not only affected by gender characteristic or genetic factor but also influenced by other factors that acting to impact the individual condition.

Qualitative Analysis

In is known that, the orbital opening was bounded completely by a bony rim. The present study noted that the anatomical appearances of *aditus orbitae* in female goats was found oval or elliptical and almost circular in shape, while in males it was trapezoidal in shape. In addition, the zygomatic arch formed the ventral border of orbit as a curvature ridge and it lowest point placed in the middle of the margin, in female. Whereas in male Ka-

cang goat was found that the lowest point was located more caudally, below the sharp corner in horizontal ridge along the ventral margin of the orbit. (as illustrated in figure 2 left and right).

Is the most important, that the caudal part (LCRO) of the bony rim¹ appears as a bridge by joining of zygomatic process of frontal bone (ZF) and frontal process of zygomatic bone (FZ). Note, however, the bridge of caudal of bony rim itself in the female more curved than to male¹⁷ which are slightly straight. Whereas the ventral border of orbit is formed by the zygomatic arch, that extended into both directions firstly, it is incline to the tip of zygomatic process as LCRO and secondly it towards to the temporal process joining in the zygomatic process of temporal bone. It is known that the ventral border and it adjoins the caudal bridge of bony rim was form the caudal corner in circumference orbit.

Discussion

¹The morphometric and morphologic approach not only has the advantage of being used for identification the measurement but also the shape of anatomical structure. This approach also enables carrying out to evaluated both of the quantitative and qualitative differentiated sexual dimorphism especially of the orbital structure. The examined of bony rim component surrounding the orbital opening of

goat, based on a sample observed in skull specimen bone.

The quantitative result we report here, that was the caudal bony rim structure of zygomatic and frontal processes width, also the orbital opening width were positively correlated with skull length (SL). In the other word, there is an increase in the skull length concurrent with ZF, FZ and Orbital width, by contrast however the measurement of caudal bony rim orbit (CRO) length was no correlated with skull length. As well, the width of zygomatic with frontal processes was correlated each other.

The result obtained from both of zygomatic process (ZF) and orbital (OW) width was statistically significant between sexes ($p < 0.05$), but both of frontal process (FZ) width also the caudal bony rim orbit (CRO) length between female and male were similar in measurement and size. Show how, the ratio of WZF, WFZ, LCRO and OW against skull length these describe that only WZF/SL ratio clearly visible different between male and female, whose the female are more larger than male. And it results most useful characteristic for sex estimation in *aditus orbitae* dimensions measure. The LCRO however was not significant different, but both of the LCRO/SL and LCRO/OW ratios was significantly larger in male than male. The value and size between LCRO ratio analysis, should emphasis to considering that is affect to form

the structure of the caudal bony rim bridge among both sexes.

Although the *aditus orbitae* have an ambiguous and unique in measurement, size and shape, the previous researchers have showed that, in general, the base of the orbital bony rim were determined to be a curved or rectangle shape. That is measured, for instance, by the horizontal and vertical zygomatic arch structures. Both of that structure set of a curvature or rectangles shape, also both of length or width of one side, would affect the morphometric of all of the objects shape. Morphometric is a method used as one way to explain shapes through quantification measurement (Mitteroecker, et al., 2013).

The result of the present study found that the skull length and the *aditus orbitae* variables of female goat were larger than those of male goat, it is suggested that the skull length and the other variables measurements and size, not only related to dimorphism aspect but also depends on the material origin of the individual specimen objects collected. The shape of the eye orbit has been used in some studies as a sex-distinguishing characteristic. Most of the previous studies reported there are some anatomical variation in measurement and shape of the skull length also the several variabilities of the orbital structure. Some was recorded that the orbital parameters larger in the female than male, otherwise men-

tioned that the male showed more length than female, or the length of skull distances was similar in measurement between sexes (Pasiaks, et al., 2012; Olawumi, 2017).

This tendency above, similar on qualitative description by Patra, et al. (2021) which described that orbit circumference shape can be divided into four type that were: encircle, elliptical, rectangular and quadr-angular orbit. There are some sexual dimorphism variation in size, measurement and shape of orbit rim which located in the lateral side of the skulls. This confirm that morphometric and morphologic of orbital opening in this study, not only reflect by contributions of genetic force, but also the environment was acting to impact the variation. It is known, that's the skulls on this observation obtained (both for males and females) were collected as an object observation within twenty years period, from the various local farmers in this country.

The facial typically features were associated with the different growth and development pattern of individual, male and female and the habitat in which these goats are found. Animals may be more influenced by impact of remodeling of its skull, by environmental pressures such as hot climates, and also these may relate to the adaptability of masticatory strains. During the life, animals, were closely related to ecological and behavioral adaptation from any management

with different husbandry practices where they were reared (Kataba, 2014). This result is supported by the opinion that the characteristics of kacang goat morphometry depend on the management of the animal, nutritional factors, behavior of grazing in the field or keeping in cages maintenance (Azmidaryanti et al., 2017; Nafiu, et al., 2020).

In human, Xing, et al. (2012), reported that the quantitative analyses of the variations in orbital shape was effective for identify between individuals and sex-distinguishing characteristic of human race from different geographic areas. Moreover, the authors demonstrated the geometric morphologic measure used for to describing of orbit shape. Lidstone (2011) demonstrated, this will be achieved by attempting to identify male and female pattern of orbital shape using a series of landmarks along the margin of the orbits. In human, quantitative analysis aperture of orbit utilizing as a tool to identify sexes, had the greatest effect between observation and the revealed varying results (Sreekanth and Hema, 2019; El-Farouny, et al., 2021).

This present study provide several quantitative descriptions of the zygomatic process of the frontal bones (WZF) in female goats were larger than in male ones and it consistent larger in WZF/SL ratio scale value. The wider of frontal process (WFZ) of the zygomatic bone among female

and male was not different between each other, so do the WFZ/SL in ratio scale, was consistent similar. The orbital width (OW) in female goats were larger than in male ones, but is not consistent in ratio scale, wherein among sexes the OW/SL value was not significant different.

The present study also described that the length of the caudal rim of the orbit (LCRO), did not differ among sexes, but in ratio scale, the LCRO/SL as also the ratio LCRO/OW was larger in male than female.

The results indicated that actually the orbital opening has more complex shape, so that the object needs a composite analysis such as ratio scale. The ratio scale may be less affected by individual growth and development but it remains fixed although the orbital opening was magnitude in size.

A review of the qualitative description of the *aditus orbitae* of kacang goat, as follow, firstly, on female mentioned that the cranial, dorsal, caudal and ventral of the orbital bony rim are completely encircle and symmetrical. Secondly, the caudal corner of circumference composed between ventral curvature of the zygomatic arch and the caudal bridge of bony rim, is more rounded, and this lower point is situated in the middle of ventral margin.

In male goat, the cranial and dorsal margin was slightly circular but not

symmetrical. The ventral of orbital opening was rectangular, and almost horizontal along the zygomatic arch. The caudal corner of orbital opening which was sharp angle, and the lower point situated rostrally beneath the caudal corner, whereas the vertical caudal structure was straight.

Considering the of the caudal rim of the orbit structure, the width of the zygomatic processes observed in males was narrower than in females, however the frontal processes was similar between the two sexes. In female, the caudal bony rim was vertical and curved back in shape, but in male is straight, incline from the zygomatic arch base to the tip of zygomatic processes of frontal bone. While despite, the caudal bony rim was different in shape, but the length showed similar in both sexes. The description of orbital variables ensure that the sexual dimorphism have various result among individual. Skull length and the other variables dimension in this study have been summarized in table 1 and 2 which showed these variations and recorded that there was no consistently of sexual dimorphism result.

Zichello et al., (2018); Kasimatis, et al., (2020) which stated that the shapes and measurements of human cranium were controlled by genetic. The morphologic characteristic result, depends on two things, firstly the base on measurement form of an object through translation and scale.

Secondly, morphological comparison is based on shape, position and orientation. Therefore, to minimize the effect of arbitrary location in complexity shape along the orbit rim, a sliding technique was used to explore the measurement (Xing, et al, 2012; Casanova, 2017). Moreover, the shape and form of the object is established and is unaffected by changes of position, orientation, size and by rescaling (Mitteroecker, et al., 2013).

Janarthanan and Asha (2017) proposed that research related to morphology will get more informative if the anatomical structures analyzed combined between size, measurement and shape for identification of sexual dimorphism and age detection from human skull.

The result of the present study showed that although the caudal rim of the orbital length (CRO) was not significantly different between the sexes but the value of LCRO/SL and LCRO/OW ratio were larger in male than in female. Therefore, both of the LCRO ratio were efficient in estimating of sexual dimorphism. The results obtained from both of zygomatic process (ZF) and orbital width (OW) was statistically significant between sexes. In addition, the *aditus orbitae* opening showed difference in appearance. The orbit in female was ellipsoid and more larger while in male was rectangular and relatively smaller.

We conclude that by utilizing both quantitative and qualitative methods

may increase the ability to assess sexual dimorphism of *aditus orbitae* of Kacang goat.

References

- Abbasabadi, B.M., Hajian, O., Rahmati, S. (2020):** Investigating the Morphometric Characteristics of Male and Female Zill Sheep Skulls for Sexual Dimorphism. *Anat Sci.*17: 13 – 20.
- Ali, S.H.M., Omar, N., Shafie, M. S., Ismail, N.A. N., Hadi, H., Nor, F. F. (2020):** Sex estimation using subpubic angle from reconstructed three-dimensional computed tomography pelvic model in a contemporary Malaysian population. *Anat Cell Biol.* 53:27-35.
- Azmidaryanti, R., Misrianti, R., Siregar, S. (2017):** Comparison of semi-intensive and intensively reared peanut goats in Kampar Regency, Riau Province. *Anim Feed Sci Tec,* 5: 84 – 88.
- Atamtürk, D., C. P., Duyar, I. (2019):** Estimation of sex from scapular measurements: use of the bone area as a criterion. *Euras J Anthropol.*10:39-45.
- Belhaoues, F., Forstenpointner, G., Breit,S.(2016):**A study of sexual dimorphism in the femur among contemporary Bulgarian population. *Revue Méd. Vét,*167: 256-268.

- Casnova, P. M. P., Siddiq, A. B., Onar, V. (2020):** Cranial size and shape sexual dimorphism in the Kangal dog from Turkey. *Turk J Vet Anim Sci*, 44: 396-403.
- Choudhary, O.P., Kalita, P. C., Doley, P. J., Kalita, A., Arya, R. S.(2018)** Morphometrical studies on the orbit of goat (*capra hircus*) of mizoram. *Rumin Sci*,7: 71-72.
- Csanády, A., Krišovský, P., Hlôška, I. (2019):** Pelvic and sacral size dimorphism and allometry in two predatory carnivores with different life histories and locomotory adaptations. *Turk J Zool*,43: 1 – 12.
- El- Farouny, R.H., Hassanein, S. A., Azab, R. M. (2021):** Morphometric evaluation of piriform and orbital aperture in sex discrimination by using computed tomography in Egyptian population. *Egypt J. Forensic Sci. Appl. Toxicol.* 21: 1 -12.
- Elledge, A. E, Allen, L. R., Carlsson, B. L., Wilton C. A. N., Leung, K. P (2008):** An evaluation of genetic analyses, skull morphology and visual appearance for assessing dingo purity: implications for dingo conservation. *Wildlife Research*, 35: 812–820.
- Hunter, R.L., Briley, K., Agnew, A. M. (2019):** Sex differences in human tibia cortical bone morphometrics from computed tomography (CT). *Ircobi Conference*: 436 – 445.
- Insan, I. A., Ishak, M. (2020):** Income analysis of goat traders in Tiroang District, Pinrang Regency. *Bongaya J Res Accoun*, 3: 1-8.
- Janarthanan, R., Asha, R. (2017):** Supraorbital margins for identification of sexual dimorphism and age detection from human skull using wavelets. *Asian J Appl Sci*, 1:279-282.
- Kanchan, R. K., Subhadarsini, S., Mishra, D. N., Mohapatr, C. I. (2021):** Sexual Variations of Femoral Neck-Shaft Angle in the Population of Odisha. *J Evolution Med Dent Sci*.10: 1397 – 1390.
- Kataba, A (2014):** Biometric and morphologic Characteristics of the skull of Gwembe Valley Dwarf Goat (*capra hircus*) breed of Zambia. Thesis. The university of Zambia Scholl of Veterinary Medicine Biomedical Science Departement Lusaka. Zambia.
- Kasimatis K. R., Ramlrez, S. S., Stevenson, Z. C. (2020):** Sexual dimorphism through the lens of genome manipulation, forward genetics, and spatiotemporal sequencing. *Genome Biol. Evol.* 13, 1 – 11.
- Lidstone, L.J. (2011):** Analysis of Sexual Dimorphism in Human Eye Orbits using Computed Tomography. Thesis. The Faculty of Graduate Studies of The University of Manitoba, Winnipeg.
- Mitteroecker, P., Gunzb, P., Windhager, S., Schaefer, K. (2013):** A brief review of shape, form, and allometry in geometric morphometrics, with applications to human facial

morphology. *Hystrix, Italian J Mamm*, 24: 59–66.

Miyakawa, N., Kishiro, T., Fujise, Y., Nakamura, G., Kato H. (2016): Sexual Dimorphism in Pelvic Bone Shape of the North Pacific Common Minke Whales (*Balaenoptera acutorostrata*). *Open J Anim Sci*, 6: 131-136.

Nafiu, L. O., Pagala, M. A., Mogiye. S. L. (2020): Production characteristics of Etawa crossbreeds and Kacang goats in different rearing systems in Toari District, Kolaka Regency. *Anim Feed Sci Tec*, 8: 91-96.

Olawumi, I. O. (2017): Skull Typology and Morphometrics of the Nigerian Local Dog (*Canis lupus familiaris*). *Niger. J. Physiol. Sci.* 32: 153-158.

Patra, A., Singla, R. K., Mathur, M., Chaudhary, P. I., Singal, A., Asghar, A., Malhotra, V. (2021): Morphological and morphometric analysis of the orbital aperture and their correlation with age and gender: a retrospective digital radiographic study. *Cureus* 13:1 – 12.

Pasicka, E., Chroszcz, A., Janeczek, M., Mucha, A. (2012): Cranio-metric analysis of Early Medieval horses *Equus przewalskiif. Caballus (Linnaeus, 1758)* from chosen areas in Poland. *Turk. J. Vet. Anim. Sci.* 36:688-697.

Plavcan, J. M. (2012): Body Size, size variation, and Sexual Size Di-

morphism in early *Homo*. *CurrAnthropol.* 53, Supplement: S409-S423

Salvagno, L., Albarella, U. (2017): A morphometric system to distinguish sheep and goat postcranial bones. *PLoS ONE* 12(6): e0178543.

Sreekanth, C., Hema, L. (2019): Morphometric study of orbit in skull bones: direct measurement study. *Indian J Anat.* 9:45 – 53.

Tomczyk, J, Dwojacka, J. N., Zalewska, M., Niemirow, W., Olczyk, W. (2017): Sex estimation of upper long bones by selected measurements in a Radom (Poland) population from the 18th and 19th centuries AD. *AnthropolRev* 80: 287–300.

Xing, S., Gibbon, V., Clarke, R., Liu, W. (2012): Geometric morphometric analyses of orbit shape in Asian, African, and European human populations. *Anthropol Sci.* 121: 1–11.

Zichello, J.M., Baab, K. L., McNulty, K. P., Raxworthy, C. J., Steiper, M. (2018): Hominoid intraspecific cranial variation mirrors neutral genetic diversity. *PNAS*: 115: 11501–11506.

Corresponding Author

epy-m-l@fkh.unair.ac.id

Orcid: <https://orcid.org/0000-0car001-7110-0939>.

Table (1). Correlation Between *Aditus Orbitae* Variables of Kacang Goat

		SL	WZF	WFZ	LCRO	OW
SL	Pearson Correlation	1	0.64**	0.65**	0.16	0.70**
	Sig. (2-tailed)		0.00	0.00	0.51	0.00
WZF	Pearson Correlation	0.64**	1	0.51*	-0.09	0.43
	Sig. (2-tailed)	0.02		0.02	0.72	0.06
WFZ	Pearson Correlation	0.65**	0.51*	1	0.06	0.40
	Sig. (2-tailed)	0.02	0.02		0.81	0.08
LCRO	Pearson Correlation	0.18	-0.09	0.06	1	0.31
	Sig. (2-tailed)	0.51	0.72	0.81		0.18
OW	Pearson Correlation	0.70**	0.43	0.40	0.31	1
	Sig. (2-tailed)	0.01	0.06	0.08	0.18	

*Correlation is significant at 0.05 level and **0.01 level (2- tailed).

Table (2). Morphometrical of the *Aditus Orbitae* Between Female and Male of Kacang Goat

	Absolute Measurement ¹⁾						Ratio Measurement (X ¹ /SL) ¹⁾					
	Female			Male			Female			Male		
	(mm)			(mm)								
SL	211.92a	±	17.19	192.42b	±	3.68						
WZF	12.49 a	±	1.45	9.33 b	±	1.19	0.06a	±	0.01	0.05b	±	0.01
WFZ	9.26	±	1.77	7.98	±	1.18	0.04	±	0.01	0.04	±	0.01
LCRO	23.67ab	±	1.75	24.48a	±	2.20	0.11b	±	0.01	0.13a	±	0.01
OW	33.59 a	±	1.62	32.07 b	±	1.38	0.16	±	0.01	0.17	±	0.01

Test significant at p < 0.05

X¹: variable WZF, WFZ, LCRO and OW

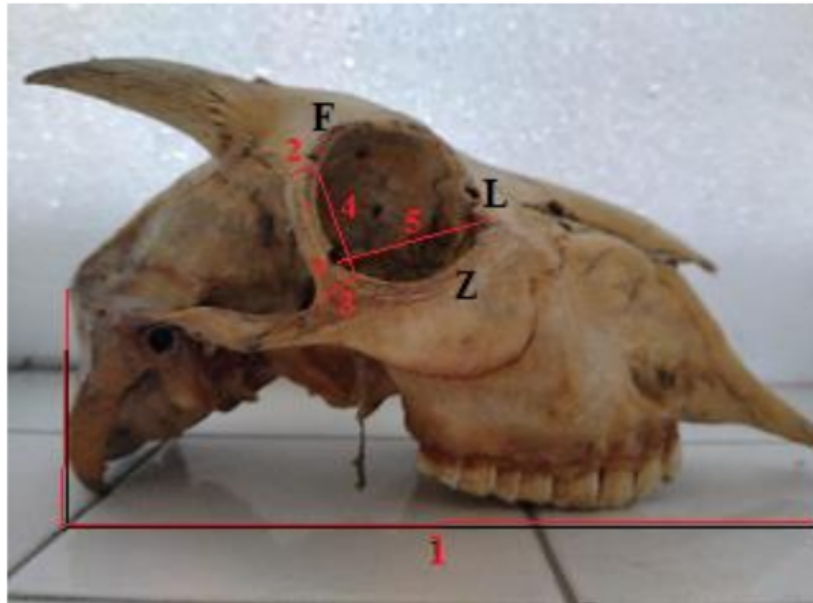


Fig (1): *Aditus orbitae* variables measured: 1 (**SL**) skull length; 2 (**WZF**) width of zygomatic process of frontal bone; 3 (**WFZ**) width of frontal process of the zygomatic bone; 4 (**LCRO**) the length (height) of caudal rima orbitae; 5. (**OW**) the great distance (width) of the *aditus orbitae*; * (Asterix) suturae of frontozygomatic bone. Z: zygomatic bone; L: lacrimal bone; F: frontal bone

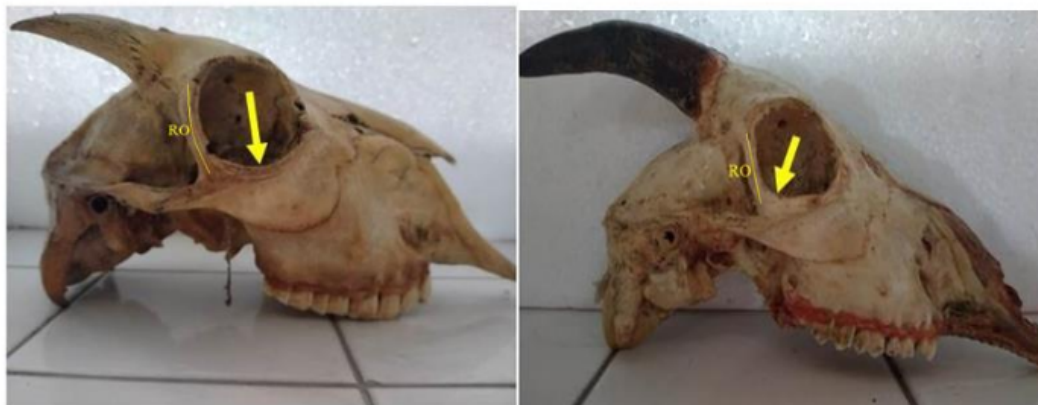

Fig (2): The lateral skull of Kacang goat. **Left:** Female goat. The circumference of aditus orbitae opening, is oval or elliptical, the zygomatic arch formed the ventral border of orbit as a curvature ridge and it lowest point placed in the middle of the margin (**arrow**), and (RO) the caudal orbit rim is curve in shape; **Right:** Male goat. The circumference of *aditus orbitae* opening is trapezoidal or rectangular, the zygomatic arch formed the margin almost horizontal along the ventral border, with the lowest point was located more caudally, below the sharp corner. (RO) the caudal orbit rim is straight incline.

Animals of this issue

Goat (*Capra aegagrus hircus*)



Kingdom: Animalia & Phylum: Chordata & Class: Mammalia & Order: Artiodactyla & Family: Bovidae & Subfamily: Caprinae & Genus: *Capra* & Species: *C. aegagrus* & Subspecies: *C.a. hircus*

Most goats naturally have two horns, of various shapes and sizes depending on the breed. Goats have horns unless they are "polled" (meaning, genetically hornless) or the horns have been removed, typically soon after birth. There have been incidents of polycerate goats (having as many as eight horns), although this is a genetic rarity thought to be inherited. Their horns are made of living bone surrounded by keratin and other proteins, and are used for defense, dominance, and territoriality.

Goats are ruminants. They have a four-chambered stomach consisting of the rumen, the reticulum, the omasum, and the abomasum. As with other mammal ruminants, they are even-toed ungulates. The females have an udder consisting of two teats, in contrast to cattle, which have four teats

Goats have horizontal, slit-shaped pupils. Because goats' irises are usually pale, their contrasting pupils are much more noticeable than in animals such as cattle, deer, most horses and many sheep, whose similarly horizontal pupils blend into a dark iris and sclera. This adaptation allows goats to see at least 320 degrees around their heads with no blind spot in front of them.

Source: Wikipedia, the free encyclopaedia

Quantitative and Qualitative Analysis of Sexual Dimorphism in Aditus Orbitae of Kacang Goat (*Capra aegragus hircus*)

ORIGINALITY REPORT

9%

SIMILARITY INDEX

7%

INTERNET SOURCES

6%

PUBLICATIONS

0%

STUDENT PAPERS

PRIMARY SOURCES

1	journals.plos.org Internet Source	2%
2	vetanat.com Internet Source	1%
3	Christopher A. King, M. Yaşar İçcan, Susan R. Loth. "Metric and Comparative Analysis of Sexual Dimorphism in the Thai Femur", <i>Journal of Forensic Sciences</i> , 1998 Publication	1%
4	mspace.lib.umanitoba.ca Internet Source	1%
5	discovery.ucl.ac.uk Internet Source	<1%
6	dspace.unza.zm Internet Source	<1%
7	Samuel Márquez, Anthony S. Pagano, Jeffrey H. Schwartz, Abigail Curtis, Bradley N. Delman, William Lawson, Jeffrey T. Laitman. "Toward Understanding the Mammalian Zygoma: Insights From Comparative Anatomy, Growth and	<1%

Development, and Morphometric Analysis", The Anatomical Record, 2017

Publication

8	journals.pan.pl Internet Source	<1 %
9	Lucas de Assis Ribeiro, Henrique Inhauser Riceti Magalhães, Adriano Ferreira Silva, Frederico Ozanam Carneiro e Silva. " Macroscopic, morphometric and tomographic features of the mandible of the collared peccary () applied to clinical morpho - physiology and imaging ", The Anatomical Record, 2022 Publication	<1 %
10	hydra.hull.ac.uk Internet Source	<1 %
11	jwpr.science-line.com Internet Source	<1 %
12	researchspace.ukzn.ac.za Internet Source	<1 %
13	www.ircobi.org Internet Source	<1 %
14	R. K. Karki, R. Bhandari, S. Karki, D. K. Shah. "Sexual Dimorphism of Greater Sciatic Notch among Nepalese Population by Three Dimensional CT Images of Pelvis", Kathmandu University Medical Journal, 2020 Publication	<1 %

15 Vineeta Saini. "Secular trends in cranial chord variables: a study of changes in sexual dimorphism of the North Indian population during 1954–2011", *Annals of Human Biology*, 2019

Publication

<1 %

16 diglib.tugraz.at

Internet Source

<1 %

17 Mahmoud Mansour, Ray Wilhite, Joe Rowe. "Guide to Ruminant Anatomy", Wiley, 2017

Publication

<1 %

18 Tefik Jashari, Sokol Duro, Ozan Gündemir, Tomasz Szara, Vlatko Ilieski, Dashmir Mamuti, Om Prakash Choudhary. "Morphology, morphometry and some aspects of clinical anatomy in the skull and mandible of Sharri sheep", *Biologia*, 2021

Publication

<1 %

19 Kristen Niemann, Lelika Lazarus, Carmen O. Rennie. "Developmental changes of the facial skeleton from birth to 18 years within a South African cohort (A computed tomography study)", *Journal of Forensic and Legal Medicine*, 2021

Publication

<1 %

Exclude quotes Off

Exclude matches Off

Exclude bibliography On