

Volume - 16

No. 1

January-2023

ISSN: 0972-8988

EISSN: 2231-0916



NAAS Rating : 5.71

Indexed in ESCI-Thomson Reuters, PubMed,  
PubMed Central, DOAJ, Scopus, CABI, CAS etc.

---

---

# Veterinary World

Open access and peer reviewed journal

---

---



**Editorial office**

Veterinary World,  
Star, Gulshan Park,  
NH-8A, Chandrapur Road,  
Wankaner. 363621,  
Dist. Morbi, Gujarat, India

Website: [www.veterinaryworld.org](http://www.veterinaryworld.org)

E-mail: [editorveterinaryworld@gmail.com](mailto:editorveterinaryworld@gmail.com)

# Veterinary World

**Editorial Office:** Veterinary World, Star, Gulshan Park, NH-8A, Chandrapur Road, Wankaner - 363621, Dist. 1\lorbi, Gujarat, India

ISSN: 0972-8988, EISSN: 2231-0916, [www.veterinaryvworld.org](http://www.veterinaryvworld.org)

## Editor-in-Chief

Anjum V. Sherasiya - Ex-Veterinary Officer, Department of Animal Husbandry, Gujarat State, India

## Associate Editors

Shambhunath Choudhary - Department of Biomedical & Diagnostic Sciences, College of Veterinary Medicine, The University of Tennessee, 2407 River Drive, Room A 201, Knoxville, TN 37996, U.S.A.

Suresh H, Basagoudanavar - FMD Vaccine Research Laboratory, IVRI, Bangalore, Bangalore- 560024, Karnataka, India

## Editorial board

R. G. Jani - Ex-Coordinator Wildlife Health, Western Region Centre, Indo-US Project, Department of Veterinary Medicine, Veterinary College, Anand - 388001, Gujarat, India

G. N. Gongal - Technical Officer, WHO South -East Asia Regional Office, New Delhi -110002, India

Ranganath Mamidi - Dr. Julian E Stelzer's Lab, Department of Physiology & Biophysics, Medical School, Case Western Reserve University, Cleveland, OH - 44106, U.S.A.

Md. Tanvir Rahman - Department of Microbiology and Hygiene, Faculty of Veterinary Science, Bangladesh Agricultural University, Mymensingh-2202, Bangladesh

Deepnala Aganaral - Cancer Prevention Laboratory, Pennington Biomedical Research Center, Baton Rouge, LA, USA.

Foud Kasim Mohammad - Professor, Department of Pharmacology & Toxicology, Vice President for Administrative & Financial Affairs, University of Mosul, P.O. Box 11136, Mosul, Iraq

Abdel-Baset Nasr Sayed Ahmed - Professor and Head, Department of Animal Nutrition and Clinical Nutrition, Faculty of Veterinary Medicine, Assiut University, Assiut, Egypt

Nicole Bore' - Department of Pathology, Vetsuisse Faculty, University of Zurich, CH-8057 Zurich, Switzerland

B. A. Lubisi - Virology, MED Programme, ARC - Onderstepoort Veterinary Institute, No. 100 Old Scutpan Road, Onderstepoort, Tshwane, 0110, South Africa

Kumar Venkitanarayan - Associate Professor, Graduate Programs Chair, Honors and Pre-Vet Programs Advisor, Department of Animal Science, University of Connecticut, Storrs, CT 06269, U.S.A.

Kemin Xu - Department of Veterinary Medicine, University of Maryland, College Park College Park, MD, 20742, U.S.A.

Vassilis Papatsiros - Faculty of Veterinary Medicine, Department of Medicine (Porcine Medicine), University of Thessaly, Thessaly, Greece

Mathias Devreese - Laboratory of Pharmacology and Toxicology, Faculty of Veterinary Medicine, Ghent University, Belgium Surmeet Sharma - Edmonton North Animal Hospital, Edmonton, Alberta, T5X 3Y7, Canada

K. P. Singh - School of Medicine and Dentistry, University of Rochester, Department of Environmental Medicine, Room: 4- 5820, 601 Elmwood Avenue, Box-EHSC, Rochester, New York-14620, U.S.A.

Raj Mohan Raja Muthiah - Massachusetts General Hospital, Harvard Medical School, Boston, Massachusetts, U.S.A. Ashok

K. Chockalingam - Division of Applied Regulatory Science, U.S. Food and Drug Administration, 10903, New Hampshire Avenue, Silver Spring, Maryland 20993, U.S.A.

Ashutosh Wadhwa - Poxvirus and Rabies Branch, Division of High-Consequence Pathogens and Pathology, National Center for Emerging and Zoonotic Infectious Diseases, Centers for Disease Control and Prevention, 1600 Clifton Road, NE, Mail Stop G33, Atlanta, GA 30 333, U.S.A.

Luiz Otavio Pereira Carvaiho - Laboratory of Immunomodulation and Protozoology, Oswaldo Cruz Institute, Ministry of Health (Brazil), Pavilhao "108"-- Sala: 09, Av. Brasil, 4365 - Manguinhos, Rio de Janeiro a R3, CEP: 21040-360, Brazil.

Mallikarjun Bidarimath - Cornell Stem Cell Program, Department of Biomedical Sciences, T2-012 Veterinary Research Tower, Cornell University, College of Veterinary Medicine, Ithaca, NY 14853-6401, USA.

**Ratings of Veterinary World:** NAAS - National Academy of Agricultural Sciences - 5.71, Scimago Journal Rank -0.284, Citescore - 0.57, SNIP - Source Normalized Impact per Paper - 0.570

## Indexing and abstracting

Academic Journals Database, AGORA, AGRICOLA, AGRIS, CABI, CAS, DOAJ, EBSCO, EMBASE, ESCI - Thomson Reuters, Gale, Goggle Scholar, HINARI, Indian Animal Science Abstracts, Indian Science Abstracts, JournalSeek, Open 3-gate, ProQuest, PubMed, PubMed Central, SCOPUS, TEEAL

## Publisher: Veterinary World

Veterinary World is an open access journal, each issue available free of cost at [www.veterinaryvworld.org](http://www.veterinaryvworld.org).

We accept online submission only. For more information regarding submission and publication charges, please visit [www.veterinaryworld.org](http://www.veterinaryworld.org)

**Rs. 8000 for Indian/USD 250 for Abroad per copy**

Printed and Published by Dr. Anjum Sherasiya on behalf of Veterinary World. Printed and Published at Star, Gulshan Park, N.H. 8A, Chandrapur Road, Wankaner-363621, Dist. Morbi, Gujarat, India.  
Editor: Dr. Anjum V. Sherasiya

---

# Veterinary World

---

ISSN: 0972-8988, EISSN: 2231-0916, [www.veterinaryworld.org](http://www.veterinaryworld.org)

---

Volume-16

No.1

January-2023

---

The articles in Veterinary World are open access articles licensed under the terms of the Creative Commons Attribution 4.0 International License (<http://creativecommons.org/licenses/by/4.0/>), which permits unrestricted use, distribution, and reproduction in any medium, provided you give appropriate credit to the original author(s) and the source, provide a link to the Creative Commons license, and indicate if changes were made. The Creative Commons Public Domain Dedication waiver (<http://creativecommons.org/publicdomain/zero/1.0/>) applies to the data made available in this article, unless otherwise stated.

---

Research (Published online: 03-01-2023)

1. Distribution pattern of antibiotic resistance genes in *Escherichia coli* isolated from colibacillosis cases in broiler farms of Egypt

Mona A. A. Abdel-Rahman, Engy A. Hamed, May F. Abdelaty, Hend K. Sorour, Heba Badr, Wafaa M. Hassan, Azhar G. Shalaby, Ahmed Abd-Elhalem Mohamed, Mohamed A. Soliman, and Heba Roshdy  
Veterinary World, 16(1): 1-11

Research (Published online: 04-01-2023)

2. Behavioral responses to baited enclosure method that activates habituation in stray dogs  
Sumpun Thammacharoen, Sapon Semsirboon, Visara Chit-Opas, Phak-Anong Tangcharoensin, Kran Nilkachatarn, and Narongsak Chaiyabutr

Veterinary World, 16(1): 12-17

Research (Published online: 06-01-2023)

3. Antifungal activity of silver nanoparticles prepared using *Aloe vera* extract against *Candida albicans*  
Mbarga Manga Joseph Arsene, Podoprigora Irina Viktorovna, Marukhlenko Alla, Morozova Mariya, Senyagin Alexander Nikolaevitch, Anyutoulou Kitio Linda Davares, Mumrova Evgenia Yurievna, Manar Rehailla, Ada Arsene Gabin, Kulikova A. Alekseevna, Yashina Natalia Vyacheslavovna, Zhigunova Anna Vladimirovna, Orlova Svetlana, and Das Milana

Veterinary World, 16(1): 18-26

Research (Published online: 07-01-2023)

4. Growth performance, meat quality, and blood characteristics of finisher crossbred pigs fed diets supplemented with different levels of green tea (*Camellia sinensis*) by-products  
Nguyen Cong Oanh, Cu Thi Thien Thu, Nguyen Thi Hong, Nguyen Thi Phuong Giang, Jean-Luc Hornick, and Pham Kim Dang

Veterinary World, 16(1): 27-34

Research (Published online: 09-01-2023)

5. Economic and value chain analysis to support an investigation and risk mitigation efforts on Marek's disease in layers in the southern part of Thailand

Tosapol Dejyong, Karoon Chanachai, Tippawon Prarakamawongsa, Wandee Kongkaew, Anyarat Thiptara, Taweesak Songserm, Theera Rukkwamsuk, Damian Tago Pacheco, and Waraphon Phimpraphai

Veterinary World, 16(1): 35-45

Review (Published online: 10-01-2023)

6. A review of new emerging livestock-associated methicillin-resistant *Staphylococcus aureus* from pig farms  
Aswin Rafif Khairullah, Shendy Canadya Kurniawan, Mustofa Helmi Effendi, Sri Agus Sudjarwo, Sancaka Chasyer Ramandinianto, Agus Widodo, Katty Hendriana Priscilia Riwu, Otto Sahat Martua Silaen, and Saifur Rehman

Veterinary World, 16(1): 46-58

Research (Published online: 10-01-2023)

7. Pathogenicity and pathogenesis of a recent highly pathogenic avian influenza subtype H5N8 in mule ducklings in Egypt

Mahmoud M. Abotaleb, Ahlam Mourad, Esraa Fouad, Walied Abdo, and Samir A. Nassif  
Veterinary World, 16(1): 59-67

---

Research (Published online: 10-01-2023)

8. Comparative protection of small ruminants against *Mannheimia haemolytica* infection by inactivated bacterin and toxoid vaccines

Dounia Bkiri, Soufiane Elmejdoub, Zahra Bamouh, Ouafaa Fassi Fihri, and Mehdi El-Harrak  
Veterinary World, 16(1): 68-75

Research (Published online: 11-01-2023)

9. Phylogenetic analysis of feline infectious peritonitis virus, feline enteric coronavirus, and severe acute respiratory syndrome coronavirus 2 of cats in Surabaya, Indonesia

Eduardus Bimo Aksono, Kania Rifa Iradatya, Teguh Hari Sucipto, Nur Syamsiatul Fajar, and Wiwik Misaco Yuniarti

Veterinary World, 16(1): 76-81

Research (Published online: 11-01-2023)

10. Ameliorating effect of *Mucuna pruriens* seed extract on sodium arsenite-induced testicular toxicity and hepato-renal histopathology in rats

Preethi Lavina Concessao, Kurady Laxminarayana Bairy, and Archana Parampalli Raghavendra

Veterinary World, 16(1): 82-93

Research (Published online: 12-01-2023)

11. First study on microscopic and molecular detection of *Acanthocheilonema reconditum* and *Leishmania infantum* coinfection in dogs in Southwest Colombia

Ruben Dario Perez-Ramirez, Rodrigo Lugo-Vargas, Julieth Michel Petano-Duque, Juan Sebastian Cruz-Mendez, and Iang Schroniltgen Rondon-Barragan

Veterinary World, 16(1): 94-103

Research (Published online: 12-01-2023)

12. The use of ultrasonographic adrenal dimensions and the adrenal dimension-to-aorta ratio in the diagnosis of benign and malignant adrenal diseases in dogs

Naparee Srisowanna, Chutimon Thanaboonnipat, Sirinun Pisamai, Kiatpichet Komin, and Nan Choisunirachon

Veterinary World, 16(1): 104-110

Research (Published online: 16-01-2023)

13. The impact of farm practices and wild carriers on white spot disease in marine shrimp in Rayong Province, Thailand

Sompit Yaemkasem, Jiraporn Promchairat, Pinchakorn Srithongkhum, Napawan Paungsroy and Chaithep Poolkhet

Veterinary World, 16(1): 111-117




Research (Published online: 16-01-2023)

14. First meta-analysis study of cholinesterase inhibition in experimental animals by organophosphate or carbamate insecticides under the influence of diphenhydramine

Fouad K. Mohammad, Hishyar M. S. Garmavy, Ammar A. Mohammed, and Hussein M. Rashid

Veterinary World, 16(1): 118-125

# Phylogenetic analysis of feline infectious peritonitis virus, feline enteric coronavirus, and severe acute respiratory syndrome coronavirus 2 of cats in Surabaya, Indonesia

Eduardus Bimo Aksono<sup>1,2</sup> , Kania Rifa Iradatya<sup>1</sup>, Teguh Hari Sucipto<sup>3</sup> , Nur Syamsiatul Fajar<sup>3</sup>, and  
Wiwik Misaco Yuniarti<sup>1</sup> 

1. Department of Veterinary Medicine, Faculty of Veterinary Medicine, Universitas Airlangga, Surabaya 60115, Indonesia; 2. Natural Science and Engineering Institute, Universitas Airlangga, Surabaya 60115, Indonesia; 3. Institute of Tropical Disease, Universitas Airlangga, Surabaya 60115, Indonesia.

**Corresponding author:** Eduardus Bimo Aksono, e-mail: [eduardus-b-a-h@fkh.unair.ac.id](mailto:eduardus-b-a-h@fkh.unair.ac.id)

**Co-authors:** KRI: [kaniathe98@gmail.com](mailto:kaniathe98@gmail.com), THS: [teguhharisucipto@staf.unair.ac.id](mailto:teguhharisucipto@staf.unair.ac.id), NSF: [ns\\_fajar14@yahoo.co.id](mailto:ns_fajar14@yahoo.co.id), WMY: [wiwikmisaco@yahoo.com](mailto:wiwikmisaco@yahoo.com)

**Received:** 31-08-2022, **Accepted:** 23-11-2022, **Published online:** 11-01-2023

**doi:** [www.doi.org/10.14202/vetworld.2023.76-81](http://www.doi.org/10.14202/vetworld.2023.76-81) **How to cite this article:** Aksono EB, Iradatya KR, Sucipto TH, Fajar NS, and Yuniarti WM (2023) Phylogenetic analysis of feline infectious peritonitis virus, feline enteric coronavirus, and severe acute respiratory syndrome coronavirus 2 of cats in Surabaya, Indonesia, *Veterinary World*, 16(1): 76–81.

## Abstract

**Background and Aim:** Questions about the origin of coronavirus and its introduction to human beings have persisted. The detection of a variety of coronavirus related to severe acute respiratory syndrome coronavirus 2 (SARS-CoV-2) in bats and pangolins led to the widespread belief that SARS-CoV-2 originated from wild animals and was introduced to humans through an intermediate animal. Thus, coronaviruses from animals, especially those in close contact with humans, have attracted particular attention. This study aimed to phylogenetically analyze feline enteric coronavirus (FECV), feline infectious peritonitis virus (FIPV), and SARS-CoV-2 found in cats in Surabaya amid the COVID-19 pandemic. The results will provide a basis for developing basic preventive and pet healthcare strategies.

**Materials and Methods:** Samples were collected on physical examinations of domestic and Persian cats (males and females) from March 2020 to March 2022. Samples were collected if there were clinical signs of FECV and FIP based on a veterinarian's diagnosis in several clinics in Surabaya. Laboratory examinations in this study were performed by reverse-transcription-polymerase chain reaction (RT-PCR) with primers for conserved regions of FIP and FECV, DNA sequencing was performed with Applied Biosystem Genetic Analyzer protocol, homology analysis was performed using Basic Local Alignment Search Tool NCBI, phylogenetic analysis was carried out with BioEdit 7.2 software, and sequences were compared with references from GenBank.

**Results:** Samples were collected from ten cats showing clinical signs of FECV and FIP, based on a veterinarian's diagnosis. On RT-PCR examinations performed with specifically designed primers for detecting FIPV in blood, peritoneal fluid, and feces, only one sample showed positivity for FIPV (1/10), namely, a peritoneal sample from a domestic cat in Surabaya. Homology analysis of the FIPV Surabaya isolate showed 98% similarity with FECV and FIPV reported in GenBank (MT444152 and DQ010921, respectively). In phylogenetic analysis, the FIPV Surabaya isolate was clustered together with SARS-CoV-2 of Clade A (MT198653) from Spain, SARS-CoV-2 Clade A (MT192765) from the USA, SARS-CoV-2 Clade D (039888) from the USA, and SARS-CoV-2 Clade F (MT020781) from Finland.

**Conclusion:** This study revealed a relationship between the SARS-CoV-2 viruses that infect humans and cats (FECV), which is an important finding for those keeping cats at home. However, this finding requires further comprehensive support from laboratory studies.

**Keywords:** cats, feline coronavirus, feline infectious peritonitis virus, phylogenetic, severe acute respiratory syndrome coronavirus 2, Surabaya.

## Introduction

The coronavirus disease 2019 (COVID-19) pandemic has now lasted for 3 years, but until now there are still reported cases every day. Besides being able to infect humans, this virus can also infect pets such as cats, for example, Feline infectious peritonitis virus

(FIPV). This virus causes a fatal feline disease and is a variant of feline enteric coronavirus (FECV). Both FECV-related disease and severe acute respiratory syndrome coronavirus 2 (SARS-CoV-2) are diseases caused by coronavirus, which have certain similarities. Both are highly transmissible, for which similar infection preventive measures have been instigated by isolating infected patients. Some anti-inflammatory compounds and antiviruses also show similar efficacy against them. However, some differences have also been identified in terms of virus biological character, targeted cells, pathogenesis, and clinical signs. The similarities and differences between FECV and SARS-CoV-2 can be used to obtain a deeper understanding

Copyright: Aksono, *et al.* Open Access. This article is distributed under the terms of the Creative Commons Attribution 4.0 International License (<http://creativecommons.org/licenses/by/4.0/>), which permits unrestricted use, distribution, and reproduction in any medium, provided you give appropriate credit to the original author(s) and the source, provide a link to the Creative Commons license, and indicate if changes were made. The Creative Commons Public Domain Dedication waiver (<http://creativecommons.org/publicdomain/zero/1.0/>) applies to the data made available in this article, unless otherwise stated.



of cell biological aspects and host–virus interaction, which could aid the development of preventive strategies and effective therapies for FIP and COVID-19. It is highly possible that FECV and SARS-CoV-2 will interact further in the future due to humans and their pet cats living in close proximity [1]. Furthermore, amid the COVID-19 pandemic, cat owners are worried about their pets being a source of infection, considering that the number of FIP cases has also increased.

Feline coronavirus and SARS-CoV-2 are single-stranded RNA viruses belonging to the order Nidovirales and family Coronaviridae. Feline coronavirus was originally classified into the genus *Alphacoronavirus* and SARS-CoV-2 into the genus *Betacoronavirus*. Feline coronavirus has a different genomic structure than SARS-CoV-2, with 5′-leader-UTR-replicase-S (Spike)-E (Envelope)-M (Membrane)-N (Nucleocapsid)-3′UTR-poly(A) tail and genes interspersed within the structural genes at the 3′-end of the genome.

Practitioners of veterinary medicine have long been familiar with coronavirus because its species variants (CoV) can cause various health problems in wild animals such as bats and birds, as well as in domestic animals such as pigs, cows, cats, and dogs [1–4]. An infectious peritonitis disease found in cat populations, especially in those under 2 years old, is FECV disease [5]. This disease shows non-specific clinical signs and laboratory changes, making its diagnosis a challenge for vets and researchers. Etiologically, feline coronavirus (FCoV) has two pathotypes. The first is the FECV pathotype, which is commonly found and highly contagious. It has a transmission rate of almost 100%, although most cats are asymptomatic or exhibit only mild diarrhea. The major transmission route is fecal-oral, through FECV-contaminated feces or food [3, 6–8]. The second pathotype is FIPV. This pathotype occurs not through contaminated food or fecal transmission but from mutations of some avirulent FECV that is generally non-infectious. However, such mutation leads to a fatal disease in cat populations, FIP [8, 9]. The connection between FECV and FIPV has been debated. From genetic and experimental evidence in animals, it has been shown that FIPV occurs as a mutated form of FECV in the continuously exposed intestinal tract of cats. However, the gene whose mutation is associated with the shift from FECV to FIPV remains unknown.

In Surabaya, Indonesia, a suspected case of FIP in a Turkish Angora was reported, which was diagnosed based on clinical, anatomical pathology, and histopathological signs [10]. Cats are rarely infected by FIPV through direct contact. Instead, this deadly disease is generally derived from FECV mutating into FIPV. One clinical sign of this disease is digestive problems in cats. Feline infectious peritonitis infects Persian and domestic cats. In terms of the survival of cats infected by FIP, this can range from 1 week to 1 year. Unfortunately, most diagnostic kits developed to date cannot differentiate between FECV and FIPV-related disease, making it difficult for vets to diagnose FIP,

especially in cats without effusion from the body cavity. Against this background, it is important to perform research to aid the definitive antemortem diagnosis of FIPV in infected cat populations [8]. Chang *et al.* [11] and Brown *et al.* [12] suggested that five amino acid residues in the matrix (M) protein can be used to differentiate virulent FIPV from avirulent FECV; meanwhile, Felten and Hartmann [8] reported that a single-nucleotide polymorphism in the S gene is found only in cats with FIP, but not in healthy cats with FECV.

Questions about the origin of coronavirus and its introduction to human beings have persisted. The detection of a variety of coronavirus related to SARS-CoV-2 in bats and pangolins led to the widespread belief that SARS-CoV-2 originated from wild animals and was introduced to humans through an intermediate animal. Thus, coronaviruses from animals, especially those in close contact with humans, have attracted particular attention.

This study aimed to phylogenetically analyze FECV, FIPV, and SARS-CoV-2 found in cats in Surabaya amid the COVID-19 pandemic. The results will provide a basis for developing basic preventive and pet healthcare strategies.

## Materials and Methods

### Ethical approval

This study was approved for animal experimentation by the Commission of Research Ethics of the Faculty of Veterinary Medicine Universitas Airlangga (No. 1. KE. 014.01.2020).

### Study period and location

This study was conducted from the beginning of the COVID-19 pandemic, from March 2020 to March 2022, using samples from 10 domestic or Persian cats, male or female, of any age. All the cats showed clinical signs of FECV and FIP based on a veterinarian's diagnosis in several clinics in Surabaya, Indonesia. The polymerase chain reaction (PCR) examinations, sequencing, homology, and phylogenetic analysis were performed at the Institute of Tropical Disease Universitas Airlangga and the Institute of Natural Sciences and Engineering Surabaya.

### Sampling

Three different sample types were used in this study (blood, n = 10; peritoneal fluid, n = 10; feces, n = 10). A primer pair for a conserved region was specifically designed to detect FIPV and FECV (F2: 5′-TCTTGCTAACTGGAAGCTTCAGCTGG-3′, R2: 5′-TGACGCGTTGTCCTGTGTG-3′).

A total of 1 or 2 mL of cat blood was collected and put into a tube with ethylenediaminetetraacetic acid. The peritoneal fluid samples were stored in a sterile tube with a screw cap. Meanwhile, 400 μL of PBS was added to 25 mg of feces and mixed with a vortex mixer. It was then centrifuged at 15,300× g for 3 min. The obtained supernatant was then used for the extraction of RNA using the QIAamp RNA Viral Mini

Kit (Qiagen, Hilden, Germany), in accordance with the manufacturer's procedure.

#### Reverse transcription-polymerase chain reaction (RT-PCR) and DNA visualization

The reverse-transcription reaction followed the protocols of ReverTra Ace quantitative PCR RT Master kit with gDNA Remover from Toyobo (Germany). A total of 2 µL of DN Master was supplemented with gDNA Remover, 1 µL of Random Primer, 2 µL of nuclease-free water, 2 µL of 5× reverse transcriptase Master Mix II, and 3 µL of RNA samples and mixed in a reaction volume of 10 µL. This mixture was then incubated at 65°C for 1 min, at 37°C for 15 min, at 42°C for 30 min, and at 98°C for 5 min.

After the RT reaction, amplification proceeded with a mixture of 12.5 µL of 2× PCR Master Mix (Intron), 1 µL of F2 (10-nmol forward primer), 1 µL of R2 (10-nmol reverse primer), 2.5 µL of nuclease-free water, and 3 µL of cDNA sample.

The polymerase chain reaction was conducted with a Bioer thermal cycler. The protocol consisted of pre-denaturation at 94°C for 5 min; 40 cycles of denaturation at 94°C for 30 s, annealing at 58°C for 30 s, and extension at 72°C for 30 s; and final extension at 72°C for 5 min.

The output from PCR was subjected to electrophoresis with a gel containing 2% agarose and TBE 1×

(Promega, Madison, USA), as well as RedSafe (iNtRON Biotechnology, Gyeonggi-do, Republic of Korea) as an agarose gel dye. Electrophoresis was performed with a Mupid-eXu apparatus (Advance) at 100 V for 35 min. NexMark 100 bp DNA markers were used as molecular weight markers.

#### DNA Sequencing and Phylogenetic Analysis

Peritoneal fluid showing a positive PCR result was then purified using QIAquick DNA Purification Kit (Qiagen). Sequencing was then performed in accordance with the Applied Biosystem Genetic Analyzer protocol. Homology analysis was conducted with a positive sample at <https://blast.ncbi.nlm.nih.gov/Blast.cgi>. Phylogenetic analysis of FIPV Surabaya isolate was performed using reference sequences from GenBank: FCoV (MT444152), FIPV (DQ010921), and SARS-CoV-2, including MT135041 (China), MT135042 (China), MT135044 (China), MN994467 (USA), MT152824 (USA), MT163717 (USA), MT198652 (Spain), MT198653 (Spain), MT039888 (USA), MT020781 (Finland), MT192765 (USA), LC529905 (Japan), LC529905 (Japan), MT066156 (Italy), MT007544 (Australia), and MT039890 (Republic of Korea).

#### Results

Table-1 shows the samples from 10 cats suspected of having FECV and FIP. In terms of their breeds, there

**Table-1:** The clinical sign and RT-PCR examinations from samples of domestic and Persian cats for FIPV Surabaya isolate amid the COVID-19 pandemic.

Case number	Clinical signs	Specimen	RT-PCR
Domestic 1: Male, Kitten, Wet-type	Diarrhea, anorexia, pale mucous	Blood	Negative
	Membranes, pyrexia, dyspnea	Peritoneal liquid	Negative
	Abdominal distension, weight loss	Feces	Negative
Domestic 2: Female, Mature, Wet-type	Diarrhea, anorexia, pale mucous	Blood	Negative
	Membranes, pyrexia, dyspnea	Peritoneal liquid	Negative
	Abdominal distension, weight loss	Feces	Negative
Domestic 3: Male, Kitten, Wet-type	Diarrhea, anorexia, pale mucous	Blood	Negative
	Membranes, pyrexia, dyspnea	Peritoneal liquid	Negative
	Abdominal distension, weight loss	Feces	Negative
Domestic 4: Male, Senior, Wet-type	Diarrhea, anorexia, pale mucous	Blood	Negative
	Membranes, pyrexia, dyspnea	Peritoneal liquid	Negative
	Abdominal distension, weight loss	Feces	Negative
Domestic 5: Male, Kitten, Wet-type	Diarrhea, anorexia, pale mucous	Blood	Negative
	Membranes, pyrexia, dyspnea	Peritoneal liquid	Positive
	Abdominal distension, weight loss	Feces	Negative
Domestic 6: Male, Kitten, Dry-type	Diarrhea, anorexia, pale mucous	Blood	Negative
	Membranes, pyrexia, dyspnea	Peritoneal liquid	Negative
	Abdominal distension, weight loss	Feces	Negative
Persian 7: Female, Junior, Dry-type	Diarrhea, anorexia, pale mucous	Blood	Negative
	Membranes, pyrexia, dyspnea	Peritoneal liquid	Negative
	Abdominal distension, weight loss	Feces	Negative
Persian 8: Female, Kitten, Dry-type	Diarrhea, anorexia, pale mucous	Blood	Negative
	Membranes, pyrexia, Dynea	Peritoneal liquid	Negative
	Abdominal distension, weight loss	Feces	Negative
Persian 9: Male, Kitten, Wet-type	Diarrhea, anorexia, pale mucous	Blood	Negative
	Membranes, pyrexia, dyspnea	Peritoneal liquid	Negative
	Abdominal distension, weight loss	Feces	Negative
Persian 10: Male, Junior, Wet-type	Diarrhea, anorexia, pale mucous	Blood	Negative
	Membranes, pyrexia, dyspnea	Peritoneal liquid	Negative
	Abdominal distension, weight loss	Feces	Negative

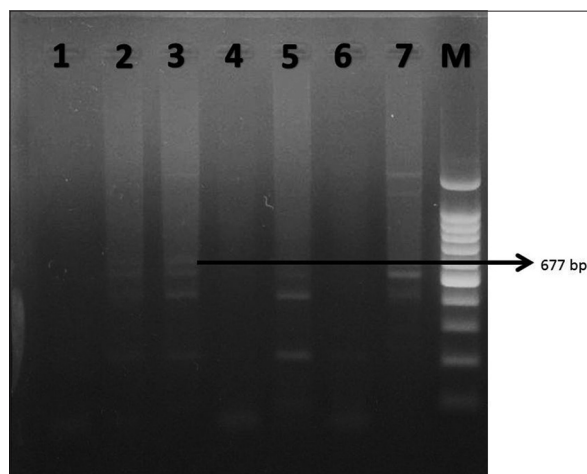
RT-PCR=Reverse transcription-polymerase chain reaction, FIPV=Feline infectious peritonitis virus, COVID-19=Coronavirus disease 2019

were six domestic cats and four Persian cats. In terms of the FIP types, seven cats had the FIP wet-type and three had the FIP Dry-type. Regarding their ages, six were kittens (0–6 months), one was a mature cat (7–10 years), two were junior cats (7 months–2 years), and one was a senior cat (11–14 years). Moreover, seven cats were male and three were female. In the physical examinations, all cats showed clinical signs of FECV and FIP, including diarrhea, anorexia, pale mucous membranes, pyrexia, dyspnea, abdominal distension, and weight loss. Reverse transcription-polymerase chain reaction (RT-PCR) examinations of blood, peritoneal liquid, and fecal samples with specifically designed primers for conserved regions of FIPV and FECV revealed positivity for FIPV (1/10) in one sample, in the Figure-1 shown DNA band at 677 bp, which was from peritoneal fluid from a domestic cat. This low isolation rate was believed to be associated with poor storage conditions for the samples during transport.

The PCR product was purified, after which homology and phylogenetic analyses were performed. In the homology analysis, the FIPV Surabaya isolate was shown to be 98% homologous to FCoV (MT444152) and FIPV (DQ010921) reported in GenBank. A phylogenetic tree of the FIPV Surabaya sample along with samples of FCoV, FIPV, and SARS-CoV-2 from humans (Clades A–I) was constructed. In this tree, the positive sample coded Sby\_FIP was clustered together with SARS-CoV-2 Clade A (MT198653) from Spain, SARS-CoV-2 Clade A (MT192765) from the USA, SARS-CoV-2 Clade D (MT039888) from the USA, and SARS-CoV-2 Clade F (MT020781) from Finland (Figure-2).

## Discussion

In the early period after the discovery of FECV, many of its clinical signs were difficult to identify. This was similar to the case in the COVID-19 pandemic



**Figure-1:** Reverse transcription-polymerase chain reaction electrophoresis result for feline infectious peritonitis virus. M-Marker DNA 100 bp. 1-Control negative; 2-Peritoneal liquid (negative); 3-Peritoneal liquid (positive); 4-Blood (negative); 5-Blood (negative); 6-Feces (negative); and 7-Feces (negative).

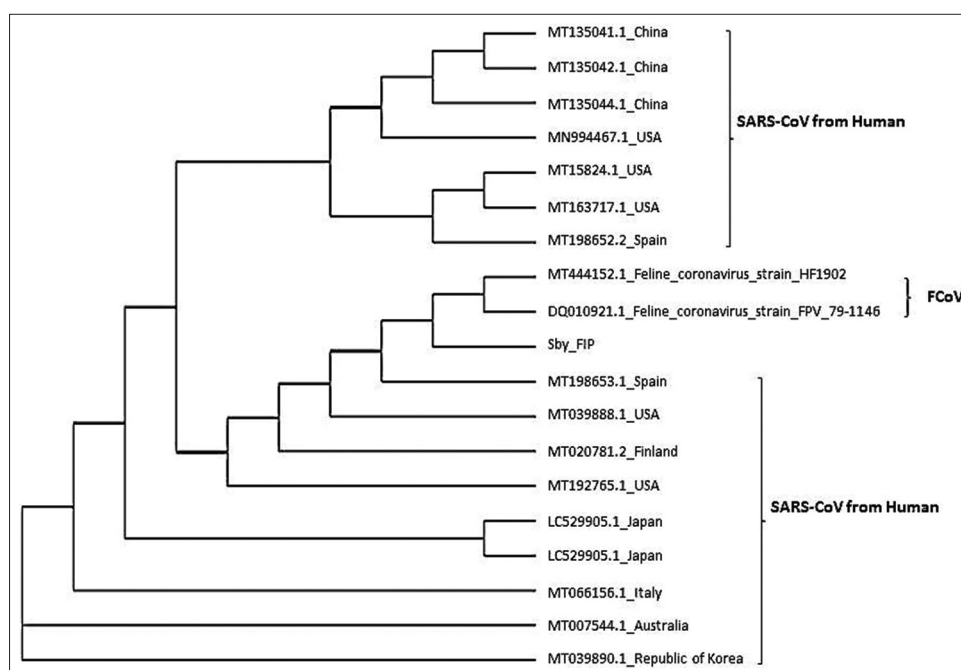
caused by SARS-CoV-2. Many questions remain about the epidemiological pathogenesis, transmission, and treatment of SARS-CoV-2. Although no reports about FECV cases during the COVID-19 pandemic in Surabaya have been published, cases of suspected FECV with FIP among domestic, Persian, and hybrid cats have increased, raising concerns among pet owners that their cats would become a source of coronavirus transmission. This anxiety about the spread of FECV and SARS-CoV-2 is often associated with these conditions initially having mild clinical signs or even being asymptomatic but potentially quickly leading to systemic disease and even death [13–15].

Infection of FCoV in cats is generally related to FECV disease and it is deemed a causative agent of mild gastrointestinal disease, being rarely encountered clinically. However, FCoV infection can deteriorate into a severe and systemic condition that leads to death, which is known as FIP and caused by FIPV [14, 15]. FIPV differs from FECV due to its ability to infect and replicate in monocytes and macrophages [14, 16] and its ability to trigger systemic inflammation. Based on FIPV's general clinical signs, there are two types. The effusive type or wet-type can rapidly progress and often causes the accumulation of high protein exudate in the abdominal cavity or thorax. Meanwhile, the non-effusive or dry-type can affect many organ systems, but generally shows neurological and ocular signs. Non-effusive FIP generally involves a chronic disease, which is less common than effusive FIP. Feline coronavirus can also be classified into two serotypes, Type I and Type II, based on major differences in their virus protein spike, which influences receptor binding and antibody response [14, 17]. The receptor of Type II FECV is feline aminopeptidase N [14, 18], while the receptor of Type I virus has yet to be identified. Type I FECV contributes to most cases of FIP [19].

The results of this study show that the FECV sample in Surabaya has become FIP. This was proved by the RT-PCR examinations with specifically designed primers for FIPV, which resulted in one sample being positive for FIPV (10%). This sample was from a domestic male kitten aged younger than 6 months with wet-type FIP. This is in line with the findings of Norris *et al.* [20] and Riemer *et al.* [5], who reported small-scale studies supporting an association between male sex and FIP development in cats. Likewise, in COVID-19, studies by Peckham *et al.* [21] and Vahidy *et al.* [22] showed that male cats have a higher risk of more severe manifestations of COVID-19.

The anxiety of cat owners during the COVID-19 pandemic is associated with the similarities in clinical signs of cats with FIP and COVID-19, including diarrhea, anorexia, pale mucous membranes, pyrexia, dyspnea, abdominal distension, and weight loss. Wolfe and Griesemer reported similarities in the FIP clinical signs and COVID-19 [23], while Arjun *et al.* [14] stated that the symptoms and clinical signs of both





**Figure-2:** Phylogenetic tree of Sby\_FIP (Surabaya Isolate), FCoV, FIPV, and SARS-CoV. FCoV=Feline coronavirus, FIPV=Feline infectious peritonitis virus, SARS-CoV=Severe acute respiratory syndrome coronavirus 2.

FIP and COVID-19 include fever, diarrhea, weakness, anorexia, and dyspnea. However, COVID-19 also involves other specific symptoms such as fever, dry cough, weakness, shortness of breath, myalgia, anosmia (loss of the sense of smell), ageusia (loss of the sense of taste), pneumonia, and also acute respiratory distress syndrome [14, 24].

Although FIP and COVID-19 differ clinically, their closest similarity is in the extrapulmonary findings, with endothelial dysfunction as vasculitis being a pathological sign of FIP [14, 25, 26], with lesions marked by perivascular infiltration, edema, blood vessel wall degeneration, and endothelial proliferation [27]. In COVID-19 cases, it was reported that extrapulmonary signs were caused by endotheliitis mediated by virus-causing vasculitis, especially in the veins with mild involvement of arterioles [28, 29].

The phylogenetic analysis performed in this study identified a unique cluster containing the FIPV Surabaya isolate (Sby-FIP) together with FECV and SARS-CoV-2 from Clades A, D, and F, which have been reported in GenBank. This differs from a report [30] describing that the coronavirus family is classified into four genera: *Alphacoronavirus*, *Betacoronavirus*, *Gammacoronavirus*, and *Deltacoronavirus*. Coronaviruses in dogs and cats are mostly alphacoronavirus, while zoonotic coronaviruses, such as SARS-CoV, MERS-CoV, and SARS-CoV-2 infecting humans, are categorized as *Betacoronavirus*. However, this information is preliminary and still requires comprehensive support from laboratory analyses [30]. We suggest that the transmission of SARS-CoV-2 and coronavirus of other domestic animals occur, so humans should pay more attention to coronavirus infections among cats and other domestic animals.

## Conclusion

Amid the COVID-19 pandemic, FECV that developed into FIP was discovered in Surabaya in a domestic male kitten aged younger than 6 months with wet-type FIP. On homology analysis, the FIPV Surabaya isolate was found to be 98% homologous with FCoV and FIPV, while the phylogenetic analysis clustered this isolate together with SARS-CoV-2 Clade A from Spain, SARS-CoV-2 Clade A from the USA, SARS-CoV-2 Clade D from the USA, and SARS-CoV-2 Clade F from Finland.

## Authors' Contributions

EBA: Concept and designed the study, data acquisition, and writing and critical review of the manuscript. KRI and WMY: Concept and designed the study and critical review of the manuscript. THS and NSF: Data acquisition and critical review of the manuscript. All authors have read and approved the final manuscript.

## Acknowledgments

The authors are thankful to Rector Universitas Airlangga-Surabaya, Indonesia, and Dean of Faculty of Veterinary Medicine, Universitas Airlangga-Surabaya, Indonesia for funding the study (Grant no. 346/UN3/2020).

## Competing Interests

The authors declare that they have no competing interests.

## Publisher's Note

Veterinary World remains neutral with regard to jurisdictional claims in published institutional affiliation.

## References

- Paltrinieri, S., Giordano, A., Stranieri, A., and Lauzi, S. (2021) Feline infectious peritonitis (FIP) and coronavirus disease 19 (COVID-19): Are they similar? *Transbound. Emerg. Dis.*, 68(4): 1786–1799.
- Su, S., Wong, G., Shi, W., Liu, J., Lai, A.C.K., Zhou, J., Liu, W., Bi, Y., and Gao, G.F. (2016) Epidemiology, genetic recombination, and pathogenesis of coronaviruses. *Trend Microbiol.*, 24(6): 490–502.
- Abdel-Moneim, A.S., and Abdelwhab, E.M. (2020) Evidence for SARS-CoV-2 infection of animal hosts. *Pathogens*, 9(7): 529.
- Decaro, N. and Lorusso, A. (2020) Novel human coronavirus (SARS-CoV-2): A lesson from animal coronaviruses. *Vet. Microbiol.*, 244: 108693.
- Riemer, F., Kuehner, K.A., Ritz, S., Sauter-Louis, C. and Hartmann, K. (2016) Clinical and laboratory features of cats with feline infectious peritonitis—a retrospective study of 231 confirmed cases (2000–2010). *J. Feline Med. Surg.*, 18(4): 348–356.
- Pedersen, N.C., Sato, R., Foley, J.E. and Poland, A.M. (2004) Common virus infections in cats, before and after being placed in shelters, with emphasis on feline enteric coronavirus. *J. Feline Med. Surg.*, 6(2): 83–88.
- Vogel, L., Van der Lubben, M., Lintelo, E.G.T., Bekker, C.P.J., Geerts, T., Schuijff, L.S., Grinwis, G.C.M., Egberink, H.F. and Rottier, P.J. (2010). Pathogenic characteristics of persistent feline enteric coronavirus infection in cats. *Vet. Res.* 41(5): 71–82.
- Felten, S. and Hartmann, K. (2019) Diagnosis of feline infectious peritonitis: A review of the current literature. *Viruses*, 11(11): 1068.
- Vennema, H., Poland, A., Foley, J. and Pedersen, N.C. (1998) Feline infectious peritonitis viruses arise by mutation from endemic feline enteric coronaviruses. *Virology*, 243(1): 150–157.
- Arimbi. (2010) Case study; Feline infectious peritonitis (FIP) suspected in purebred cats in Surabaya. *Vet. Med.*, 3(2): 109–114.
- Chang, H.W., Egberink, H.F. and Rottier, P.J.M. (2011) Sequence analysis of feline coronaviruses and the circulating virulent/avirulent theory. *Emerg. Infect. Dis.*, 17(4): 744–746.
- Brown, M.A., Troyer, J.L., Pecon-Slatery, J., Roelke, M.E. and O'Brien, S.J. (2009) Genetics and pathogenesis of feline infectious peritonitis virus. *Emerg. Infect. Dis.*, 15(9): 1445–1452.
- Chen, J., Qi, T., Liu, L., Ling, Y., Qian, Z., Li, T., Li, F., Xu, Q., Zhang, Y., Xu, S., Song, Z., Zeng, Y., Shen, Y., Shi, Y., Zhu, T. and Lu, H. (2020). Clinical progression of patients with COVID-19 in Shanghai, China. *J. Infect.*, 80(5): e1–e6.
- Arjun, N.S., Andre, N.M., Stout, A.E., Licitra, B.N., and Whittaker, G.R. (2022) Clinical and molecular relationships between COVID-19 and feline infectious peritonitis (FIP). *Viruses*, 14(3): 481.
- Hartmann, K. (2005) Feline infectious peritonitis. *Vet. Clin. N. Am. Small Anim. Pract.*, 35(1): 39–79.
- Rottier, P.J., Nakamura, K., Schellen, P., Volders, H. and Haijema, B.J. (2005) Acquisition of macrophage tropism during the pathogenesis of feline infectious peritonitis is determined by mutations in the feline coronavirus spike protein. *J. Virol.*, 79(22): 14122–14130.
- Jaimes, J.A., Millet, J.K., Stout, A.E., Andre, N.M. and Whittaker, G.R. (2020). A tale of two viruses: The distinct spike glycoproteins of feline Coronaviruses. *Viruses*, 12(1): 83.
- Tresnan, D.B., Levis, R. and Holmes, K.V. (1996) Feline aminopeptidase N serves as a receptor for feline, canine, porcine, and human coronaviruses in serogroup I. *J. Virol.*, 70(12): 8669–8674.
- Benetka, V., Kubber-Heiss, A., Kolodziejek, J., Nowotny, N., Hofmann-Parisot, M. and Mostl, K. (2004) Prevalence of feline coronavirus Types I and II in cats with histopathologically verified feline infectious peritonitis. *Vet. Microbiol.*, 99(1): 31–42.
- Norris, J.M., Bosward, K.L., White, J.D., Baral, R.M., Catt, M.J. and Malik, R. (2005) Clinicopathological findings associated with feline infectious peritonitis in Sydney, Australia: 42 cases (1990–2002). *Aust. Vet. J.*, 83(11): 666–673.
- Peckham, H., de Gruijter, N.M., Raine, C., Radziszewska, A., Ciurtin, C., Wedderburn, L.R., Rosser, E.C., Webb, K. and Deakin, C.T. (2020) Male sex identified by global COVID-19 meta-analysis as a risk factor for death and ICU admission. *Nat. Commun.*, 11(1): 6317.
- Vahidy, F.S., Pan, A.P., Ahnstedt, H., Munshi, Y., Choi, H.A., Tiruneh, Y., Nasir, K., Kash, B.A., Andrieni, J.D. and McCullough, L.D. (2021) Sex differences in susceptibility, severity, and outcomes of coronavirus disease 2019: Cross-sectional analysis from a diverse US metropolitan area. *PLoS One*, 16(1): e0245556.
- Wolfe, L.G., and Griesemer, R.A. (1966) Feline infectious peritonitis. *Pathol. Vet.*, 3(3): 255–270.
- Lovato, A., and de Filippis, C. (2020) Clinical presentation of COVID-19: A systematic review focusing on upper airway symptoms. *Ear Nose Throat J.*, 99(9): 569–576.
- August, J.R. (1984) Feline infectious peritonitis. An immune-mediated coronavirus vasculitis. *Vet. Clin. North. Am. Small Anim. Pract.*, 14(5): 971–984.
- Hayashi, T., Goto, N., Takahashi, R. and Fujiwara, K. (1977) Systemic vascular lesions in feline infectious peritonitis. *Nihon Juigaku Zasshi*, 39(4): 365–377.
- Stout, A.E., Andre, N.M., Zimmerberg, J., Baker, S.C. and Whittaker, G.R. (2021) Coronaviruses as a cause of vascular disease: A comparative medicine approach. *eCommons*, 2021(1): 1–7.
- Varga, Z., Flammer, A.J., Steiger, P., Haberecker, M., Andermatt, R., Zinkernagel, A.S., Mehra, M.R., Schuepbach, R.A., Ruschitzka, F. and Moch, H. (2020) Endothelial cell infection and endotheliitis in COVID-19. *Lancet*, 395(10234): 1417–1418.
- Becker, R.C. (2020) COVID-19-associated vasculitis and vasculopathy. *J. Thromb. Thrombolysis*, 50(3): 499–511.
- Brownlie, J., and Sibley, D. (2020) What can animal coronaviruses tell us about emerging human coronaviruses? *Vet. Rec.*, 186(14): 446–448.

\*\*\*\*\*