

## Source details

### Romanian Journal of Neurology/ Revista Romana de Neurologie

Open Access ⓘ

Scopus coverage years: from 2009 to Present

Publisher: Editura Medicala

ISSN: 1843-8148 E-ISSN: 2069-6094

Subject area: Medicine: Neurology (clinical) Neuroscience: Neurology

Source type: Journal

CiteScore 2021 ⓘ

0.2

SJR 2021 ⓘ

0.118

SNIP 2021 ⓘ

0.068

[View all documents >](#) [Set document alert](#) [Save to source list](#)

[CiteScore](#) [CiteScore rank & trend](#) [Scopus content coverage](#)

**i** Improved CiteScore methodology ✕

CiteScore 2021 counts the citations received in 2018-2021 to articles, reviews, conference papers, book chapters and data papers published in 2018-2021, and divides this by the number of publications published in 2018-2021. [Learn more >](#)

**CiteScore** 2021 ▼

$$0.2 = \frac{27 \text{ Citations 2018 - 2021}}{164 \text{ Documents 2018 - 2021}}$$

Calculated on 05 May, 2022

**CiteScoreTracker 2022** ⓘ

$$0.2 = \frac{41 \text{ Citations to date}}{189 \text{ Documents to date}}$$

Last updated on 05 September, 2022 • Updated monthly

#### CiteScore rank 2021 ⓘ

Category	Rank	Percentile
Medicine		
↳ Neurology (clinical)	#334/359	7th
Neuroscience		
↳ Neurology	#162/170	5th

[View CiteScore methodology >](#) [CiteScore FAQ >](#) [Add CiteScore to your site ↗](#)

## About Scopus

[What is Scopus](#)  
[Content coverage](#)  
[Scopus blog](#)  
[Scopus API](#)  
[Privacy matters](#)

## Language

[日本語版を表示する](#)  
[查看简体中文版本](#)  
[查看繁體中文版本](#)  
[Просмотр версии на русском языке](#)

## Customer Service

[Help](#)  
[Tutorials](#)  
[Contact us](#)

---

## ELSEVIER

[Terms and conditions](#) [Privacy policy](#)

Copyright © [Elsevier B.V.](#). All rights reserved. Scopus® is a registered trademark of Elsevier B.V.

We use cookies to help provide and enhance our service and tailor content. By continuing, you agree to the [use of cookies](#).



also developed by scimago. **SCIMAGO INSTITUTIONS RANKINGS**

**SJR** Scimago Journal & Country Rank

Home Journal Rankings Country Rankings Viz Tools Help About Us

**Index Copernicus Indexed**

Kinesiology Journal

Publish your paper within 3 days. Team of 200+ Editors

[iosjournals.org](http://iosjournals.org) [OPEN](#)

## Romanian Journal of Neurology/ Revista Romana de Neurologie

COUNTRY	SUBJECT AREA AND CATEGORY	PUBLISHER	H-INDEX
Romania 	<a href="#">Medicine</a> <ul style="list-style-type: none"> <li><a href="#">Neurology (clinical)</a></li> </ul> <a href="#">Neuroscience</a> <ul style="list-style-type: none"> <li><a href="#">Neurology</a></li> </ul>	<a href="#">Editura Medicala</a>	5
PUBLICATION TYPE	ISSN	COVERAGE	INFORMATION
Journals	18438148, 20696094	2009-2021	<a href="#">Homepage</a> <a href="#">How to publish in this journal</a> <a href="mailto:redactia@amaltea.ro">redactia@amaltea.ro</a>

### SCOPE

ROMANIAN JOURNAL OF NEUROLOGY (Revista Română de Neurologie), the official journal of the Romanian Society of Neurology, was founded in 2001, being a prestigious scientific journal that provides a high quality in terms of scientific content, but also the editorial and graphic aspect, both through an impartial process of selection, evaluation and correction of articles (peer review procedure), as well as providing editorial, graphic and printing conditions at the highest level. In order to increase the scientific standards of the journal, special attention was paid to the improvement of the quality of the published materials. Guidance articles, clinical trials and case studies are structured in several sections: reviews, original articles, case reports, images in neurology. All articles are published entirely in English. A team of reputable medical professionals in the field of neurology is involved in a rigorous peer review process that complies with international ethics and quality rules in the academic world.

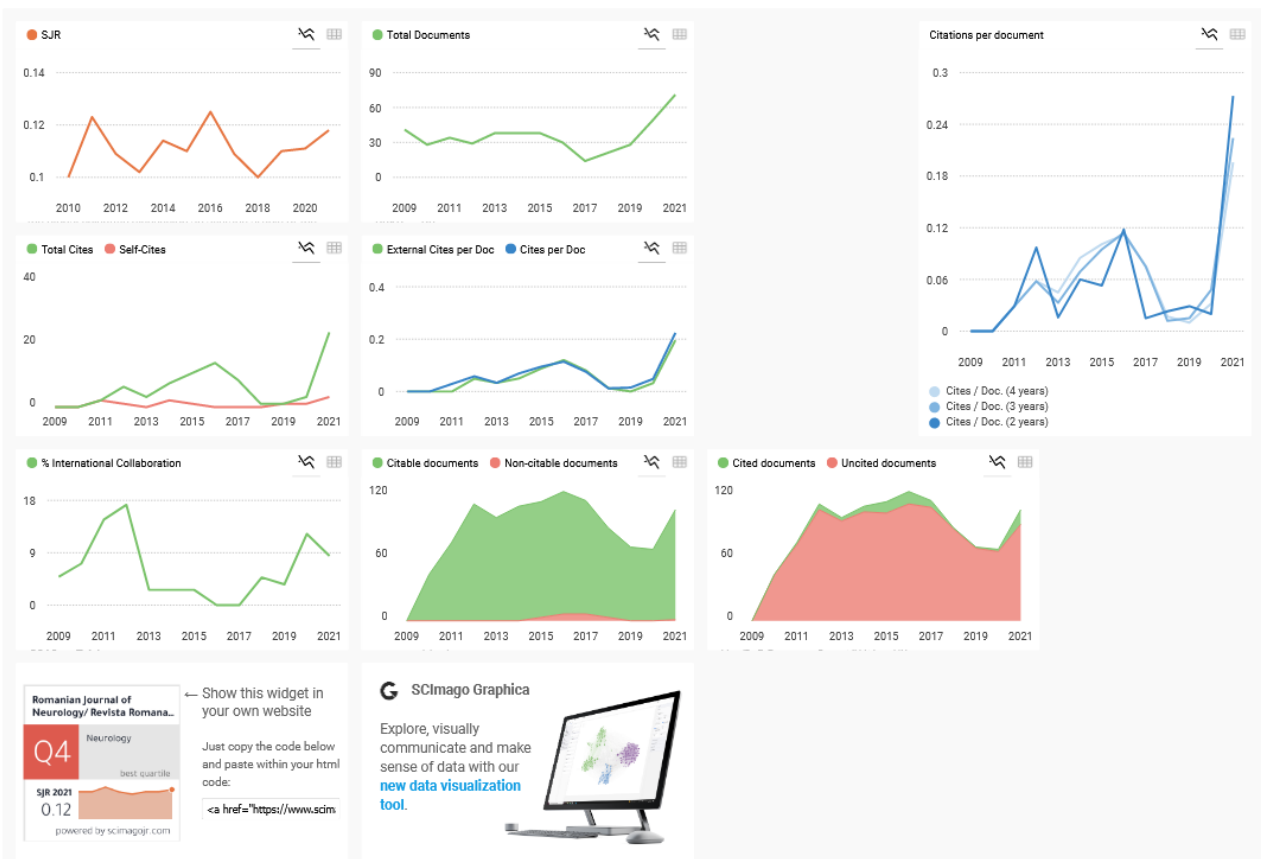
Join the conversation about this journal

### Quartiles

#### FIND SIMILAR JOURNALS

options

1 <b>Neurology Asia</b> MYS	2 <b>Acta Neurologica Belgica</b> ITA	3 <b>Expert Review of Neurotherapeutics</b> GBR	4 <b>Journal of Clinical Neurology (Korea)</b> KOR	5 <b>Current Neurology and Neuroscience Reports</b> USA
<b>68%</b> similarity	<b>66%</b> similarity	<b>62%</b> similarity	<b>62%</b> similarity	<b>61%</b> similarity



Metrics based on Scopus® data as of April 2022.

**Leave a comment**

Name

Email

(will not be published)



Submit

The users of Scimago Journal & Country Rank have the possibility to dialogue through comments linked to a specific journal. The purpose is to have a forum in which general doubts about the processes of publication in the journal, experiences and other issues derived from the publication of papers are resolved. For topics on particular articles, maintain the dialogue through the usual channels with your editor.

Developed by:



Powered by:



Follow us on [@ScimagoJR](#)

Scimago Lab, Copyright 2007-2022. Data Source: [Scopus®](#)

EST MODUS IN REBUS  
Horatio (Saturni 1.1.106)

[Edit Cookie Consent](#)



# ROMANIAN JOURNAL OF NEUROLOGY

REVISTA ROMÂNĂ DE NEUROLOGIE

Vol. 51 No. 1 Year 2022

**REVIEWS**

Neurophysiology: Evidence, etiology, clinical characteristics and management

The Clinical benefits of Herpes Zoster (COVID-19)

A Literature Review

Epidemiology and Psychological Interventions in

Psychiatric Services (Book)

The role of occipital nerve block with

ultrasound guidance in occipital neuralgia

case

**ORIGINAL ARTICLES**

Prevalence and spectrum of mouth lesions

and dental caries with mucocutaneous

inflammation in immunosuppressed patients on

chemotherapy (Case Report)

**CLINICAL STUDIES**

The effect of depressive symptoms

on cognitive function in older adults

with

Alzheimer's disease (Cross-sectional study)

Effect of the COVID-19 pandemic on the

Smoking Habits of a General Practice

in Romania: A Descriptive Study

Frequency of patterns of sleep and

arousal patterns in patients presenting

with neurodegenerative disorders: a

clinical neurophysiological study of patients

with Alzheimer's disease (Case Report)

**CASE REPORTS**

Severe hypoxic encephalopathy in a patient with

small vessel disease and Marfan syndrome

(Case Report)

Acute encephalopathy in a patient with

Alzheimer's disease (Case Report)

Benefits of vitamin D as an add-on therapy in

resistant diabetic neuropathy - case report

and literature review

Cerebral arteriovenous malformation associated

with subarachnoid hemorrhage and

intracerebral hemorrhage: a case report

and literature review

A case of traumatic myelitis and COVID-19

infection (Case Report)

Parosmia: epidemiology and a case

report of a patient with COVID-19 infection: a

case report

A malignant disseminated tuberculoma

associated intracranial hemorrhage with

disseminated granuloma in a young

immunocompetent patient

Successful acute thrombolysis beyond

guidelines: a case report

ISSN 1841-8829

ISSN 1841-8837

ISSN 1841-8845

ISSN 1841-8853

ISSN 1841-8861

ISSN 1841-8869

ISSN 1841-8877

ISSN 1841-8885

ISSN 1841-8893

ISSN 1841-8901

ISSN 1841-8909

ISSN 1841-8917

ISSN 1841-8925

ISSN 1841-8933

ISSN 1841-8941

ISSN 1841-8949

ISSN 1841-8957

ISSN 1841-8965

ISSN 1841-8973

ISSN 1841-8981

ISSN 1841-8989

ISSN 1841-8997

ISSN 1841-8995

ISSN 1841-8993

ISSN 1841-8991

ISSN 1841-8989

ISSN 1841-8987

ISSN 1841-8985

ISSN 1841-8983

ISSN 1841-8981

ISSN 1841-8979

ISSN 1841-8977

ISSN 1841-8975

ISSN 1841-8973

ISSN 1841-8971

ISSN 1841-8969

ISSN 1841-8967

ISSN 1841-8965

ISSN 1841-8963

ISSN 1841-8961

ISSN 1841-8959

ISSN 1841-8957

ISSN 1841-8955

ISSN 1841-8953

ISSN 1841-8951

ISSN 1841-8949

ISSN 1841-8947

ISSN 1841-8945



**AMALTEA**  
Medical Publishing House





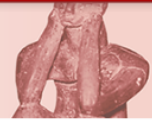AIMS & SCOPE

STANDARDS

EDITORIAL COUNCIL

PEER REVIEW

# ROMANIAN JOURNAL OF NEUROLOGY



## SELECT ISSUE

RJN Vol. 21, No. 1, Year 2022



Contact

ISSN 1843-8148 | e-ISSN 2069-6094

ISSN-L 1843-8148

DOI: 10.37897/RJN

## Indexed



Similarity Check by iThenticate, world leading professional plagiarism checking system



The intended audience of the site content is professionals from the medical and pharmaceutical community. This site does not collect any personal data nor does it use cookies that might obtain such data from your browser. [\[ info \]](#)

Agree



## REVIEWS

**Neuroglycopenia: Common etiologies, clinical characteristics and management***Anshul Singh, Nirendra Kumar Rai, Amit Agrawal**[ full article ] – Ref: Ro J Neurol. 2022;21(1). DOI: 10.57897/RJN.2022.1.1***The Characteristics of Headache in COVID-19: A Literature Review***Shierly, I. Ketut Sumada, Desie Yuliani, Riki Sukiandra, Chandra Wirawan**[ full article ] – Ref: Ro J Neurol. 2022;21(1). DOI: 10.57897/RJN.2022.1.2***Epilepsy and Psychological Interventions: A Systematic Review Study***Sajjad Saadat, Farzin Bagheri Sheykhangafshe, Babak Bakhshayesh Eghbali, Seyed Sepehr Khatami, Adele Isanazar**[ full article ] – Ref: Ro J Neurol. 2022;21(1). DOI: 10.57897/RJN.2022.1.3***The role of occipital nerve block with ultrasound guidance in occipital neuralgia cases***Yusak Mangara Tua Siahaan**[ full article ] – Ref: Ro J Neurol. 2022;21(1). DOI: 10.57897/RJN.2022.1.4*

## ORIGINAL ARTICLES

Contact

**Proliferation and apoptosis of smooth muscle and endothelial cells with immune inflammation in cerebrovascular diseases on atherosclerosis background***S. Mankovskiy, N. Ya. Chuiko, O. G. Kuryk**[ full article ] – Ref: Ro J Neurol. 2022;21(1). DOI: 10.57897/RJN.2022.1.5*

## CLINICAL STUDIES

**The effect of dapoxetine on chronic constriction injury (cci) induced neuralgia in rats***Akram Zare Bidaki, Mohsen Zabihi, Mohadeseh Asadi, Reza Bidaki**[ full article ] – Ref: Ro J Neurol. 2022;21(1). DOI: 10.57897/RJN.2022.1.6***Effect of the COVID-19 Pandemic on Acute Stroke Admissions at a Referral Stroke Center in Indonesia: A Descriptive Study***Rizaldy Pinzon, Vincent Ongko Wijaya**[ full article ] – Ref: Ro J Neurol. 2022;21(1). DOI: 10.57897/RJN.2022.1.7***Frequency of pattern of clinical and laboratory features in patients presenting with neuroleptic malignant syndrome***Suneeta Amrat, Naeemullah Bullo, Dileep Kumar, Saira Abbas, Aijaz Ali, Muhammad Sohaib Asghar**[ full article ] – Ref: Ro J Neurol. 2022;21(1). DOI: 10.57897/RJN.2022.1.8***Clinical neurological characteristics of geriatric patients with Coronavirus disease 2019 (COVID-19)***Adriana Marsha Yolanda, Anak Agung Ayu Putri Laksmidewi, Anak Agung Ayu Meidiary**[ full article ] – Ref: Ro J Neurol. 2022;21(1). DOI: 10.57897/RJN.2022.1.9*

## CASE REPORTS

**Severe hyponatremia in ischemic stroke with covid 19: case report and literature review***Rizaldy Taslim Pinzon, Advent Nara Nunsiano**[ full article ] – Ref: Ro J Neurol. 2022;21(1). DOI: 10.57897/RJN.2022.1.10***Acute confusional state in a patient with bilateral thalamic ischemic stroke***Iulia Elena Petre, Ioan Cristian Lupescu, Ioana Gabriela Lupescu, Mihaela Marian, Adriana Octavia Dulamea**[ full article ] – Ref: Ro J Neurol. 2022;21(1). DOI: 10.57897/RJN.2022.1.11***Benefits of vitamin D as an additional therapy in painful diabetic neuropathy: case report and recent literature review***Rizaldy Taslim Pinzon, Diana Teresa**[ full article ] – Ref: Ro J Neurol. 2022;21(1). DOI: 10.57897/RJN.2022.1.12***Cerebral autosomal dominant arteriopathy with subcortical infarcts and**





### Persistent cognitive impairment as a rare manifestation of mild COVID-19 infection, a case series

Saba Naghavi, Omid Mirmosayyeb, Mohammad Amin Najafi, Hamed Ghoshouni, Iman Adibi, Vahid Shaygannejad

[ full article ] – Ref: Ro J Neurol. 2022;21(1). DOI: 10.37897/RJN.2022.1.15

### A malignant disseminated tuberculosis: concurrent intracranial tuberculosis with skipped multilevel spondylitis in a young immunocompetent patient

Felisitas Farica Sutantoyo, Paulus Sugianto

[ full article ] – Ref: Ro J Neurol. 2022;21(1). DOI: 10.37897/RJN.2022.1.16

### Successful stroke thrombolysis beyond guidelines: a case series

Azliza Ibrahim, Mohd Fandi Al Khafiz, Anna Misyail, Alvin Oliver Payus, Yap Moon Yan, Abdul Hanif Khan, Loh Wei Chao, Janudin, Maz Anirah, Liyana Najwa, Wan Aliaa, Hoo Fan Kee, Hamidon Basri

[ full article ] – Ref: Ro J Neurol. 2022;21(1). DOI: 10.37897/RJN.2022.1.17

#### SEARCH



Contact

#### STANDARDS

Instructions for AUTHORS

Peer review process

Submit article

Submit your article to the journal by using the form here:

Submit

#### Subscriptions

To receive the **Ro Journal of NEUROLOGY** click here:

SUBSCRIBE



The intended audience of the site content is professionals from the medical and pharmaceutical community. This site does not collect any personal data nor does it use cookies that might obtain such data from your browser. [ info ]

Agree

 [editor@rjn.com.ro](mailto:editor@rjn.com.ro)

Subscribe to the Newsletter



Articles from the journal are licensed under a [Creative Commons Attribution 4.0 International License](#)

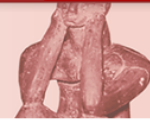[Terms & Conditions](#)  
[Open Access Statement](#)

*Publisher : AMALTEA Medical Publishing House*

Contact

The intended audience of the site content is professionals from the medical and pharmaceutical community. This site does not collect any personal data nor does it use cookies that might obtain such data from your browser. [\[ info \]](#)

Agree



SELECT ISSUE

Select



Contact

ISSN 1843-8148 | e-ISSN 2069-6094

ISSN-L 1843-8148

DOI: 10.37897/RJN

Indexed



Similarity Check by iThenticate, world leading professional plagiarism checking system



The intended audience of the site content is professionals from the medical and pharmaceutical community. This site does not collect any personal data nor does it use cookies that might obtain such data from your browser. [ info ]

Agree

**Honorary Founding Editor**

† Ovidiu Alexandru BAJENARU – Bucharest, Romania

**Editor-in-Chief**

Bogdan Ovidiu POPESCU – Bucharest, Romania

**Scientific Associate Editor**

Dafin Fior MURESANU – Cluj-Napoca, Romania

**President – Romanian Society of Neurology**

Cristina TIU – Bucharest, Romania

**EDITORIAL BOARD**

Florina ANTOCHI – Bucharest, Romania

Natan BORNSTEIN – Tel-Aviv, Israel

Vivian DRORY – Tel-Aviv, Israel

Jelena DRULOVIC – Belgrade, Serbia

† Franz GERSTENBRAND – Vienna, Austria

Wolfgang GRISOLD – Vienna, Austria

Carolina IONETE – Worcester, USA

Pavel KALVACH – Prague, Czech Republic

Amos KORCZYN – Tel-Aviv, Israel

Vladimir KOSTIC – Belgrade, Serbia

Ioannis MILONAS – Thessaloniki, Greece

Ioana MINDRUTA – Bucharest, Romania

Cristina PANEA – Bucharest, Romania

Cristian FALUP-PECURARIU – Brasov, Romania

Lacramioara PERJU-DUMBRAVA – Cluj-Napoca, Romania

Daniel PIRICI – Craiova, Romania

Zvezdan PIRTOSEK – Ljubljana, Slovenia

Constantin POPA – Bucharest, Romania

† Cristian Dinu POPESCU – Iasi, Romania

Maja RELJA – Zagreb, Croatia

Alexandru SERBANESCU – Bucharest, Romania

Mihaela SIMU – Timisoara, Romania

Aksel SIVA – Istanbul, Turkey

Cristina TIU – Bucharest, Romania

Emil TOESCU – Birmingham, UK

Valeria TUDORICA – Craiova, Romania

Laszlo VECSEI – Szeged, Hungary

**Secretary of Assistant Editors office**

Mihai VASILE – Bucharest, Romania

**Assistant Editors**

Laura Cristina CEAFALAN – Bucharest, Romania

Irene DAVIDESCU – Bucharest, Romania

Laura DUMITRESCU – Bucharest, Romania

Athena Cristina MERGEANI – Bucharest, Romania

Florina MOLDOVAN – Cluj-Napoca, Romania

Horia NICOLAE – Bucharest, Romania

Alexandra OPRISAN – Bucharest, Romania

Cecilia ROSCA – Timisoara, Romania

Elena TERECOSA – Bucharest, Romania



## STANDARDS

### Instructions for AUTHORS

Peer review process

Submit article

Submit your article to the journal by using the form here:

[Submit](#)

## Subscriptions

To receive the **Ro Journal of NEUROLOGY** click here:

[SUBSCRIBE](#)



[editor@rjn.com.ro](mailto:editor@rjn.com.ro)

[Subscribe to the Newsletter](#)



Articles from the journal are licensed under a [Creative Commons Attribution 4.0 International License](#)

[Terms & Conditions](#)

[Open Access Statement](#)

*Publisher : AMALTEA Medical Publishing House*

The intended audience of the site content is professionals from the medical and pharmaceutical community. This site does not collect any personal data nor does it use cookies that might obtain such data from your browser. [\[ info \]](#)

[Agree](#)



[HOME](#) · [Editorial Team](#)

## Editorial Team

### Editor-in-Chief

[ijhs@utm.edu.ec](mailto:ijhs@utm.edu.ec) | [ijhs@sciencescholar.us](mailto:ijhs@sciencescholar.us) | [editorsciencescholar@gmail.com](mailto:editorsciencescholar@gmail.com)

M. R. Herrera, Scopus ID: [7202050008](#), Nursing, Universidad Estatal del Sur de Manabí, Ecuador

### Chief Executive Editor

[executive\\_editor@utm.edu.ec](mailto:executive_editor@utm.edu.ec) | [executive\\_editor@sciencescholar.us](mailto:executive_editor@sciencescholar.us)

M. R. Gámez, Scopus ID: [57204684841](#), Universidad Técnica de Manabí, South America

### Founder & Managing Editor

[iwayansuryasa@utm.edu.ec](mailto:iwayansuryasa@utm.edu.ec) | [suryasa@stikom-bali.ac.id](mailto:suryasa@stikom-bali.ac.id)

W. Suryasa, Scopus ID: [57200211897](#), ITB STIKOM Bali, Indonesia

## International Advisory Board

M. Cantor, Scopus ID: [7005614403](#), Clinical Informatics, United States

J. Aarts, Scopus ID: [7007174257](#), Erasmus University Rotterdam, Netherlands

T. Karopka, Scopus ID: [56635405100](#), BioCon Valley GmbH, eHealth, Germany

S. de Lusignan, Scopus ID: [7003334937](#), University of Surrey, United Kingdom

C. Kalun Or, Scopus ID: [55957532700](#), The University of Hong Kong, Hong Kong

D. M. P. Hernández, Scopus ID: [57201006495](#), University of Medical Sciences of Havana, Cuba

A. M. Salem, Scopus ID: [36762342200](#), Ain Shams University, Egypt

R. Makhachashvili, Amazon ID: [1499008](#), Borys Grinchenko University, Ukraine

## Editorial Board

A. P. C. Mendoza, Ref ID: [00770810](#), Universidad Tecnica de Manabi, Portoviejo, Ecuador

D. Singh, Scopus ID: [57203079484](#), Houston Methodist Research Institute, USA

U. R. Acharya, Scopus ID: [7004510847](#), Ngee Ann Polytechnic, Singapore, Singapore

B. Dresp-Langley, Scopus ID: [57216804437](#), University of Strasbourg, France

T. Lambrou, Scopus ID: [16552782200](#), University of Lincoln, United Kingdom

O. Oluwagbemi, Scopus ID: [36680459800](#), Federal University Lokoja, Nigeria

F. Zhou, Scopus ID: [55634210800](#), Jilin University, China

L. Johnson, Scopus ID: [8538531600](#), University of Cape Town, South Africa

**H. Nishiura**, Scopus ID: [7005501836](#), JSCA, Hokkaido University, Japan  
**J. McCaw**, Scopus ID: [21735020500](#), University of Melbourne, Australia  
**G. V. Oleskeviciene**, Scopus ID : [57194223762](#), Mykolas Romeris University, Lithuania

## Production Editor

**Antonio**, Scopus ID: [57210942626](#), Universidad Técnica de Manabí, Ecuador  
**T. Koldoris**, Scopus ID: [57415636800](#), Queen Mary University of London, United Kingdom

## Editorial Office

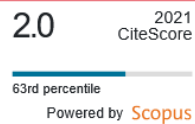
[ss.support@utm.edu.ec](mailto:ss.support@utm.edu.ec) | [support@sciencescholar.us](mailto:support@sciencescholar.us)

**V. Vucic**, Scopus ID: [36069696900](#), Universidad Técnica de Manabí, Ecuador

## Retired Editor

**M. I. Bordelois**, Ref ID: [00757030](#), [GS](#), Medicina, Universidad Técnica de Manabí, Ecuador  
[See more...](#)

### CITESCORE 2021

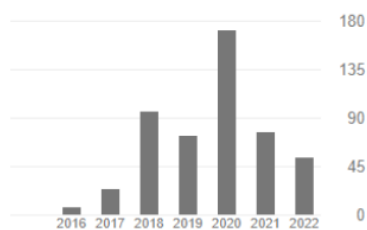


### GOOGLE SCHOLAR

Google Scholar

Cited by

	All	Since 2017
Citations	514	504
h-index	13	13
i10-index	21	21



Last updated: 1 August 2022

### MAIN MENU

[Current Issues](#)

[Previous Issues](#)

### FOR AUTHORS

[Aims & Scope](#)

[Call For Papers](#)

[Note to Contributors](#)

[Contact Us](#)

[Online Submission](#)

[Need Help](#)

PUBLISH WITH US

[High ranking](#)

[Worldwide representation](#)

['Online First' publishing](#)

[Global exposure](#)

MEMBERSHIP



turnitin



THOMSON  
REUTERS



INFORMATION

[For Readers](#)

[For Authors](#)

[For Librarians](#)

Copyright © 2022 International Journal of Health Sciences



This work is licensed under a Creative Commons Attribution-NonCommercial-NoDerivatives 4.0 International License.



# A malignant disseminated tuberculosis: concurrent intracranial tuberculosis with skipped multilevel spondylitis in a young immunocompetent patient

Felisitas Farica Sutantoyo, Paulus Sugianto

Department of Neurology, Faculty of Medicine Airlangga University, Dr. Soetomo General Hospital, Surabaya, Indonesia

## ABSTRACT

**Background/aim.** *Mycobacterium tuberculosis* (*M. tuberculosis*) infection can cause pulmonary and extrapulmonary tuberculosis (TB), resulted from hematogenous or lymphatic dissemination of the bacteria. Disseminated TB is characterized by the presence of two or more non-contiguous sites from the spread. Dissemination to the central nervous system (CNS TB) has several manifestations that can cause devastating neurological complications. Several predisposing factors include older age, human immunodeficiency virus (HIV) coinfection, and pharmacological immunosuppression. As the manifestation of CNS TB itself is rare, diagnosing it remains a challenge. Prompt antituberculosis treatment is needed to improve patient's outcome. This paper aims to present a rare case of malignant disseminated TB in a young immunocompetent patient.

**Case.** This case presents an immunocompetent 17-year-old male with weakness in the four extremities. Through comprehensive history taking and examination, the patient was diagnosed with malignant disseminated TB, presenting as cerebellar tuberculoma, tuberculous meningitis, and multiple skipped level spondylitis TB; and concurrent pulmonary TB. Then, the patient underwent a surgery for the cervical lesion and was started on antituberculosis treatment in combination with corticosteroid. After the treatment, the patient's motoric and sensoric functions improved and he was able to urinate and defecate normally.

**Conclusion.** This case demonstrates the importance of considering disseminated TB in the differential diagnosis of a patient with neurological deficits, regardless of the fact that the patient is young and immunocompetent. Prompt diagnosis and rapid initiation of treatment can improve the patient's outcome.

**Keywords:** disseminated tuberculosis; tuberculosis meningitis; tuberculoma, spondylitis tuberculosis

## INTRODUCTION

Tuberculosis (TB) remains one of the world's leading causes of illness and mortality. It is one of the top ten causes of death worldwide and the main cause of death from a single infectious agent. One in every three people, or 2–3 billion people, is infected with *Mycobacterium Tuberculosis* (*M. Tuberculosis*), with 5–15 percent of those infected developing active TB disease during their lifetime. [1,2]. *M. tuberculosis* primarily causes TB in the lungs, however, it can also affect the other organs, resulting in extrapulmonary TB (EPTB). EPTB has two forms, primary EPTB, which occurs at the site of initial infec-

tion and secondary EPTB, which is disseminated, occurring as a result of hematogenous or lymphatic spread of bacteria from the primary organ, reactivation of latent TB, ingestion of infected sputum, or local spread from adjacent organs [3]. The presence of two or more non-contiguous sites from the spread is defined as disseminated TB [4]

In 2019, an estimated 10 million people contracted TB globally, of which there were 5.6 million men, 3.2 million women, and 1.2 million children, with 1.4 million cases of death [2]. According to the World Health Organization (WHO), South-East Asia (44%), Africa (25%), and the Western Pacific (18%) had the

*Corresponding author:*  
Felisitas Farica Sutantoyo  
E-mail: felisitasfarica@gmail.com

*Article history:*  
Received: 23 February 2022  
Accepted: 3 March 2022

highest percentages of people diagnosed with TB in 2019, with smaller percentages in the Eastern Mediterranean (8.2%), the Americas (2.9%), and Europe (2.5%). India (26%), Indonesia (8.5%), China (8.4%), the Philippines (6.0%), Pakistan (5.7%), Nigeria (4.4%), Bangladesh (3.6%), and South Africa (3.6%) contributed for two-thirds of the global total [5]. Indonesia had an estimated 845,000 cases of TB with 93,000 death in 2018. TB is the fourth leading cause of mortality in the whole country and is the leading cause of death from a communicable disease among Indonesians aged 15 to 49. Only 569,865 (67%) of the estimated 845,000 cases reported in 2018 with the remaining one third was either undetected or diagnosed but not reported to the National Tuberculosis Program (NTP) [6].

The mechanism by which disseminated TB occurs is still unknown. One theory says that the lung infection causes the epithelial layer of alveolar cells to erode, allowing the infection to migrate into pulmonary vein. The bacteria pass through the left side of the heart and then, systemic circulation, where it multiplies, resulting in systemic disseminated TB. Clinical manifestation of disseminated TB ranges from constitutional symptoms, such as fever, weight loss, and night sweats to various clinical signs and symptoms of organ failure, depending on the organ involved [4].

It is a potentially fatal variant of TB caused by large lymphohematogenous spread of *M. tuberculosis* bacilli. Delayed presentation is linked to a higher death rate, emphasizing the significance of early antituberculosis treatment [7].

This paper aims to report a case of malignant disseminated TB in young immunocompetent patient.

## CASE REPORT

A 17-year-old male was admitted to the hospital with weakness in the four extremities. The complaint began 3 months before admission, starting from the right side of the body. One month before, weakness was also felt on the left side of the body, accompanied with lump on the low back and low back pain which was aggravated in supine position. Therefore, the patient slept on either of his side and could not rise from the bed. The patient also complained of headache and fever since the last 3 months before admission, cough and weight loss since the last 6 months before admission, shortness of breath since the last 2 weeks before admission, and numbness from the neck down to the toes. Urination and defecation had been difficult for the past week; hence, urine catheter must be placed.

On physical examination, the patient was found to be anemic and there was nuchal rigidity in neurological examination. The patient's motoric function was 222233/333444 for the upper extremities and

33344/33444 for the lower extremities. Hyperreflexia was found on both sides. Pathological reflexes, including Hoffman, Tromner, Babinski, and Chaddock reflexes were found to be positive bilaterally. A gibbus was found on the physical examination of the vertebral column (Figure 1).

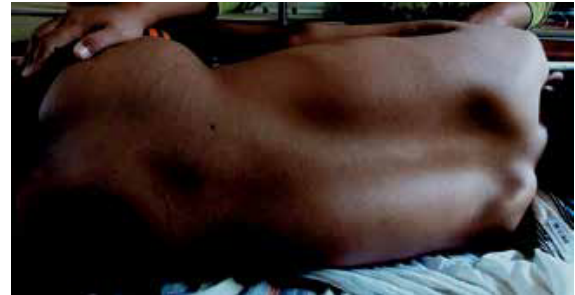

FIGURE 1. Lump (gibbus) on the lower back of the patient

Complete blood count, comprehensive metabolic panel, chest radiograph, head and cervical computed tomography with contrast, thoracic magnetic resonance imaging with contrast were performed. There was decreased haemoglobin, increased white blood cell count, decreased albumin, and increased erythrocyte sedimentation rate (ESR). Hepatitis B surface antigen (HBSAg) and human immunodeficiency virus (HIV) examination showed non-reactive results.

Chest x-ray showed blunting of the costophrenic angle and air fluid level, suggesting pleural effusion on the right side (Figure 2). Meanwhile, CT-scan of the head showed hypodense lesion in the size of 1.23 cm x 1.79 cm x 0.94 cm with rim contrast enhancement and perifocal edema in the cortex-subcortex of left cerebellar hemisphere, suggesting a tuberculoma (Figure 3).

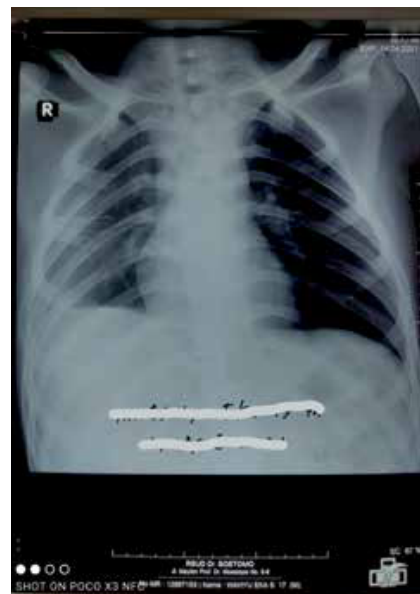
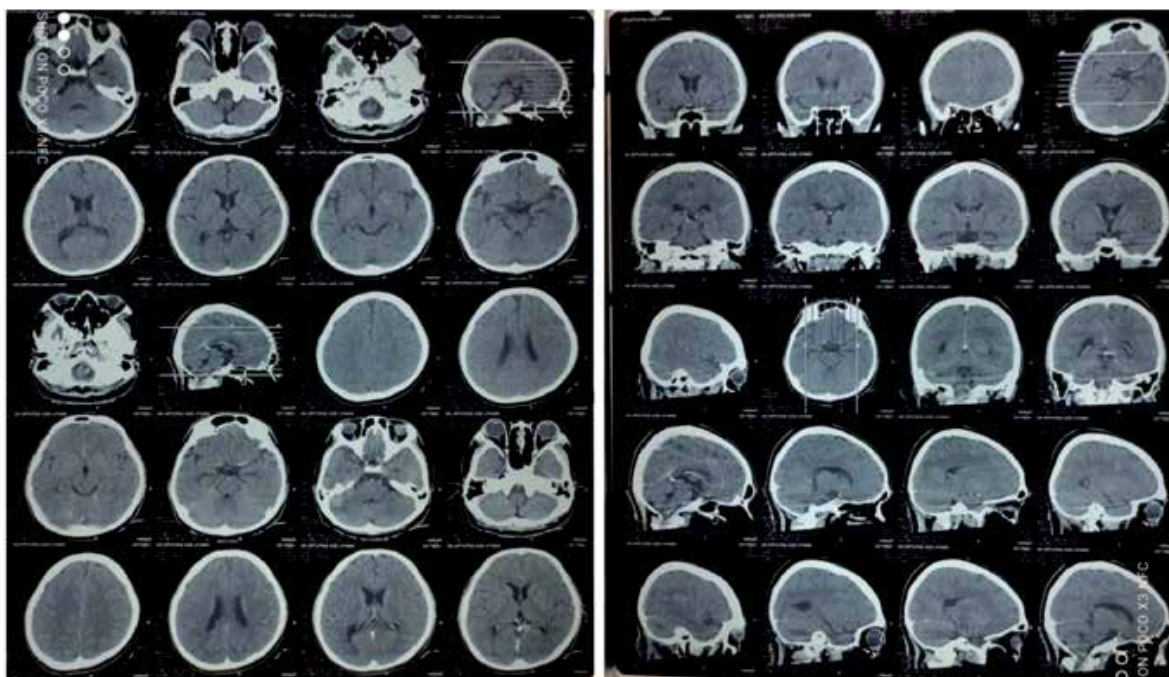


FIGURE 2. Chest x-ray showed pleural effusion on the right side of the lung



**FIGURE 3.** CT scan of the head suggesting a tuberculoma in the cortex-subcortex of the left cerebellar hemisphere with perifocal edema

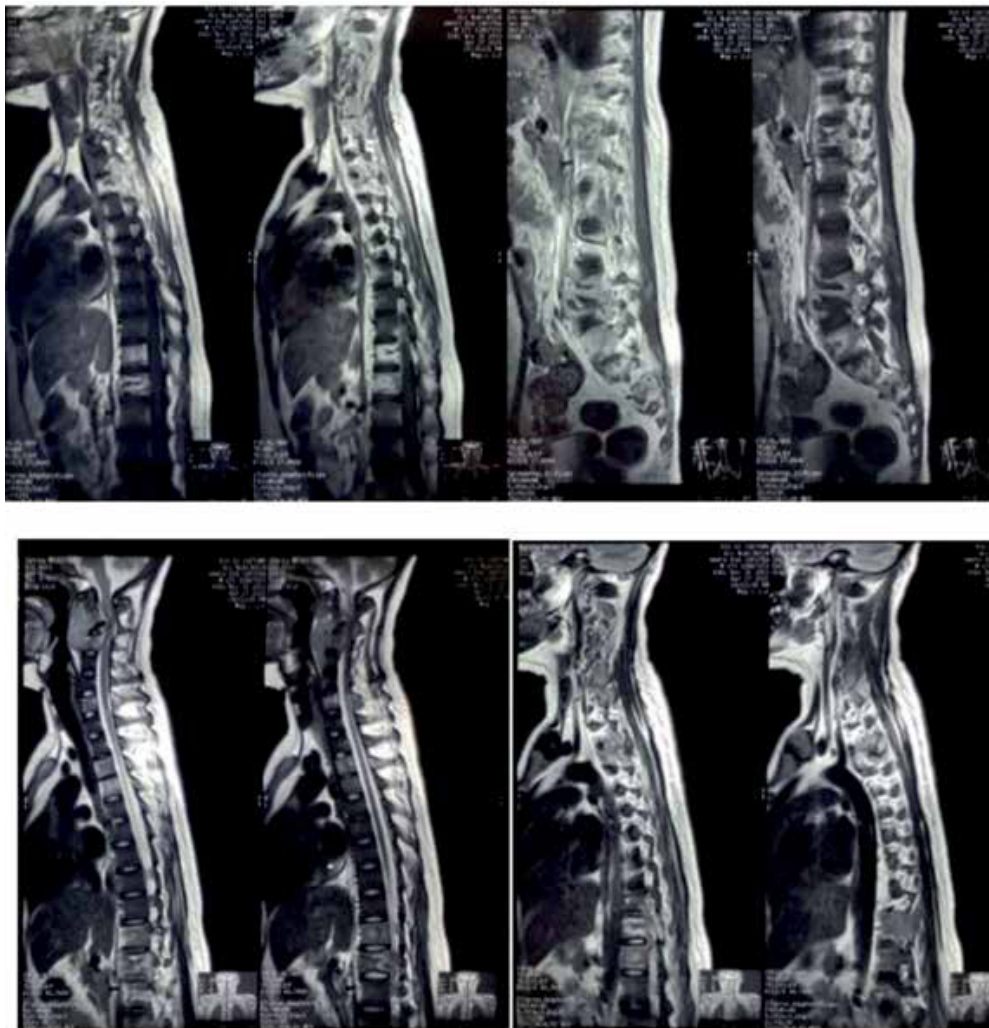
On whole spine Magnetic Resonance Imaging (MRI) (Figure 4), destruction of the anterior aspect of the corpus vertebrae C2-C4 with intraosseous abscess and paravertebral soft tissue mass, forming a 3.6 cm x 3.6 cm x 4.7 cm abscess at C2-C4 level which was hypointense on T1WI, hyperintense on T2WI, restricted diffusion area on DWI, with rim contrast enhancement was found. The mass extends to the epidural causing severe spinal cord compression, severe left and right foramina stenosis as high as C2-C4 level, and myeloedema at C2-C3 level which is slightly hyperintense on T1WI and hyperintense on T2WI. There were lesions with the same characteristics in the corpus vertebrae C7, T2 and T3, T9 and T10, accompanied by a paravertebral soft tissue mass that formed an abscess at T2-T3, T8-T9 and T9-T10 level that extended and caused severe foraminal stenosis. Severe destruction of the anterior to posterior aspect with compression of the corpus vertebrae L3-L5 was also found, with an intraosseous abscess and the surrounding paravertebral soft tissue mass forming an abscess at the level of L1-L5, compressing adjacent spinal cord.

The patient was diagnosed with tuberculous spondylitis, left cerebellar tuberculoma, tuberculous meningitis, and lung TB. Surgery was done to fix the cervical lesion followed by gene Xpert and pathology examination on the tissue biopsy after the surgery of the cervical lesion. Cervical radiograph post-surgery in (Figure 5).

Two months after surgery, the patient's motoric function was 44333/33344 for the upper extremities and 55554/45555 for the lower extremities. Sensory deficit was reduced to hypesthesia at T3-T4 level. Complaint of pain on the neck decreased and the patient was able to urinate and defecate normally. Screening for other blood-borne viruses such as hepatitis B and C, as well as assessing nutritional status, blood pressure, blood sugar, and encouraging smoking cessation, can also be highlighted during clinical care as part of a package of person-related health management.

## DISCUSSION

This paper presents an immunocompetent 17-year-old male with clinical abnormal motoric function upper extremities and lower extremities and having gibbus. Gibbus deformities are characterized by anterior collapse of one or more vertebral bodies resulting in kyphosis cause from spinal infections after tuberculosis [8]. Headache, fever, cough, weight loss, shortness of breath and numbness from the neck down to the toes is a classic clinical presentation of pulmonary TB. This infection of pulmonary TB is defined as tuberculosis of the lung parenchyma and the tracheobronchial tree only. Manifestation in adults should be distinguished from post-primary pulmonary TB, which is the most frequent TB. The classic clinical features of pulmo-



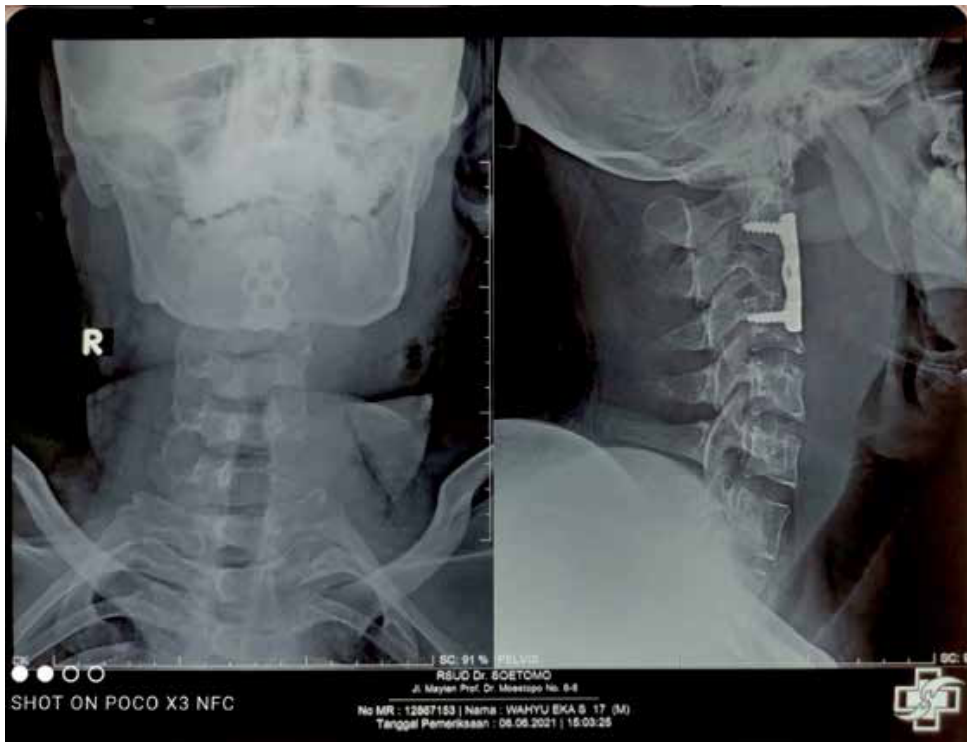**FIGURE 4.** MRI examination of the whole spine showing destruction of corpus vertebrae at C2-C4, C7, T2-T3, T9-T10, and L3-L5 level with intraosseous abscess and paravertebral soft tissue mass that extends to the epidural causing severe spinal cord compression

nary TB include chronic cough, sputum production, appetite loss, weight loss, fever, night sweats, and hemoptysis. Someone presenting with any of these symptoms should be suspected of having TB. If they are or were known to be in contact with infectious TB, they are even more likely to be suffering from TB [9].

This patient diagnosed with malignant disseminated TB despite being immunocompetent without any history of HIV infection, malignancy, or autoimmune disease. Disseminated TB accounts for 1 to 3% of all TB cases with predisposing factors such as old age, history of infections in childhood, HIV infection, alcohol abuse, diabetes, chronic kidney or liver failure, organ transplant, pharmacological immunosuppression, pregnancy, and symptoms lasting over 12 weeks [10,11]. Central nervous system TB (CNS TB) accounts for 1 to 5% of all patients with TB

and occurs in 10% of patients with AIDS-related TB. CNS TB can be manifested as tuberculous meningitis, tuberculoma of the CNS, tuberculous brain abscess, and spinal TB. Spinal TB itself consists of extradural and intradural tuberculous spinal infection. Extradural tuberculous spinal infection can manifest as spondylitis, paraspinal, and epidural abscess [12].

CNS TB manifestations that can be found in our patient is cerebellar tuberculoma, tuberculous meningitis, and tuberculous spondylitis in spite of the absence of predisposing factors. The spread of mycobacteria to the CNS results in the formation of granulomatous foci that can manifest as tuberculous meningitis or as tuberculoma depending on whether the infection spreads into the subarachnoid space or is contained by a granulomatous inflammatory reaction [12]. Tuberculous meningitis is a serious infection of the central nervous system



**FIGURE 5.** Cervical radiograph post-surgery

(CNS) that primarily affects the brain parenchyma, meninges, and spinal cord. Neuroimaging features of tuberculous meningitis include leptomeningeal and basal cisternal enhancement, hydrocephalus, periventricular infarctions, and tuberculoma [13]. In patients with tuberculous meningitis, nonspecific symptoms like fever, headache, fatigue, malaise, anorexia, and myalgia can be found lasting between 2 to 8 weeks before symptoms of meningeal irritation, such as stiff neck with focal neurological deficits occur. Only 10% of the patients have previous TB infection and 30 to 50% of the patients have active pulmonary TB seen on chest x-ray. Pleocytosis, increased protein, and low sugar can be seen from the cerebrospinal fluid examination. Patients with tuberculoma or a tuberculous brain abscess may experience headaches, seizures, papilledema, or other indicators of elevated intracranial pressure, depending on where the infection is located [14].

Tuberculous spondylitis, or Pott disease, occurs in 1 to 5% of TB cases. The diagnosis of TB spondylitis is difficult since it requires a high level of clinical suspicion. Despite the fact that TB spondylitis has a low mortality rate, it is associated with higher morbidity rate because significant diagnostic delay results in severe bone abnormalities and neurological deficits. TB spondylitis most commonly affects the thoracic and thoracolumbar segments, causing vertebral bodies to be destroyed. Concomitant paraspinal abscesses and epidural involvement can be

found in about 70% and 65% of the patients, respectively. Multifocal engagement and involvement of other segment are unusual [15]. Atypical presentation of TB spondylitis refers to patients who do not have the typical clinical characteristics of axial pain, constitutional symptoms, kyphosis, or normal radiological findings (paradisical). Atypical radiographic patterns include concentrated vertebral collapse, isolated neural arch involvement, ivory vertebra, circumferential vertebral involvement, contiguous or skip vertebral lesions, and multifocal osseous involvement [16]. As seen in this case, the patient has atypical presentation of tuberculous spondylitis, showing a multilevel skipped lesion in the cervical, thoracic, and lumbar vertebrae.

Tuberculous pleurisy might manifest as an acute disease with a high fever or as a subacute or chronic illness with a low fever. Pleuritic chest discomfort (dry pleurisy) may be the first symptom, although breathlessness is the most common symptom produced by pleural effusion. Dullness on percussion and decreased breath sounds at the afflicted location are physical indications of effusion [9].

The patient was diagnosed with disseminated TB because of the presence of intracranial manifestations (cerebellar tuberculoma and tuberculous meningitis), bone manifestation (spondylitis TB), and pulmonary TB.

Complaints of weight loss, fever, headache, and nuchal rigidity supported the diagnosis of tubercu-

lous meningitis, while cough and difficulty breathing showed symptoms of pulmonary TB. The diagnosis of spondylitis is supported by the weakness symptoms in the four extremities. The laboratory, radiology, and pathology examinations also support the diagnosis.

The diagnosis of spinal TB is based on the correlation of clinical and imaging findings, and it was verified by culture and sensitivity tests, Gene Xpert PCR testing, or histological evidences. Caseative necrosis, epithelioid cell granuloma, and Langhans giant cells are the typical histological hallmarks of TB, and they have been documented in 72 to 97% of cases [16].

Gene Xpert tissue biopsy showed that the sample was sensitive to rifampicin and pathology report from the resected tissue revealed abundant caseous necrosis accompanied by multinucleated giant cells, confirming the diagnosis of spondylitis TB.

The start of treatment is linked to a considerable improvement in outcomes. Anti-tuberculosis medication is the mainstay of tuberculous meningitis treatment. Treatment for TB must be sustained for at least 9 to 12 months. Isoniazid, rifampicin, pyrazinamide, streptomycin, and ethambutol are among the first-line anti-tuberculosis medicines used; treatment is separated into two phases: an intense (initial) phase and a maintenance phase. The anti-tuberculosis regimen in the intensive phase consists of a combination of four first-line drugs: isoniazid, rifampicin, streptomycin, and pyrazinamide. The intense phase will last two months. A two-drug regimen (isoniazid and rifampicin) is administered for 7 or 10 months in the continuation phase. To avoid the development of further resistance in multidrug-resistant TB, therapy with at least one susceptible injectable and at least three additional susceptible medicines is necessary. In disseminated TB with meningitis, pericarditis, and adrenal insufficiency, as well as disseminated TB with refractory hypoxemia, adjunct corticosteroid therapy can be administered [4,17].

Cervical collar brace was put on the patient. Oral rifampicin 450 mg, isoniazid 300 mg, pyrazinamide 1,000 mg, and ethambutol 750 mg were given daily. One gram of streptomycin intramuscular injection were given for 2 months. Five mg of intravenous dexamethasone injection was given three times a day that tapered of weekly. Anterior cervical corpec-

tomy and fusion surgery was done on the patient and the patient was referred for physiotherapy.

Monitoring this case about skipped multilevel spondylitis in 6 month, every years to Five-year evaluated for patients about clinical finding and physical examination. Contrast-enhanced and diffusion-weighted magnetic resonance imaging can used when clinical deterioration. The principle of treatment is as same as typical cases [18]. For the management of extra-pulmonary TB (the bones and joints), duration treatment is extended to 9 months. Meantime, surgery is an efficient treatment for spinal TB patients with manifestations of neurological deficits, kyphotic deformity, or large abscesses. Patients with skip non-contiguous lesions are vulnerable to create neurological complications indicating a high need of surgical medication. Identification of non-contiguous spinal TB can influence the plan for surgical intervention decisions [19–21]. Following clinical history and physical examination, trials of anti-TB medication and the use of spinal MRI and Bone CT scan have played an essential role in the early diagnosis and prompt treatment that will significantly increase outcome of patients.

## CONCLUSION

Dissemination of *M. tuberculosis* into the central nervous system often has a late presentation, resulting in late diagnosis and treatment that significantly impair the patient's quality of life. CNS TB is a rare manifestation of disseminated TB, making the diagnosis often difficult and requires a high clinical suspicion. Its clinical symptoms and radiologic findings might also be mistaken for those of other diseases. Prompt diagnosis and treatment are needed to prevent morbidity and other neurological complications in order to improve the patient's quality of life.

Competing interests

No competing interests were disclosed.

### Conflict of interest

The authors declare no conflict of interest, financial or otherwise.

### Acknowledgements

Declared none.

**Ethical approval:** The patient has given permission and informed consent for the publication of this case report.

*Conflict of interest:* none declared

*Financial support:* none declared

## REFERENCES

1. Agyeman AA, Ofori-Asenso R. Tuberculosis—an overview. *J Public Heal Emerg.* 2017;1(3):7–7.
2. World Health Organization. Tuberculosis Key facts. *World Health Organization.* 2020.
3. Gopaldaswamy R, Dusthacker VNA, Kannayan S, Subbian S. Extrapulmonary Tuberculosis—An Update on the Diagnosis, Treatment and Drug Resistance. *J Respir.* 2021;1(2):141–64.
4. Khan FY. Review of literature on disseminated tuberculosis with emphasis on the focused diagnostic workup. *J Family Community Med [Internet].* 2019;26(2):83–91. Available from: <http://www.ncbi.nlm.nih.gov/pubmed/31143078> <http://www.pubmedcentral.nih.gov/articlerender.fcgi?artid=PMC6515764>
5. World Health Organization. Global Tuberculosis Report. Geneva; 2020.
6. USAID. Indonesia Tuberculosis Roadmap Overview, Fiscal Year 2021. *USAID From Am People.* 2021;3.
7. Valenzona Madamba H. Disseminated Tuberculosis with Involvement of the Bone Marrow. *Obstet Gynecol Int J.* 2016;5(4):1–7.
8. Garg RK, Somvanshi DS. Spinal tuberculosis: A review. Vol. 34, *Journal of Spinal Cord Medicine.* 2011. p. 440–54.
9. Loddenkemper R, Lipman M, Zumla A. Clinical aspects of adult tuberculosis. *Cold Spring Harb Perspect Med.* 2016;6(1):1–26.
10. Esposito S, Levi J, Matuzsan Z, Amaducci A, Richardson D. A Case Report of Widely Disseminated Tuberculosis in Immunocompetent Adult Male. *Clin Pract Cases Emerg Med.* 2020;4(3):375–9.
11. Nelwan EJ, Kuniawan J, Praptini MN, Pohan HT. Disseminated tuberculosis diagnosed first as leptospirosis in immunocompetent patient. *Med J Indones.* 2015;24(4):252–6.
12. Schaller MA, Wicke F, Foerch C, Weidauer S. Central Nervous System Tuberculosis: Etiology, Clinical Manifestations and Neuroradiological Features. *Clin Neuroradiol.* 2019;29(1):3–18.
13. Hwang JH, Lee KM, Park JE, Kim HG, Kim EJ, Choi WS, et al. Atypical cerebral manifestations of disseminated Mycobacterium tuberculosis. *Front Neurol.* 2017;8(SEP):1–8.
14. Cherian A, Thomas S. Central nervous system tuberculosis. *Afr Health Sci.* 2011;11(1).
15. Lacerda C, Linhas R, Duarte R. Tuberculous spondylitis: A report of different clinical scenarios and literature update. *Case Rep Med.* 2017;2017.
16. Rajasekaran S, Soundararajan DCR, Shetty AP, Kanna RM. Spinal Tuberculosis: Current Concepts. *Glob Spine J.* 2018;8(4\_suppl):965–1085.
17. Garg RK, Malhotra HS, Gupta R. Spinal cord involvement in tuberculous meningitis. *Spinal Cord.* 2015;53(9):649–57.
18. Jain A. Tuberculosis of spine: Research evidence to treatment guidelines. Vol. 50, *Indian Journal of Orthopaedics.* 2016. p. 3–9.
19. Sivalingam J, Kumar A. Spinal tuberculosis resembling neoplastic lesions on MRI. *J Clin Diagnostic Res.* 2015;9(11):TC01–3.
20. Thammaroj J, Kitkhuandee A, Sawanyawisuth K, Chowchuan P, Promon K. MR findings in spinal tuberculosis in an endemic country. *J Med Imaging Radiat Oncol.* 2014;58(3):267–76.
21. Khan F, Govender S. Sacroiliac joint involvement in spinal tuberculosis. *SA Orthop J.* 2018;17(3)