



Paulus Sugianto <paulus.sugianto.unair@gmail.com>

Submit article : case report "Secondary Fahr's Disease: A Differential to be Considered in a COVID-19 Pneumonia Patient with Neuropsychiatric Presentations"

5 messages

Paulus Sugianto <paulus.sugianto.unair@gmail.com>
To: editor@rjn.com.ro

Fri, Aug 6, 2021 at 9:44 AM

August 6th, 2021

Dear Editor-in-Chief
Romanian Journal of Neurology

I am pleased to submit an case report entitled "Secondary Fahr's Disease: A Differential to be Considered in a COVID-19 Pneumonia Patient with Neuropsychiatric Presentations" for being considered to be published in the Romanian Journal of Neurology. In this manuscript, we believe this manuscript is appropriate for publication by the rjn because fit within the journal's aim and scope to communicate high-quality articles in the field of anaesthesiology, perioperative neurology. This manuscript has not been published as well as not under consideration to be publishes elsewhere. We have no conflicts of interest to disclose and no special preference regarding those who is expected or not expected to review the manuscript.

Thank you for your consideration.

Sincerely,

Paulus Sugianto
Department of Neurology, Faculty of Medicine,
Universitas Airlangga, Surabaya, Indonesia,
Dr. Soetomo General Hospital,
Jl. Mayjen Prof. Dr. Moestopo 47, Surabaya, Indonesia (Zip Code: 60131)

3 attachments **cover letter.docx**
19K **Informed Consent Form (2).doc.docx**
46K **Secondary fahr disease_Case Report 2.docx**
340K

Anca Haldan <anca.haldan@amaltea.ro>
To: Paulus Sugianto <paulus.sugianto.unair@gmail.com>

Fri, Aug 6, 2021 at 7:44 PM

Dear author,

We received your article. Thank you.

Your article will be considered for the 4th issue of 2021, which will be online at the end of December.

Best regards,



Anca HALDAN, MD
Medical Editor
Mobil: 0742 155 512
Tel.: 021 210 45 55 | 031 405 99 00
Email: anca.haldan@amaltea.ro

[Quoted text hidden]



Virus-free. www.avast.com

Anca Haldan <anca.haldan@amaltea.ro>
To: Paulus Sugianto <paulus.sugianto.unair@gmail.com>

Sun, Sep 19, 2021 at 8:46 PM

Dear author,

After we receive the answer of the reviewers I will send you an acceptance letter, most probably at the end of October.

Best regards,



Anca HALDAN, MD
Medical Editor
Mobil: 0742 155 512
Tel.: 021 210 45 55 | 031 405 99 00
Email: anca.haldan@amaltea.ro

From: Paulus Sugianto
Sent: Friday, September 17, 2021 12:53
To: Anca Haldan
Subject: Re: Submit article : case report "Secondary Fahr's Disease: A Differential to be Considered in a COVID-19 Pneumonia Patient with Neuropsychiatric Presentations"

Dear Editor-in-Chief of the Romanian Journal of Neurology,

We had submitted a case report on August 6th, 2021 with title "Secondary Fahr's Disease: A Differential to be Considered in a COVID-19 Pneumonia Patient with Neuropsychiatric Presentations" for being considered to be published in the Romanian Journal of Neurology at the end of December.

If our manuscript suitable with your criteria, could we asked for the letter of acceptance or the ID of the manuscript?

Thank you very much for your attention.

Yours sincerely,

Paulus Sugianto, MD, PhD

[Quoted text hidden]

Paulus Sugianto <paulus.sugianto.unair@gmail.com>
To: Anca Haldan <anca.haldan@amaltea.ro>

Fri, Nov 12, 2021 at 7:42 AM

To the editor of the romanian journal Neurology

I am Paulus, MD,PhD who on August 6 submitted a case report entitled "Secondary Fahr's Disease: A Differential to be Considered in a COVID-19 Pneumonia Patient with Neuropsychiatric Presentations" for being considered to be published in the Romanian Journal of Neurology at December, I have email about my manuscript getting letter of accepted in last October, but now i have not get it, when can I receive the letter of accepted or the ID of the manuscript, thank you.

Yours sincerely,

Paulus Sugianto, MD,PhD

[Quoted text hidden]



Anca HALDAN, MD
Medical Editor
Mobil: 0742 155 512
Tel.: 021 210 45 55 | 031 405 99 00
Email: anca.haldan@amaltea.ro

Editura-Amaltea-Anca[3].gif
14K

Anca Haldan <anca.haldan@amaltea.ro>
Reply-To: Anca Haldan <anca.haldan@amaltea.ro>
To: Paulus Sugianto <paulus.sugianto.unair@gmail.com>

Sun, Nov 28, 2021 at 9:26 PM

Dear author,

I have the confirmation of the reviewers that your article will be online at the end of December, in the December issue.

[Quoted text hidden]

Secondary Fahr's disease: A differential to be considered in a COVID-19 pneumonia patient with neuropsychiatric presentations

Felisitas Farica Sutantoyo, Paulus Sugianto

Department of Neurology, Faculty of Medicine, Airlangga University, Dr. Soetomo General Hospital, Surabaya, Indonesia

ABSTRACT

Background, aim. Fahr's disease is a rare neurodegenerative disease caused by intracranial calcifications. This case report aims to accentuate the importance of considering rare disease like Fahr's disease as the differential diagnosis of neuropsychiatric deficits, especially in patients with a history of thyroidectomy.

Case presentation. A 50-year-old female who underwent thyroidectomy 5 years previously presented with incoherent speech, behavioural problems, and hand stiffness. On evaluation, several neurobehavioral deficits and carpopedal spasms were observed, along with low Mini-Mental State Examination (MMSE), Hachinski, Activities of Daily Living (ADL), and Instrumental Activities of Daily Living Scale (IADL) score of 22, 4, 13, and 12, respectively. Clinically significant laboratory abnormalities include low serum calcium of 4.7 mg/dl, low thyroid stimulating hormone (TSH) level of 0.113 mIU/l, and low parathyroid hormone (PTH) level of 1.2 pg/ml. In addition, severe acute respiratory syndrome coronavirus-2 (SARS-CoV-2) reverse transcription-polymerase chain reaction (RT-PCR) test showed a positive result. Meanwhile, brain computerized tomography (CT)-scan results showed multiple bilateral calcifications in the basal ganglia, bilateral cortical-subcortical calcifications in the frontal lobe, and subcortical calcification in the left frontal lobe.

Results. The patient was diagnosed with Fahr's disease secondary to post-thyroidectomy hypoparathyroidism and coronavirus disease 2019 (COVID-19). The patient was treated with calcium lactate, levothyroxine, donepezil, favipiravir for COVID's infection, vitamin B1, B6, and B12.

Conclusions. Fahr's disease should be considered in patients with neuropsychiatric deficits and spasm disorders, especially in patients with a history of thyroidectomy. Routine follow-up CT-scans after thyroidectomy are recommended.

Keywords: basal ganglia calcification, Fahr's disease, hypoparathyroidism

INTRODUCTION

Fahr's disease is one of the rarest neurodegenerative diseases with a very low prevalence (approximately less than one per million population) and is considered underreported. It was first discovered in 1930 by a German pathologist, Karl Theodor Fahr, who described a case of a male patient presented with symmetrical calcifications of the basal ganglia and cerebral cortex [1,2]. Fahr's disease can be classified as primary and secondary. Primary Fahr's disease is an inherited disease characterized by the presence of an abnormal autosomal dominant or

recessive genetic trait. Meanwhile, secondary Fahr's disease (also known as Fahr's syndrome) is caused by known etiologies and commonly characterized by the presence of endocrinopathies [3]. Patients with a history of thyroidectomy are at risk of developing hypoparathyroidism which is considered a rare metabolic disorder. Hypoparathyroidism causes a decrease in parathyroid hormone secretion which eventually causes hypocalcaemia and calcifications.[4] In this case report, we reported a case of a COVID-19 female patient with a history of thyroidectomy and was diagnosed with Fahr's disease. We

Corresponding author:
Paulus Sugianto
E-mail: paulus.sugianto.unair@gmail.com

Article history:
Received: 15 September 2021
Accepted: 20 December 2021

aim to accentuate the importance of considering rare disease like Fahr's disease as the differential diagnosis of neuropsychiatric deficits, especially in patients with hypoparathyroidism who underwent thyroidectomy.

The patient has given permission and informed consent for the publication of this case report.

CASE PRESENTATION

A 50-year-old female patient was admitted to the hospital upon a previous hospital referral with suspected encephalitis. The patient's family noticed changes in the patient's overall behaviour, including incoherent speech, forgetfulness, and blank stare since the last 9 days before admission. Incoherent speech was fluctuating, however, since the last 3 days before admission, it has gotten worse and the patient was unable to carry out daily activities as a housewife. According to the patient's family, the patient has never experienced similar complaints before. Moreover, the patient's hands often looked stiff and have gotten worse since the last 2 days before admission, the patient's family was worried that these symptoms are part of seizures. In addition, the patient also had complaints of cough and cold with white nasopharyngeal discharge since the last 7 days before admission. Weakness or tingling of the body, headache, fever, shortness of breath, sore throat, and micturition or

defecation disorders were denied. The patient had undergone a thyroidectomy in November 2016, with anatomical pathology examination results, namely an adenomatous goitre with bleeding without signs of neoplasm. The patient consumed levothyroxine after the thyroidectomy for an unknown period of time until her thyroid value was considered normal. History of stroke, tumour, trauma, central nervous system infection, autoimmune disorder, similar symptoms in the family, contact with COVID-19 patients was denied. History of narcotic and psychotropic drugs consumption, smoking, alcohol consumption, tattoo, and unhealthy sex was also denied.

On admission, the patient's vital signs were within normal limits, the patient had a blood pressure of 120/70 mmHg, heart rate of 110/minute, respiratory rate of 20/minute, and oxygen saturation of 98% on room air. The patient's neurological examination results were also within normal limits. The patient later underwent neurobehavioral assessments. Based on neurobehavioral assessments, cognitive impairments in memory, attention, language/verbal and visual-spatial domains were observed, with a Mini-Mental State Examination (MMSE) total score of 22/30. Next, laboratory test results showed low serum calcium of 4.7 mg/dl, low thyroid stimulating hormone (TSH) level of 0.113 mIU/l, and low parathyroid hormone (PTH) level of 1.2 pg/ml, which indicated hypocalcaemia and hypoparathyroidism.

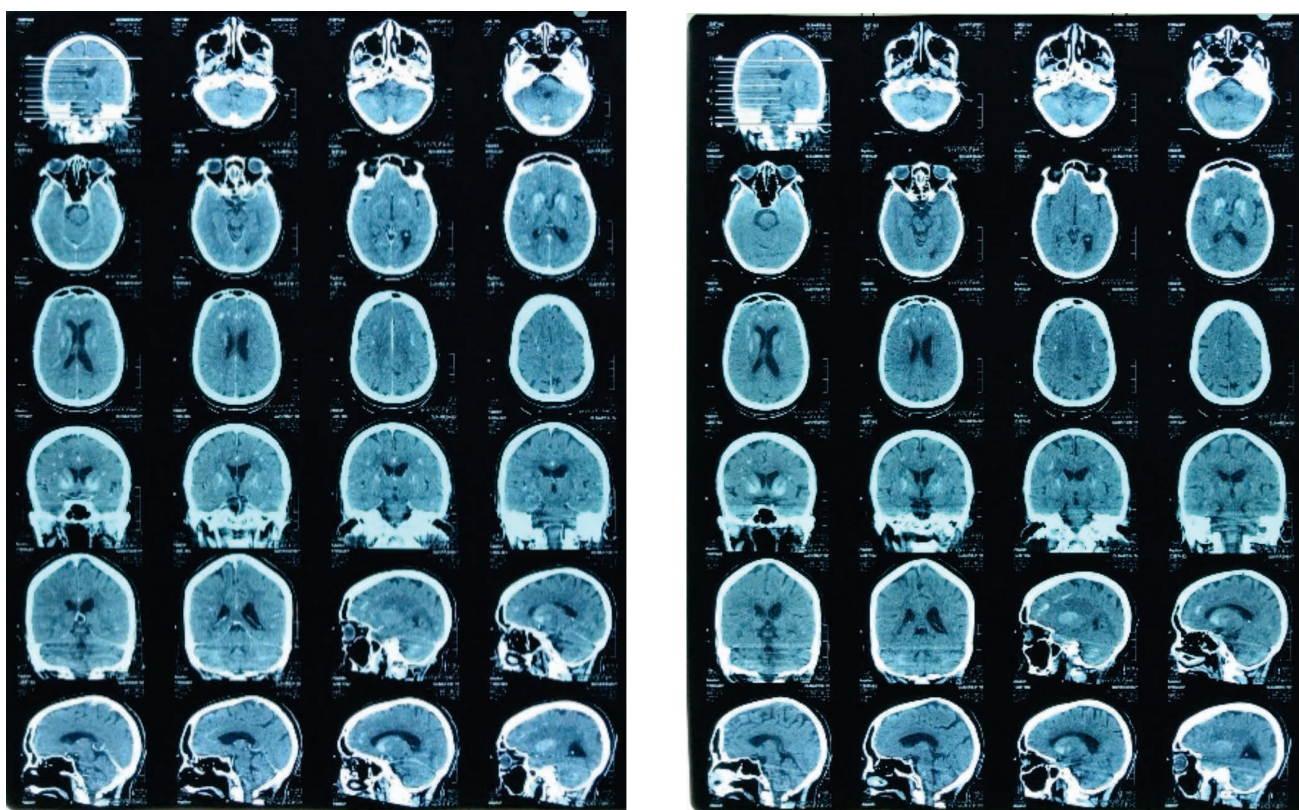


FIGURE 1. CT-scan of the brain shows multiple intracranial calcifications

Electroencephalogram (EEG) showed normal results which excluded the suspicion of seizures. In addition, severe acute respiratory syndrome coronavirus-2 (SARS-CoV-2) reverse transcription-polymerase chain reaction (RT-PCR) test showed a positive result. Furthermore, brain computerized tomography (CT)-scan results showed multiple bilateral calcifications in the basal ganglia, bilateral cortical-subcortical calcifications in the frontal lobe, and subcortical calcification in the left frontal lobe (as shown in Figure 1).

Based on the clinically significant findings, the patient was diagnosed with Fahr's disease secondary to post-thyroidectomy hypoparathyroidism and coronavirus disease 2019 (COVID-19). The patient was treated with 5 g of 20% MgSO₄ in 0.9% NaCl by drip for 24 hours, 3x2 ampules of calcium gluconate in 0.9% NaCl by drip, 2x1 g of intravenous ceftriaxone, 1x5 mg of oral donepezil, 1 x 100 mcg of oral levothyroxine, 2x1 tablet of oral vitamin B1, B6, and B12, 3 x 1000 mg of oral calcium lactate, and 2 x 1600 mg for loading dose and continued 2 x 600 mg for 5 days of favipiravir. After being discharged from the hospital, the antibiotic therapy was replaced by 2 x 100 mg of oral cefixime and the previous oral therapies were continued.

DISCUSSION

Fahr's disease (or Fahr's syndrome), also known as basal ganglia calcification, is a rare neurodegenerative disease. Fahr's disease is characterized by a wide range of progressive neuropsychiatric symptoms [2,5]. Neuropsychiatric and cognitive impairment are common and progressive. Neuropsychiatric symptoms might be the first or the most common features of Fahr's disease, ranging from mild concentration and memory deficits to personality and/or behaviour changes. In some extreme cases, it might also lead to psychosis and dementia. The patient in this case had a low MMSE score with marked cognitive impairment in memory, attention, language/verbal and visual-spatial domains which might be caused by Fahr's disease-related mild cognitive impairment, however, further evaluation is needed to observe the changes in the patient's behaviour [6,7]. In addition, the patient was also confirmed with COVID-19 pneumonia which could exacerbate the neuropsychiatric symptoms. According to Ticinesi et al., neuropsychiatric symptoms (i.e. delirium) are common in COVID-19 patients, especially in geriatric patients with neuropsychiatric comorbidities [8,9].

Furthermore, it was known that the patient has a history of thyroidectomy with a marked decrease

in serum calcium, TSH, and PTH level, which indicated hypocalcaemia and hypoparathyroidism. According to similar case reports by Arruda et al. and Zhou et al., patients with a history of thyroidectomy are at risk of developing hypoparathyroidism, a rare metabolic disorder that can cause a decrease in parathyroid hormone secretion which later disturb calcium mobilization from bone and calcium reabsorption from kidneys and gut. This condition eventually causes hypocalcaemia and calcifications. Although rare, this condition can also cause intracerebral calcifications which later manifested as Fahr's disease [4,10].

CT-scan and magnetic resonance imaging (MRI) are widely used to identify mineral depositions. Calcified areas are identified as hyperdense lesions on CT-scan which is considered crucial for diagnosis. On brain CT-scans, Fahr's disease is characterized by bilateral basal ganglia calcification and usually associated with phosphorus and/or calcium metabolism disorders. Calcium deposits consist up of calcium carbonate and calcium phosphate which are most commonly located in the basal ganglia, followed by thalamus, hippocampus, cerebral cortex, cerebellar subcortical white matter, and dentate nucleus [2,5,11,12]. In this patient, the brain CT-scan results showed multiple bilateral calcifications in the basal ganglia, bilateral cortical-subcortical calcifications in the frontal lobe, and subcortical calcification in the left frontal lobe, which are considered decisive for the diagnosis of Fahr's disease.

To date, there is no definitive cure for Fahr's disease yet. The treatment for Fahr's disease targets the symptoms and quality of life improvement. Treatment of underlying conditions like hypoparathyroidism has been shown to improve the symptoms, however, there are no specific treatments that can limit the progression of intracerebral calcifications. The prognosis is variable, unpredictable, and is known to be unrelated to the calcification extent. If not treated properly, progressive neurological deterioration may result in disability and death [13,14].

CONCLUSIONS

Fahr's disease should be considered as one of differential diagnoses in patients with neuropsychiatric deficits and spasm disorders, especially in patients who underwent thyroidectomy who are in risk of hypoparathyroidism. Therefore, we recommend routine follow-up CT-scans after thyroidectomy which enables health care providers to detect and treat Fahr's disease as early as possible.

REFERENCES

1. Jaworski K, Styczyńska M, Mandecka M, Walecki J, Kosior DA. Fahr Syndrome – an Important Piece of a Puzzle in the Differential Diagnosis of Many Diseases. *Polish J Radiol.* 2017;82:490-3.
2. Saleem S, Aslam H, Anwar M, Anwar S, Saleem M, Saleem A, et al. Fahr's syndrome: literature review of current evidence. *Orphanet J Rare Dis.* 2013;8(1):156.
3. Lippmann S, Perugula ML. Differential Diagnoses: Fahr's Disease or Fahr's Syndrome. *Innov Clin Neurosci.* 2018;13(7-8):45-8.
4. Arruda ACG de, Guerra ACDZ, Pessoa CH, Marquezine GF, Delfino VDA. Hypoparathyroidism and Fahr's syndrome: case series. *Brazilian J Nephrol.* 2021;1-5.
5. Mahmood N, Hamid J, Khan F, Khurram M, Alam M. Secondary Fahr's Disease: A Consequence of Post-Thyroidectomy Hypoparathyroidism. *Eur J Case Reports Intern Med.* 2019;6(6):1.
6. Otu AA, Anikwe JC, Cocker D. Fahr's disease: a rare neurological presentation in a tropical setting. *Clin Case Reports.* 2015;3(10):806-8.
7. Kumar DS. "Fahr's Disease"- A Rare Entity Presenting with Cognitive Impairment and Neuro-Psychiatric Behavioural Symptoms. *J Med Sci Clin Res.* 2016;04(11):14224-8.
8. Ticinesi A, Cerundolo N, Parise A, Nouvenne A, Prati B, Guerra A, et al. Delirium in COVID-19: epidemiology and clinical correlations in a large group of patients admitted to an academic hospital. *Aging Clin Exp Res.* 2020;32(10):2159-66.
9. Kennedy M, Helfand BKI, Gou RY, Gartaganis SL, Webb M, Moccia JM, et al. Delirium in Older Patients With COVID-19 Presenting to the Emergency Department. *JAMA Netw Open.* 2020;3(11):e2029540.
10. Zhou Y-Y, Yang Y, Qiu H-M. Hypoparathyroidism with Fahr's syndrome: A case report and review of the literature. *World J Clin Cases.* 2019;7(21):3662-70.
11. Donzuso G, Mostile G, Nicoletti A, Zappia M. Basal ganglia calcifications (Fahr's syndrome): related conditions and clinical features. *Neurol Sci.* 2019;40(11):2251-63.
12. Schupper AJ, Chen MM. A Unique Presentation Of Fahr Syndrome Secondary To Chronic Hypoparathyroidism: A Case Report. *Imaging Med.* 2018;10(5):129-31.
13. Pourshahid S, Salloum MN, Elfishawi M, Barakat M, Basith M. Fahr's Disease: A Differential to Be Considered for Various Neuropsychiatric Presentations. *Cureus.* 2018;10(3):3-6.
14. Ahad MA, Kamal S, Salma U. Fahr's Syndrome: A Rare Neurodegenerative Disorder. *Med Today.* 2017;29(1):39-41.