



PAULUS SUGIANTO <paulus.sugianto@fk.unair.ac.id>

---

## [ijhs] Submission Acknowledgement

1 pesan

---

**Prof. Dr. M. R. Herrera** <editorsciencescholar@gmail.com>  
Kepada: Paulus Sugianto <paulus.sugianto@fk.unair.ac.id>

18 Juli 2022 17.19

Hello,

Prof. Dr. Maria R. Herrera has submitted the manuscript, "Cerebellar tuberculoma in an immunocompetent patient: A case report and literature review" to International journal of health sciences.

If you have any questions, please contact me. Thank you for considering this press as a venue for your work.

Prof. Dr. M. R. Herrera

**Editor-in-Chief**

[ijhs@utm.edu.ec](mailto:ijhs@utm.edu.ec) | [ijhs@sciencescholar.us](mailto:ijhs@sciencescholar.us)

**M. R. Herrera**, Scopus ID: [7202050008](https://orcid.org/0000-0002-7202-0500), Nursing, Universidad de Camagüey, Camaguey, Cuba

---

[International journal of health sciences](#)



PAULUS SUGIANTO &lt;paulus.sugianto@fk.unair.ac.id&gt;

---

## [ijhs] Submissions with Production Completed

1 pesan

---

**Prof. Dr. Maria R. Herrera** <editorsciencescholar@gmail.com>  
Kepada: Wendy Amelia Sihombing <paulus.sugianto@fk.unair.ac.id>

18 Juli 2022 17.20

Wendy Amelia Sihombing, Paulus Sugianto:

The editing of your submission, "Cerebellar tuberculoma in an immunocompetent patient: A case report and literature review," is complete. We are now sending it to production.

Submission URL: <https://sciencescholar.us/journal/index.php/ijhs/authorDashboard/submission/10774>

**If you wish to Increase the Citation Index of your articles, follow these steps immediately:**

1. Join [SSRN of Elsevier](#) for FREE and upload all published articles here. This network will increase your citation very fast.
2. Join [Academia Edu](#) for FREE and upload the article here. Select keywords carefully so that it reaches to maximum audiences. [Can easily join by GMail]
3. Create a Google Scholar account and you can manually add your articles.
4. Join [Mendeley's network](#) and share your published article with peers.
5. Upload in your University repositories and share your article with colleagues and peers.
6. Share the above URL of your article on Facebook, Twitter, and linked-in platforms so that your contacts can see your work and can read and cite.

**Chief Executive Editor**

**M. R. Gámez**, Scopus ID: [57204684841](#), Universidad Técnica de Manabí, South America  
[executive\\_editor@utm.edu.ec](mailto:executive_editor@utm.edu.ec) | [executive\\_editor@sciencescholar.us](mailto:executive_editor@sciencescholar.us)

---

[International journal of health sciences](#)

## Editor-in-Chief

[ijhs@utm.edu.ec](mailto:ijhs@utm.edu.ec) | [ijhs@sciencescholar.us](mailto:ijhs@sciencescholar.us)

**M. R. Herrera**, Scopus ID: [7202050008](#), Nursing, Universidad de Camagüey, Camagüey, Cuba

---

[International journal of health sciences](#)



PAULUS SUGIANTO &lt;paulus.sugianto@fk.unair.ac.id&gt;

---

**[ijhs] Editor's Decision [Accept]**

1 pesan

---

**Prof. Dr. Maria R. Herrera** <editorsciencescholar@gmail.com>  
Kepada: Wendy Amelia Sihombing <paulus.sugianto@fk.unair.ac.id>

18 Juli 2022 17.20

Wendy Amelia Sihombing, Paulus Sugianto:  
Paper ID: **[IJHS-10774]**

We have reached a decision regarding your submission to International journal of health sciences, "Cerebellar tuberculoma in an immunocompetent patient: A case report and literature review".

Thank you for submitting your manuscript to **Universidad Tecnica de Manabi**. The paper was received, checked with Turnitin/iThenticate and no similarities were found, and ultimately was registered for peer-reviewing. Please always quote your Paper ID in all future inquiries or communications. You will be notified regarding the editorial result and production.

Your submission to IJHS implies that the manuscript has not been published previously with a max 15% Turnitin report, and is not currently submitted for publication elsewhere. If any case of concurrent submission is found, the submission will be immediately rejected and the author's names will be put on our blacklist.

Author(s) should note that they will be requested to pay the article processing charges, for more details please visit <https://sciencescholar.us/journal/index.php/ijhs/apc>

Do not hesitate to contact us if you have any inquiries. Thank you for considering this journal as a venue for your work. Our decision is **Approved for Publication**

Three publication procedures are expected to be completed: (1) paper charge payment, (2) paper revision, and (3) copyright form. After the payment is made, details of the other two publication procedures (2) paper revision, and (3) copyright form will be sent to you.

It is a pleasure to accept your manuscript for publication in IJHS. The comments of the referee(s) who reviewed your manuscript are included at the bottom of this letter.

---

Referee(s)' Comments to Author:

---

Reviewing #1

Comments to the Author

Acceptable and considerable for publication

*Significance*

- The manuscript represents a new and demonstratively significant advancement in research on international students

*Review of Literature*

- The manuscript includes a well-organized and analytical review of relevant literature
- The manuscript uses a clear and well-developed theoretical/conceptual framework

*Research Design*

- The manuscript reflects appropriate design and methodology
- The manuscript reflects high-quality data and analysis

*Discussion*

- The discussion and conclusion highlight the relevance of the findings for research, policy, and practice

## Style

- The manuscript clear, logical, and concise
- 

## Reviewing #2

### Comments to the Author

### Recommended to Associate Editor

- The manuscript must follow APA publication guidelines and will be done by Copy Editor.
- Production Editor will arrange all term of APA citation in copy editing, therefore, they have a responsibility regarding the contents of the manuscript
- Acceptable for next copy-editing process and recommended to Associate Editor.

### Associate Editor Comments to Author:

### Comments to Author:

- The content of the manuscript is consistent with the scope and aims of the journal
- The manuscript consistently includes articles that are scientifically sound and relevant to an international academic or professional audience in this field by citations in other journals currently covered by Scopus.
- Approve for publication and recommended to Publisher.

## Chief Executive Editor

**M. R. Gámez**, Scopus ID: [57204684841](#), Universidad Técnica de Manabí, South America  
[executive\\_editor@utm.edu.ec](mailto:executive_editor@utm.edu.ec) | [executive\\_editor@sciencescholar.us](mailto:executive_editor@sciencescholar.us)

---

[International journal of health sciences](#)

## Editor-in-Chief

[ijhs@utm.edu.ec](mailto:ijhs@utm.edu.ec) | [ijhs@sciencescholar.us](mailto:ijhs@sciencescholar.us)

**M. R. Herrera**, Scopus ID: [7202050008](#), Nursing, Universidad de Camagüey, Camagüey, Cuba

---

[International journal of health sciences](#)

## Letter of Acceptance

Dear Author(s),

Mr./Mrs. Paulus Sugianto

Title: *Cerebellar Tuberculoma In An Immunocompetent Patient: A Case Report and Literature Review*

*Reference your article, I would like to inform you that the 1st round evaluation of your manuscript has been completed. Based on the reviewer's recommendations, I am delighted to inform you that your manuscript has been initially accepted. The article as well as has been processed utilizing the peer-review process, and has been accepted for publication. The article will be published in International Journal of Health Sciences (IJHS) for the next publication.*

Thank you very much for submitting your article to "International Journal of Health Sciences."  
e-ISSN: 2550-696X, p-ISSN: 2550-6978

Journal Impact Factor

(SJIF 2021: 6.553)

(Google-based Impact Factor 2021: 3.722)

Citations: 367, h-index: 11, i10-index: 15

Abstracting and Indexing (click to view):

SCOPUS, Index Copernicus International, Elsevier Mendeley, Thomson Reuters, CrossRef (PILA), Google Scholar, ROAD (Directory of Open Access Scholarly Resources), Bielefeld University Library, Simon Fraser University Library, OAI Organization, CiteULike, Indonesian Publication Index, Directory Indexing of International Research Journals, WorldCat, Microsoft Academic, GARUDA RISTEKDIKTI, International Scientific Indexing (ISI), WorldCat.

Thank you for your contribution to the Journal and we are looking forward to your future participation!

Best Regards,

Prof. María Rodríguez Gámez, Ph.D.  
Chief Executive Editor



### Contact and Information

Email : [ijhs@utm.edu.ec](mailto:ijhs@utm.edu.ec)

Website : [IJHS Homepage](#)

Publisher: Universidad Técnica de Manabí





**EJA**

**WENDY SIHOMBING**  
SURABAYA, INDONESIA

**INVOICE NO**  
**EJA-275**

**DATE: JULY, 2022**

---

<b>QTY</b>	<b>DESCRIPTION</b>	<b>TOTAL</b>
1	JOURNAL APC - IJHS (250 USD)	3.000.000

---

**TOTAL: 3.000.000**

**PAID**

**PAYMENT INFORMATION:**

BANK: MANDIRI

NAME: ARIF NUR MUHAMMAD ANSORI

ACCOUNT NUMBER: 1420016277443

**How to Cite:**

Sihombing, W. A., & Sugiarto, P. (2022). Cerebellar tuberculoma in an immunocompetent patient: A case report and literature review. *International Journal of Health Sciences*, 6(S6), 1629–1640. <https://doi.org/10.53730/ijhs.v6nS6.10774>

## **Cerebellar tuberculoma in an immunocompetent patient: A case report and literature review**

**Wendy Amelia Sihombing**

Department of Neurology, Faculty of Medicine, Universitas Airlangga – Dr. Soetomo General Academic Hospital, Surabaya, Indonesia

**Paulus Sugiarto**

Department of Neurology, Faculty of Medicine, Universitas Airlangga – Dr. Soetomo General Academic Hospital, Surabaya, Indonesia

\*Corresponding author email: [paulus.sugiarto@fk.unair.ac.id](mailto:paulus.sugiarto@fk.unair.ac.id)

**Abstract**---Background: Tuberculosis infection of the Central Nervous System is the major cause of death and morbidity in developing countries. The clinical manifestations and radiological findings in tuberculoma are nonspecific. This article reports a rare case of cerebellar tuberculoma with the manifestation related to an intracranial mass and without the typical clinical symptoms of Tuberculosis in an immunocompetent patient. Case Report: A 20-year-old female with seizure, headache, and vertigo. A mass in the posterior fossa was revealed by Magnetic Resonance Imaging. Thorax scan results showed the Tuberculosis process. The patient then underwent surgery. Histopathological examination displayed chronic granulomatous inflammation and the presence of Acid-Fast Bacilli. The patient received anti-tuberculous drug treatment for one year and anti-seizure medication. Discussion: Cerebellar tuberculoma can resemble an intracranial tumor or cranial abscess. Diagnosis is based on clinical, radiological manifestations, and histopathological analysis. Surgical intervention still has a role in the treatment of this disease. The finding of Mycobacterium tuberculosis on histopathological examination is the gold standard in diagnosing Tuberculosis. Conclusions: Although it is rare, the involvement of Tuberculosis in the CNS should be taken into account in both immunocompetent and immunocompromised patients with neurological symptoms who are living in an endemic area.

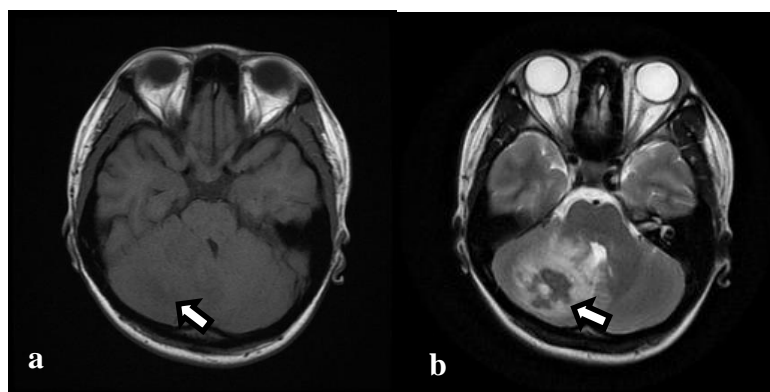
**Keywords**---cerebellar tuberculoma, CNS tuberculosis, disseminated tuberculosis, extrapulmonary tuberculosis.

## Introduction

Tuberculosis infection of the CNS is the major cause of death and morbidity in developing countries (Zahrou *et al.*, 2019). It occurs in 2-5% of TB patients and 10% of Human Immunodeficiency Virus (HIV) patients (Weidauer *et al.*, 2020). Tuberculous meningitis (TBM) is the most common form of CNS TB with a lower incidence than intracranial tuberculoma, tuberculous brain abscess, tuberculous encephalopathy, spinal cord tuberculous meningitis, non-osseous spinal cord tuberculosis, Pott's paraplegia, and Pott's spine (Chen *et al.*, 2018), (Israr Khan *et al.*, 2019). Infection of MTB can result in the hematogenous or lymphatic spread of the pathogens, which can lead to pulmonary and extrapulmonary TB (Sutantoyo and Sugianto, 2022). CNS tuberculoma is a rare cause of intracranial masses; they are granulomas that form from an inflammatory response to MTB infection, with 3-4% of cases involving the cerebellum (Bouali *et al.*, 2020), (Er *et al.*, 2018). Cerebellar or brainstem tuberculoma is found at much lower rates in adults (Bouali *et al.*, 2020). The radiological findings of CNS tuberculoma are nonspecific, and usually similar to other diseases (Agrawal *et al.*, 2020). Therapeutic approaches and results depend on identifying the source of CNS infections (Imran *et al.*, 2019). We illustrate this case because it is rare in immunocompetent patients and the issue is in preoperative analysis. We describe the clinical presentation, imaging, pathological findings, management, and outcomes.

## Case report

A 20-year-old female, with no medical history, presented with the first-time seizures in her life and a history of fever, headache, vertigo, nausea, vomiting, and, tendencies to fall to the right side when standing. A neurological examination revealed an abnormal cerebellar function test. The serology of the HIV test was negative and there was an increase in the Erythrocyte Sedimentation Rate (ESR) by 62 mm/hour. Electroencephalography findings showed intermittent slow activity and sharp waves in the left temporal region suggesting there was potential epileptogenicity in the left temporal lobe. The results of thorax Computed Tomography (CT), revealed the tuberculosis process. Initial head MRI displayed solid intra-axial lesions with well-defined, irregular edges on the right cerebellum, with cerebellar tonsillar herniation (Fig. 1a-d)





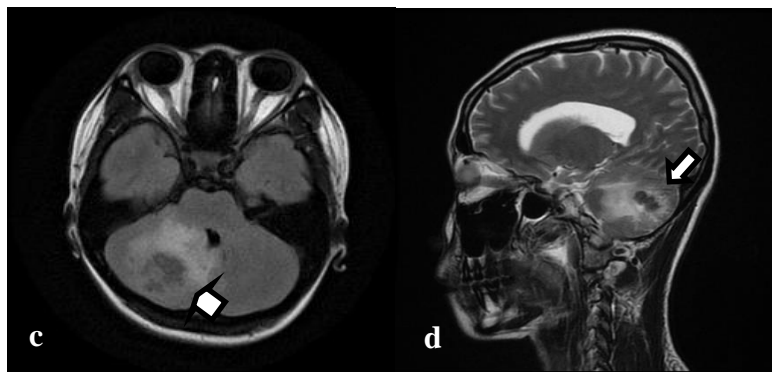


Figure 1. MRI findings: isointense on T1W1 (a), slightly hyperintense on T2W1 (b), appeared hypointense on T2 Fluid-Attenuated Inversion Recovery (FLAIR) (c), sagittal T2 (d)

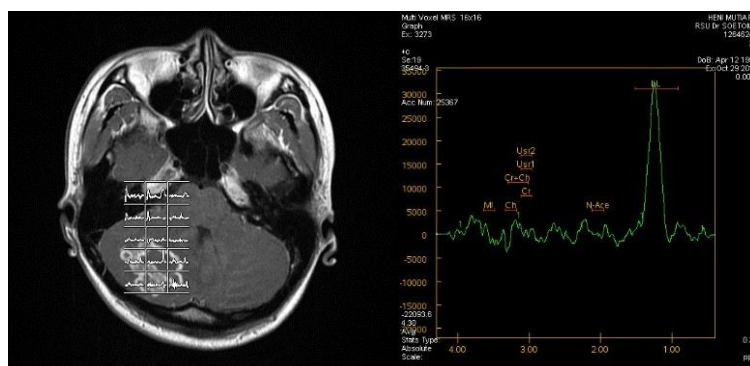


Figure 2. MR Spectroscopy

MR spectroscopy reveals increased Cholin/Creatinine and Cholin/NAA ratios, as well as high lipid concentrations in the intra- and perilesional. The patient underwent surgical specimens of the cerebellar mass, and intraoperative findings revealed a solid, spongy mass, with well-defined lobes, easily separated from the cortex. In conclusion, histopathology shows chronic granulomatous inflammation suggestive of tuberculosis.

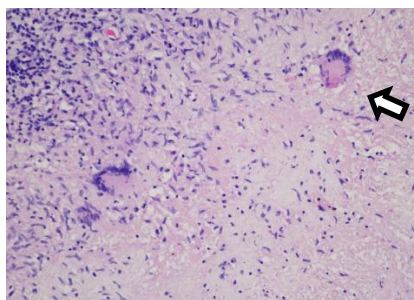


Figure 3. Histopathological appearance showing granulomatous inflammation with central caseous necrosis and datia Langhans cells 20x magnification

Rifampicin, isoniazid, and pyrazinamide were given for 2 months, followed by isoniazid and rifampicin for 10 months. The patient also received an intramuscular injection of streptomycin for the first 2 months and phenytoin for anti-seizure medication. One year of treatment led to clinical improvement and a decrease in ESR from 62 mm/hour to 3 mm/hour. The chest x-ray evaluation revealed no abnormality.

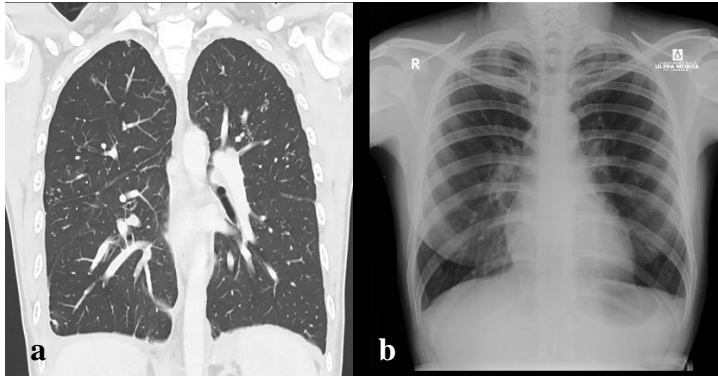

Figure 4. (a) Initial Thorax CT scan showing Tb process, (b) Normal chest x-ray evaluation

Head MRI evaluation after 1-year treatment showed gliosis and hemiatrophy on the right cerebellum.

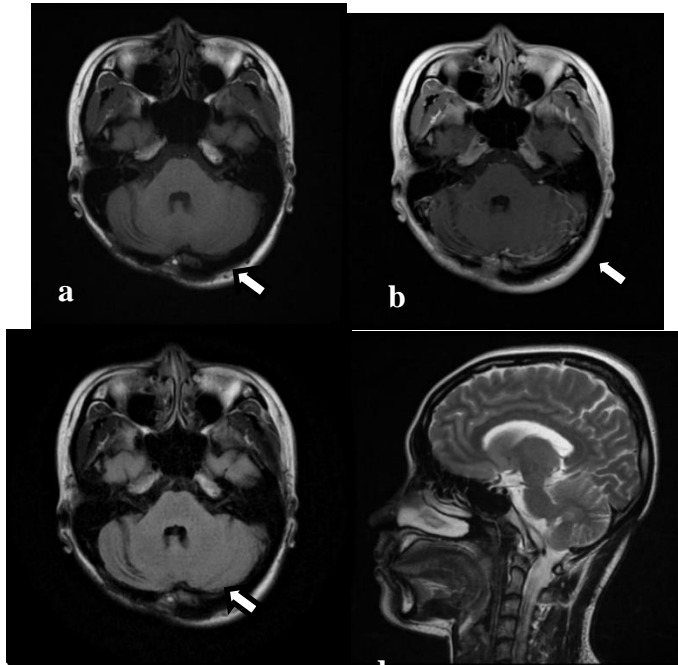


Figure 5. Radiological findings (evaluation), hypointense on T1W1 (a) no contrast enhancement (b), hypointense on T2 FLAIR (c), hyperintense on T2W1, sagittal (d)

## Discussion

### Epidemiology

TB remains a worldwide burden, with the vast majority of recent active TB cases occurring in underdeveloped and developing countries (Rock *et al.*, 2008). Intracranial tuberculoma expands in approximately 1% of all sufferers with active TB (Ikbal and Sugianto, 2022). However, it can develop without evidence of active disease (Chen *et al.*, 2018),(Nicolls *et al.*, 2005). Hematogenous spread of tuberculosis causes CNS involvement, which can occur supra- and infratentorial (though posterior fossa involvement is uncommon) and manifest as single or multiple lesions (Fabrizio *et al.*, 2017). Intracranial tuberculoma primarily occurs in the supratentorial region in adults and the infratentorial region in children, often in the frontal and parietal regions (Bouali *et al.*, 2020). CNS TB is more common in immunocompromised patients (Binesh, Zahir, and Bovanlu, 2013). Risk factors for CNS tuberculosis include age (children are more common than adults), HIV coinfection, malnutrition, history of measles in children, alcoholism, the presence of malignant tumors, and use of immunosuppressive agents in adults (Binesh, Zahir and Bovanlu, 2013). However, in this case, the patient is an immunocompetent young female without any risk factor and has no history of pulmonary TB.

### Pathophysiology

MTB bacteria are inhaled as droplet nuclei, which leads to infection, and bacilli accumulation in the alveoli of the lungs. Bacilli are processed into draining lymph nodes early in this phase, leading up to the infection containment, and there is low-level bacteremia, in which MTB spreads to distant places in the body. The brain and other organs with high oxygen levels are where hematogenous seeding occurs most frequently (Rock *et al.*, 2008). Tuberculoma is caused by the growth of rich foci that are surrounded by intracerebral tissue (Chaulagain, 2019). Tuberculomas are considered to form when tubercles in the brain parenchyma grow without rupturing into the subarachnoid space (Rock *et al.*, 2008). A tuberculoma of the brain exhibits a classic granulomatous reaction containing epithelioid cells, giant cells, and main lymphocytes around a central area of caseating necrosis (Rock *et al.*, 2008). In contrast to pus, liquefaction of the center area of necrosis contains clear or straw-colored fluid (Rock *et al.*, 2008).

Tuberculoma of the posterior fossa is more dangerous to the patient's life than tuberculoma of the supratentorial fossa. They usually appear as solitary lesions with no indication of systemic tuberculosis, and they resemble tumors rather than the infectious process (Bouali *et al.*, 2020). According to Bernaerts and Binesh *et al.*, tuberculoma lesions located in the infratentorial commonly occur in children (Rock *et al.*, 2008),(Bernaerts *et al.*, 2003; Binesh, Zahir and Bovanlu, 2013). The reason why the lesions in children are predominantly located in the cerebellum remains unclear (Wakisaka, Soejima, And Matsuoka, 1987). Meanwhile, adults are commonly found in the frontal and parietal lobes (Bernaerts *et al.*, 2003). According to the infection hypothesis, the hematogenic spread is further enhanced by the vascular distribution, particularly in the area of

the middle cerebral artery (Zahrou *et al.*, 2019),(Gasparetto, Tazoniero and Neto, 2003).

### **Clinical findings**

Tuberculoma cannot be recognized from other lesions that occupy brain space only based on clinical symptoms (Nicolls *et al.*, 2005). Symptomatic intracranial tuberculoma depends on its anatomic location (Nicolls *et al.*, 2005),(Gupta *et al.*, 2022). Systemic symptoms vary, but the majority of patients complain of fever, headache, and weight loss (Davis, Meintjes,, and Wilkinson, 2018).The typical manifestation of cerebellar tumors are signs of increased brain pressure and cerebellar incoordination (Işik *et al.*, 2009). Headache, seizures, papilledema, and other indications of elevated intracranial pressure are common in individuals (Rock *et al.*, 2008). In tuberculoma, the onset of symptoms is usually measured in weeks or months (Rock *et al.*, 2008). After treatment, around 25% of these patients showed persistent impairments. Delays in diagnosis, extreme ages, and the presence of hydrocephalus at presentation were all linked to long-term neurological impairments (Nicolls *et al.*, 2005).

### **Diagnosis**

Clinical characteristics alone are insufficient to distinguish tuberculoma from other types of brain tumors (Thwaites *et al.*, 2009). Only 30% of cerebral tuberculoma patients have a suggestive chest radiograph (Agrawal *et al.*, 2020). Also, tubercle bacilli are not always visible in the cerebrospinal fluid (CSF), so a CSF analysis may not be helpful (Agrawal *et al.*, 2020). The diagnosis is problematic because tuberculoma cannot be distinguished from other masses, however, the neuroimaging presentation can be diverse and non-specific (Agrawal *et al.*, 2020). In many situations, biopsy remains the gold standard for intracranial tuberculoma for histopathology and acid-fast bacilli stain and culture can provide a conclusive diagnosis (Agrawal *et al.*, 2020),(Nicolls *et al.*, 2005). The patient in our case underwent surgical procedures to make a diagnosis and alleviate symptomatic or life-threatening mass effects (Marais *et al.*, 2019). Histopathology and acid-fast bacilli were used to confirm the diagnosis of a CNS lesion in the cerebellum.

### **Radiological features**

Radiological features might be helpful in the diagnosis and monitoring of the disease, as well as for the assessment of complications (Binesh, Zahir,, and Bovanlu, 2013). Any ring-enhancing lesion in the brain raises a diagnostic challenge for clinicians because the majority of these patients present with similar clinical syndromes (Soni, 2021). Tuberculoma is typically solitary lesions, but it can be multiple in 15–34 percent of cases, and it is most commonly found in the frontal and parietal lobes. Tuberculoma is a spherical granulomatous mass that is firm, avascular, and distinguished by small, round or oval-shaped nodules size in diameter from 2 to 12 mm (Agrawal *et al.*, 2020),(Rock *et al.*, 2008),(Nicolls *et al.*, 2005),(Leonard, 2021). They are clearly distinguished from the brain tissue around the lesion, which is compressed and shows gliosis and edema (Leonard, 2021). The interior of these masses may contain necrotic areas composed of

caseous material, which can be thick and purulent at times, and in which tubercle bacilli can be seen (Leonard, 2021).

### **CT scan**

A head CT scan is necessary as the initial neuroimaging modality in individuals with a suspected brain infection (Wibawani *et al.*, 2019). On CT, early lesions may appear hypodense. Lesions become isodense and show ring-enhancement after intravenous contrast administration as the capsule forms around the tuberculoma. When lesions calcify, they become hyperdense and show little enhancement. There may be minor or severe associated edema. When multiple lesions are found, each lesion may be at a different stage of progression, resulting in a patient with a mix of ring-enhancing and solid lesions (Nicolls *et al.*, 2005).

### **MRI**

Depending on the type of granulomatous lesion, the neuroimaging picture of cerebral tuberculoma differs (Agrawal *et al.*, 2020). The appearance of tuberculoma on MRI varies depending on its stage of maturation, that is, whether it is non-caseating, caseating with a solid center, or caseating with a liquid center (Binesh, Zahir, and Bovanlu, 2013). The degree of edema around the tuberculoma is thought to be inversely proportional to the age of the lesion (Rock *et al.*, 2008). If the tuberculoma consists of non-caseating granulomas, the lesion is commonly hypointense or isointense to gray matter on T1-weighted images and hyperintense on T2-weighted MR images (Agrawal *et al.*, 2020). On T1W and T2W images, a solid caseating tuberculoma appears isointense to hypointense, with an isointense to the hyperintense rim on T2W images (Binesh, Zahir and Bovanlu, 2013). Gliosis and monocyte infiltration can make a central region of T2-hypointensity visible. This is an important finding because it is not found in many other intracranial lesions (Agrawal *et al.*, 2020). In tuberculoma post-contrast imaging we usually see a peripheral ring-enhancement due to vasogenic edema (Agrawal *et al.*, 2020). In tuberculoma, central liquefactive necrosis can occur, making differentiation from a cerebral abscess difficult (Agrawal *et al.*, 2020). According to some reports, cerebral tuberculoma has the 'target sign,' which is a ring-enhancing lesion with an additional central area of enhancement or calcification (Agrawal *et al.*, 2020).

### **Diffusion-weighted MRI**

Diffusion-weighted MRI images of tuberculoma show restricted diffusion (Soni, 2021).

### **MR Spectroscopy**

Advances in MR spectroscopy have shown that tuberculoma can be distinguished from cysticercosis but not from CNS non-Hodgkin lymphoma. There is an elevated lactate peak, a decreased NAA and creatinine peak, and a choline/creatinine ratio of greater than one in tuberculoma (Thwaites *et al.*, 2009),(Soni, 2021).



Table 1  
Tuberculoma radiographic features (Bouali *et al.*, 2020),(Agrawal *et al.*, 2020),(Binesh, Zahir and Bovanlu, 2013),(Gupta *et al.*, 2022),(Leonard, 2021)

Modality	Non-caseating	Caseating with a solid center	Central liquefaction
CT Imaging			
Non-contrast	Hypo- to isodense, and rounded or lobulated masses, irregular walls	Hypo-to hyperdense	Hypodense
Contrast	Homogenous enhancement, irregular walls of varying thickness, surroundings vasogenic edema	A ring with heterogeneous enhancement in the center	Ring enhancement
MRI Imaging			
T1	Iso-hypointense	Iso/hypointense	Hypointense
T1 with gadolinium contrast	Homogenous enhancement	Ring enhancement	Ring enhancement
T2	Hyperintense	Iso/hypointense	Hyperintense, showing ring enhancement with a peripheral hypointense rim

## Treatment

### Medical management

Antituberculosis therapy (ATT) is usually effective in treating cerebral tuberculoma (Agrawal *et al.*, 2020). Similar to pulmonary TB, the majority of cases necessitate a long course of ATT lasting nine to 18 months, with an intensive phase followed by a maintenance phase (Agrawal *et al.*, 2020),(Thwaites *et al.*, 2009). The World Health Organization (WHO) recommends a 2-month initial phase of rifampicin, isoniazid, pyrazinamide, and streptomycin, followed by a 7-month maintenance phase of isoniazid and rifampicin for CNS TB, which includes tuberculoma (Leonard, 2021). The key components of the regimen are rifampicin and isoniazid. Rifampicin penetrates the CSF less well (maximum concentrations of around 30% of plasma), but the high mortality from rifampicin-resistant TBM has confirmed its central role in the treatment of CNS disease. Isoniazid easily penetrates the CSF and has potent early bactericidal activity. Even though pyrazinamide is well absorbed orally and achieves high concentrations in the CSF, there is no conclusive evidence that it improves the outcome of CNS tuberculosis (Thwaites *et al.*, 2009).

Ethambutol has the poorest penetration of the current first-line drugs, even when the BBB is inflamed, raising the question of its utility in the treatment regimen

(Davis, Meintjes and, Wilkinson, 2018). Most experts recommend streptomycin or ethambutol, though neither penetrates the CSF well in the absence of inflammation and both can cause serious side effects. Streptomycin should not be given to pregnant women or those with renal impairment, and resistance is relatively common worldwide (Thwaites *et al.*, 2009). Corticosteroids are commonly used to treat high intracranial pressure, paradoxical progression during treatment, and intracranial lesion-associated edema (Bouali *et al.*, 2020),(Nicolls *et al.*, 2005).

### **Surgery**

Surgical intervention may be required in cases of acute complications such as obstructive hydrocephalus, large lesions with significant mass effect, or brainstem compression (Agrawal *et al.*, 2020). Additionally, surgery can be performed in cases of diagnostic confusion caused by infratentorial tumors (Bouali *et al.*, 2020). Cerebellar lesions may be more commonly resected due to their increased likelihood of causing these severe symptoms (Capone *et al.*, 2021). Stereotactic craniotomy, excision of superficial small tuberculoma, and microsurgery are now used (Davis, Meintjes and Wilkinson, 2018).

### **Stereotactic**

Because of the lower surgical risk, stereotactic brain biopsy is preferred over craniotomy. Stereotactic biopsy has an overall complication rate of 0.6–6.3%, and when combined with paraffin sectioning, it has been shown to have an 85 percent diagnostic efficacy. When to conduct a brain biopsy, on the other hand, is still debatable. Most experts advise evaluating the role of biopsy on a case-by-case basis. A low threshold for performing a brain biopsy for definitive diagnosis should be used when managing patients at high risk for other infectious processes or malignancies (e.g., people infected with HIV) (Nicolls *et al.*, 2005). In our case, the patient got a combination of surgery and chemotherapy. Patients were also treated conservatively because the majority of these lesions resolve completely with ATT (A, 2015). Total tuberculoma resolution is shown when scans reveal no enhancing lesions or only a calcified region (Bouali *et al.*, 2020). Accordance in this case, after ATT for a year, head MRI evaluation showed gliosis and hemiatrophy on the right cerebellum. In conjunction with established ATT, resection of these lesions remains a viable treatment option that is both safe and effective (Capone *et al.*, 2021).

### **Differential Diagnosis**

In most developing countries, CNS tuberculoma is one of the first differential diagnoses of an enhancing intraaxial lesion (Capone *et al.*, 2021). Tuberculoma imaging features are known to overlap with those of other intracranial focal lesions, such as chronic pyogenic brain abscess, fungal granulomas, neurocysticercosis healing stage, and lymphomas (Binesh, Zahir, and Bovanlu, 2013). Some metastases and gliomas may have characteristics similar to tuberculoma and should be considered in differential diagnoses (Binesh, Zahir and Bovanlu, 2013).

## Conclusion

Tuberculosis of the CNS can be difficult to diagnose because it is a rare condition that can easily be mistaken for an intracranial mass (Er *et al.*, 2018). Although rare, tuberculoma should be taken into account in both immunocompetent and immunocompromised patients with neurological symptoms who are living in an endemic area for tuberculosis (Nabiuni and Sarvarian, 2011).

## Acknowledgments

None

## References

- A, B. (2015) 'Cerebellar Tuberculoma In A Hiv Coinfected Patient With Arnold-Chiari I Malformation', *Journal Of Hiv And Aids ( Issn 2380-5536 )*, 1(1), Pp. 2014–2016. Doi: 10.16966/2380-5536.104.
- Agrawal, P. Et Al. (2020) 'Giant Cerebral Tuberculoma Masquerading As Malignant Brain Tumor – A Report Of Two Cases', *Cureus*, 12(9). Doi: 10.7759/Cureus.10546.
- Bernaerts, A. Et Al. (2003) 'Tuberculosis Of The Central Nervous System: Overview Of Neuroradiological Findings', *European Radiology*, 13(8), Pp. 1876–1890. Doi: 10.1007/S00330-002-1608-7.
- Binesh, F., Zahir, S. T. And Bovanlu, T. R. (2013) 'Isolated Cerebellar Tuberculoma Mimicking Posterior Cranial Fossa Tumour', *Bmj Case Rep*, Pp. 1–4. Doi: 10.1136/Bcr-2013-009965.
- Bouali, S. Et Al. (2020) 'Giant Posterior Fossa Tuberculoma In Immunocompetent Adults', *Human Pathology: Case Reports*, 19(August 2019), P. 200342. Doi: 10.1016/J.Ehpc.2019.200342.
- Capone, S. Et Al. (2021) 'Presentation, Diagnosis, And Treatment Of A Cerebellar Tuberculoma: Illustrative Case', *Journal Of Neurosurgery: Case Lessons*, 2(18), Pp. 2–5. Doi: 10.3171/Case21170.
- Chaulagain, D. (2019) 'Symptoms ,, Diagnosis And Surgical Procedures Of Tuberculoma Of Brain Among Infants- A Systematic Review', 9(June), Pp. 345–357.
- Chen, F. Et Al. (2018) 'Intracisternal Tuberculoma: A Refractory Type Of Tuberculoma Indicating Surgical Intervention', *Bmc Neurology*, 18(1), P. 10. Doi: 10.1186/S12883-017-0996-X.
- Davis, A., Meintjes, G. And Wilkinson, R. J. (2018) 'Treatment Of Tuberculous Meningitis And Its Complications In Adults', *Current Treatment Options In Neurology*, 20(3). Doi: 10.1007/S11940-018-0490-9.
- Er, M. Et Al. (2018) 'A Rare Case Of Cerebellar And Lung Tuberculosis Coexistence Which Presenting Intracranial Mass Symptoms', *Eastern Journal Of Medicine*, 23(1), Pp. 36–39. Doi: 10.5505/Ejm.2018.36035.
- Fabrizio, P. Et Al. (2017) 'Cognitive Age And Usability Of Health Website Among Older Adults', *Journal Of Neurosurgery Research And Reviews*, 1(1), Pp. 1–5. Doi: 10.36959/363/404.
- Gasparetto, E. L., Tazoniero, P. And Neto, A. De C. (2003) 'Disseminated Tuberculosis In A Pregnant Woman Presenting With Numerous Brain Tuberculomas: Case Report', *Arquivos De Neuro-Psiquiatria*, 61(3 B), Pp. 855–858. Doi: 10.1590/S0004-282x2003000500028.

- Gupta, Shivani Et Al. (2022) 'Abducens Nerve Palsy: A Sole Presentation Of Isolated Cerebellar Tuberculoma', Pp. 205–208. Doi: 10.4103/Jdrntruhs.Jdrntruhs.
- Ikbal, M. And Sugianto, P. (2022) 'Perbaikan Klinis Dan Radiologis Tuberkuloma Serebral Dengan Terapi Non Operatif: Dua Laporan Kasus', *Aksona*, 1(1), Pp. 18–23. Doi: 10.20473/Aksona.V1i1.96.
- Imran, D. Et Al. (2019) 'Barriers To Diagnosis And Management Of Cns Infections In Indonesia', *American Academy Of Neurology*, 92(2), Pp. 104–106. Doi: 10.1212/Wnl.0000000000006732.
- Işik, U. Et Al. (2009) 'Seizures As The Sole Manifestation Of Cerebellar Lesions In Three Children', *Journal Of Pediatric Neurology*, 7(2), Pp. 193–198. Doi: 10.3233/Jpn-2009-0286.
- Israr Khan, D. Et Al. (2019) 'Chronic Headache: The Only Manifestation Of Cerebellar Tuberculoma', *Biosciences, Biotechnology Research Asia*, 16(04), Pp. 711–714. Doi: 10.13005/Bbra/2786.
- Leonard, J. M. (2021) 'Tuberculosis Of The Central Nervous System', In *Aminoff's Neurology And General Medicine*. Elsevier, Pp. 717–726. Doi: 10.1016/B978-0-12-819306-8.00040-X.
- Marais, S. Et Al. (2019) 'Management Of Intracranial Tuberculous Mass Lesions: How Long Should We Treat For?', *Wellcome Open Research*, 4(158), P. 158. Doi: 10.12688/Wellcomeopenres.15501.1.
- Nabiuni, M. And Sarvarian, S. (2011) 'Primary Cerebellar Tuberculoma In Arnold-Chiari Malformation Mimicking Posterior Cranial Fossa Tumor: The First Report', *Global Spine Journal*, 1(1), Pp. 019–021. Doi: 10.1055/S-0031-1296052.
- Nicolls, D. J. Et Al. (2005) 'Intracranial Tuberculomas Developing While On Therapy For Pulmonary Tuberculosis', *The Lancet Infectious Diseases*, 5(12), Pp. 795–801. Doi: 10.1016/S1473-3099(05)70299-1.
- Rock, R. B. Et Al. (2008) 'Central Nervous System Tuberculosis: Pathogenesis And Clinical Aspects', *Clinical Microbiology Reviews*, 21(2), Pp. 243–261. Doi: 10.1128/Cmr.00042-07.
- Soni, R. (2021) 'A Case Of Rarest Presentation Of Cns Tuberculosis As Disseminated Miliary Tuberculoma Brain'. Doi: Doi: <https://doi.org/10.21203/rs.3.rs-523117/v1> License:
- Sutantoyo, F. F. And Sugianto, P. (2022) 'A Malignant Disseminated Tuberculosis: Concurrent Intracranial Tuberculosis With Skipped Multilevel Spondylitis In A Young Immunocompetent Patient', *Romanian Journal Of Neurology*, 21(February), Pp. 83–89. Doi: 10.37897/Rjn.2022.1.16.
- Thwaites, G. Et Al. (2009) 'British Infection Society Guidelines For The Diagnosis And Treatment Of Tuberculosis Of The Central Nervous System In Adults And Children', *Journal Of Infection*, 59(3), Pp. 167–187. Doi: 10.1016/J.Jinf.2009.06.011.
- Wakisaka, S., Soejima, T. And Matsuoka, S. (1987) 'Cerebellar Tuberculoma', *Neurologia Medico-Chirurgica*, 27(1), Pp. 31–36. Doi: 10.2176/Nmc.27.31.
- Weidauer, S. Et Al. (2020) 'Cns Infections In Immunoincompetent Patients', *Clinical Neuroradiology*, 30(1), Pp. 9–25. Doi: 10.1007/S00062-019-00837-6.
- Wibawani, R. Et Al. (2019) 'Head Computed Tomography Images Of Hiv/Aids Patients With Suspected Cerebral Toxoplasmosis In Dr. Soetomo General Hospital Surabaya', *Biomolecular And Health Science Journal*, 2(1), P. 21. Doi: 10.20473/Bhsj.V2i1.13343.

- Zahrou, F. Et Al. (2019) 'Diagnosis And Management Of Intracranial Tuberculomas: About 2 Cases And A Review Of The Literature', *Pan African Medical Journal*, 34, Pp. 1–6. Doi: [Doi:10.11604/Pamj.2019.34.23.17587](https://doi.org/10.11604/Pamj.2019.34.23.17587).
- Parmin, P., Suarayasa, K., & Wandira, B. A. (2020). Relationship between quality of service with patient loyalty at general polyclinic of kamonji public health center. *International Journal of Health & Medical Sciences*, 3(1), 86-91. <https://doi.org/10.31295/ijhms.v3n1.157>
- Rinartha, K., Suryasa, W., & Kartika, L. G. S. (2018). Comparative Analysis of String Similarity on Dynamic Query Suggestions. In *2018 Electrical Power, Electronics, Communications, Controls and Informatics Seminar (EECCIS)* (pp. 399-404). IEEE.
- Suryasa, I. W., Rodríguez-Gómez, M., & Koldoris, T. (2021). Get vaccinated when it is your turn and follow the local guidelines. *International Journal of Health Sciences*, 5(3), x-xv. <https://doi.org/10.53730/ijhs.v5n3.2938>