

Right Cerebellar Tuberculosis with Cranial Nerve Palsy in Pulmonary Tuberculosis Patient

by I Komang Rusgi Yandi

Submission date: 04-Jun-2022 12:54PM (UTC+0800)

Submission ID: 1850161201

File name: sis_with_Cranial_Nerve_Palsy_inPulmonaryTuberculosis_Patient.pdf (391.47K)

Word count: 2607

Character count: 14127

CASE REPORT

Right Cerebellar Tuberculosis with Cranial Nerve Palsy in Pulmonary Tuberculosis Patient

I Komang Rusgi Yandi*, Isnin Anang Marhana

Department of Pulmonology and Respiratory Medicine, Faculty of Medicine, Universitas Airlangga/Dr. Soetomo General Hospital, Surabaya, Indonesia

ARTICLE INFO

Article history:

Received 06 April 2020

Received in revised form 11 May 2021

Accepted 26 May 2021

Available online 31 May 2021

Keywords:

CNS TB,
Tuberculosis,
Anti-tuberculosis,
Cerebellum.

ABSTRACT

Introduction: Tuberculosis (TB) is a major public health issue. The most devastating clinical manifestations of TB is Central nervous system (CNS) TB. CNS TB is found approximately in 1% of all patients with active TB, and cerebellar TB is rarely reported. CNS TB can present as meningitis, arachnoiditis, tuberculomas, or the uncommon forms of tuberculous subdural empyema and brain abscess.

Case: A 23-year-old patient was reported in October 2018 with signs and symptoms of 2-month history of vertigo, headache, vomiting, weakness, fever, blurred vision, lingual palsy, dysmetria, and decrease of consciousness. The patient had a few months of history of cough, contact with a TB patient, his father, and loss of body weight. On admission, the patient had fever (38.50 C) and Glasgow coma score of 13.

Discussion: CNS TB can occur in an immunocompromised patient with malnutrition, whether a child or young adult. The patient in this case had risk factors because he is a young adult and had contact with a patient of TB, his father. Based on epidemiology, clinical signs and symptoms, radiological findings, and the result of AFB-stained sputum, the patient was diagnosed with right cerebellar TB and PTB.

Conclusion: The high morbidity and mortality characteristics of CNS TB are very important to note, thus the prompt diagnosis and therapy should be done. The specific therapy of ATD combined with surgery seems to provide a good result. The clinical and radiological findings were used as the evaluation of the medication.

INTRODUCTION

In 2017, it was estimated that 10 million people developed TB, which consisted of 1 million children, 3.2 million women, and 5.8 million men.¹ TB with CNS involvement accounts for approximately 1% of all TB diseases,²⁻⁴ and the rare form of CNS TB is brain abscess.^{5,6} CNS TB patients who have no Human Immunodeficiency Virus (HIV) infection occurs in only 4 to 8% of patients.⁷ There are 3 clinical-pathological forms of CNS TB, tuberculomas, meningoencephalitis, and abscesses.⁸ Tuberculous brain abscess (TBA) is uncommon and cerebellar tuberculosis is a very rare form of CNS TB.^{9,10}

The high morbidity and mortality characteristics of CNS TB are very important to note, thus the prompt diagnosis and therapy should be done. It

is also important to prevent the severe neurological sequelae, even in patients who are adequately treated.^{11,12} The signs and symptoms, brain imaging, and laboratory findings of CNS TB are nonspecific, but the initial diagnosis is based on it, and the definitive diagnosis is made by bacteriological methods.^{10,12,13}

ATD treatment is given immediately because of high morbidity and mortality rate in CNS TB.¹⁴ Although the effective ATD therapy has been performed, adverse results usually occur in patients with CNS TB, such as severe neurological sequelae and death. For the prevention of these adverse results, corticosteroids have been used as an adjunctive in the medication.^{2,13}

For the end of therapy in patients with CNS TB, there are no established criteria recently. The response

*Correspondence: ikomangrusgiyandi@gmail.com



of the medication frequently must be based on clinical and brain imaging findings. For patients with CNS TB, bacteriological evaluation is limited because of the difficulty in getting specimens.¹⁵

CNS TB can be noticed in both immunocompetent and immunocompromised patients. We reported an immunocompetent patient, a young adult, who had contact with TB patient (his father), who was diagnosed with right cerebellum TB and PTB.

CASE

A 23-year-old patient was reported in October 2018 with signs and symptoms of 2-month history of vertigo, headache, vomiting, weakness, fever, blurred vision, lingual palsy, dysmetria, and decrease of consciousness. The patient had a few months of history of cough, contact with a TB patient, his father, and loss of body weight. On admission, the patient had pyrexia (38.5°C) and Glasgow coma score of 13. Neurological examination revealed a decrease of consciousness and direction-changing positional nystagmus. The general examination also showed a decrease of visus, in 1/3 lower of right hemithorax was dullness in percussion,

and a decrease of vesicular breath sound. The result of AFB-stained sputum was 1+. The chest X-ray (Figure 1) revealed the fibro infiltrates process in both hemithoraxes, homogenous opacity at the right lower hemithorax, and the costophrenic angle blunting at the right hemithorax. The head CT-scan (Figure 2) without contrast revealed a cystic lesion in the right cerebellar hemisphere and with contrast revealed a ring-enhancing mass in the right cerebellar hemisphere.

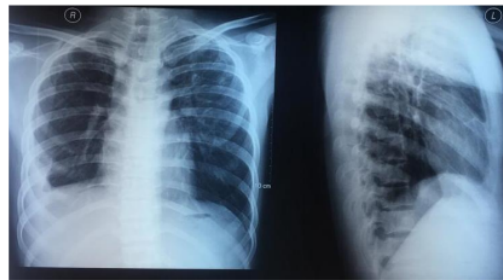


Figure 1. Chest X-ray revealed the fibro infiltrates process in both hemithoraxes, homogenous opacity at the right lower hemithorax, and the costophrenic angle blunting at the right hemithorax

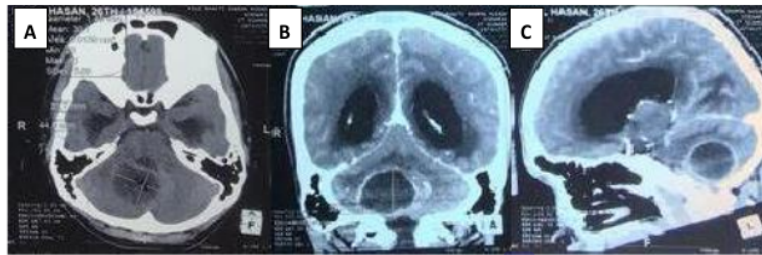


Figure 2. Axial view of head CT-scan without contrast (A) revealed the cystic lesion in the right cerebellar hemisphere and with contrast (B) revealed a ring-enhancing mass in the right cerebellar hemisphere. Sagittal view of head CT-scan with contrast (C) revealed the ring-enhancing mass was located in the infratentorial region of the brain.

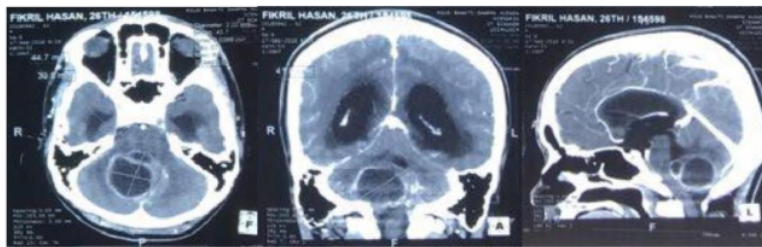

Figure 3. The head CT-scan with contrast revealed communicating hydrocephalus and a ring-enhancing mass pushed the cerebellar and caused the impending cerebellar herniation.

Communicating hydrocephalus could be seen in the head CT-scan (Figure 3), the mass pushed the cerebellar and caused the impending cerebellar herniation. The brain MR-imaging (Figure 4) in the T1-weighted image revealed a ring-enhancing mass in the right cerebellar hemisphere, in the FLAIR sequence revealed a ring-enhancing mass in the right cerebellar hemisphere with perifocal edema, and in the diffusion-weighted image (DWI) sequence revealed a restricted diffusion area. The brain MR-imaging (Figure 5) also revealed the communicating hydrocephalus, dilatation of right and left lateral ventricles, dilatation of the third ventricle, and the fourth ventricle.

The patient was diagnosed with right cerebellar TB and PTB. Surgery was preferred as medical treatment, which was reserved for diagnostic and

therapy of complications, but the patient's family disagreed and denied the action. ATD treatment, including rifampicin, isoniazid, pyrazinamide, ethambutol, and streptomycin, were given. Corticosteroid (dexamethasone) was also given as indicated.

The evaluation was performed after the patient underwent the ATD treatment for 12 months. In the evaluation, the patient had no complaints and could do his daily activities well. The evaluation of brain MR-imaging (Figure 6) did not show a ring-enhancing mass in the right cerebellar hemisphere, but in the FLAIR sequence revealed the perifocal edema could be caused by post-infection. The DWI sequence revealed unrestricted diffusion area.

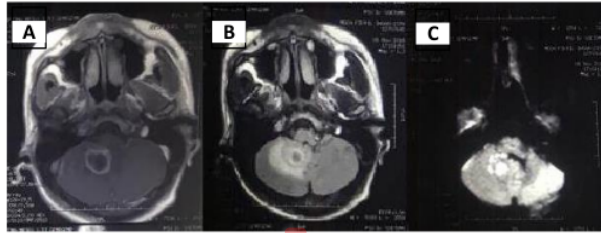


Figure 4. Brain MR-imaging in the T1-weighted image. (A) revealed a ring-enhancing mass in the right cerebellar hemisphere. The FLAIR sequence; (B) revealed a ring-enhancing mass in the right cerebellar hemisphere with perifocal edema. In DWI sequence (C) revealed a restricted diffusion area.

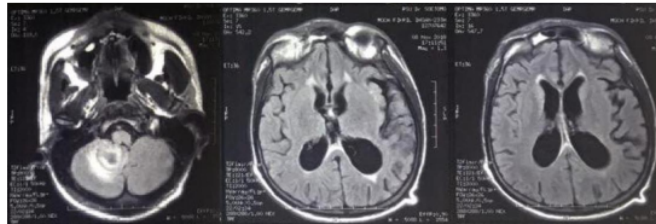


Figure 5. The brain MR-imaging revealed the communicating hydrocephalus, dilatation of right and left lateral ventricles, dilatation of third ventricle, and fourth ventricle.

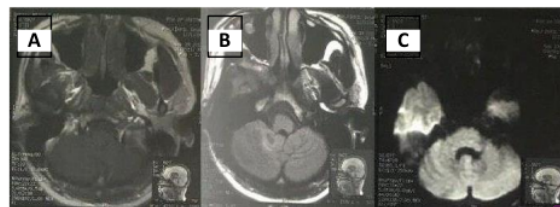


Figure 6. The brain MR-imaging in the T1-weighted image (A) did not show a ring-enhancing mass in the right cerebellar hemisphere, but in the FLAIR sequence (B) revealed the perifocal edema in the right cerebellar hemisphere could be caused by post-infection. The DWI sequence (C) revealed an unrestricted diffusion area.

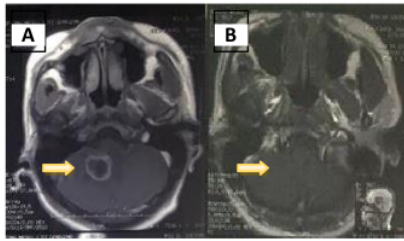


Figure 7. Comparison of the brain MR-imaging in the T1-weighted image before (A) and after (B) ATD treatment for 12 months.

(A) Brain MR-imaging in the T1-weighted image revealed a ring-enhancing mass in the right cerebellar hemisphere (shown by arrows).

(B) MR-imaging in the T1-weighted image did not show a ring-enhancing mass in the right cerebellar hemisphere (shown by arrows).

DISCUSSION

TB is a fundamental public health problem in developing countries. The most usual clinical presentation of active TB is pulmonary TB (PTB), but TB can manifest in any tissue of the human body including CNS. The involvement of CNS in TB is rare and is associated with high mortality and morbidity rates, even inadequately treatment.^{11,12} CNS TB can occur in an immunocompromised patient with malnutrition, whether a child or young adult. In TB with HIV-positive patients, CNS involvement is five times more often than HIV-negative patients.¹⁶ TB meningitis in adults usually presents with the classic meningitis symptoms such as fever, headache, stiff neck, a decrease of consciousness, focal neurological deficits, and behavioral changes. Tuberculoma and TBA present symptoms of headache, papilledema, blurred vision, seizures, vomiting, a decrease of consciousness, and have clinical manifestations depend on their location.^{14,17}

Culture of *Mycobacterium* TB organisms from a specimen obtained from the patient is a gold standard for definitive diagnosis of TB,¹⁵ but the easily accessible tools for diagnostic suspected patient of PTB is AFB-stained sputum.^{18,19} When the patients are suspected of suffering an extra-pulmonary TB (EPTB), every test should be made to obtain tissue/relevant body fluid for diagnostic testing.²⁰ The sensitivity of diagnostic tests is low, it can be caused by the difficulty in obtaining the specimens.¹⁵ Prompt diagnosis of tuberculous etiology is significant for clinical outcome and a history of recent TB contact is also important.¹⁶

Cerebrospinal fluid (CSF) examination (e.g., CSF AFB staining, CSF culture, CSF analysis) is important for a diagnostic test of TBM.¹³ In cases of TBA and tuberculomas, the histological examination is a gold standard for diagnostic, and about 60% of tissue specimens show AFB in smear and culture.¹⁶ The signs and symptoms, brain imaging, and laboratory findings of CNS TB are nonspecific, but the initial diagnosis is based on it, and the definitive diagnosis is made by bacteriological methods.^{10,12,13}

The lumbar puncture (LP) was not performed in this case because of the increased intracranial pressure (ICP) as a contraindication for LP. Surgery was preferred as medical treatment, which was reserved for diagnostic and therapy of complications. Hydrocephalus with raised ICP requires CSF diversion by ventriculoperitoneal shunt insertion. The surgery was not performed because the patient's family disagreed and denied the action.

Early treatment is important to avoid severe neurological sequelae. ATD treatment is given immediately because of high morbidity and mortality rate in CNS TB.¹⁴ Although the effective ATD therapy has been performed, adverse results usually occur in patients with CNS TB, such as severe neurological sequelae and death. For the prevention of these adverse results, corticosteroids have been used as an adjunctive in the medication.^{2,13}

In this case, ATD and dexamethasone were given early and observation for the decrease of consciousness was performed continuously. In several days, the patient's condition was getting better. In this case, the patient was given the ATD treatment for 12 months consisting of intensive phase for 2 months (rifampicin, isoniazid, pyrazinamide, ethambutol, and injection of streptomycin) and continuous phase for 10 months in the intermittent dose (isoniazid and rifampicin).

For the end of therapy in patients with CNS TB, there are no established criteria recently. The response of the medication frequently must be based on clinical and brain imaging findings. For patients with CNS TB, bacteriological evaluation is limited because of the difficulty in getting specimens.¹⁵

In this case, the evaluation of the treatment was based on clinical and brain imaging findings. The patient had no complaints and could do his daily activities well.

The evaluation of brain MRI did not show a ring-enhancing mass in the right cerebellar hemisphere and in the FLAIR sequence revealed the perifocal edema could be caused by post-infection.

CONCLUSION

The high morbidity and mortality characteristics of CNS TB are very important to note, thus the prompt diagnosis and therapy should be done. The specific therapy of ATD combined with surgery seems to provide a good result. The clinical and radiological findings were used as the evaluation of the medication.

REFERENCES

1. Organization WH. Global Tuberculosis Report 2018. Geneva, <https://apps.who.int/iris/bitstream/handle/10665/274453/9789241565646-eng.pdf?sequence=1&isAllowed=y> (2018).
2. Thwaites G, Fisher M, Hemingway C, et al. British Infection Society Guidelines for the Diagnosis and Treatment of Tuberculosis of the Central Nervous System in Adults and Children. *J Infect* 2009; 59: 167–187.
3. Mukherjee S, Das R, Begum S. Tuberculoma of the Brain - A Diagnostic Dilemma: Magnetic Resonance Spectroscopy a New Ray of Hope. *J Assoc Chest Physicians* 2015; 3: 3–8.
4. Monteiro R, Carneiro JC, Costa C, et al. Cerebral Tuberculomas - A Clinical Challenge. *Respir Med Case Reports* 2013; 9: 34–37.
5. Whitener DR. Tuberculous Brain Abscess. Report of a Case and Review of the Literature. *Arch Neurol* 1978; 35: 148–155.
6. Ansari MK, Jha S. Tuberculous Brain Abscess in an Immunocompetent Adolescent. *Journal of Natural Science, Biology, and Medicine* 2014; 5: 170–172.
7. Parekh R, Haftka A, Porter A. A Rare Case of Central Nervous System Tuberculosis. *Case Rep Infect Dis* 2014; 2014: 186030.
8. Cárdenas G, Soto-Hernández JL, Orozco RV, et al. Tuberculous Brain Abscesses in Immunocompetent Patients: Management and Outcome. *Neurosurgery* 2010; 67: 1081–1087.
9. Menon S, Bharadwaj R, Chowdhary A, et al. Tuberculous Brain Abscesses: Case Series and Review of Literature. *Journal of Neurosciences in Rural Practice* 2011; 2: 153–157.
10. Wanjari K, Baradkar VP, Nataraj G, et al. A Rare Case of Tubercular Cerebellar Abscess. *Indian J Med Microbiol* 2009; 27: 363–365.
11. Li H, Liu W, You C. Central Nervous System Tuberculoma. *J Clin Neurosci Off J Neurosurg Soc Australas* 2012; 19: 691–695.
12. Chou P-S, Liu C-K, Lin R-T, et al. Central Nervous System Tuberculosis: A Forgotten Diagnosis. *Neurologist* 2012; 18: 219–222.
13. Faksri K, Prammananan T, Leechawengwongs M, et al. Molecular Epidemiology and Drug Resistance of Tuberculous Meningitis. 2012. Epub ahead of print 30 March 2012. DOI: 10.5772/31973.
14. Sharma SK, Ryan H, Khaparde S, et al. Index-TB Guidelines: Guidelines on Extrapulmonary Tuberculosis for India. *Indian J Med Res* 2017; 145: 448–463.
15. Lee JY. Diagnosis and Treatment of Extrapulmonary Tuberculosis. *Tuberc Respir Dis (Seoul)* 2015; 78: 47–55.
16. Katti MK. Pathogenesis, Diagnosis, Treatment, and Outcome Aspects of Cerebral Tuberculosis. *Med Sci Monit Int Med J Exp Clin Res* 2004; 10: RA215-29.
17. Rock RB, Olin M, Baker CA, et al. Central Nervous System Tuberculosis: Pathogenesis and Clinical Aspects. *Clin Microbiol Rev* 2008; 21: 243–261.
18. Chang C-Y, Hong J-Y, Yuan M-K, et al. Risk Factors in Patients with AFB Smear-Positive Sputum Who Receive Inappropriate Antituberculous Treatment. *Drug Des Devel Ther* 2013; 7: 53–58.
19. Lewinsohn DM, Leonard MK, LoBue PA, et al. Official American Thoracic Society/Infectious Diseases Society of America/Centers for Disease Control and Prevention Clinical Practice Guidelines: Diagnosis of Tuberculosis in Adults and Children. *Clin Infect Dis an Off Publ Infect Dis Soc Am* 2017; 64: 111–115.
20. Sharma SK, Mohan A. Extrapulmonary Tuberculosis. *Indian J Med Res* 2004; 120: 316–353.

Right Cerebellar Tuberculosis with Cranial Nerve Palsy in Pulmonary Tuberculosis Patient

ORIGINALITY REPORT

14%

SIMILARITY INDEX

7%

INTERNET SOURCES

13%

PUBLICATIONS

0%

STUDENT PAPERS

PRIMARY SOURCES

- 1** Corey Raffel. "Postirradiation cerebellar glioma : Case report", Journal of Neurosurgery, 02/1985 2%
Publication
- 2** Nuria Mellado-Calvo. "Cerebral Tumours", Lishman s Organic Psychiatry, 07/31/2009 1%
Publication
- 3** academic.oup.com 1%
Internet Source
- 4** tbassnindia.org 1%
Internet Source
- 5** link.springer.com 1%
Internet Source
- 6** F. Binesh, S. Taghipour Zahir, T. Roshan Bovanlu. "Isolated cerebellar tuberculoma mimicking posterior cranial fossa tumour", Case Reports, 2013 1%
Publication

7	<p>"Tuberculosis of the Central Nervous System", Springer Science and Business Media LLC, 2017 Publication</p>	1 %
8	<p>Otavio T. Ranzani, Laura C. Rodrigues, Eliseu A. Waldman, Carlos R. R. Carvalho. "Estimating the impact of tuberculosis anatomical classification on treatment outcomes: A patient and surveillance perspective analysis", PLOS ONE, 2017 Publication</p>	1 %
9	<p>ir.cput.ac.za Internet Source</p>	1 %
10	<p>"Abtracts from the 30th Annual Meeting of the Society of General Internal Medicine", Journal of General Internal Medicine, 2007 Publication</p>	<1 %
11	<p>V. R. Roopesh Kumar, S. K. Gundamaneni, R. Biswas, V. S. Madhugiri. "Tuberculous cerebellar abscess in immunocompetent individuals", Case Reports, 2012 Publication</p>	<1 %
12	<p>Fatma Ciftci, Naoto Shimbori, Demet Karnak. "Concurrent central nervous system and endobronchial tuberculosis mimicking a metastatic lung cancer", The Clinical Respiratory Journal, 2017 Publication</p>	<1 %

13	cdn.intechopen.com Internet Source	<1 %
14	ruralneuropractice.com Internet Source	<1 %
15	scholar.sun.ac.za Internet Source	<1 %
16	www.ncbi.nlm.nih.gov Internet Source	<1 %
17	Federica Novegno, Giuseppe Umana, Pierluigi Granaroli, Filippo Borri, Augusto Orlandi, Pierpaolo Lunardi. "Current management of central nervous system metastasis from cholangiocarcinoma: the neurosurgical perspective. Literature review", British Journal of Neurosurgery, 2019 Publication	<1 %
18	Safayet Ahammed, Mohammed Sana Ullah Sarker, Md Zulfikar Ali. "Diagnostic Value of Bronchoalveolar Lavage Examination in Sputum Negative Patients for AFB in Suspected Pulmonary Tuberculosis", KYAMC Journal, 2021 Publication	<1 %
19	doctorlib.info Internet Source	<1 %
20	journals.plos.org	

Internet Source

<1 %

21

synapse.koreamed.org

Internet Source

<1 %

22

"Extrapulmonary Tuberculosis", Springer
Science and Business Media LLC, 2019

Publication

<1 %

23

"Iatrogenic cerebellar implantation of a
vestibular schwannoma", Journal of
Neurosurgery, 03/2006

Publication

<1 %

24

Ahmad Data Dariansyah, Wihasto
Suryaningtyas, Muhammad Arifin Parenrengi.
"Tuberculoma mimicking postoperative VP
shunt seeding of craniopharyngioma: A rare
case report", Surgical Neurology International,
2021

Publication

<1 %

Exclude quotes On

Exclude matches Off

Exclude bibliography On

Right Cerebellar Tuberculosis with Cranial Nerve Palsy in Pulmonary Tuberculosis Patient

GRADEMARK REPORT

FINAL GRADE

/100

GENERAL COMMENTS

Instructor

PAGE 1

PAGE 2

PAGE 3

PAGE 4

PAGE 5
