

Lung Pseudomesothelioma in Patient with Asbestos

by Devy Trianne Putri

Submission date: 04-Jun-2022 12:46PM (UTC+0800)

Submission ID: 1850158059

File name: Lung_Pseudomesothelioma_in_Patient_with_Asbestos.pdf (339.92K)

Word count: 3068

Character count: 17729

CASE REPORT

Lung Pseudomesothelioma in Patient with Asbestos Exposure: A Case Report

Devy Trianne Putri^{1*}, Isnin Anang Marhana¹, Dhihintia Jiwangga²

¹Department of Pulmonology and Respiratory Medicine, Faculty of Medicine, Universitas Airlangga/Dr. Soetomo General Hospital, Surabaya, Indonesia.

²Department of Thoracic, Cardiac, and Vascular Surgery, Faculty of Medicine, Universitas Airlangga/Dr. Soetomo General Hospital, Surabaya, Indonesia.

ARTICLE INFO

Article history:

Received 9 July 2019

Received in revised form 2 October 2019

Accepted 22 May 2020

Available online 30 May 2020

Keywords:

Pseudomesotheliomatous, Adenocarcinoma, Asbestos exposure, Thoracoscopic biopsy.

ABSTRACT

Background: Pseudomesotheliomatous carcinoma is a rare case of lung cancer with marked pleural extension resembling malignant pleural mesothelioma on diagnostic imaging. One of tool to diagnose lung pseudomesothelioma is by performing thoroscopy pleural biopsy. Diagnostic thoracoscopy also has a higher sensitivity than pleural fluid cytology and needle biopsy.

Case: We report a rare case of pseudomesotheliomatous carcinoma of the lung in a 50-year-old man with asbestos exposure. The patient had complained of dyspnea and chest roentgenogram showed left pleural effusion. Computed tomography (CT) of the chest revealed diffuse irregular left pleural thickening and without a clear initial primary lesion found in both of lung parenchyma, which mimicked pleural mesothelioma. Pleural tissue sampling was performed to obtain definitive diagnosis by video-assisted thoracoscopic surgery. At the operation, the tumor was found to have spread along the pleural surface and primary lesion was not detected in the right lung parenchyma. Immunohistochemically, the tumor was positive for Thyroid Transcription Factor- 1 (TTF-1), but negative for calretinin, P63, and Neuron Specific Enolase (NSE). Final diagnosis was adenocarcinoma of the lung and patient had good clinical response to Gefitinib.

Conclusion: Based on the results of clinical studies (images and clinical observations), although pseudomesotheliomatous in patient with asbestos exposure is difficult to distinguish from pleural mesothelioma, we have a case of pseudomesotheliomatous lung diagnosed by a thoracoscopic pleura biopsy. For such cases, thoracoscopic pleural biopsy should be performed at an early stage.

INTRODUCTION

Pseudomesotheliomatous carcinoma is a rare case of lung cancer with marked pleural extension resembling malignant pleural mesothelioma on diagnostic imaging without a clear initial lesion in lung parenchyma. Most of pseudomesotheliomatous appear in pleural tissue of chest cavity which macroscopically, radiologically, and diagnostically confirmed by thoracoscopic pleural biopsy which resembles pleural mesothelioma.^{1, 2} This term was first proposed by Harwood, *et al.* in 1976 through an autopsy process in 6

We report a rare case of pseudomesotheliomatous carcinoma of the lung in a 50-year-old man who has risk factor for an asbestos exposure with chief complaints of shortness of breath, chest roentgenogram showed massive pleural effusion. Computed tomography (CT) of the chest showed irregular spread of pleural thickening that resembled malignant pleural

mesothelioma. The biopsy of pleural tissue sampling had been carried out to get a definitive diagnosis through Video-Assisted Thoracoscopic Surgery (VATS). During surgery, we found attachment between the visceral and parietal pleura with an uneven thickening of the parietal pleura and the primary lesion was not detected in left lung parenchyma. Immunohistochemically, the tumor was positive for TTF-1, but negative for calretinin, NSE and P63. The final diagnosis is pulmonary adenocarcinoma.

CASE

A 50 years-old-man, his profession was lecturer and lived in Tanggulangin Sidoarjo. has been living for more than 10 years in a house which roofs are made from asbestos. He was hospitalized in Dr. Soetomo General Hospital with chief complaint of shortness of breath since 1 month before admitted, the symptom

*Correspondence: dphi_tp@yahoo.com



became heavily increasing when he did activities. He experienced coughing with no phlegm since 1 week before admitted, got drastic lost of appetite and body weight. He had no night sweating and previously he was treated at a private hospital in Surabaya with chest X-ray showed a pleural effusion. He got a history of reddish yellow pleural fluid evacuation with the total of 1400 cc once but there was no pleural fluid cytology examination data. Then the patient was referred to Dr. Soetomo General Hospital to get further treatment.

The patient did not experience a similar complaint and serious illness before. History of using anti-tuberculosis drugs, diabetes mellitus, heart disease, and hypertension was denied. The patient works as a lecturer at Faculty of Law of a private university in Surabaya and did not smoke, but lives in a house which roofs are made from asbestos.

Based on physical examination, the patient's general appearance was weakness composmentis, with blood pressure 120/70 mmHg, pulse rate 100x/minute, breathing rate 26x/minute, and axillary temperature 36.5°C. From the examination of head and neck we found dyspnea. From physical examination of thorax region, both on inspection and palpation, we found asymmetrical chest wall movement (left diminished). The percussion was dullness in 2/3 lower of hemithorax sinistra and the auscultation was decreased of vesicular sound in 2/3 lower of hemithorax sinistra and there was no ronchi or wheezing in both of hemithorax. From the examination of the heart, abdominal and extremity were within normal limit.

Based on blood tests, the results of routine hematology, renal function test, liver function test and electrolyte serum were within normal limit and procalcitonin <0.05 ng/ml. BGA examination showed there was mild hypoxemia with pO₂ 73 mmHg and without acid base disorder. Tumor markers CEA 1.54 ng/ml, AFP 8.3 ng/ml, PSA 0.70 ng/ml. The examination of pleural fluid analysis was exudated with a chronic process that was pH 8, WBC-BF 2831/uL, RBC-BF 4304/uL, MN 18.1%, PMN 81.9%, number of cells 2840/uL, glucose 4 mg/dL, protein 14.9 g/dL, LDH 203 U/L. Based on AP position, chest X-ray showed the left heart border was covered by opacity, right phrenicocostal sinus angle was sharp which showed pleural effusion (figure 1).

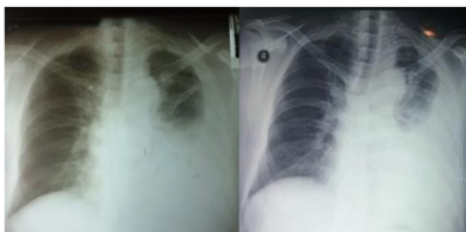

Figure 1. Chest X-ray AP position post thoracosynthesis 1500 cc and post chest tube installation showed opacities that covered the left heart border and left phrenicocostal sinus angle.

The patient had performed twice serial evacuation of pleural fluid with the total of 1500 cc and then followed by chest tube insertion. Pleural fluid was examined cytologically with the result of an adenocarcinoma. The patient also had a CT scan of the chest thorax with contrast and obtained enhanced irregular thickening in the left pleura, but there was no visible appearance of the left lung mass detected which led to the mesothelioma imaging (figure 2). Medical thoracoscopy could not be performed because there was no space and patient refused FOB procedure. Multidisciplinary team meeting decided to do pleural biopsy with VATS (figure 3 and figure 4). The result still could not distinguish between carcinoma of the lung or epitheloid mesothelioma, thus we did histochemical examination with TTF-1, P63, NSE, and calretinin antibodies. Histochemical examination showed positive TTF-1, negative P63, negative NSE, and negative calretinin, which finally could be concluded as adenocarcinoma.

The patient had performed twice serial evacuation of pleural fluid with the total of 1500 cc and then followed by chest tube insertion. Pleural fluid was examined cytologically with the result of an adenocarcinoma. The patient also had a CT scan of the chest thorax with contrast and obtained enhanced irregular thickening in the left pleura, but there was no visible appearance of the left lung mass detected which led to the mesothelioma imaging (Figure 2). Medical thoracoscopy could not be performed because there was no space and the patient refused FOB procedure. Multidisciplinary team meeting decided to do pleural biopsy with VATS (figure 3 and figure 4). The result still could not distinguish between carcinoma of the lung or epitheloid mesothelioma, thus we did histochemical examination with TTF-1, P63, NSE, and calretinin antibodies. Histochemical examination showed positive TTF-1, negative P63, negative NSE, and negative calretinin, which finally could be concluded as adenocarcinoma.

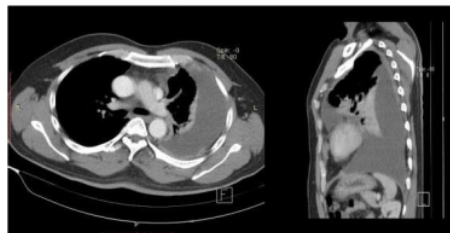


Figure 2. Chest CT scan showed enhanced thickening of the left pleural (64HU) accompanied by fluid density in the pleural cavity caused compressive atelectasis of the inferior lobe and left lung lingula with a suspicious paratracheal lymph node which was leading to mesothelioma, the left pulmonary mass was not revealed.

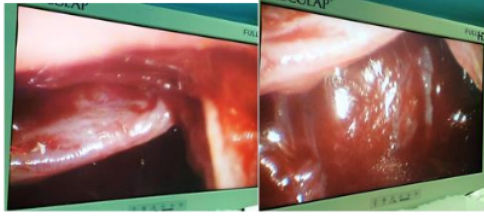


Figure 3. Surgery findings showed attachment between the parietal pleura and visceral pleura and also an uneven thickening of the parietal pleura.

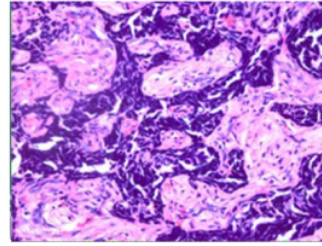


Figure 4. Sample parietal pleural tissue and visceral pleura, as well as pleural tissue histopathology.

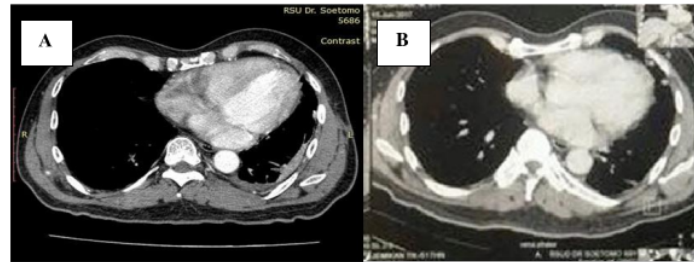


Figure 5. A. The mass appeared to be attached to the thorax wall of the left anterolateral side. Thickening of the left pleura, fibrosis in the posterobasal, left pleural effusion were still visible. RECIST criteria: progressive disease.
B. The mass appeared to be attached to the thorax wall of the left anterolateral side, when compared to the previous CT scan, the impression of size was smaller. Left pleural thickening, fibrosis in posterobasal, and loculated fluid in left minor fissure. RECIST criteria: partial response.

DISCUSSION

Cases of malignant pleural mesothelioma have been found in a number of countries such as America, Australia, South Africa, and reported cases have increased from year to year. Based on researches conducted in these countries, mesothelioma is closely related due to asbestos exposure.⁴ In this case, the patient with asbestos exposure is related to the roofs of the patient's house which are made from asbestos. In 1960, Wagner reported that it was not a new thing that asbestos (crocidolite) could cause a malignant pleural mesothelioma, but it was for the first time non-occupational asbestos exposure was found, and from the research conducted by Emily Goswami, *et al.* mesothelioma could occur due to non-occupational asbestos exposure, it may be caused by inhaling fibers from household appliances that contain asbestos (generally contains tremolite/erionite whitewash) or can also be caused by external exposure attached to clothes and bodies carried into the house or called paraoccupational.⁵ Asbestos exposure is also associated with lung cancer, although the mechanism of asbestos as a carcinogen has not been clearly understood until this day, several theories exist such as:

1. DNA damage by reactive oxygen species (ROS) induced by asbestos fibers.
2. Damage to cell DNA directly due to the interaction of asbestos fibers with target cells.

3. Increased cell proliferation by asbestos fibers.
4. Asbestos fibers provoke chronic cytokine inflammation and growth factors.
5. The role of fiber as a co-carcinogen or other chemical carcinogen carrier in the target tissue.⁶

Mesotheliomas are rare neoplasms (malignant tumors) originating from mesothelial cells and the majority occur in the pleural cavity layer of the thorax, but can also include peritoneal and pericardial.² Histopathologically, mesotheliomas with epithelioid type are difficult to distinguish from adenocarcinoma (mimicking adenocarcinoma), because both of them have the same glandular pattern, tubular pattern, or papillary pattern imaging.⁷

Pseudomesothelioma of lung cancer is a concept of the disease proposed by Harwood, *et al.* through his research in 1976 that found pleural effusion and no real primary lesions were found in the parenchyma. This finding is a pulmonary adenocarcinoma that has the same developmental form as malignant mesotheliomas.³ In fact, in this case, shortness of breath due to pleural effusion and pleural thickening without lung parenchymal lesions on CT scan was found, thus malignant pleural mesotheliomas were highly suspected.⁸ Diagnosis of thoracoscopy indicated in all cases with suspicion of mesothelioma.⁹ In this case, the thoroscopic findings indicated the attachment of the parietal pleura to the visceral pleura and uneven thickening of the parietal pleura. This corresponds to the research conducted by Herbert and Gallagher that

thoroscopic findings obtained in the parietal pleura with suspected mesothelioma cases may be:

1. Nodules or masses (in some cases can be multiple nodules that resemble grapes).
2. Thickening of the pleura with regular or irregular edges and can be accompanied by elevation, pale, hard.
3. Nodules or masses with pachypleuritis formation.
4. Non-specific forms of inflammation such as fine granulations, congestion, hypervascularization or local thickening of the pleura.⁹

Thoroscopic diagnostics also have a higher sensitivity value than pleural fluid cytology and needle biopsy (table 1).⁹

Table 1. Sensitivity of diagnosis methods in malignant mesotheliomas.⁹

Method	Number/Total	Percent
Fluid cytology	49 / 175	28 %
Abrams needle biopsy	33 / 135	24 %
Thoracoscopy	185 / 188	98 %
Surgery	9 / 9	100 %

According to Harwood, *et al.* histogenesis of pleural nodules and pleural thickening in pseudomesothelioma lung carcinoma cannot be explained with certainty, but based on his research, it can be caused due to emergence of nodules in the pleura which is the development of the tumor (sub pleural nodules). Other findings explain that the emergence of pleural thickening is not all caused by tumors but has existed before the tumor, so that tumors can spread rapidly in the pleural tissue that is thickened.³ Asbestos exposure in the long term can cause pleural thickening.^{10,11}

The main diagnostic problem in this regard is distinguishing between mesotheliomas from epithelial tumors, especially adenocarcinomas. Histologically, adenocarcinoma is difficult to distinguish from epitheloid mesothelioma, so an antibody panel is needed through immunohistochemical examination to distinguish the two of them.¹¹ Immunohistochemistry is an examination technique to measure the degree of immunity or levels of antibodies and antigens in tissue preparation by using the interaction between target antigens and specific antibodies given label (table 2, table 3 and table 4).¹²

Table 2. Immunohistochemistry of mesothelioma and adenocarcinoma stains.^{7,11,13,14}

IHC stain	Mesothelioma	Adenocarcinoma
Cytokeratin 5/6	Positive	Negative
Calretinin	Positive	Negative
D2-40 (podoplanin)	Positive	Negative
WT1 (Wilm's Tumour 1 Gene)	Positive	Negative
B72.3 (TAG 72)	Negative	Positive
MOC-31	Negative	Positive
TTF-1 (Thyroid Transcription Factor)	Negative	Positive
Claudin-4	Negative	Positive
Ber-EP4	Negative	Positive
CD57 (Leu7)	Negative	Positive
CD15 (Leu-M1)	Negative	Positive
CEA	Negative	Positive
EGFR	Negative	Positive

Table 3. Immunohistochemistry of adenocarcinoma figure⁷

Antibody	Lung	Bowel (colon)	Breast	Endometrium
Pan-keratin	+	+	+	+
TTF-1	+	-	-*	+*,125
Keratin 7	+	-	+	+
Keratin 20	- / +*	+	-	-
CDX-2	- / +	+	-	-
ER	- / +	-	-	+
PR	-	-	-	+
GCDFP	-	-	+	-
CEA	+	+	+	- / +
Mammoglobin	-	-	+	-
Surfactant	+	-	-	-

* In any cases, sporadic cells have positive staining ; + positive staining ; - negative staining ; - / + generally negative staining, but probably positive staining in some cases; CEA (Carcino Embryonic Antigen) ; ER (Estrogen Receptor) ; GCDFP (Gross Cystic Disease Fluid Protein) ; PR (Progesterone Receptor) ; TTF-1 (Thyroid Transcription Factor-1).

Table 4. Positive staining immunohistochemistry of lung adenocarcinoma dan squamous cell carcinoma.¹⁵

Lung Adenocarcinoma	TTF1, Napsin A, CK7
Squamous cell carcinoma	P63, CK5/6, P40, Desmocollin-3

Gold standard examination in cases of suspected mesothelioma uses an electron microscope, but due to limitations because it requires larger samples, specially preparation, expertise technical and delays in obtaining results, making it less valuable or has a lower value on diagnosis compared to immunohistochemistry (table 5).¹⁶

Table 5. Microscopic electron figure between mesothelioma and adenocarcinoma.¹⁶

	Mesothelioma	Adenocarcinoma
Apical microvilli	Long and slim, tonofilament bundles	Short and have microvilli
Perinuclear	Have	None
Basal lamina	Have	None
Long desmosomes	Have	None

Patients with pulmonary adenocarcinoma have positive mutation EGFR and given targeted therapy as first line chemotherapy. Chemotherapy with Gefitinib in these patients gives a good response, although in the first evaluation it is said that it is a progressive disease because of the discovery of new lesions, but clinically shows improvement.

CONCLUSION

From the results of clinical case studies reported in 50 years old male patient who has risk factor for asbestos exposure with chief complaint of shortness of breath and chest roentgenogram showing massive pleural effusion, CT scan of the thorax showed pleural thickening that spread irregularly showing pleural mesothelioma like. Pleural tissue sampling was performed to get a definitive diagnosis through biopsy with VATS. It found an uneven pleural thickening and an undetected primary lesions in the lung parenchyma. Immunohistochemically, the tumor was positive for

TTF-1 antigens, but negative for calretinin, P63, and NSE. The final diagnosis is pulmonary adenocarcinoma. Although both clinically and radiologically pseudomesotheliomas are difficult to distinguish from mesotheliomas, in such case, performing a thoracoscopic pleural biopsy at an early stage is a proper diagnostic investigation.

REFERENCES

1. Maeda R, Iswa N, Kawasaki Y, et al. [Pseudomesotheliomatous Carcinoma of the Lung]. *Kyobu Geka the Japanese Journal of Thoracic Surgery*. 2007; 60: 555-558.
2. Dodson RF and Hammar SP. Analysis of Asbestos Concentration in 20 Cases of Pseudomesotheliomatous Lung Cancer. *Ultrastructural Pathology*. 2015; 39: 13-22.
3. Harwood TR, Gracey DR and Yokoo H. Pseudomesotheliomatous Carcinoma of the Lung. A Variant of Peripheral Lung Cancer. *American Journal of Clinical Pathology*. 1976; 65: 159-167.
4. Dunitz M. In: Robinson BWS and Chahinian AP, (Eds.). *Mesothelioma*. London: Martin Dunitz Ltd., Taylor & Francis Group. 2005; 1-93.
5. Goswami E, Craven V, Dahlstrom DL, Alexander D and Mowat F. Domestic Asbestos Exposure: A Review of Epidemiologic and Exposure Data. *Int J Environ Res Public Health*. 2013; 10: 5629-5670.
6. *Dasar-Dasar Diagnosis Kanker Paru*. Jakarta: Universitas Indonesia Press, 2017.
7. Moran C, Suster S. *Tumors and Tumor-Like Conditions of the Lung and Pleura*. 2010; 1-465.
8. Network NCC. Malignant Pleural Mesothelioma. In: *Oncology NCPGI*, (Ed.). Pennsylvania: National Comprehensive Cancer Network, 2017.
9. Astoul P, Boutin C. Pleuroscopy in the Management of Malignant Pleural Mesothelioma. In: Robinson BWS and Chahinian AP, (Eds.). *Mesothelioma*. London: Martin Dunitz Ltd., Taylor & Francis Group, 2005; 127-142.
10. Simonsen J. Pseudomesotheliomatous Carcinoma of the Lung with Asbestos Exposure. *The American Journal of Forensic Medicine and Pathology*. 1986; 7: 49-51.
11. Attanoos RL and Gibbs AR. 'Pseudomesotheliomatous' Carcinomas of the Pleura: A 10-Year Analysis of Cases from the Environmental Lung Disease Research Group, Cardiff. *Histopathology*. 2003; 43: 444-452.
12. Hood J. Peran Imunohistokimia pada Diagnosis Patologi. Surabaya: Fakultas Kedokteran Universitas Airlangga, 1993; 1-11.
13. British Thoracic Society Standards of Care Committee. Statement on Malignant Mesothelioma in the United Kingdom. *Thorax*. 2001; 56: 250-65.
14. Ordonez NG. The Immunohistochemical Diagnosis of Mesothelioma: A Comparative Study of Epithelioid Mesothelioma and Lung Adenocarcinoma. *The American Journal of Surgical Pathology*. 2003; 27: 1031-51.
15. Segal A, Combrinck M, Chai SM. Pleural Fluid Cytology. In: Light RW and Lee YCG, (Eds.). *Textbook of Pleural Diseases*. 3rd Ed. Florida: CRC Press, 2017; 251-65.
16. Segal A, Whitaker D, Henderson D and Shilkin K. Pathology of Mesothelioma. In: Robinson BWS and Chahinian AP, (Eds.). *Mesothelioma*. London: Martin Dunitz Ltd., Taylor & Francis Group, 2005; 143-176.

Lung Pseudomesothelioma in Patient with Asbestos

ORIGINALITY REPORT

13%

SIMILARITY INDEX

7%

INTERNET SOURCES

10%

PUBLICATIONS

0%

STUDENT PAPERS

PRIMARY SOURCES

1	journal.publications.chestnet.org Internet Source	1%
2	medicopublication.com Internet Source	1%
3	Mario Sergio Pergolini. "Posters", Internal and Emergency Medicine, 2012 Publication	1%
4	www.pathologyoutlines.com Internet Source	1%
5	"Oncological Surgical Pathology", Springer Science and Business Media LLC, 2020 Publication	1%
6	B. P. Amrith, Animesh Ray, Aanchal Kakkar, Sanjeev Sinha. "Diffuse pleural thickening: cases of pseudomesotheliomatous adenocarcinoma and pleural tuberculosis", Egyptian Journal of Bronchology, 2018 Publication	1%
7	Pathology of Asbestos-Associated Diseases, 2014. Publication	1%

8	<p>Sadiq, N., M. K. Mohsen, and I. A. Al Bozom. "Pseudomesotheliomatous Lung Carcinoma of Poorly Differentiated Large Cell Type: A case report and review of the literature", Qatar Medical Journal, 2008.</p> <p>Publication</p>	1 %
9	<p>Yuichi Tambo, Toshiyuki Kita, Yoshinori Kibe, Kazuo Kasahara, Masaki Fujimura, Shinji Nakao. "An Autopsy Case of Pseudomesotheliomatous Adenocarcinoma of the Lung", Haigan, 2006</p> <p>Publication</p>	1 %
10	<p>academic.oup.com</p> <p>Internet Source</p>	1 %
11	<p>www.balimedicaljournal.org</p> <p>Internet Source</p>	1 %
12	<p>"Handbook of Practical Immunohistochemistry", Springer Science and Business Media LLC, 2015</p> <p>Publication</p>	1 %
13	<p>C. Boutin. "Thoracoscopy in pleural malignant mesothelioma: A prospective study of 188 consecutive patients. Part 1: Diagnosis", Cancer, 07/15/1993</p> <p>Publication</p>	1 %
14	<p>Reagen Irwan Kolibu, Arief Bakhtiar. "Pulmonary spindle cell carcinoma with</p>	<1 %

hemothorax: A rare case report",
International Journal of Surgery Case Reports,
2022

Publication

15

vtechworks.lib.vt.edu

Internet Source

<1 %

16

jpatholm.org

Internet Source

<1 %

17

www.omicsonline.org

Internet Source

<1 %

18

Samuel P. Hammar, Douglas W. Henderson,
Sonja Klebe, Ronald F. Dodson. "Chapter 12
Neoplasms of the Pleura", Springer Science
and Business Media LLC, 2008

Publication

<1 %

19

coek.info

Internet Source

<1 %

20

dokumen.pub

Internet Source

<1 %

21

es.scribd.com

Internet Source

<1 %

22

"OS14: COPD 1 : Oral Sessions", Respiriology,
2013.

Publication

<1 %

Exclude quotes On

Exclude matches Off

Exclude bibliography On

Lung Pseudomesothelioma in Patient with Asbestos

GRADEMARK REPORT

FINAL GRADE

/100

GENERAL COMMENTS

Instructor

PAGE 1

PAGE 2

PAGE 3

PAGE 4

PAGE 5
