



# Source details

## Surgical Neurology International

Scopus coverage years: from 2011 to Present

Publisher: Scientific Scholar

ISSN: 2152-7806

Subject area: Medicine: Surgery Medicine: Neurology (clinical)

Source type: Journal

[View all documents >](#)

[Set document alert](#)

[Save to source list](#)

CiteScore 2021

1.1



SJR 2021

0.309



SNIP 2021

0.662



[CiteScore](#) [CiteScore rank & trend](#) [Scopus content coverage](#)

### i Improved CiteScore methodology



CiteScore 2021 counts the citations received in 2018-2021 to articles, reviews, conference papers, book chapters and data papers published in 2018-2021, and divides this by the number of publications published in 2018-2021. [Learn more >](#)

CiteScore 2021 ▼

$$1.1 = \frac{1,582 \text{ Citations } 2018 - 2021}{1,500 \text{ Documents } 2018 - 2021}$$

Calculated on 05 May, 2022

CiteScoreTracker 2022 ⓘ

$$1.1 = \frac{1,957 \text{ Citations to date}}{1,841 \text{ Documents to date}}$$

Last updated on 05 February, 2023 • Updated monthly

### CiteScore rank 2021 ⓘ

Category	Rank	Percentile
Medicine └ Surgery	#301/469	35th
Medicine └ Neurology (clinical)	#272/359	24th

[View CiteScore methodology >](#) [CiteScore FAQ >](#) [Add CiteScore to your site](#)

---

## About Scopus

[What is Scopus](#)

[Content coverage](#)

[Scopus blog](#)

[Scopus API](#)

[Privacy matters](#)

## Language

[日本語版を表示する](#)

[查看简体中文版本](#)

[查看繁體中文版本](#)

[Просмотр версии на русском языке](#)

## Customer Service

[Help](#)

[Tutorials](#)

[Contact us](#)

---

## ELSEVIER

[Terms and conditions](#) ↗ [Privacy policy](#) ↗



Copyright © Elsevier B.V. ↗. All rights reserved. Scopus® is a registered trademark of Elsevier B.V.

We use cookies to help provide and enhance our service and tailor content. By continuing, you agree to the use of cookies ↗.






## Surgical Neurology International

<p><b>COUNTRY</b></p> <p>India</p> <p> Universities and research institutions in India</p> <p> Media Ranking in India</p>	<p><b>SUBJECT AREA AND CATEGORY</b></p> <p>Medicine</p> <ul style="list-style-type: none"> <li>Neurology (clinical)</li> <li>Surgery</li> </ul>	<p><b>PUBLISHER</b></p> <p>Scientific Scholar LLC</p>	<p><b>H-INDEX</b></p> <p><b>37</b></p>
<p><b>PUBLICATION TYPE</b></p> <p>Journals</p>	<p><b>ISSN</b></p> <p>21527806</p>	<p><b>COVERAGE</b></p> <p>2011-2021</p>	<p><b>INFORMATION</b></p> <p><a href="#">Homepage</a></p> <p><a href="#">How to publish in this journal</a></p> <p><a href="mailto:editor@surgicalneurologyint.com">editor@surgicalneurologyint.com</a></p>

### SCOPE

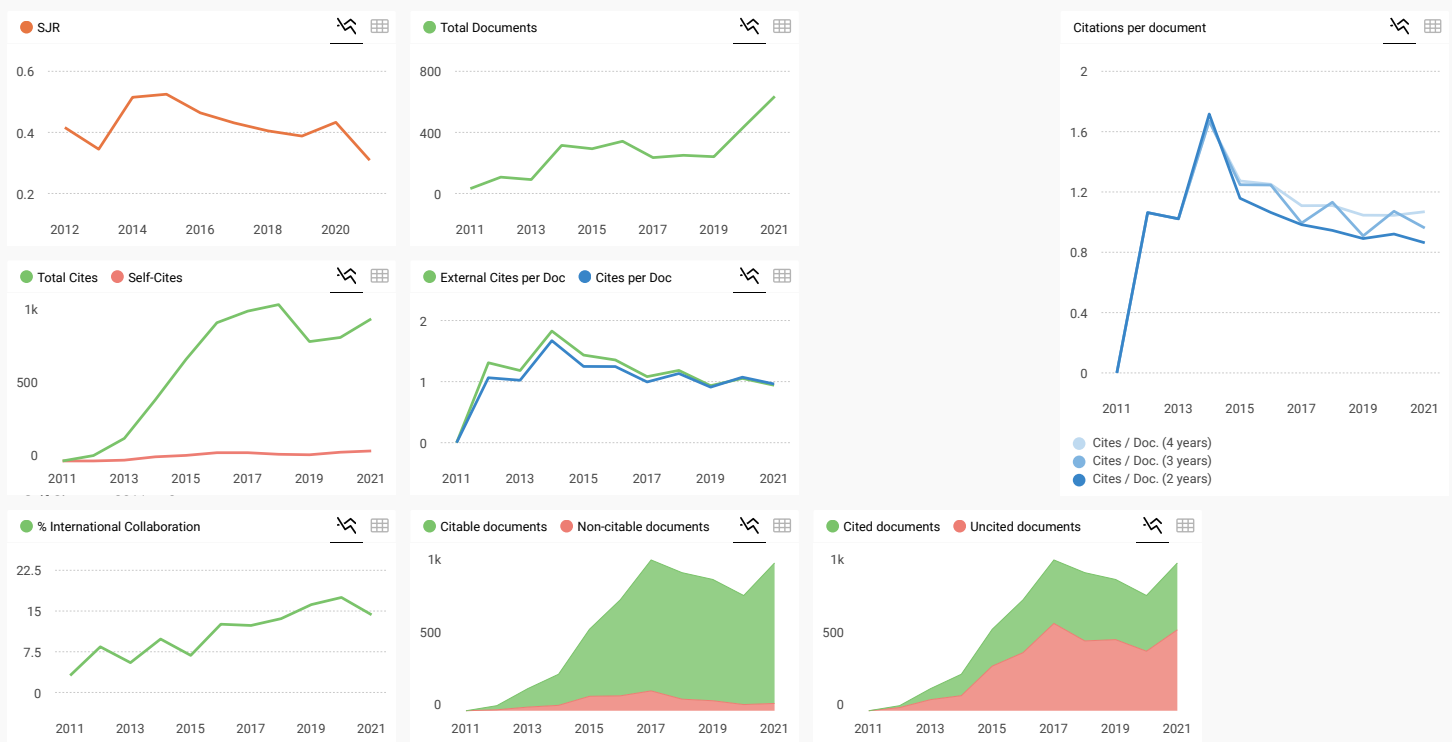
Surgical Neurology International® (SNI) is an open access, Internet-only journal that publishes the latest developments in the field of neurosurgery and related clinical and basic neurosciences. SNI® will also discuss timely and controversial clinical, social, ethical, and political subjects related to the neurosciences of its readers worldwide. SNI® is an independent publication that is not affiliated with any society or organization. The journal welcomes papers and opinions from neurosurgeons and clinical and basic neuroscientists everywhere. Articles submitted to SNI must undergo a double-blind peer review process. SNI publishes on a continuous basis, currently averaging 25 articles per month. Its papers can be downloaded for free by anyone.

 Join the conversation about this journal

FIND SIMILAR JOURNALS

options

<p>1 <b>Interdisciplinary Neurosurgery: Advanced</b> NLD</p> <p><b>93%</b> similarity</p>	<p>2 <b>British Journal of Neurosurgery</b> GBR</p> <p><b>91%</b> similarity</p>	<p>3 <b>World Neurosurgery</b> USA</p> <p><b>91%</b> similarity</p>	<p>4 <b>Neurosurgical Review</b> DEU</p> <p><b>88%</b> similarity</p>	<p>5 <b>Neurosurgical Focus</b> USA</p> <p><b>87%</b> similarity</p>
---	--	---	---	--



**Surgical Neurology International**

Neurology (clinical)

**Q3** best quartile

**SJR 2021**

**0.31**

powered by scimagojr.com

Show this widget in your own website

Just copy the code below and paste within your html code:

`<a href="https://www.scimagojr.com" data-bbox="195 805 295 815">`

**SCImago Graphica**

Explore, visually communicate and make sense of data with our **new data visualization tool.**



**Leave a comment**

Name

Email

(will not be published)

Submit

The users of Scimago Journal & Country Rank have the possibility to dialogue through comments linked to a specific journal. The purpose is to have a forum in which general doubts about the processes of publication in the journal, experiences and other issues derived from the publication of papers are resolved. For topics on particular articles, maintain the dialogue through the usual channels with your editor.

Developed by:



Powered by:



Follow us on [@ScimagoJR](#)

Scimago Lab, Copyright 2007-2022. Data Source: Scopus®

EST MODUS IN REBUS

Horatio (Satire 1,1,106)

[Edit Cookie Consent](#)

Volume 12; 2021

## Book Reviews

---

### [Vitamin C in human health and disease](#)

Seyed Ali Khonsary

Surg Neurol Int. 2021; 12: 142. Published online 2021 Apr 8. doi: 10.25259/SNI\_198\_2021

PMCID: PMC8088531

[Article](#) [PubReader](#) [PDF-240K](#) [Cite](#)

### [“Plants of the Gods” and their hallucinogenic powers in neuropharmacology — A review of two books](#)

Miguel Faria

Surg Neurol Int. 2021; 12: 343. Published online 2021 Jul 12. doi: 10.25259/SNI\_560\_2021

PMCID: PMC8326085

[Article](#) [PubReader](#) [PDF-2.2M](#) [Cite](#)

### [Book review: The China Virus: What is the Truth? by James I. Ausman, MD, PhD, and Russell L. Blaylock, MD. Reviewed by Miguel A. Faria, MD](#)

Miguel Faria

Surg Neurol Int. 2021; 12: 410. Published online 2021 Aug 16. doi: 10.25259/SNI\_705\_2021

PMCID: PMC8422406

[Article](#) [PubReader](#) [PDF-235K](#) [Cite](#)

### [The temporal lobes and the limbic system in neuropsychiatry: A book review](#)

Miguel Faria

Surg Neurol Int. 2021; 12: 423. Published online 2021 Aug 24. doi: 10.25259/SNI\_727\_2021

PMCID: PMC8422460

[Article](#) [PubReader](#) [PDF-299K](#) [Cite](#)

## Case Reports

---

### [Surgical resection of a large posttraumatic middle meningeal artery pseudoaneurysm with associated epidural hematoma](#)

Ryan Michael McCormack, Amber Y. Chen, Lindsey M. Schwartz, Cole T. Lewis, Ryan S. Kitagawa

Surg Neurol Int. 2021; 12: 1. Published online 2021 Jan 5. doi: 10.25259/SNI\_209\_2020

PMCID: PMC7827436

[Article](#) [PubReader](#) [PDF-675K](#) [Cite](#)

### [Cerebellar tallocosis following posterior reversible encephalopathy syndrome in an intravenous methamphetamine abuser](#)

Nidal Bassam Omar, Gustavo Chagoya, Galal A. Elsayed, Silvio H. Litovsky, James R. Hackney, Winfield S. Fisher

Surg Neurol Int. 2021; 12: 2. Published online 2021 Jan 5. doi: 10.25259/SNI\_616\_2020

PMCID: PMC7827572

[Article](#) [PubReader](#) [PDF-1.8M](#) [Cite](#)

### [Basilar artery dissection with rupture 6 years after accidental detection: A case report](#)

Yoshimichi Sato, Kuniyasu Niizuma, Hideki Ota, Hidenori Endo, Teiji Tominaga

Surg Neurol Int. 2021; 12: 4. Published online 2021 Jan 5. doi: 10.25259/SNI\_735\_2020

**PMCID:** PMC7827296

[Article](#) [PubReader](#) [PDF-1.3M](#) [Cite](#)

### [Epidural lipomatosis in elderly patient: A rare cause of cauda equina compression](#)

Abiodun Idowu Okunlola, Tesleem Olayinka Orewole, Cecilia Kehinde Okunlola, Olakunle Fatai Babalola, Akinola Akinmade

Surg Neurol Int. 2021; 12: 7. Published online 2021 Jan 5. doi: 10.25259/SNI\_840\_2020

**PMCID:** PMC7827431

[Article](#) [PubReader](#) [PDF-673K](#) [Cite](#)

### [Two cases of normal pressure hydrocephalus caused by ependymoma of the cauda equina](#)

Isamu Miura, Motoo Kubota, Nobuhiko Momozaki, Masahito Yuzurihara

Surg Neurol Int. 2021; 12: 8. Published online 2021 Jan 5. doi: 10.25259/SNI\_851\_2020

**PMCID:** PMC7827580

[Article](#) [PubReader](#) [PDF-1.3M](#) [Cite](#)

### [Chemotherapy-induced changes in tumor consistency can allow gross total resection of previously unresectable brainstem pilocytic astrocytoma](#)

Douglas J. Chung, Bilal Arif, Yazmin Odia, Vitaly Siomin

Surg Neurol Int. 2021; 12: 12. Published online 2021 Jan 13. doi: 10.25259/SNI\_594\_2020

**PMCID:** PMC7827363

[Article](#) [PubReader](#) [PDF-1.5M](#) [Cite](#)

### [Osimertinib-induced rapid regression of large metastatic tumor to the pituitary in a patient with lung adenocarcinoma](#)

Andrew K. Wong, Troy W. Close, Ricky H. Wong

Surg Neurol Int. 2021; 12: 13. Published online 2021 Jan 13. doi: 10.25259/SNI\_629\_2020

**PMCID:** PMC7827509

[Article](#) [PubReader](#) [PDF-847K](#) [Cite](#)

### [Resolution of venous pressure gradient in a patient with idiopathic intracranial hypertension after ventriculoperitoneal shunt placement: A proof of secondary cerebral sinovenous stenosis](#)

Thomas Buell, Dale Ding, Daniel Raper, Ching-Jen Chen, Zaid Aljuboori, Davis Taylor, Tony Wang, Natasha Ironside, Robert Starke, Kenneth Liu

Surg Neurol Int. 2021; 12: 14. Published online 2021 Jan 13. doi: 10.25259/SNI\_700\_2020

**PMCID:** PMC7827289

[Article](#) [PubReader](#) [PDF-1.2M](#) [Cite](#)

### [Grisel's syndrome in adults: A case report](#)

Dilyan Ferdinandov, Dimo Yankov, Assen Bussarsky

Surg Neurol Int. 2021; 12: 15. Published online 2021 Jan 13. doi: 10.25259/SNI\_733\_2020

**PMCID:** PMC7827359

[Article](#) [PubReader](#) [PDF-801K](#) [Cite](#)

### [Trauma may affect vasa vasorum to promote thrombosis and enlargement of intracranial aneurysms: A](#)

### [A case of Wilson disease with the ATP7B mutation presenting movement disorders](#)

Huong Van Nguyen, Diep Ngoc Nguyen, Huong Thi Nguyen

Surg Neurol Int. 2021; 12: 303. Published online 2021 Jun 28. doi: 10.25259/SNI\_489\_2021

PMCID: PMC8326090

[Article](#) [PubReader](#) [PDF-485K](#) [Cite](#)

### [Clinical presentation and management of hypophysitis: An observational study of case series](#)

Marouan Karrou, Salma Benyakhlef, Achwak Alla, Najoua Messaoudi, Asmae Oulad Amar, Siham Rouf, Imane Kamaoui, Nouredine Oulali, Faycal Moufid, Naima Abda, Hanane Latrech

Surg Neurol Int. 2021; 12: 304. Published online 2021 Jun 28. doi: 10.25259/SNI\_454\_2021

PMCID: PMC8326108

[Article](#) [PubReader](#) [PDF-633K](#) [Cite](#)

### [Ectopic intraconal orbital meningioma – A rare case report](#)

Anil Kumar Sharma, Charandeep Singh Gandhoke, Somen Misra, Ashik Ravi, Rakesh Kumar Gupta, Surendra Kumar Gupta

Surg Neurol Int. 2021; 12: 305. Published online 2021 Jun 28. doi: 10.25259/SNI\_84\_2021

PMCID: PMC8326082

[Article](#) [PubReader](#) [PDF-1.6M](#) [Cite](#)

### [Deadly complication of sacrificing superior petrosal vein during cerebellopontine angle tumor resection: A case report and literature review](#)

Irwan Barlian Immadoel Haq, Andhika Tomy Permana, Rahadian Indarto Susilo, Joni Wahyuhadi

Surg Neurol Int. 2021; 12: 306. Published online 2021 Jun 28. doi: 10.25259/SNI\_948\_2020

PMCID: PMC8326145

[Article](#) [PubReader](#) [PDF-973K](#) [Cite](#)

### [To cut or not to cut? A case report on pediatric intervertebral disc calcification](#)

Hunter J. King, Rohin Ramchandani, Christina Maxwell, Atom Sarkar, Tina Loven

Surg Neurol Int. 2021; 12: 307. Published online 2021 Jun 28. doi: 10.25259/SNI\_207\_2021

PMCID: PMC8326060

[Article](#) [PubReader](#) [PDF-568K](#) [Cite](#)

### [Rare incidence of tension pneumocephalus 2 months after repeat microvascular decompression](#)

Jaims Lim, Elizabeth Nyabuto, Kunal Vakharia, Elad I. Levy

Surg Neurol Int. 2021; 12: 311. Published online 2021 Jun 28. doi: 10.25259/SNI\_917\_2020

PMCID: PMC8326134

[Article](#) [PubReader](#) [PDF-914K](#) [Cite](#)

### [Management of recurrent schwannoma of the cauda equina: A case report](#)

Francisco Perez-Pinto, Juan Felipe Abaunza-Camacho, David Vergara-Garcia, Camilo Benavides, William Mauricio Riveros, Leonardo Laverde

Surg Neurol Int. 2021; 12: 312. Published online 2021 Jun 28. doi: 10.25259/SNI\_357\_2021

PMCID: PMC8326104

[Article](#) [PubReader](#) [PDF-1.2M](#) [Cite](#)

### [Ganglioglioma of the cervicothoracic spinal cord in a patient with neurofibromatosis type 1: A case report](#)

Thainá Zanon Cruz, Pedro Henrique Costa Ferreira-Pinto, Ana Carolina Gonçalves Brito, Leandro Ururahy, Jefferson Trivino Sanchez, Flavio Nigri



PMCID: PMC8326088

[Article](#) [PubReader](#) [PDF-2.2M](#) [Cite](#)

### [Meningioma as the host for metastatic breast cancer: A rare occurrence with important therapeutic impact](#)

Mohammad Hosseinzadeh, Seyed Mehdi Ketabchi, Seyed Ali Ahmadi, Kasra Hendi, Maysam Alimohamadi

Surg Neurol Int. 2021; 12: 314. Published online 2021 Jun 28. doi: 10.25259/SNI\_148\_2021

PMCID: PMC8326081

[Article](#) [PubReader](#) [PDF-953K](#) [Cite](#)

### [S-100-negative, GNA11 mutation-positive intramedullary meningeal melanocytoma of the thoracic spine: A radiographic challenge and histologic anomaly](#)

Alex Flores, Ron Gadot, Ibrahim Noorbhai, Hayden Hall, Kent Alan Heck, Daniel Matthew Sholto Raper, David Xu, Patrick Karas, Jacob J. Mandel, Alexander Eli Ropper

Surg Neurol Int. 2021; 12: 315. Published online 2021 Jun 28. doi: 10.25259/SNI\_416\_2021

PMCID: PMC8326103

[Article](#) [PubReader](#) [PDF-1.1M](#) [Cite](#)

### [Surgical treatment of spinal arachnoid web: Report of two cases and literature review](#)

Anderson Batista Rodrigues, Daniella Brito Rodrigues, Joao Welberthon Matos Queiroz, Kaito Alves Carvalho Laube, Murillo Cunegatto Macullo Braga, William Seiti Kita, Allexsandro Aparecido Alvarenga Nascimento Faria De Luna, Rafael Wilson De Souza, Ricardo Henrique Doria Netto

Surg Neurol Int. 2021; 12: 316. Published online 2021 Jun 28. doi: 10.25259/SNI\_493\_2021

PMCID: PMC8326061

[Article](#) [PubReader](#) [PDF-1.0M](#) [Cite](#)

### [Coronavirus disease 2019 infection and pituitary apoplexy: A causal relation or just a coincidence? A case report and review of the literature](#)

Walaa A. Kamel, Mustafa Najibullah, Mamdouh S. Saleh, Waleed A. Azab

Surg Neurol Int. 2021; 12: 317. Published online 2021 Jun 28. doi: 10.25259/SNI\_401\_2021

PMCID: PMC8326077

[Article](#) [PubReader](#) [PDF-1.3M](#) [Cite](#)

### [Trigeminal neuralgia secondary to onyx embolization of a right occipital arteriovenous malformation](#)

Mohamad El Houshiemy, Shadi Abdelatif Bsar, Ryan El Ghazal, Charbel Moussalem, Ali Amine, Sarah Kawtharani, Adham Halaoui, Hazem Assi, Houssein Darwish

Surg Neurol Int. 2021; 12: 318. Published online 2021 Jun 28. doi: 10.25259/SNI\_379\_2021

PMCID: PMC8326083

[Article](#) [PubReader](#) [PDF-805K](#) [Cite](#)

### [Traumatic epidural hematoma treated with endovascular coil embolization](#)

Michael T. Madison, Patrick C. Graupman, Jason M. Carroll, Collin M. Torok, Jillienne C. Touchette, Eric S. Nussbaum

Surg Neurol Int. 2021; 12: 322. Published online 2021 Jul 6. doi: 10.25259/SNI\_939\_2020

PMCID: PMC8326102

[Article](#) [PubReader](#) [PDF-671K](#) [Cite](#)

### [Thoracic dorsal arachnoid web with rapid onset of symptoms: A report of two cases and brief review of the literature](#)

Tripp Hines, Catherine Wang, Christine Duttlinger, Jay Thompson, Kevin Watford, Benjamin Motley, Greg Wheeler

Surg Neurol Int. 2021; 12: 323. Published online 2021 Jul 6. doi: 10.25259/SNI\_339\_2021

PMCID: PMC8326092

[Article](#) [PubReader](#) [PDF-1.5M](#) [Cite](#)

### [Giant Actinomyces brain abscess in an immunocompetent child: A management strategy](#)

Nicole H. Chicoine, Jackson Griffith-Linsley, Joling Goh, John J. Manaloor, Jeffrey S. Raskin

Surg Neurol Int. 2021; 12: 325. Published online 2021 Jul 6. doi: 10.25259/SNI\_164\_2021

PMCID: PMC8326064

[Article](#) [PubReader](#) [PDF-1.0M](#) [Cite](#)

### [Supratentorial lymphocytic inflammation with parenchymal perivascular enhancement responsive to steroids: A case report and literature review](#)

Vivek Sudhakar, Zachary Gersey, Sean P. Polster, Megan Mantica, George Zenonos

Surg Neurol Int. 2021; 12: 327. Published online 2021 Jul 6. doi: 10.25259/SNI\_355\_2021

PMCID: PMC8326066

[Article](#) [PubReader](#) [PDF-1.3M](#) [Cite](#)

### [Remarkable shrinkage of a thrombosed giant aneurysm by stent-assisted jam-packed coil embolization](#)

Takaaki Mitsui, Ichiro Nakagawa, Masashi Kotsugi, HunSoo Park, Shohei Yokoyama, Kaoru Myouchin, Hiroyuki Nakase

Surg Neurol Int. 2021; 12: 328. Published online 2021 Jul 6. doi: 10.25259/SNI\_511\_2021

PMCID: PMC8326107

[Article](#) [PubReader](#) [PDF-1.2M](#) [Cite](#)

### [Spontaneous epidural pneumorrhachis in 14 years old](#)

Joseph Scott Hudson, Seung Jeong, Xiaoran Zhang, Taylor J. Abel

Surg Neurol Int. 2021; 12: 329. Published online 2021 Jul 6. doi: 10.25259/SNI\_414\_2021

Correction in: [Surg Neurol Int. 2021; 12: 404.](#)

PMCID: PMC8326144

[Article](#) [PubReader](#) [PDF-370K](#) [Cite](#)

### [Thoracic intramedullary neurosarcoidosis with thoracic disc herniation: Diagnostic importance of intramedullary contrast enhancement](#)

Justin Beiriger, Hussam Abou-Al-Shaar, Hansen Deng, Mansour Mathkour, David O. Okonkwo

Surg Neurol Int. 2021; 12: 331. Published online 2021 Jul 6. doi: 10.25259/SNI\_535\_2021

PMCID: PMC8326063

[Article](#) [PubReader](#) [PDF-596K](#) [Cite](#)

### [Posttraumatic C2-C3 spondyloptosis without focal neurological deficit, treated with anterior and posterior approaches: A case report](#)

Arash Fattahi, Abdoulhadi Daneshi, seyed Mohammad Reza Mohajeri

Surg Neurol Int. 2021; 12: 332. Published online 2021 Jul 6. doi: 10.25259/SNI\_462\_2021

PMCID: PMC8326071

[Article](#) [PubReader](#) [PDF-514K](#) [Cite](#)

### [High-flow bypass surgery using a radial artery graft for an extracranial internal carotid artery aneurysm: Case reports and literature review](#)

Kenta Koketsu, Kyongsong Kim, Minoru Ideguchi, Rinko Kokubo, Takayuki Mizunari, Akio Morita

Articles ▾

Posts ▾

Videos ▾

Societies ▾

Apps

About US

Editorial Board



**SURGICAL NEUROLOGY**

**INTERNATIONAL<sup>®</sup>**



**INNOVATION IN**

**LEARNING<sup>™</sup>**

Log in

MENU

English

Search our growing library of 5945 free articles, videos, and more

## Editorial Board

### Editor-in-Chief

Nancy Epstein, MD

Professor of Clinical Neurosurgery,

School of Medicine, State University of New York at Stony Brook; New York, NY

Chief of Neurosurgical Spine and Education

NYU Winthrop Hospital; Mineola, NY

### Emeritus Editor-in-Chief

James I. Ausman, MD, PhD

UCLA Department of Neurosurgery, Los Angeles, CA

### Founding Editors

James Ausman – UCLA Department of Neurosurgery, Los Angeles, CA

Atos de Sousa (2010–2013) – Gerais Santa Casa Hospital and Lifecenter Hospital; Belo Horizonte, Brazil

Robert "Bob" Goodkin (2010–2012) – University of Washington; Seattle, WA, USA

Pat Kelly – NYU School of Medicine; New York, NY, USA

Neil Martin – Geisinger Health System; Danville, PA

## Managing Editor

Jim Cook  
31855 Date Palm Drive, Suite 3-400  
Cathedral City, CA 92234  
(760) 349-6600

## Supplements

### SNI: Computational

#### Associate Editor-in-Chief:

Pieter L. Kubben, MD, PhD  
Maastricht University Medical Center; Maastricht, The Netherlands

#### Editors:

Alkinoos Athanasiou – Aristotle University of Thessaloniki; Thessaloniki, Greece  
Philippe Bijlenga – Hôpitaux Universitaires de Genève; Geneva, Switzerland  
Guillaume Charvet – Clinatex; Grenoble, France  
Daniel John DiLorenzo – Loma Linda University Medical Center; Loma Linda, CA, USA  
Francesco DiMeco – Istituto Nazionale Neurologico "C.Besta"; Milan, Italy  
Erik Gommer – Maastricht University Medical Center; Maastricht, The Netherlands  
Michael Murek – Inselspital, Universitätsspital Bern; Bern, Switzerland  
Felix Scholtes – Centre Hospitalier Universitaire de Liège; Liège, Belgium  
Philipp Schucht – Inselspital, Universitätsspital Bern; Bern, Switzerland  
Peter Willems – Leiden University Medical Center; Leiden, The Netherlands

### SNI: Digital Medicine

#### Associate Editor-in-Chief:

James I. Ausman, MD, PhD  
UCLA Department of Neurosurgery, Los Angeles, CA;

#### Editors:

Abdul Hadi Al-Khalili – Baghdad University; Baghdad, Iraq  
Zahraa Al-Sharshahi – Neurosurgery Teaching Hospital; Baghdad, Iraq  
Tarun Arora – University of California at San Francisco; San Francisco, CA, USA  
Iype Cherian – Bharatpur College of Medical Sciences; Chitwan, Nepal  
Chandrashekar Deopujari – Hinduja Hospital; Mahim, Mumbai, India  
Abdeslam El Khamlichi – Mohammed V University of Rabat; Rabat, Morocco  
S. Ather Enam – Aga Khan University; Karachi, Sindh, Pakistan  
Nancy Epstein – State University of New York at Stony Brook; New York, NY, USA  
Moneer Faraj – University of Baghdad; Baghdad, Iraq  
Marco Gonzales-Portillo – Instituto Neurociencias de Lima; Lima, Peru  
Marwan Hariz – Umeå University; Umeå, Sweden  
Kazuhiro Hongo – Shinshu University; Matsumoto, Japan  
Samer Hoz – University of Cincinnati; Cincinnati, OH, USA  
Seyed Ali Khonsary – University of California at Los Angeles; Los Angeles, CA, USA  
Jorge Lazareff – University of California Los Angeles; Los Angeles, CA, USA  
Jay Morgan – Sierra Neurosurgery Group; Reno, NV, USA  
Hiba Abdulmir Nasir – Dr. Saad Alwitry Neurosciences Hospital; Baghdad, Iraq  
Eric Nussbaum – National Brain Aneurysm & Tumor Center, Twin Cities, MN, USA  
Frank Van Calenbergh – University Hospitals; Leuven, Belgium

### SNI: Epilepsy

#### Associate Editor-in-Chief:

Warren Boling, MD  
Loma Linda University Medical Center; Loma Linda, CA, USA

### SNI: General Neurosurgery

#### Associate Editor-in-Chief:

Eric Nussbaum, MD

## **SNI: Global Health and Education**

### **Associate Editor-in-Chief:**

Jorge Lazareff MD, FAANS

University of California Los Angeles; Los Angeles, CA, USA

### **Editors:**

Seyed Ali Khonsary – University of California at Los Angeles; Los Angeles, CA, USA

## **SNI: Head and Spinal Cord Transplantation**

### **Associate Editors-in-Chief:**

Sergio Canavero, MD

XiaoPing Ren, MD

HEAVEN/GEMINI International Collaborative Group, Turin, Italy

### **Editors:**

Farid Amirouche – University of Illinois at Chicago

## **SNI: History of Medicine**

### **Associate Editor-in-Chief:**

Miguel Faria, MD

Founder and Editor Emeritus, Medical Sentinel; [www.haciendapublishing.com](http://www.haciendapublishing.com); Macon, GA, USA

### **Editor:**

Russell Blaylock – Advanced Nutritional Concepts and Theoretical Neurosciences; Ridgeland, MS, USA

## **SNI: Infection**

### **Associate Editor-in-Chief:**

Ali Akhaddar, MD, IFAANS

Avicenne Military Hospital; Marrakech, Morocco

### **Editors:**

Mohamed Benzagmout – University Hospital of Fez; Fez, Morocco

Walter Hall – State University of New York; Syracuse, NY, USA

Julio Sotelo – National Institute of Neurology and Neurosurgery; Mexico City, Mexico

Mehmet Turgut – Adnan Menderes University School of Medicine; Aydin, Turkey

## **SNI: Medical Legal Public Health and Policy**

### **Associate Editor-in-Chief:**

Clark Watts, MD

University of Texas School of Law; Austin, TX, USA

## **SNI: Neuroanatomy/Neurophysiology**

### **Associate Editor-in-Chief:**

Seyed Ali Khonsary, MD

University of California at Los Angeles; Los Angeles, CA, USA

## **SNI: Neuroanesthesia and Critical Care**

### **Associate Editor-in-Chief:**

Ramsis F. Ghaly, MD

University of Illinois at Chicago; Chicago, IL, USA

## **SNI: Neuroendoscopy**

### **Associate Editor-in-Chief:**

J. André Grotenhuis, MD

Radboud University Medical Center; Nijmegen, The Netherlands

### **Editor:**

Chandrashekhara Deopujari – Hinduja Hospital; Mahim, Mumbai, India

## **SNI: Neuro–Inflammation**

### **Associate Editor–in–Chief:**

Russell Blaylock, MD

Advanced Nutritional Concepts and Theoretical Neurosciences; Ridgeland, MS, USA

### **Editors:**

F. Gómez–Pinilla – University of California at Los Angeles; Los Angeles, CA, USA

## **SNI: Neuro–oncology and Skull Base**

### **Associate Editor in Chief:**

Mitsutoshi Nakada, MD, PhD

Kanazawa University; Ishikawa, Japan

### **Editors:**

Chandrashekhara Deopujari – Hinduja Hospital; Mahim, Mumbai, India

Yasuhiko Hayashi – Kanazawa Medical University; Ishikawa, Japan

Lauren Hertan – Beth Israel Deaconess Medical Center; Boston, MA, USA

Imad N. Kanaan – The King Faisal Specialist Hospital and Research Center; Riyadh, Saudi Arabia

Kazuhiko Kurozumi – Okayama University; Okayama, Japan

Anand Mahadevan – Beth Israel Deaconess Medical Center; Boston, MA, USA

Aldo A. Spallone – NCL – Institute of Neurosciences; Rome, Italy

Lee E. Tessler – Neurological Surgery, P.C.; Long Island, NY, USA

## **SNI: Neuropathology**

### **Associate Editor–in–Chief:**

Istvan Bodi

King's College Hospital NHS Foundation Trust; London, United Kingdom

### **Editors:**

Johannes A. Hainfellner, MD – Medical University of Vienna; Vienna, Austria

Tibor Hortobágyi, MD – Faculty of Medicine, University of Debrecen; Debrecen, Hungary

## **SNI: Neuropsychiatry**

### **Associate Editors–in–Chief:**

Miguel Faria, MD

Founder and Editor Emeritus, Medical Sentinel; [www.haciendapublishing.com](http://www.haciendapublishing.com); Macon, GA, USA

Russell Blaylock, MD

Advanced Nutritional Concepts and Theoretical Neurosciences; Ridgeland, MS, USA

### **Editor:**

C. Pritchard – Bournemouth University; Poole, England

Robert B. Young – University of Rochester School of Medicine; Rochester, NY, USA

Oswaldo Vilela–Filho – Federal University of Goiás; Goiânia, Brazil

## **SNI: Neurosurgery Concepts: Perspectives on Key Articles in Neurosurgery**

### **Associate Editor–in–Chief:**

Isaac Yang, MD

UCLA Medical Center; Los Angeles, CA, USA

### **Editors:**

A.M. Bohnen – Northwestern University; Chicago, IL, USA

J.M. Cho – Ajou University School of Medicine; Suwon, South Korea

C.B. Colen – Beaumont Hospital; Grosse Pointe, MI, USA

N.S. Dahdaleh – Northwestern University; Chicago, IL, USA

E. Duckworth – Baylor College of Medicine; Houston, TX, USA

A.V. Germanwala – Loyola University School of Medicine; Maywood, IL, USA

P. Kan – Baylor College of Medicine; Houston, TX, USA

A. Khalessi – University of California at San Diego; San Diego, CA, USA

C.Y. Kim – Seoul National University Bundang Hospital; Seongnam-si, Gyeonggi-do, South Korea  
S. Lam – Baylor College of Medicine; Houston, TX, USA  
G. Li – Stanford University; Stanford, CA, USA  
M. Lim – Johns Hopkins University; Baltimore, MD, USA  
J.H. Sherman – George Washington University; Washington, DC, USA  
V.Y. Wang – University of California at San Francisco; San Francisco, CA, USA  
G. Zada – Keck School of Medicine at U.S.C.; Los Angeles, CA, USA

## **SNI: Neurovascular**

### **Associate Editor-in-Chief:**

Kazuhiro Hongo, MD  
Shinshu University; Matsumoto, Japan

### **Editors:**

Vladimir Beneš – Charles University; Prague, Czech Republic  
G.W. Britz – The Methodist Hospital; Houston, TX, USA  
J.A. Dye – University of California at Los Angeles; Los Angeles, CA, USA  
J. Frösen – Helsinki University Central Hospital; Helsinki, Finland  
Atul Goel, MD – King Edward Memorial Hospital, Mumbai, India  
G. Grasso – University of Palermo; Palermo, Italy  
Tetsuyoshi Horiuchi, MD, PhD – Shinshu University School of Medicine, Asahi, Japan  
Kiyohiro Houkin, MD, PhD – Hokkaido University Hospital, Sapporo, Japan  
Vijendra K. Jain – Max Superspecialty Hospital; New Delhi, India  
Yoko Kato – Fujita Health University Hospital, Toyoake, Japan  
M.J. Korja – Macquarie University Hospital; Sydney, Australia  
Satoshi Kuroda, MD, PhD – University of Toyama, Toyama, Japan  
G. Lanzino – Mayo Clinic; Rochester, MN, USA  
Yasushi Matsumoto, MD – Kohnan Hospital, Sendai, Japan  
R. Loch Macdonald – University of Toronto; Toronto, Ontario, Canada  
Yuichi Murayama, MD – Jikei University School of Medicine, Tokyo, Japan  
E.S. Nussbaum – St. Joseph's Hospital; Twin Cities, MN, USA  
Amitendu Sekhar – Manipal Hospital; Salem, India  
T. Shibuya – Nihon University School of Medicine; Tokyo, Japan  
Yuichiro Tanaka, MD – St. Marianna University School of Medicine, Kawasaki, Japan  
P. Taussky – University of Utah; Salt Lake City, UT, USA  
K. Van Overbeeke – Maastricht University Medical Centre; Maastricht, The Netherlands  
D.A. Vega-Moreno – National Autonomous University of Mexico; Mexico City, Mexico  
Shinichi Yoshimura – Hyogo College of Medicine, Hyogo, Japan  
J. Zabramski – Barrow Neurosurgical Associates; Phoenix, AZ, USA

## **SNI: Nursing**

### **Associate Editor-in-Chief:**

Nancy Epstein, MD  
NYU Winthrop Hospital; Mineola NY, USA

## **SNI: Pain**

### **Associate Editor-in-Chief:**

Jeff Brown  
Neurological Surgery, P.C.; Great Neck, NY, USA

## **SNI: Pediatric Neurosurgery**

### **Associate Editor-in-Chief:**

Frank Van Calenbergh, MD  
University Hospitals; Leuven, Belgium

### **Editors:**

Chandrashekhara Deopujari – Hinduja Hospital; Mahim, Mumbai, India  
G. Grant – University Medical Center; Durham, NC, USA  
J. Lazareff – University of California at Los Angeles; Los Angeles, CA, USA  
M.Z. Tahir – Great Ormond Street Children's Hospital, NHS Foundation Trust; London, UK

# SNI: Review of Randomized Controlled Trials

## Associate Editor-in-Chief:

Benjamin W. Y. Lo, MD

Montreal Neurological Institute & Hospital, McGill University; Quebec, Canada

## Editors:

Mark Angle – Montreal Neurological Institute & Hospital, McGill University; Quebec, Canada

Hitoshi Fukuda – Kochi University Hospital; Kochi, Japan

Masaomi Koyanagi – National Hospital Organization Himeji Medical Center (Kyoto University); Hyogo, Japan

Matthew Wai-Man Lui – Queen Mary Hospital, University of Hong Kong; Pokfulam, Hong Kong

Satoru Miyawaki – The University of Tokyo; Tokyo, Japan

Jeanne Teitelbaum – Montreal Neurological Institute & Hospital, McGill University; Quebec, Canada

Anderson C.O. Tsang – The University of Hong Kong; Hong Kong

George Kwok Chu Wong – Prince of Wales Hospital, Chinese University of Hong Kong; Shatin, Hong Kong

## Ad Hoc Members:

Mitchell A. H. Levine – McMaster University; Hamilton, Ontario, Canada

Abbas Sadikot – Montreal Neurological Institute & Hospital, McGill University

# SNI: Revista Argentina de Neurocirugía

## Associate Editors-in-Chief:

Álvaro Campero -- Hospital Padilla, S. M. Tucumán

Matteo Baccanelli -- Hospital Italiano de Buenos Aires; Buenos Aires, Argentina

Secretario de Redacción: Rubén Mormandi – FLENI, CABA

Editor Fundador: León Turjanski – Hospital Cosme Argerich, CABA

### Comité de Redacción

Matteo Baccanelli – Hospital Italiano de Buenos Aires

Martín Guevara – Hospital Fernández, CABA

Martín Saez – Hospital Gandulfo, Lomas de Zamora

Fidel Sosa – Hospital El Cruce, Florencio Varela

Pablo Rubino – Hospital El Cruce, Florencio Varela

Pablo Ajler – Hospital Italiano, CABA

Sergio Pampín – Hospital Posadas, Ramos Mejía

Tomás Funes – Sanatorio Otamendi, CABA

Jorge Bustamante – Hospital El Cruce, Florencio Varela

Federico Landriel – Hospital Italiano, CABA

Leopoldo Luque – Hospital El Cruce, Florencio Varela

### Comité Asesor y de Revisión

Coordinador: Marcelo Platas

#### Miembros:

Jaime Rimoldi

Jorge Oviedo

Rafael Torino

Juan Mezzadri

Graciela Zúccaro

Luis Lemme Plaghos

Jorge Salvat

Julio César Suarez

Julio Antico

Horacio Fontana

Oscar Stella

Antonio Carrizo

Silvia Berner

Jorge Lambre

Francisco Papalini

León Turjanski

Alejandra Rabadán

Javier Gardella



Matteo Baccanelli – Hospital Italiano de Buenos Aires

Pablo Ajler – Hospital Italiano, CABA

Federico Landriel – Hospital Italiano, CABA,

## **SNI: Socioeconomics, Politics, Medicine and World Affairs**

### **Associate Editors-in-Chief:**

James I Ausman, MD, PhD

UCLA Department of Neurosurgery, Los Angeles, CA

Russell Blaylock, MD

Advanced Nutritional Concepts and Theoretical Neurosciences; Ridgeland, MS, USA

Miguel Faria, MD

Founder and Editor Emeritus Medical Sentinel; [www.haciendapublishing.com](http://www.haciendapublishing.com)

Walter Johnson, MD

World Health Organization; Geneva, Switzerland

### **Editors:**

Youssef Fares, MD, PhD, EMBA – Lebanese University; Beirut, Lebanon

## **SNI: Stereotactic**

### **Associate Editor-in-Chief:**

Konstantin V. Slavin

University of Illinois at Chicago; Chicago, IL, USA

### **Editors:**

Antonio A.F. De Salles – University of California; Los Angeles, CA, USA

Moneer Faraj – University of Baghdad; Baghdad, Iraq

Alessandra Gorgulho – University of California; Los Angeles, CA, USA

D. Kondziolka – University of Pittsburgh; Pittsburgh, PA, USA

K. Lizarraga – University of Rochester; Rochester, NY, USA

T. Mindermann – Klinik Im Park; Zurich, Switzerland

Hiba Abdulmir Nasir – Dr. Saad Alwitry Neurosciences Hospital; Baghdad, Iraq

N. Pouratian – University of California; Los Angeles, CA, USA

G. Sinclair – North Middlesex University Hospital NHS Trust, London, UK

## **SNI: Spine**

### **Associate Editor-in-Chief:**

Nancy Epstein, MD

NYU Winthrop Hospital; Mineola NY, USA

### **Editors:**

K. Abumi – Hokkaido University Health; Sapporo, Japan

P. Arnold – University of Kansas; Kansas City, KS, USA

J. Baisden – University of Wisconsin, Milwaukee, WI, USA

P.G. Benton – Atlanta Medical Center, Atlanta, GA, USA

B.R. Cohen – NYU Winthrop Hospital; Mineola, NY, USA

F. Cohen – Palm Beach Gardens Medical Center; Palm Beach Gardens, FL, USA

B. Cunha – NYU Winthrop Hospital; Mineola, NY

R. A. Deyo – Oregon Health and Science University; Portland, OR, USA

D. J. DiLorenzo – Loma Linda University Medical Center; Loma Linda, CA, USA

T. B. Ducker – Retired, Johns Hopkins University; Baltimore, MD, USA

J.H. Dunn – Southern Arizona VA Health Center; Tucson, AZ, USA

C. L. Forte – Blume, Goldfaden, Berkowitz, Donnelly, Fried, & Forte; Jersey City, NJ, USA

F. W. Gamache – Cornell Medical Center; NY, NY, USA

E. N. Hanley – Carolinas Health Care; Charlotte, NC, USA

D. L. Hilton – Neurosurgical Associates of San Antonio; San Antonio, TX, USA

L. T. Holly – UCLA Medical Center; Los Angeles, CA, USA

R. Hollingsworth – NYU Winthrop Hospital; Mineola, NY, USA

G. B. Jacobs – Hackensack University Medical Center; South Hackensack, NJ, USA  
P. M. Lippe – Vista de Almaden; San Jose, CA, USA  
B. W. Lo – Montreal Neurological Institute & Hospital, McGill University; Quebec, Canada  
J. Loeser – University of Washington; Seattle, WA, USA  
D. J. Maiman – University of Wisconsin; Milwaukee, WI, USA  
R. A. McGuire – University of Mississippi Medical Center; Jackson, MS, USA  
H. Morgan – University of Texas Southwestern Medical Center; Dallas, TX, USA  
H. Moses – Greater Baltimore Medical Center; Baltimore, MD, USA  
H. Nakagawa – Univeristy of Nagoya; Nagoya, Japan  
A. Okawa – Tokyo Medical and Dental University, Graduate School of Medicine; Tokyo, Japan  
A. A. Patel – Loyola University Health System; Maywood, IL, USA  
R. Pawl – Loyola University Hospital; Lake Forest, IL, USA  
G. R. Reichtine – Florida Orthopedic Institute; Tampa, FL, USA  
K. Shinomiya – Tokyo Medical and Dental University; Tokyo, Japan  
M. Stecker – University of California at San Francisco; Fresno, CA, USA  
P. J. Tortolani – Union Memorial Hospital; Baltimore, MD, USA  
V. C. Traynelis – Hackensack University Medical Center; South Hackensack, NJ, USA  
M. Visocchi – Catholic University of Rome; Rome, Italy  
J. Wang – UCLA School of Medicine; Santa Monica, CA, USA  
C. Watts – University of Texas School of Law; Austin, TX, USA  
K. Yonenobu – Osaka–Minami Medical Center; Kawachinagano, Osaka, Japan  
S. Zeidman – The Uniformed Services University of the Health Sciences; Bethesda, MD, USA

## **SNI: Trauma**

### **Associate Editors–in–Chief:**

Naveed Ashraf

University of Health Sciences; Lahore, Pakistan

Iype Cherian

Krishna institute of Medical Sciences; Malkapur, India

Corrado Iaccarino

University of Modena and Reggio Emilia; Modena, Italy

Jutty Parthiban

Kovai Medical Center and Hospital; Tamil Nadu, India

### **Editors:**

P.D. Le Roux – The Brain and Spine Center; Wynnewood, PA, USA

Eric Thelin – Karolinska University Hospital; Stockholm, Sweden

## **SNI: Unique Case Observations**

### **Associate Editor–in–Chief:**

S. Ather Enam, MD, PhD

Aga Khan University; Karachi, Sindh, Pakistan

### **Editors:**

Bilal Khan Afridi – Lady Reading Hospital; Peshawar, Pakistan

Mehboob Alam – POF Hospital; Wah Cantt, Islamabad, Pakistan

Muhammad Alam – The Aga Khan University Hospital; Karachi, Pakistan

Altaf Alilaghari – The Aga Khan University Hospital; Karachi, Pakistan

Hafiza Fatima Aziz – The Aga Khan University Hospital; Karachi, Pakistan

Waqas Baqai – The Aga Khan University Hospital; Karachi, Pakistan

Saad Bin Anis – Shaukat Khanum Hospital; Lahore, Pakistan

Ehsan Bari – The Aga Khan University Hospital; Karachi, Pakistan

Ali Bydon – Johns Hopkins Hospital; Baltimore, MD, United States

Jaskaran Singh Gosal – All India Institute of Medical Sciences; Jodhpur, Rajasthan, India

Waeel Hamouda – Cairo University; Cairo, Egypt

Muhammad Imran – Dow University of Health Sciences; Karachi, Pakistan

Gohar Javed – Aga Khan University, Karachi, Pakistan

Saad Akhter Khan – The Aga Khan University Hospital; Karachi, Pakistan

Sara Khan – The Aga Khan University Hospital; Karachi, Pakistan

Rajesh Kumar – Dubai Medical College; Dubai, United Arab Emirates

Ian Lee – Henry Ford Hospital; Detroit, MI, United States

Farhan Mirza – Montreal Neurological Institute; Montreal, Quebec, Canada  
Fatima Mubarak – The Aga Khan University Hospital; Karachi, Pakistan  
Moshiur Rahman – Holy Family Red Crescent Medical College, Dhaka, Bangladesh  
Bharath Raju – Rutgers University; New Brunswick, NJ, United States  
Yaseen Rauf – Patel Hospital; Karachi, Pakistan  
Shahzad Shamim – The Aga Khan University Hospital; Karachi, Pakistan  
Zaeem Sultan – Queen Elizabeth Hospital; Birmingham, United Kingdom  
Morteza Taheri – Iran University of Medical Sciences; Tehran, Iran  
Zubair Tahir – Great Ormond Street Childrens Hospital; London, England  
Badar Ujjan – Memom Medical Institute; Karachi, Pakistan  
Naveed Zaman – Rehman Medical Institute; Peshawar, Pakistan

## Contributing Editors

Ethics: L.F. Post, MD  
Genetics: R. Rosenberg, MD

## SNI Publications

Owners:

James I. And Carolyn R. Ausman Educational Foundation, a 501c3, Tax Deductible Private Operating Foundation

## 2 Comments



Carol L. Harte

Posted December 2, 2022, 10:55 am

I had occasion to read “COVID UPDATE: What is the Truth?” written by a Russell L. Blaylock, who serves on your editorial board in several non-scientific capacities (history, socioeconomics, etc.). Although I agree with many of his assertions, I am mystified that his excessive hyperbole, personal attacks and over-the-top rhetoric would remotely qualify this article for inclusion in the SNI (or any scientific) database. Perhaps your mission statement provides some justification in its reference to peer reviews and fact-based content while, at the same time, acknowledging that readers may interpret facts differently...but that’s a real stretch here. I am apolitical but instinctively question the credibility of any medical practitioner who refers (in this instance) to a Biden or Fauci in such disparaging terms. You may want to revisit your criteria for publication and also for membership on your editorial board.

Reply



Marvin Salgado Pérez

Posted January 20, 2023, 10:18 pm

ESPERO LA OCASIÓN EN QUE MI PAÍS NICARAGUA SEA INGRESADA AL CONSEJO EDITORIAL DE SNI.

Reply

## Leave a Reply

Your email address will not be published. Required fields are marked \*

Comments:\*

Express your thoughts, idea or write a feedback by clicking here & start an awesome comment

Your Name\*

Your Name (No Keywords)

Your Email\*

your-real-email@example.com

**Website**

http://your-site-name.com

Save my name, email, and website in this browser for the next time I comment.

Notify me of new posts by email.

SUBMIT COMMENT

**Join now!**

There is no charge to read or download any SNI content, but registering for a free membership will provide you with additional special features. Learn more by subscribing now.

**SUBSCRIBE NOW**

[Home](#)

[About](#)

[Submit an Article](#)

[Contact SNI](#)

[Editorial Board](#)

[Advertisement Opportunities](#)

[Privacy Policy](#)

[Terms of Use](#)

[Disclaimer](#)

[Cookie Policy](#)

[Site Map](#)

Sign up for our newsletters!

**SUBSCRIBE**



© Copyright Surgical Neurology International. All rights reserved.



## Case Report

# Deadly complication of sacrificing superior petrosal vein during cerebellopontine angle tumor resection: A case report and literature review

Irwan Barlian Immadoel Haq, Andhika Tomy Permana, Rahadian Indarto Susilo, Joni Wahyuhadi

Department of Neurosurgery, Faculty of Medicine Universitas Airlangga - Dr. Soetomo General Academic Hospital, Surabaya, East Java, Indonesia.

E-mail: Irwan Barlian Immadoel Haq - immadoelhaq@gmail.com; Andhika Tomy Permana - andhika\_2010@yahoo.com; Rahadian Indarto Susilo - rahadian-i-s@fk.unair.ac.id, \*Joni Wahyuhadi - joniwahyuhadi@fk.unair.ac.id



### \*Corresponding author:

Joni Wahyuhadi,  
Department of Neurosurgery,  
Faculty of Medicine Universitas  
Airlangga - Dr. Soetomo  
General Academic Hospital,  
Surabaya, East Java, Indonesia.

[joniwahyuhadi@fk.unair.ac.id](mailto:joniwahyuhadi@fk.unair.ac.id)

Received : 25 December 2020

Accepted : 01 April 2021

Published : 28 June 2021

### DOI

10.25259/SNI\_948\_2020

### Quick Response Code:



## ABSTRACT

**Background:** Tumors of the cerebellopontine angle (CPA) are challenging to resect and have been proven difficult for neurosurgeons to manage optimally. Superior petrosal vein complex (SPVC) as the main drainage system and close proximity to CPA could be an obstacle during operation. There is an incidence ranging from 55% to 84% of injury to one part of the SPVC during CPA tumor surgery.

**Case Description:** We report a case of 65-year-old woman with CPA tumor, who complained of unilateral hearing loss, dizziness, and facial pain. During tumor resection, one part of SPV complex was injured, then cerebellar edema develops.

**Conclusion:** This case provides an overview of surgical complication associated with venous sacrifice. This would support the agreement to preserve SPV regarding risks and improve the quality of surgical decision making.

**Keywords:** Cerebellopontine angle, Meningioma, Sacrifice, Superior petrosal vein, Tumor resection

## INTRODUCTION

Meningiomas account for 26% of primary intracranial neoplasms. Among intracranial meningiomas, 5–10% are located in the cerebellopontine angle (CPA).<sup>[9]</sup> Meningiomas represent the second most common type of neoplasm of CPA<sup>[5,9,12]</sup> with a prevalence of 3–13% of all CPA lesions.<sup>[5]</sup> CPA meningiomas account for 1.5% of intracranial meningiomas and dominated (58.3%) in a series of meningiomas of the posterior skull base.<sup>[12]</sup>

CPA often enabling complete surgical removal. However, complete removal can carry potential risks that may be significant, especially when the tumor has invaded brain tissue or surrounding veins.<sup>[5]</sup> Superior petrosal veins (SPVs) are often obstacles during surgery in the upper CPA.<sup>[16]</sup> SPV complex (SPVC) is a major draining system in the posterior fossa and a consistent landmark within the CPA.<sup>[17]</sup>

Attention has been paid to SPVs during surgeries for tumor in the upper CPA, and the number of reports on associated complications, especially during meningioma surgeries, has recently increased.<sup>[16]</sup> Injury of a part of the SPVC has been frequently reported in large case series, with an incidence ranging from 55% to 84% of cases.<sup>[4]</sup>

This is an open-access article distributed under the terms of the Creative Commons Attribution-Non Commercial-Share Alike 4.0 License, which allows others to remix, tweak, and build upon the work non-commercially, as long as the author is credited and the new creations are licensed under the identical terms.

©2021 Published by Scientific Scholar on behalf of Surgical Neurology International

Subsequently, sacrifice of veins is common practice to gain surgical exposure.<sup>[2]</sup> The safety of SPV sacrifice is a challenging question.<sup>[20]</sup> Yet, current literature indicates that complications following venous sacrifice are underreported. Hence, surgical literature on safety and complications of venous sacrifice in the posterior fossa remains contradictory.<sup>[2]</sup> In this manuscript, we report a case of the complication of SPV sacrifice during CPA tumor resection.

## ILLUSTRATIVE CASE

### History and examination

A 65-year-old woman was referred from the previous hospital with some symptoms of a CPA tumor. She reported a history of pain on her cheeks and lower jaw. She also complained about left ear hearing loss and dizziness. These symptoms have appeared for 6 months and are getting worse. Neurological examination revealed cranial nerve V, VII, and VIII abnormalities. The patient had already been informed and consent regarding the publication of her data.

### Radiological findings

Magnetic resonance imaging without contrast was performed at previous hospital and showed a lesion at left CPA [Figure 1]. Diagnosis of petrotentorial tumor has been confirmed. Due to economic issue, radiologic examination with contrast agent was not conducted. Preoperative venography did not perform on CPA tumor according to hospital policy.

### Operation and postoperative reports

Surgery was initiated with park-bench position, retrosigmoid craniotomy, and exploration of the CPA. It appears that the cerebellum relaxes and the left cerebellopontine exposes after the cisterna magna was opened and cerebrospinal fluid was released.

Arachnoid detachment was performed to separate the tumor from the cerebellar tissue. During surgical debulking

of tumor, the left SPV attached to the tumor was cut off. Coagulation technique with bipolar cautery to stop bleeding was given immediately. The surgeon noticed progressive cerebellar swelling and the CPA becomes inaccessible a 15 min later. Cerebellar tissue begins to swell and extends beyond the border of the craniotomy. In consequence, the craniotomy was widened so that we could remove the rest of tumor. Bone flap was not put back in place. Dural graft was chosen to be placed over the cerebellar tissue followed by closure of the muscle, fascia, and skin.

The patient was transferred in radiology for an emergency computed tomography (CT) scan and the results showed left cerebellar edema and hemorrhage with concomitant developing hydrocephalus [Figure 2].

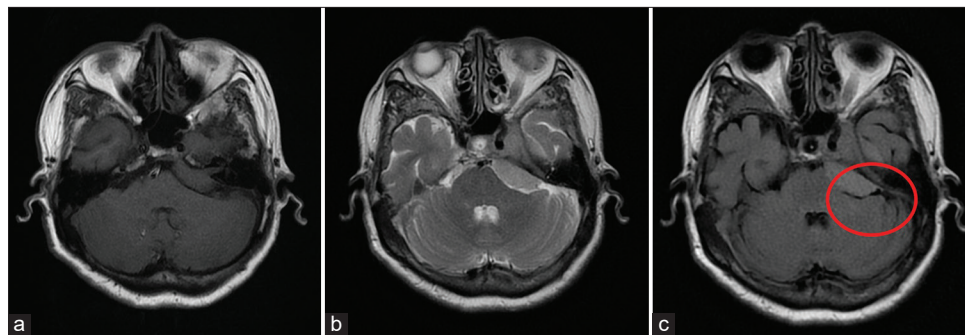
The patient was transferred back to the operating room and the Kocher's point for the right external ventricular drainage was positioned. The patient was then transferred to the intensive care unit and remained sedated for 24 h. Another head CT scan was performed and showed an advancement of hemorrhage [Figure 3].

When sedation is stopped, the pupils are small and unreactive. The patient does not respond to pain, verbal, and eye stimulation. Glasgow Coma Scale is 3. No corneal reflex. The patient died 24 h later.

## DISCUSSION

### Anatomical perspective of SPV

The venous drainage of the SPV has many variations. These veins are among the largest and the most frequent veins in the posterior fossa. The SPVs drain the anterior and lateral surfaces of the brainstem, the petrosal surface, and some lateral parts of the tentorial and suboccipital surfaces.<sup>[11]</sup> Tanriover *et al.* group updated the classification as Type 1, Type 2, and Type 3 based on relationship of its site of entry into the SPS, Meckel cave, and the internal acoustic meatus (IAM) [Figure 4].<sup>[4,20,27]</sup> In Type 1, the SPV complex empties



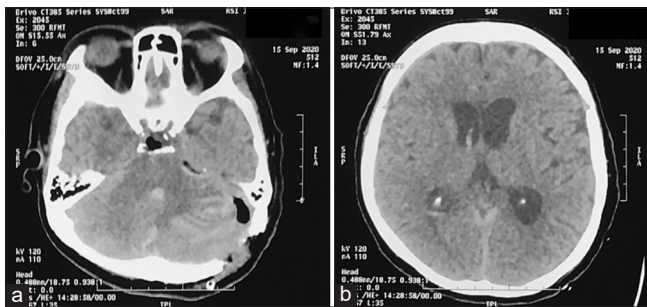
**Figure 1:** MR without contrast imaging of axial shows hypointense on T1 (a) and hyperintense in T2 (b) revealed extra-axial lesion in the left cerebellopontine angle. Flow void appearance on T2 flair (c) refers to the left superior petrosal vein attached to the lesion.

in to the superior petrosal sinus (SPS) or lateral to the IAM. In Type 2, SPV complex empties into the SPS between the lateral limit of the trigeminal nerve and the medial limit of facial nerve. In Type 3, the SPV complex empties into the SPS at a point medial to the lateral limit of trigeminal nerve.<sup>[20]</sup>

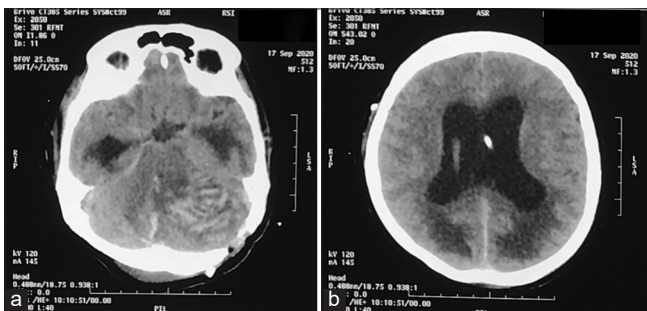
After SPV obliteration, compensatory venous blood drainage seems to occur through anastomotic pathways directed to the ipsilateral supratentorial deep veins. Anastomoses to the contralateral petrosal vein system do not suffice to install an adequate outflow.<sup>[11]</sup>

**Clinical implication of SPV occlusion**

CPA has always proven difficult for neurosurgeons to optimally manage,<sup>[1]</sup> also challenging to resect because of their complex



**Figure 2:** CT imaging early postoperative shows cerebellar edema and hemorrhagic on cerebellum (a) and hydrocephalus (b).



**Figure 3:** CT imaging 2 days postoperative shows increase of cerebellar edema and hemorrhagic on cerebellum (a) and hydrocephalus with extraventricular drainage device placement (b).

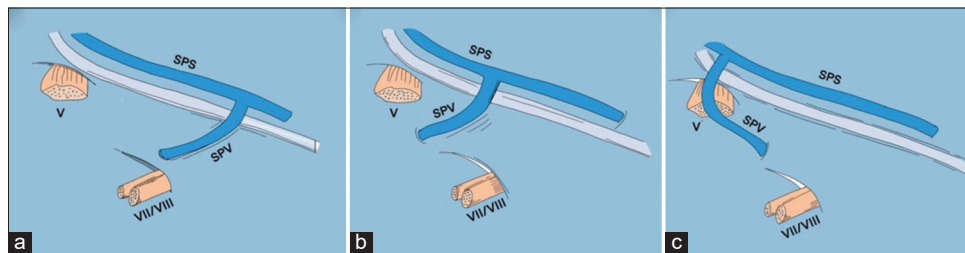
regional anatomy, the deep and narrow surgical corridors involved, and the abundance of vital neurovascular structures in the surgical field.<sup>[25]</sup> The posterior fossa venous anatomy is often not well visualized during surgery. This is particularly true regarding the SPVC. The SPV also has variable anatomy as it may be the terminal segment of one single vein or may form as the common union of multiple veins.<sup>[15]</sup>

Coagulation and dissection of the SPV do not frequently cause adverse sequelae. Several large series study of sacrificing SPV in petrous tumor showed negligible complication, in a study of 55 patients with petrous meningioma surgery, the SPV was sacrificed in 49% of the case and only 3 patients had hearing loss complication, compared with other group which SPV was preserved, 3 patients also had hearing loss complication ( $P > 0.05$ ).<sup>[10]</sup> Another study conducted in 12 patients which all of the patient’s SPV were sectioned, no mortality was found and all of the patient had good performance after the surgery.<sup>[24]</sup>

Another study conducted in sacrificing SPV showed the benefit of venography before surgery to identify SPV type and its tributary, helping surgeon decision to preserve or to sacrifice the SPV. This study described no venous complication for all patient who underwent surgery with sacrificing or preserving SPV with 1 patient as SPV Type 1, 2 patients as SPV Type 2 and 4 patients as SPV Type 3 in sacrificed group, and 17 patients as SPV Type 2 and 1 patient as SPV Type 3.<sup>[19]</sup>

Larger study supporting the safety of sacrificing SPV was conducted in microvascular decompression (MVD) procedure for trigeminal neuralgia (TN). A study in 4400 patients underwent MVD procedure for TN showed that SPV is safe to be sectioned without causing major morbidity or mortality.<sup>[18]</sup> Another study with fewer case also reported that sacrificing SPV causes only <0.5% of venous infarction and not causing direct morbidity to the patient.<sup>[7]</sup>

In the opposite hand, several studies reported some devastating effect due to sacrificing of SPV [Table 1].<sup>[3,10,13–15,19,21–23,28,29]</sup> The complication was reported occurred in up to 31% of the case. Recent study on a substantial number of patients with petrous apex meningiomas has revealed minor venous congestion phenomena in 23% and major complications in almost 7% of



**Figure 4:** Type of SPV drainage into the SPS according to Tanriover *et al.*<sup>[27]</sup> Type I drainage of the SPV into the SPS (a). Type II drainage (b). Type III drainage (c). SPS: Superior petrosal sinus, SPV: Superior petrosal vein, V: Fifth cranial nerve, VII/VIII: Seventh and eighth cranial nerves.<sup>[4]</sup>

**Table 1:** Study showing complication of sacrificing SPV and preserving SPV.

Author and year	Total patients	Sample's diagnosis	Complication	Imaging evaluation	Study result
Xia et al. (2020) <sup>[29]</sup>	592	TN	No venous complication	No edema, no hydrocephalus, and no hemorrhage	No venous complication was shown in SPV sacrificed group Venous complication was shown on 1.1% of patients in SPV preserved group
Watanabe et al. (2013) <sup>[28]</sup>	43	Petrous Apex Meningioma	Elevated ICP	Venous infarction of cerebellum Cerebellar edema	SPV preservation showed no complication ( $n=24$ ) Sacrificing SPV cause major and minor morbidity in 31% of patients ( $n=14$ ) ( $P<0.05$ )
Gharabaghi et al. (2006) <sup>[10]</sup>	55	Petrous Apex Meningioma	Hearing loss	No edema, no hydrocephalus, and no hemorrhage	Sacrificing SPV ( $n=27$ ) and preserving SPV ( $n=26$ ) showed no significance different in causing complication ( $P>0.05$ )
Koerbel et al. (2009) <sup>[14]</sup>	59	Petrous Apex Meningioma	Elevated ICP	Ventriculomegaly Cerebellar edema Venous infarction	SPV preservation showed no complication ( $n=27$ ) Sacrificing SPV cause major and minor morbidity in 30% of patients ( $n=30$ ) ( $P<0.05$ )
Kaku et al. (2012) <sup>[13]</sup>	5	Petroclival Meningioma	Facial numbness	NA	Minor complication occurred in 1 patient which SPV was sacrificed and no complication was noted in 4 other patients which SPV was preserved
Mizutani et al. (2016) <sup>[19]</sup>	28	Petroclival Meningioma	No venous complication	NA	No venous complication was observed in sacrificed ( $n=7$ ) and preserved ( $n=18$ ) SPV group
Perrini et al. (2017) <sup>[22]</sup>	1	Petrous Apex Meningioma	Elevated ICP	Obstructive hydrocephalus Cerebellar venous infarction	Patient was unconscious after surgery with elevated ICP, hydrocephalus, and cerebellar venous infarction. Patient died 13 days after surgery
Ryu et al. (1999) <sup>[23]</sup>	132	TN	Elevated ICP	Bleeding cerebellar infarction	Only 1 patient had complication after SPV sacrifice (0.01%), where overall mortality was 0.8%
Liebelt et al. (2017) <sup>[15]</sup>	98	TN	Elevated ICP Hemiparesis Slurred speech Facial palsy	Cerebellar and brainstem infarction with edema	SPV preservation resulting no complication and all patients with SPV sacrifice have venous complication ( $P<0.05$ )
Pathmanaban et al. (2017) <sup>[21]</sup>	224	TN	Elevated ICP Cerebellar syndrome	Sinus thrombosis	Only 2.7% of patients had sinus thrombosis and no venous infarction was identified in all patients who had SPV sacrifice in surgery ( $n=184$ )
Anichini et al. (2016) <sup>[3]</sup>	1	TN	Elevated ICP Comma	Obstructive Hydrocephalus Cerebellar Infarction	Complication occurred on second surgery when SPV was sacrificed

SPV: Superior petrosal veins, ICP: Intracranial pressure, TN: Trigeminal neuralgia

cases after intraoperative obliteration of the SPV.<sup>[28]</sup> Another study in petrous apex meningioma, the patient also showed significance difference in complication resulted by sacrificing SPV compared to preserving it with the complication rate reach 30% of the cases.<sup>[14]</sup>

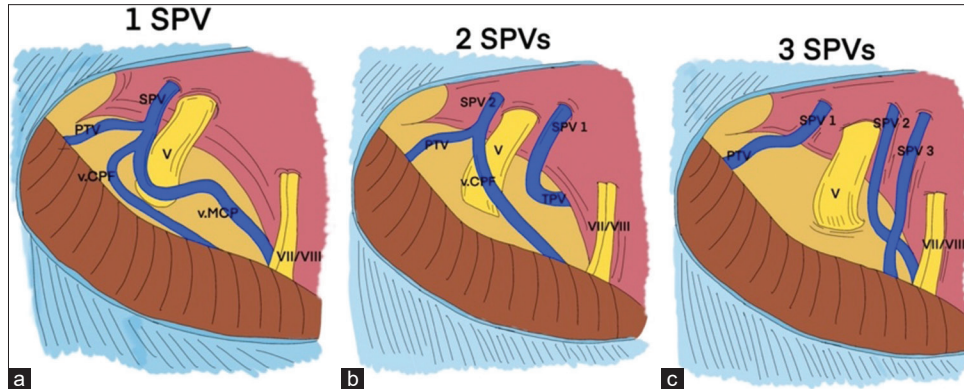
In general, one out of several tributaries of the SPV or tentorial veins was considered safe to occlude, although most surgeon considered certain risks of infarction and edema with any venous occlusion [Figure 5]. In contrast, mortality was considered to exceed 10% with sacrifice of the specific structure such as the SPV main trunk, one of the sigmoid sinuses, and extensive tentorial bridging venous drainage.<sup>[2]</sup>

Sacrifice of veins rarely leads to complications (1.6% on average, according to reports). Nevertheless, some

may be severe and even life threatening and necessitate emergency management.<sup>[6]</sup> The complications reported in the previous study include contralateral hearing loss, transient postoperative cochlear nerve deficit, cerebellar and brainstem edema, cerebellar venous infarction, peduncular hallucinosis, cerebellar hemorrhage, brainstem hemorrhage, and hydrocephalus, leading in some cases to coma and death.<sup>[11]</sup> Alaoui-Ismaïli *et al.* findings supported the notion that routine venous sacrifice for surgical access may carry a risk of serious complications and death.<sup>[2]</sup> Some patients died from unexpected major complications such as extensive cerebellar swelling and hemorrhagic infarction.<sup>[16]</sup>

Neurosurgeons commonly sacrifice SPV to widen the operative exposure at the apex.<sup>[2]</sup> It was proven that sacrifice





**Figure 5:** The three main patterns of an SPVC. (a) An SPVC with single SPV, (b) an SPVC with 2 SPVs, (c) an SPVC with 3 SPVs. ALMv: Anterior lateral marginal vein, PTV: Pontotrigeminal vein, SPS: Superior petrosal sinus, SPV: Superior petrosal vein, SPVC: Superior petrosal vein complex, SPV1: First superior petrosal vein, SPV2: Second superior petrosal vein, SPV3: Third superior petrosal vein, TPV: Transverse pontine vein, v.CPF: Vein of cerebellopontine fissure, v.MCP: Vein of the middle cerebellar peduncle, V: Trigeminal nerve, VII/VIII: Seventh and eighth cranial nerves.<sup>[4]</sup>

of even only 1 branch of the SPV may induce venous congestion, so the individual variations of the venous system necessitate a careful tailored attitude.<sup>[6]</sup> As was the case with our patient, in the absence of adequate data on SPV radiologically or intraoperatively in this patient, sacrifice SPV in our patient resulted in fatal cerebellar congestion.

Effort should be made to avoid the complication of sectioned SPV. Although not always possible, radiological study of venous anatomical variation through venography in each patient could tell the surgeon whether it is safe or not to sacrifice the SPV and its tributaries.<sup>[30]</sup> In general, what is assessed on CTV in patients with CPA tumors is the patency and extent of SPV visualization. In cases where the SPV cannot be visualized by the CTV (SPV Type 4), the petrosal vein only drains the vascularization from the tumor itself, meaning that the vein may be safely sacrificed after the devascularization of the tumor.<sup>[19]</sup>

Another way of assessing the safety of SPV sacrifice can also be done intraoperatively with temporary clamping of SPV. Assessment can be made in plain view to assess the edema, but a more objective report by monitoring the auditory potential of the brain stem has been reported.<sup>[26,30]</sup> In addition, another study reported reports of collateral venous drainage in transient vein clamping with indocyanine green video angiography.<sup>[8]</sup>

Surgical technique with combined petrosal approach, SPV preservation, and dural incision approach described in previous report could be used to increase the probability to preserve SPV.<sup>[11]</sup> A good extension of arachnoid dissection also could provide easier maneuvering and mobilization to get good exposure to the operation target. In case which SPV has to be sacrificed, the main trunk and its big tributary

should be avoided to prevent venous complication. The diameter of the SPV which will be sacrificed should also be considered since the previous study described that SPV with diameter <2 mm was safe to be sacrificed.<sup>[20]</sup>

Similarly, the use of fully endoscopic and endoscope-assisted microsurgery with and without angled optics may minimize the extent of venous sacrifice required to obtain optimum visualization. The risk of inadvertent injury to a preserved SPV with resultant bleeding into the CPA seems unlikely to be improved with this approach however and may be worse due to loss of vision for structures superficial to the tip of the endoscope. Furthermore, management of such bleeding in the CPA may be problematic with an endoscope, where a clear view of the field can be lost. Subsequently, although the problem is often not discussed in the endoscopic literature, some authors describe sacrifice of the SPV when it is encountered to improve endoscopic exposure as with the microscopic technique.<sup>[21]</sup>

## CONCLUSION

The surgeon must fully understand the essential anatomical knowledge of the veins to assess surgical risk and assess feasibility of venous sacrifice. The decision not to sacrifice SPV should be made during CPA tumor resection or other intracanal case surgery because of the potentially lethal complication. According to this case, there are several options that could be made, that is, preservation of the veins, temporary vein clamping followed by intraoperative evaluation, preoperative venography to consider the safety of sacrificing SPV complex, and avoiding long and continuous retraction of cerebellum.

## Declaration of patient consent

Patient's consent not required as patients identity is not disclosed or compromised.

## Financial support and sponsorship

Nil.

## Conflicts of interest

There are no conflicts of interest.

## REFERENCES

- Agarwal V, Babu R, Grier J, Adogwa O, Back A, Friedman AH, *et al.* Cerebellopontine angle meningiomas: Postoperative outcomes in a modern cohort. *Neurosurg Focus* 2013;35:E10.
- Alaoui-Ismaili A, Krogager ME, Jakola AS, Poulsgaard L, Couldwell W, Mathiesen T. Surgeons' experience of venous risk with CPA surgery. *Neurosurg Rev* 2020;2020:01365-5.
- Anichini G, Iqbal M, Rafiq NM, Ironside JW, Kamel M. Sacrificing the superior petrosal vein during microvascular decompression. Is it safe? Learning the hard way. Case report and review of literature. *Surg Neurol Int* 2016;7:S415-20.
- Basamh M, Sinning N, Kehler U. Individual variations of the superior petrosal vein complex and their microsurgical relevance in 50 cases of trigeminal microvascular decompression. *Acta Neurochir (Wien)* 2020;162:197-209.
- Belachew A, Chowdhury T, Spiriev T, Sandu N, Schaller B. Classification of Meningiomas. *Springer Sci Media* 2015;14:43-53.
- Dumot C, Sindou M. Veins of the cerebellopontine angle and specific complications of sacrifice, with special emphasis on microvascular decompression surgery. A review. *World Neurosurg* 2018;117:422-32.
- Elhammady MS, Heros RC. Cerebral veins: To sacrifice or not to sacrifice, that is the question. *World Neurosurg* 2015;83:320-4.
- Ferrolli P, Nakaji P, Acerbi F, Albanese E, Broggi G. Indocyanine green (ICG) temporary clipping test to assess collateral circulation before venous sacrifice. *World Neurosurg* 2011;75:122-5.
- Gao K, Ma H, Cui Y, Chen X, Ma J, Dai J. Meningiomas of the cerebellopontine angle: Radiological differences in tumors with internal auditory canal involvement and their influence on surgical outcome. *PLoS One* 2015;10:e0122949.
- Gharabaghi A, Koerbel A, Löwenheim H, Kaminsky J, Samii M, Tatagiba M. The impact of petrosal vein preservation on postoperative auditory function in surgery of petrous apex meningiomas. *Neurosurgery* 2006;59:ONS68-74.
- Haq IB, Susilo RI, Goto T, Ohata K. Dural incision in the petrosal approach with preservation of the superior petrosal vein. *J Neurosurg* 2016;124:1074-8.
- He X, Liu W, Wang Y, Zhang J, Liang B, Huang JH. Surgical management and outcome experience of 53 cerebellopontine angle meningiomas. *Cureus* 2017;9:e1538.
- Kaku S, Miyahara K, Fujitsu K, Hataoka S, Tanino S, Okada T, *et al.* Drainage pathway of the superior petrosal vein evaluated by CT venography in petroclival meningioma surgery. *J Neurol Surg B Skull Base* 2012;73:316-20.
- Koerbel A, Gharabaghi A, Safavi-Abbasi S, Samii A, Ebner FH, Samii M, *et al.* Venous complications following petrosal vein sectioning in surgery of petrous apex meningiomas. *Eur J Surg Oncol* 2009;35:773-9.
- Liebelt BD, Barber SM, Desai VR, Harper R, Zhang J, Parrish R, *et al.* Superior Petrosal vein sacrifice during microvascular decompression: Perioperative complication rates and comparison with venous preservation. *World Neurosurg* 2017;104:788-94.
- Matsushima T, Kawashima M, Inoue K, Matsushima K. Anatomy of the superior petrosal veins and their exposure and management during petrous apex meningioma surgery using the lateral suboccipital retrosigmoid approach. *Neurosurg Rev* 2014;37:535-456.
- Matsushima T, Rhoton AL Jr, de Oliveira E, Peace D. Microsurgical anatomy of the veins of the posterior fossa. *J Neurosurg* 1983;59:63-105.
- McLaughlin MR, Jannetta PJ, Clyde BL, Subach BR, Comey CH, Resnick DK. Microvascular decompression of cranial nerves: Lessons learned after 4400 operations. *J Neurosurg* 1999;90:1-8.
- Mizutani K, Toda M, Yoshida K. The Analysis of the petrosal vein to prevent venous complications during the anterior transpetrosal approach in the resection of petroclival meningioma. *World Neurosurg* 2016;93:175-82.
- Narayan V, Savardekar AR, Patra DP, Mohammed N, Thakur JD, Riaz M, *et al.* Safety profile of superior petrosal vein (the vein of Dandy) sacrifice in neurosurgical procedures: A systematic review. *Neurosurg Focus* 2018;45:E3.
- Pathmanaban ON, O'Brien F, Al-Tamimi YZ, Hammerbeck-Ward CL, Rutherford SA, King AT. Safety of superior petrosal vein sacrifice during microvascular decompression of the trigeminal nerve. *World Neurosurg* 2017;103:84-7.
- Perrini P, Di Russo P, Benedetto N. Fatal cerebellar infarction after sacrifice of the superior petrosal vein during surgery for petrosal apex meningioma. *J Clin Neurosci* 2017;35:144-5.
- Ryu H, Yamamoto S, Sugiyama K, Yokota N, Tanaka T. Neurovascular decompression for trigeminal neuralgia in elderly patients. *Neurol Med Chir (Tokyo)* 1999;39:226-9.
- Samii M, Tatagiba M, Carvalho GA. Retrosigmoid intradural suprameatal approach to Meckel's cave and the middle fossa: Surgical technique and outcome. *J Neurosurg* 2000;92:235-41.
- Spena G, Sorrentino T, Altieri R, Zinis LR, Stefini R, Panciani PP, *et al.* Early-career surgical practice for cerebellopontine angle tumors in the era of radiosurgery. *J Neurol Surg B Skull Base* 2018;79:269-81.
- Strauss C, Neu M, Bischoff B, Romstöck J. Clinical and neurophysiological observations after superior petrosal vein obstruction during surgery of the cerebellopontine angle: Case report. *Neurosurgery* 2001;48:1157-9; discussion 1159-61.
- Tanriover N, Abe H, Rhoton AL Jr, Kawashima M, Sanus GZ, Akar Z. Microsurgical anatomy of the superior petrosal venous complex: New classifications and implications for subtemporal transtentorial and retrosigmoid suprameatal approaches. *J Neurosurg* 2007;106:1041-50.
- Watanabe T, Igarashi T, Fukushima T, Yoshino A, Katayama Y. Anatomical variation of superior petrosal vein and its

- management during surgery for cerebellopontine angle meningiomas. *Acta Neurochir (Wien)* 2013;155:1871-8.
29. Xia Y, Kim TY, Mashouf LA, Patel KK, Xu R, Casaos J, *et al.* Absence of ischemic injury after sacrificing the superior petrosal vein during microvascular decompression. *Oper Neurosurg (Hagerstown)* 2020;18:316-20.
30. Zhong J, Li ST, Xu SQ, Wan L, Wang X. Management of

petrosal veins during microvascular decompression for trigeminal neuralgia. *Neurol Res* 2008;30:697-700.

**How to cite this article:** Haq IB, Permana AT, Susilo RI, Wahyuhadi J. Deadly complication of sacrificing superior petrosal vein during cerebellopontine angle tumor resection: A case report and literature review. *Surg Neurol Int* 2021;12:306.