

# 18. Lifesaving Decompressive Craniectomy for High Intracranial Pressure

*by* Irwan Barlian Immadoel Haq

---

**Submission date:** 06-Jul-2022 01:26PM (UTC+0800)

**Submission ID:** 1867193249

**File name:** ing\_Decompressive\_Craniectomy\_for\_High\_Intracranial\_Pressure.pdf (1.6M)

**Word count:** 4744

**Character count:** 26044

## Lifesaving Decompressive Craniectomy for High Intracranial Pressure Attributed to Deep-Seated Meningioma: Emergency Management

### Abstract

**Objects:** As the most common intracranial extra-axial tumor among adults who tend to grow slowly with minimal clinical manifestation, the patients with meningioma could also fall in neurological emergency and even life-threatening status due to high intracranial pressure (ICP). In those circumstances, decompressive craniectomy (DC) without definitive tumor resection might offer an alternative treatment to alleviate acute increasing of ICP. The current report defines criteria for the indications of lifesaving DC for high ICP caused by deep-seated meningioma as an emergency management. **Patients and Methods:** This study collected the candidates from 2012 to 2018 at Dr. Soetomo General Hospital, Surabaya, Indonesia. The sample included all meningioma patients who came to our ER who fulfilled the clinical (life-threatening decrease in Glasgow Coma Scale [GCS]) and radiography (deep-seated meningioma, midline shift in brain computed tomography [CT] >0.5 cm, and diameter of tumor >4 cm or tumor that involves the temporal lobe) criteria for emergency DC as a lifesaving procedure. GCS, midline shift, tumor diameter, and volume based on CT were evaluated before DC. Immediate postoperative GCS, time to tumor resection, and Glasgow Outcome Scale (GOS) were also assessed postoperation. **Results:** The study enrolled 14 patients, with an average preoperative GCS being  $9.29 \pm 1.38$ , whereas the mean midline shift was  $15.84 \pm 7.02$  mm. The average of number of tumor's diameter and volume was  $5.59 \pm 1.44$  cm and  $66.76 \pm 49.44$  cc, respectively. Postoperation, the average time interval between DC and definitive tumor resection surgery was  $5.07 \pm 3.12$  days. The average immediate of GCS postoperation was  $10.07 \pm 2.97$ , and the average GOS was  $3.93 \pm 1.27$ . **Conclusion:** When emergency tumor resection could not be performed due to some limitation, as in developing countries, DC without tumor resection possibly offers lifesaving procedure in order to alleviate acute increasing ICP before the definitive surgical procedure is carried out. DC might also prevent a higher risk of morbidity and postoperative complications caused by peritumoral brain edema.

**Keywords:** Decompressive craniectomy, lifesaving, meningioma, skull base surgery

### Introduction

Meningioma is the most common intracranial extra-axial tumor among adults, comprising around 20%–30% of all central nervous system tumors.<sup>[1,2]</sup> In majority of cases, meningioma tends to grow slowly with minimal clinical manifestation.<sup>[3]</sup> However, patients with meningioma in the emergency unit presenting neurological emergency status such as decreased consciousness are scarce. Raised intracranial pressure (ICP) secondary to large tumor size, extensive peritumoral brain edema (PTBE), hydrocephalus, and intratumoral bleeding are assumed as underlying factors for that emergency status making an immediate treatment as the utmost importance. Emergency

meningioma resection become the standard therapy though it is not always possible to do in developing countries, because there are only small number of 24-hour tumor resection facilities available making meningioma resection as not possible to be performed. Decompressive craniectomy (DC) is believed as the most primitive neurosurgical procedure, and until now, it has been widely used worldwide, especially for the treatment of severe traumatic brain injury and stroke.<sup>[4-9]</sup> In the last decades, not only for both of them, but DC is also performed in cases of severe intracranial infection, dural sinus thrombosis, and inflammation condition.<sup>[10]</sup> However, to the best of our knowledge,

This is an open access journal, and articles are distributed under the terms of the Creative Commons Attribution-NonCommercial-ShareAlike 4.0 License, which allows others to remix, tweak, and build upon the work non-commercially, as long as appropriate credit is given and the new creations are licensed under the identical terms.

For reprints contact: [WKHLRPMedknow\\_reprints@wolterskluwer.com](mailto:WKHLRPMedknow_reprints@wolterskluwer.com)

**How to cite this article:** Haq IB, Niantiarno FH, Arifianto MR, Nagm A, Susilo RI, Wahyuhadi J, et al. Lifesaving decompressive craniectomy for high intracranial pressure attributed to Deep-Seated meningioma: Emergency management. *Asian J Neurosurg* 0;0:0.

Submitted: 27-Apr-2020 Revised: 06-Jun-2020  
Accepted: 14-Aug-2020 Published: 23-Feb-2021

Irwan Barlian  
Immadoel Haq,  
Fajar Herbowo  
Niantiarno,  
Muhammad Reza  
Arifianto,  
Alhusain Nagm<sup>1,2</sup>,  
Rahadian Indarto  
Susilo,  
Joni Wahyuhadi,  
Takeo Goto<sup>1</sup>,  
Kenji Ohata<sup>1</sup>

Department of Neurosurgery, Faculty of Medicine, Universitas Airlangga – Dr. Soetomo General Hospital, Surabaya, Indonesia, <sup>1</sup>Department of Neurosurgery, Graduate School of Medicine, Osaka University, Osaka, Japan, <sup>2</sup>Department of Neurosurgery, Faculty of Medicine, Al-Azhar University, Nasr City, Cairo, Egypt

**Address for correspondence:**  
Dr. Joni Wahyuhadi,  
Department of Neurosurgery/  
Dr. Soetomo General Academic  
Hospital – Faculty of Medicine/  
Universitas Airlangga,  
Surabaya – Indonesia.  
E-mail: [joniwahyuhadi@fk.unair.ac.id](mailto:joniwahyuhadi@fk.unair.ac.id)

Access this article online

Website: [www.asianjns.org](http://www.asianjns.org)

DOI: 10.4103/ajns.AJNS\_179\_20

Quick Response Code:



21

there are no published studies discussing the efficacy of DC for a treatment of neurological emergency caused by meningioma. The index study proposes an algorithm regarding DC as a lifesaving procedure for neurological emergency secondary to meningioma, in which immediate tumor resection is not possible.

### Patients and Methods

This retrospective study included the sample from 2012 to 2018 at Dr. Soetomo General Hospital, Surabaya, Indonesia. Patients were selected retrospectively based on medical records. All meningioma patients who came to our emergency room (ER) with acute neurological emergency deficits fulfilled the criteria for emergency DC and did not respond after 4–6 h evaluation to aggressive medical therapy. We routinely followed our algorithm [Figure 1] before decided whether DC might give advantages for the patients or not. DC for meningioma was also decided based on findings from head computed tomography (CT) at the ER or previous brain magnetic resonance imaging (if available). Patients with any extracranial problem that might underlie the symptoms mimicking acute neurology deficits were excluded.

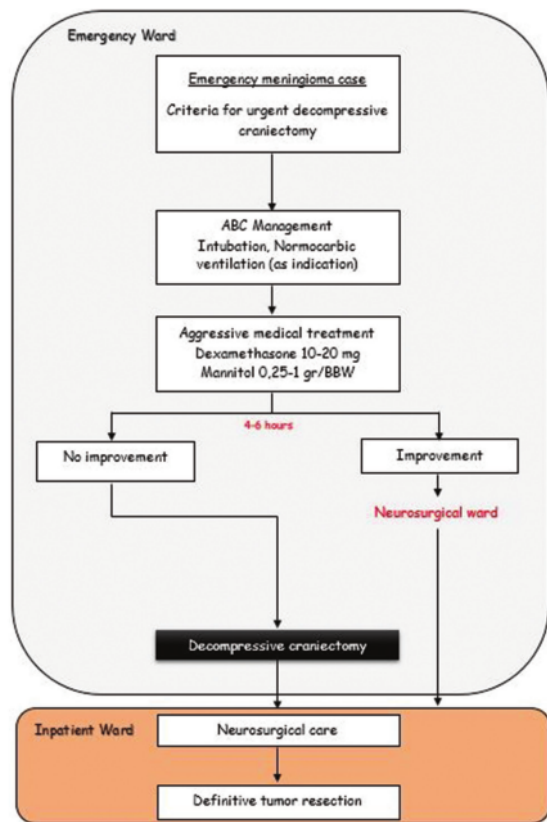


Figure 1: The algorithm of emergency meningioma that was eligible for decompressive craniectomy

2

### Criteria for urgent decompressive craniectomy for emergency meningioma case

Before deciding whether the patient was necessary to have an emergency DC, we selected the patient using our routine proposed criteria that indicate high ICP in deep-seated meningioma. The selected patient must fulfill all the following criteria:

#### Clinical manifestation

The patient who exhibit acute neurological deterioration and life-threatening decrease in Glasgow Coma Scale (GCS).

#### Radiography criteria

1. Deep-seated meningioma
2. Significant midline shift in brain CT scan (more than 0.5 cm)
3. The tumor mass is assumed as the main cause of acute neurological deterioration. Strong indication: tumor size maximum diameter >4 cm or tumors that involve or compress the temporal lobe.

Deterioration of GCS is a warning sign that indicates a neurological disorder, in which urgent treatment is often needed. We defined deep-seated meningioma as a meningioma where the primary attachment originally at the skull base radiographically.

After selecting the eligible patients based on our criteria, we initially started with general treatments of raised ICP (airway, breathing, and circulation [ABC] management, normocarbic ventilation, head elevation, and aggressive dehydrating measures using mannitol and dexamethasone). At the end, when all of the initial treatments did not give improvement, we performed DC as a lifesaving procedure.

#### Airway, breathing, and circulation management, normocarbic ventilation, and head up

The assessment and management of the ABCs are the beginning point. Early endotracheal intubation should be considered for those patients with GCS <8, evidence of brain herniation, and apnea or has the inability to secure their airways. Intubation should be proceeded with administration of medications to control the ICP during the procedure. Proper oxygenation should be ascertained. The PaCO<sub>2</sub> is maintained to the range of 30–35 mmHg. If there is evidence of circulatory failure, fluid bolus should be given. Mild head elevation of 15°–30° is mandatory for every patient who is suspected of having high ICP in order to encourage jugular venous drainage (provided if there are no contraindications).

#### Aggressive dehydrating measures

In emergency settings due to acute neurological deterioration secondary to high ICP that is attributed to peritumoral edema, aggressive medical treatment using the combination of corticosteroid (dexamethasone) and osmotherapy agent (mannitol) is widely used to alleviate



the ICP. Typically, at initial presentation, large doses of 10–20 mg of dexamethasone and 0.25–1 g per body weight of intravenous mannitol 20% are given simultaneously. The evaluation was assessed in 4–6 h after administration (as both dexamethasone and mannitol are assumed to reach optimum doses at that point) to show their effect.

#### Evaluation (improvement vs. no improvement)

After 4–6 h of aggressive medical treatment, the re-evaluation of all criteria was conducted. At this point, neurosurgeons will evaluate clinical findings merely from physical examination. If the signs and symptoms of acute neurological deterioration are diminished, the initial management is successful and categorized as “improvement.” It means that the patient will be monitored closely in neurosurgical care to prepare well-planned tumor resection surgery in a nonemergency setting. For evaluating the level of consciousness, we are using GCS. Any improvement of GCS scores more than 2 means the significant improvement.

#### Decompressive craniectomy

DC defines the temporary removal of a portion of the skull for reducing high ICP. It can be achieved by removal of the cranial bone over one or both sides. Part of cranial bone that will be removed depends on where the meningioma is located. Following DC, the dura was incised in order to gain maximum effect in reducing the ICP and continued with the addition of expansive duraplasty using autologous periosteum graft. The preoperative planning of definitive tumor resection was also another factor to be considered for making decision of DC procedure. The removed bone flap was stored in a sub-zero degree Celsius (–20°C) temperature freezer in our hospital tissue and bone bank for anticipation of the subsequent cranioplasty. ICP evaluation was clinically relying on the tension of decompressive site whether it was bulging or not.

#### Neurosurgical care and definitive tumor resection

After DC, the patient will begin the recovery process in intensive care unit that will be cared for with a team of doctors and nurses who are specially trained in neurology and critical care. The patients were allowed to transfer into low care unit when the doctor declared that the patients no longer need ventilation. In that period, PTBE was expected to resolve. Moreover, waiting for the availability of facilities also can prolong this period. Definitive tumor resection was performed after patient’s general condition in optimum state. It variably between each patient with the shortest interval was 1 day and the longest interval was 10 days. In that period, PTBE was expected to resolve. Moreover, waiting the availability of facilities also can prolong this period.

#### Results

The study enrolled 14 female participants with a mean age of 45.7 ± 7.62 years who suffered consciousness decreases due to meningioma.

GCS, location, midline shift, tumor diameter, and volume based on CT were assessed before DC [Table 1]. The mean preoperative GCS was 9.29 ± 1.38, with the tumor attachment at sphenoid amounted to 5 (35.7%), clinoid 3 (21.4%), tuberculum sellae (21.4%), olfactory groove 2 (14.2%), and petrous 1 (7.14%) participant. The mean midline shift was 15.84 ± 7.02 mm, whereas tumor’s diameter and volume mean were 5.59 ± 1.44 cm and 66.76 ± 49.44 cc, respectively. After DC, immediate postoperative GCS, time interval to tumor resection, and Glasgow Outcome Scale (GOS) were also assessed. The mean time interval between DC and definitive tumor resection surgery was at average of 5.07 ± 3.12 days. The mean immediate postoperative GCS was 10.07 ± 2.97, and the average of GOS was 3.93 ± 1.27.

Among those 14 patients, 10 patients underwent fronto-temporo-parietal decompression DC and 4 patients had bifrontal DC [Table 2].

#### Illustrative cases

##### Case illustration 1: Meningioma of tuberculum sellae

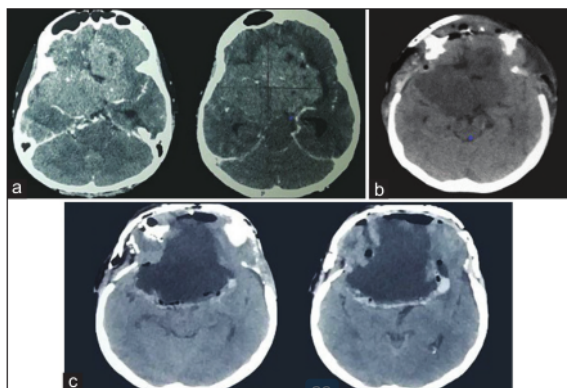
A 44-year-old woman came to the emergency unit with a primary complaint of consciousness decrease. Initial GCS was 8/15 without signs of lateralization. Noncontrast head CT scan [Figure 2] revealed hyperdense mass at the midline expanding to both sides. The hyperdense mass is suspected to be tuberculum sellae meningioma. Signs of increasing ICP were also evident from the CT. Bifrontal DC was

**Table 1: Clinical characteristic of patients in this study**

Decompressive craniectomy	Result (n=14)
Sample number (n)	14
Sex (female:male)	14:0
Age (years old), mean±SD	45.71±7.62
Tumor location, n (%)	
Olfactory groove	2 (14.2)
Sphenoid	5 (35.7)
Clinoid	3 (21.4)
Tuberculum sellae	3 (21.4)
Petrous apex	1 (7.14)
Preoperative, mean±SD	
GCS preoperative	9.29±1.38
Midline shift (mm)	15.84±7.02
Tumor diameter (cm)	5.59±1.44
Tumor volume (cc)	66.76±49.44
Postoperative	
Time interval until definitive surgery (days)	5.07±3.12
Immediate postoperative GCS	10.07±2.97
GOS, n (%)	3.93±1.27
Good recovery	7 (50)
Moderate disability	1 (7.14)
Severe disability	5 (35.7)
Dead	1 (7.14)

SD – Standard deviation; GCS – Glasgow Coma Scale; GOS – Glasgow Outcome Scale

then performed. Dramatical GCS improvement to 14/15 was seen at day 3 after DC. Four days after DC, definitive meningioma resection with osteoplasty was conducted. One day after the resection, GCS fully returned to 15/15.



**Figure 2:** Computed tomography scan of a 44-year-old female diagnosed with meningioma of tuberculum sellae suffering consciousness decrease. (a) Contrast computed tomography scan of the head showing hyperdense lesion which was homogeneously enhanced. The lesion occupying the anterior and middle cranial base was spreading bilaterally and obliterating the basal cistern which indicates severe brain edema. (b) A noncontrast head computed tomography, 3 days after bifrontal decompressive craniectomy, brain edema was released seen from the re-opening of the cistern. (c) Head computed tomography scan 3 weeks after tumor resection surgery and cranioplasty, there were no signs of intracranial pressure increase

**Case illustration 2: Medial right sphenoid meningioma**

A 43-year-old woman was brought to the emergency unit with a consciousness decreases for 10 days before admission. Initial GCS was 9/15. Head CT scan with contrast [Figure 3] revealed a solid homogeneous mass at medial right sphenoid suggestive of meningioma. The mass was surrounded with the hypodense area of perifocal edema. There were midline shift more than 5 mm and hydrocephalus. DC on the right side was performed and GCS was improved to 11/15 postoperatively. Tumor resection was performed 2 days after the emergency DC, and the patient's GCS returned to 15/15.

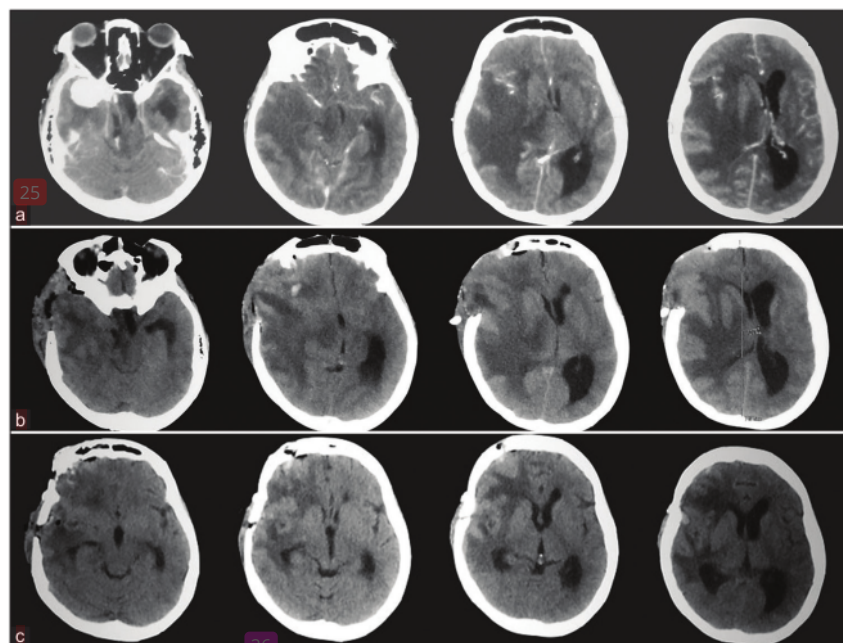
**Case illustration 3: Sphenoid wing meningioma**

A 44-year-old woman was brought to the emergency unit because of consciousness decreases 7 h before the admission. Initial examination revealed the GCS of 7/15, anisocoria of the pupil, and right hemiparesis. There was a history of a 4-month chronic headache for

**Table 2: Decompressive craniectomy classification that was performed in this study**

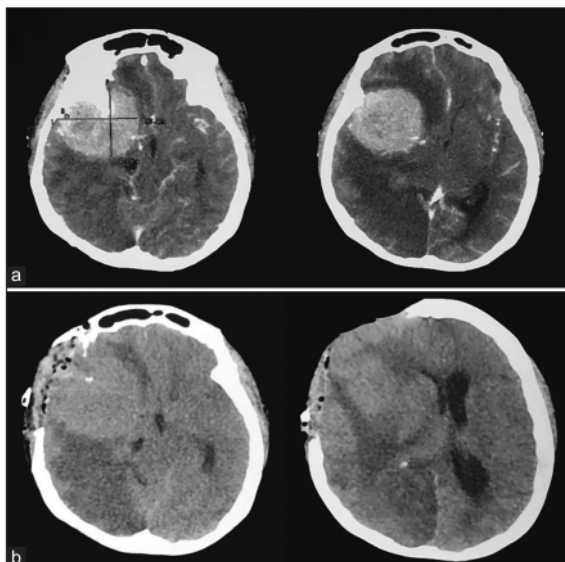
Classification of DC	Frequency
FTP decompression	10
Bifrontal decompression	4

FTP – Fronto-temporo-parietal; DC – Decompressive craniectomy



**Figure 3:** A head computed tomography scan of a 42-year-old female diagnosed with right medial sphenoid meningioma suffering of consciousness decreases for 10 days before admission. (a) Predecompressive craniectomy computed tomography scan showed a homogenous contrast-enhanced lesion in the right temporal fossa, severe brain edema was also shown in the right hemisphere with midline shifting more than 5 mm and hydrocephalus. (b) Postdecompressive craniectomy, hydrocephalus and brain edema were still observed. (c) Head computed tomography scan after tumor resection surgery in 2 days after decompressive craniectomy, several improvements were shown, brain edema and hydrocephalus were resolved





**Figure 4:** Head computed tomography scan of a 44-year-old woman with the consciousness decreases for 7 h before admission. (a) Head computed tomography scan with contrast revealed homogenous hyperdensity mass at the right sphenoid bone which caused midline shifting to the contralateral side. It was suggestive of a right lateral sphenoid meningioma. (b) Immediate postdecompressive craniectomy of head computed tomography scan without contrast. The right temporo-fronto-parietal bone of right sides had been removed. Cerebral infarction was observed in the right hemisphere

4 months associated with difficulty to communicate for a week. Head CT scan contrast [Figure 4] showed a solid, homogeneously contrast enhanced mass at lateral of right sphenoid wing suggestive of sphenoid wing meningioma. Signs of increased ICP were also evident. Emergency TFP DC was performed. No significant improvement observed immediately with postoperative GCS of 8/15. Seven days after DC, however, the patient died due to complication of pneumonia.

## Discussion

DC is a neurosurgical procedure in which a segment of the skull is temporarily removed in order to provide a space for the swelling brain. The rationale for DC is based on the Monro-Kellie doctrine.<sup>[11]</sup> By doing DC, it is expected that the additional space would help decrease the ICP and will increase the compliance of the swelling brain. Therefore, cerebral perfusion can be maintained and viable brain tissue is salvaged from the dreadful impact of increasing ICP.<sup>[11]</sup>

During this study period, we performed 14 DC surgeries in the emergency setting for patients with presenting symptoms of acute neurological deterioration secondary to meningioma. Decreased level of consciousness was found in all of the total participants as the main symptom in emergency ward examination. Although previous study has shown that headache is major common symptom in patients with meningioma, it was contrary to our findings, but it is

possibly caused by different setting of when the patients were diagnosed. All of our patients were diagnosed in an emergency setting while the other study was performed in the outpatient ward.<sup>[12]</sup> Lateness in diagnosis might also contribute as a factor that makes the majority of our patients to come to the emergency ward with decreased level of consciousness. This factor might be related to the lack of awareness to perform routine health screening even when they have already exhibited the symptoms, unavailability of neurosurgeons, great distance to get neurosurgery services from their domicile, and low socioeconomic status as well.

Meningioma is a slow-growing intracranial tumor that is often present with no symptom. However, acute neurological deterioration also can occur in some cases.<sup>[12-14]</sup> The increase of ICP due to an additional intracranial mass of tumor is probably underlying the process. In that circumstance, the definitive therapy is an emergency tumor resection. Yet, acute neurological deterioration has occurred and emergency tumor resection cannot be performed in every health center. The absence of emergency brain tumor surgery facilities, the inappropriate ratio between qualified neurosurgeons for tumor resection and patients, and the ever increasing number of meningioma patients due to technology advances in early diagnosing are among several factors that might contribute. DC without tumor resection may offer as an alternative lifesaving procedure in any health center who faces those limitations, though it has rarely been reported. Before finally deciding whether DC surgery is necessary, general basic management to alleviate raised ICP should be performed.<sup>[15,16]</sup>

Patients with GCS <8, apnea or have the inability to secure airway and evidence of brain herniation should be considered for early endotracheal intubation. Intubation should be proceeded with administration of medications to blunt the ICP during the procedure.<sup>[17]</sup> Proper oxygenation should be ascertained. The PaCO<sub>2</sub> is maintained to the range of 30–35 mmHg because it is an effective and rapid procedure to reduce ICP.<sup>[17,18]</sup> Hyperventilation effects are constriction of cerebral blood vessels and lowering of cerebral blood flow (CBF). This vasoconstrictive effect on cerebral arterioles lasts only 11–20 h since the pH of the cerebrospinal fluid will rapidly equilibrate to the new PaCO<sub>2</sub> level. Moreover, aggressive hyperventilation can lead to cerebral ischemia due to the decrease of CBF.<sup>[19,20]</sup> Hence, the most effective use of hyperventilation is for acute, sharp increases in ICP or signs of impending herniation.<sup>[21]</sup> When there is evidence of circulatory failure, fluid bolus should be given. The main goal of fluid therapy is to maintain euvoolemia and normoglycemia and prevent hyponatremia. Maintenance fluids usually consist of normal saline with the daily requirements of potassium chloride based on body weight. All fluids administered must be isotonic or hypertonic (e.g., Ringer's lactate and normal saline) and hypotonic fluids must be avoided (e.g., 0.18% saline in 5% dextrose).<sup>[22]</sup>

Mild head elevation of 15°–30° is necessary for every patient who is suspected with increased ICP in order to encourage jugular venous drainage. It has been shown to reduce ICP with no significant destructive effects on cerebral perfusion pressure or CBF.<sup>[22]</sup> One has to ensure that the patients are in euvoletic state and not in shock before placing in this position.<sup>[17]</sup> After ABC management was applied as first step management and followed by mild head elevation, we also simultaneously performed aggressive medical therapy for reducing increased ICP. The combination of dexamethasone and mannitol is widely used to reduce the ICP. Corticosteroids are particularly beneficial in brain tumor patients with significant peritumoral edema and associated neurological deficits.<sup>[3,23]</sup>

Deep-seated meningioma is a tumor located in a deep area of the brain so that common surgery is difficult to be performed because it is high-risk injury of pertinent neurovascular. Like other meningiomas, deep-seated meningioma can also lead patients to emergency condition due to its unusual edema formation which is known as PTBE. In previous report, meningioma with PTBE appearance made surgery more difficult. It is related to the surgical prognosis and conferred a higher risk of morbidity and postoperative complications.<sup>[24]</sup> In this circumstance, DC procedure might give advantage. It is expected that DC would give some time to let the PTBE resolve and reduce difficulty for definitive meningioma resection.

Another factor being considered to perform DC as a lifesaving procedure in patients with emergency meningioma is unavailability of facilities for brain tumor resection in emergency unit of all hospitals, especially in developing countries. The benefit of DC without tumor resection in this study should not be underestimated. In the majority cases, their level of consciousness could improve quiet well after DC procedure, making tumor resection surgery being able to be prepared as definitive therapy further. Previous studies showed that DC without opening the dura mater could lower ICP up to 15% and more extreme in DC with opening the durotomy which could lower the ICP up to 75% from the initial pressure.<sup>[25]</sup> Not only its effects on reducing ICP but also DC could improve oxygenation to the brain cells preventing further brain damages.<sup>[26]</sup>

## Conclusion

Based on our study, in developing countries, lifesaving DC for high ICP is attributed to deep-seated meningioma and can be considered as an effective emergency management in the neurosurgeons' armamentarium.

## Acknowledgment

The completion of this study could not have been possible without the support and assistance of seniors of the Faculty of Medicine, Airlangga University, and many others whose names cannot be mentioned one by one.

6

## Financial support and sponsorship

Nil.

## Conflicts of interest

There are no conflicts of interest.

## References

1. Kotecha RS, Pascoe EM, Rushing EJ, Rorke-Adams LB, Zwerdling T, Gao X, *et al.* Meningiomas in children and adolescents: A meta-analysis of individual patient data. *Lancet Oncol* 2011;12:1229-39.
2. Bondy M, Ligon BL. Epidemiology and etiology of intracranial meningiomas: A review. *J Neurooncol* 1996;29:197-205.
3. Oya S, Kim SH, Sade B, Lee JH. The natural history of intracranial meningiomas. *J Neurosurg* 2011;114:1250-6.
4. Cooper DJ, Rosenfeld JV, Murray L, Arabi YM, Davies AR, D'Urso P, *et al.* Decompressive craniectomy in diffuse traumatic brain injury. *N Engl J Med* 2011;364:1493-502.
5. Aarabi B, Hesdorffer DC, Ahn ES, Aresco C, Scalea TM, Eisenberg HM. Outcome following decompressive craniectomy for malignant swelling due to severe head injury. *J Neurosurg* 2006;104:469-79.
6. Gupta A, Sattur MG, Aoun RJ, Krishna C, Bolton PB, Chong BW, *et al.* Hemispheric craniectomy for ischemic and hemorrhagic stroke: Facts and controversies. *Neurosurg Clin N Am* 2017;28:349-60.
7. Merenda A, DeGeorgia M. Craniectomy for acute ischemic stroke: How to apply the data to the bedside. *Curr Opin Neurol* 2010;23:53-8.
8. Takeuchi S, Takasato Y, Masaoka H, Nagatani K, Otani N, Wada K, *et al.* Decompressive craniectomy for arteriovenous malformation-related intracerebral hemorrhage. *J Clin Neurosci* 2015;22:483-7.
9. Clower WT, Finger S. Discovering trepanation: The contribution of Paul Broca. *Neurosurgery* 2001;49:1417-25.
10. Goedemans T, Verbaan D, Coert BA, Kercklaan BJ, van den Berg R, Coutinho JM, *et al.* Neurologic outcome after decompressive craniectomy: Predictors of outcome in different pathologic conditions. *World Neurosurg* 2017;105:765-74.
11. Quinn TM, Taylor JJ, Magarik JA, Vought E, Kindy MS, Ellegala DB. Decompressive craniectomy: Technical note. *Acta Neurol Scand* 2011;123:239-44.
12. Rockhill J, Mrugala M, Chamberlain MC. Intracranial meningiomas: An overview of diagnosis and treatment. *Neurosurg Focus* 2007;23:E1.
13. Yamamoto J, Takahashi M, Idei M, Nakano Y, Soejima Y, Akiba D, *et al.* Clinical features and surgical management of intracranial meningiomas in the elderly. *Oncol Lett* 2017;14:909-17.
14. Missori P, Domenicucci M, Paolini S, Mancarella C, Tola S, D'Elia A, *et al.* Emergency decompressive craniectomy after removal of convexity meningiomas. *Surg Neurol Int* 2016;7:96.
15. Sankhyam N, Vykunta Raju KN, Sharma S, Gulati S. Management of raised intracranial pressure. *Indian J Pediatr* 2010;77:1409-16.
16. Rangel-Castilla L, Gopinath S, Robertson CS. Management of intracranial hypertension. *Neurol Clin* 2008;26:521-41, x.
17. Marcoux KK. Management of increased intracranial pressure in the critically ill child with an acute neurological injury. *AACN Clin Issues* 2005;16:212-31.
18. Marsh ML, Marshall LF, Shapiro HM. Neurosurgical intensive care. *Anesthesiology* 1977;47:149-63.

19. Skippen P, Seear M, Poskitt K, Kestle J, Cochrane D, Annich G, *et al.* Effect of hyperventilation on regional cerebral blood flow in head-injured children. *Crit Care Med* 1997;25:1402-9.
20. Robertson CS, Valadka AB, Hannay HJ, Contant CF, Gopinath SP, Cormio M, *et al.* Prevention of secondary ischemic insults after severe head injury. *Crit Care Med* 1999;27:2086-95.
21. Miller JD, Leech P. Effects of mannitol and steroid therapy on intracranial volume-pressure relationships in patients. *J Neurosurg* 1975;42:274-81.
22. Feldman Z, Kanter MJ, Robertson CS, Contant CF, Hayes C, Sheinberg MA, *et al.* Effect of head elevation on intracranial pressure, cerebral perfusion pressure, and cerebral blood flow in head-injured patients. *J Neurosurg* 1992;76:207-11.
23. Galicich JH, French LA, Melby JC. Use of dexamethasone in treatment of cerebral edema associated with brain tumors. *J Lancet* 1961;81:46-53.
24. Vignes JR, Sesay M, Rezajooi K, Gimbert E, Liguoro D. Peritumoral edema and prognosis in intracranial meningioma surgery. *J Clin Neurosci* 2008;15:764-8.
25. Jourdan C, Convert J, Mottolese C, Bachour E, Gharbi S, Artru F. Evaluation of the clinical benefit of decompression hemicraniectomy in intracranial hypertension not controlled by medical treatment. *Neurochirurgie* 1993;39:304-10.
26. Jaeger M, Soehle M, Meixensberger J. Effects of decompressive craniectomy on brain tissue oxygen in patients with intracranial hypertension. *J Neurol Neurosurg Psychiatry* 2003;74:513-5.



# 18. Lifesaving Decompressive Craniectomy for High Intracranial Pressure

## ORIGINALITY REPORT

17%

SIMILARITY INDEX

11%

INTERNET SOURCES

13%

PUBLICATIONS

0%

STUDENT PAPERS

## PRIMARY SOURCES

1	<a href="http://ijnmr.mui.ac.ir">ijnmr.mui.ac.ir</a> Internet Source	2%
2	<a href="http://www.omicsonline.org">www.omicsonline.org</a> Internet Source	1%
3	Kelly Keefe Marcoux. "Management of Increased Intracranial Pressure in the Critically Ill Child With an Acute Neurological Injury :", AACN Clinical Issues Advanced Practice in Acute & Critical Care, 04/2005 Publication	1%
4	<a href="http://www.springerlink.com">www.springerlink.com</a> Internet Source	1%
5	<a href="http://www.thieme-connect.de">www.thieme-connect.de</a> Internet Source	1%
6	<a href="http://eprints.bournemouth.ac.uk">eprints.bournemouth.ac.uk</a> Internet Source	1%
7	Tedy Apriawan, Rizki Meizikri, Endra Wibisono Harmawan, Heru Kustono. "Intraparenchymal fiberoptic intracranial pressure monitoring	1%

and decompressive craniectomy in meningioma case with critical intracranial pressure: A case report during COVID-19 pandemic", International Journal of Surgery Case Reports, 2022

Publication

---

8

Suvasini Sharma, Devendra Mishra, Satinder Aneja, Rashmi Kumar, Amita Jain, Vipin M. Vashishtha. "Consensus guidelines on evaluation and management of suspected acute viral encephalitis in children in India", Indian Pediatrics, 2012

Publication

---

9

[www.hopkinsmedicine.org](http://www.hopkinsmedicine.org)

Internet Source

---

10

Irwan Barlian Immadoel Haq, Dirga Rachmad Aprianto, Rahadian Indarto Susilo, Joni Wahyuhadi. "Corticosteroid Therapy for Brain Tumor Patients with Adrenal Insufficiency", Open Access Macedonian Journal of Medical Sciences, 2021

Publication

---

11

Jörg Dietrich, Krithika Rao, Sandra Pastorino, Santosh Kesari. "Corticosteroids in brain cancer patients: benefits and pitfalls", Expert Review of Clinical Pharmacology, 2014

Publication

---

1 %

1 %

1 %

1 %

12	T. M. Quinn. "Decompressive craniectomy: technical note : Decompressive craniectomy", Acta Neurologica Scandinavica, 07/18/2010 Publication	1 %
13	Vignes, J.R.. "Peritumoral edema and prognosis in intracranial meningioma surgery", Journal of Clinical Neuroscience, 200807 Publication	1 %
14	cdn.intechopen.com Internet Source	<1 %
15	edoc.pub Internet Source	<1 %
16	opac.wsb.torun.pl Internet Source	<1 %
17	acikerisim.istinye.edu.tr Internet Source	<1 %
18	eprints.manipal.edu Internet Source	<1 %
19	res.mdpi.com Internet Source	<1 %
20	George Wong, Mak, Gabriel Lu Yeow Yuen. "Review and recommendations on management of refractory raised intracranial pressure in aneurysmal subarachnoid	<1 %



# hemorrhage", Vascular Health and Risk Management, 2013

Publication

---

21 "Decompressive craniectomy in children with nontraumatic refractory high intracranial pressure", Journal of Neurosurgery Pediatrics, 01/2009 <1 %

Publication

---

22 "The 23rd International Symposium on Cerebral Blood Flow, Metabolism and Function", Journal of Cerebral Blood Flow & Metabolism, 2016 <1 %

Publication

---

23 Daniela Alexandru, Michael J. Glantz, Lyndon Kim, Marc C. Chamberlain, Daniela A. Bota. "Pulmonary metastases in patients with recurrent, treatment-resistant meningioma", Cancer, 2011 <1 %

Publication

---

24 [pubmed.ncbi.nlm.nih.gov](http://pubmed.ncbi.nlm.nih.gov) <1 %

Internet Source

---

25 [www.thieme-connect.com](http://www.thieme-connect.com) <1 %

Internet Source

---

26 "Principles of Neuro-Oncology", Springer Science and Business Media LLC, 2021 <1 %

Publication

---

27 D. Agrawal, N. Hussain. "Decompressive craniectomy in cerebral toxoplasmosis", European Journal of Clinical Microbiology & Infectious Diseases, 2005

Publication

<1 %

28 Rai Kou, Takuo Hiratani, Hideki Yagi, Haruhiko Kuwatsuka et al. "Inter-layer light transition in hybrid III-V/Si waveguides integrated by  $\mu$ -transfer printing", Optics Express, 2020

Publication

<1 %

29 [annalsofian.org](http://annalsofian.org)

Internet Source

<1 %

30 [iapindia.org](http://iapindia.org)

Internet Source

<1 %

31 [research-information.bris.ac.uk](http://research-information.bris.ac.uk)

Internet Source

<1 %

32 "Textbook of Pediatric Neurosurgery", Springer Science and Business Media LLC, 2020

Publication

<1 %

33 Acta Neurochirurgica Supplementum, 2009.

Publication

<1 %

34 Jean F. Soustiel. "Cerebral Blood Flow and Metabolism Following Decompressive Craniectomy for Control of Increased

<1 %

# Intracranial Pressure :", Neurosurgery,

07/2010

Publication

---

35

Juan Sahuquillo. "Decompressive craniectomy for the treatment of refractory high intracranial pressure in traumatic brain injury", Cochrane Database of Systematic Reviews Reviews, 01/25/2006

Publication

---

<1 %

36

Shelly D. Timmons. "Current trends in neurotrauma care", Critical Care Medicine, 2010

Publication

---

<1 %

---

Exclude quotes      On

Exclude matches      Off

Exclude bibliography      On



# 18. Lifesaving Decompressive Craniectomy for High Intracranial Pressure

---

GRADEMARK REPORT

---

FINAL GRADE

**/100**

GENERAL COMMENTS

**Instructor**

---

PAGE 1

---

PAGE 2

---

PAGE 3

---

PAGE 4

---

PAGE 5

---

PAGE 6

---

PAGE 7

---