

# A comparative study of full-thickness wound healing in rats using Nile tilapia skin and fresh human amnion

Nyssa Claresta Adhya Sastri<sup>1\*</sup>, Iswinarno Doso Saputro<sup>2</sup>, Lobredia Zarasade<sup>2</sup>

## ABSTRACT

**Background:** Human amnion contains several growth factors, inflammatory inhibitors, collagen and hyaluronic acid, which are proven to accelerate wound healing. The collection, processing, and storage of data have several limitations, especially in remote areas. Nile Tilapia fish (*Oreochromis niloticus*) skin contains amino acids, collagen, and tilapia piscidin, which allows it to be used as a xenograft. This study analyzes the effectiveness of tilapia fish skin compared to the fresh human amnion.

**Method:** Twenty-four rats were divided into three groups. Group I was a full-thickness wound treated with tilapia skin, group II was treated with fresh human amnion, and group III was a control. On the third day, a punch biopsy was performed. The granulation tissue thickness and collagen density were examined. A wound area measurement and histopathological examination of the entire wound were performed on the seventh day.

**Results:** The speed of epithelialization in the tilapia group compared to the amnion was not significantly different ( $p = 0.065$ ). On the third day, histopathologically, the tilapia group formed the same amount of granulation tissue as the amnion group. In the middle section between tilapia, amnion and control with the Kruskal-Wallis test showed no significant difference ( $p = 0.573$ ). There was no significant difference in collagen density on the third day between the three groups at the edges and in the middle of the wound ( $p = 0.097$  and  $0.253$ ). The Mann-Whitney test on the seventh day found that the density of collagen between tilapia and amnion groups was not much different ( $p = 0.126$ ).

**Conclusion:** The speed of epithelialization, growth of granulation tissue, and collagen density of wound healing in full-thickness rats were not significantly different between Nile tilapia skin and fresh human amnion. The skin of Nile Tilapia fish can be used for wound care or as a temporary biological dressing until the wound can be permanently closed.

**Keywords:** *biological dressing, fresh human amnion, Nile tilapia skin.*

**Cite This Article:** Sastri, N.C.A., Saputro, I.D., Zarasade, L. 2022. A comparative study of full-thickness wound healing in rats using Nile tilapia skin and fresh human amnion. *Bali Medical Journal* 11(3): 1945-1952. DOI: 10.15562/bmj.v11i3.3927

<sup>1</sup>Resident of Plastic Reconstructive and Aesthetic Surgery Department, Faculty of Medicine, Universitas Airlangga, East Java, Surabaya, Indonesia;

<sup>2</sup>Plastic Reconstructive and Aesthetic Surgery Department, Faculty of Medicine, Universitas Airlangga, East Java, Surabaya, Indonesia;

\*Corresponding author:

Nyssa Claresta Adhya Sastri;  
Resident of Plastic Reconstructive and Aesthetic Surgery Department, Faculty of Medicine, Universitas Airlangga, East Java, Surabaya, Indonesia;  
sastrinyssa@gmail.com

Received: 2022-10-22

Accepted: 2022-11-25

Published: 2022-12-19

## INTRODUCTION

The development of science and the discovery of new materials for wound healing are currently growing. Wound dressings with biomaterial-based ingredients containing bioactive compounds are starting to become an option. These bioactive compounds come from natural sources and are then processed into a biological dressing. Biological dressings have the advantage of creating an ideal environment for wound healing and play an important role in wound healing by controlling the inflammatory phase, accelerating the growth of fibroblasts, granulation tissue, and migration of keratinocytes.<sup>1,2</sup>

The wound will pass through three

phases, namely the inflammatory, proliferation and maturation phases, before finally healing. The wound-healing phases overlap and cannot be separated from one another. Wounds will become chronic if there is interference in that phase.<sup>3</sup> Therefore, appropriate wound dressings are needed to keep the wound healing process moving forward, such as biological dressings. Burns require a temporary wound covering to reduce evaporation, exudation and protein loss as a skin substitute.<sup>2,4</sup>

The human amniotic membrane is a natural biomaterial whose benefits have been known since ancient times and have been used for various medical conditions. The use of amnion as a biological dressing allows the wound to remain clean,

moist, and close spontaneously in small wounds. Meanwhile, larger wounds can be prepared to be closed definitively. Human amnion can reduce the number of bacteria in infected and contaminated wounds and can stimulate the healing and granulation of tissue in chronic wounds and burns.<sup>5</sup>

The availability of amniotic fluid on the market is still limited due to the large number of requests that are not proportional to the amount of production. This is because the raw materials for the manufacture of human amniotic membranes are still lacking and difficult to obtain. Amnion processing requires certain techniques and storage areas. Amnion is currently produced by several tissue banks in Indonesia, which are preserved and sterilized by chemical

means and gamma radiation. Network banks in Indonesia are also still limited in number.

Research shows that wound care products made from fish skin can improve skin wound healing. Sitje *et al.*, in their search through PubMed, found 392 articles related to wound healing with fish skin. The evidence shows that scaffold materials made from fish are biocompatible and biodegradable and do not require frequent dressing changes. It also contains components that can accelerate wound healing, have antibacterial and antiviral effects and are not at risk of transmitting disease or unwanted immunological reactions.<sup>6</sup>

Nile Tilapia (*Oreochromis niloticus*) species are often found in everyday life. There are also many by-products that are not used, such as skin and bones. Tilapia fish skin is a high-quality product because of its durability resembling leather and traction resistance. Tilapia skin exhibits similar histomorphological characteristics to human skin, with collagen bundles arranged horizontally and vertically within the dermis layer. It is possible to use Tilapia fish skin as a temporary biological dressing for burns.<sup>7</sup> In one study, it was stated that fish skin in a cellular form could stimulate cell growth in three dimensions better than human amnion.<sup>8</sup>

The potential of tilapia skin for treating wounds is not widely discussed, especially in Indonesia. Tilapia skin is readily available and does not require donor approval, making it easier to obtain. It is different from amnion, which requires donor approval from a mother. The aim of this study was to examine the healing effects of tilapia skin compared to human amnion on rat wounds. The skin of the tilapia fish can be further developed and could become a wound-healing alternative, particularly in regions lacking modern dressings and biological dressings.

## METHOD

This research was carried out using a post-test-only control group design. The independent variables were tilapia skin and human amnion, while the variables studied were epithelialization velocity, granulation tissue thickness and collagen density. We used 24 Wistar rats (*Rattus*

*norvegicus*) divided into three groups for this experiment, all of whom were male, 2-3 months old, and weighed between 150 and 200 grams.

The amnion used is fresh human amnion produced by the Center for Biomaterials – Tissue and Cell Bank of Dr. Soetomo General Academic Hospital Surabaya. The amnion was obtained from a healthy patient and was processed and screened after birth. After processing, the amnion sheet is stored in a special preservation tube. Microbiological culture tests were carried out before the amnion was applied to experimental animals.

Fish skin comes from tilapia of the *Oreochromis niloticus* species obtained from fish cultivation certified by the UPT Fish Health and Environment Laboratory of East Java Province, weighing between 200-300 grams, and 2 males. After cleaning the scales, the fish skin is separated with a special knife and rinsed with clean water to remove the blood and other impurities. Then the fish skin is put into a container containing sterile isotonic NaCl solution (0.9%), which has been cooled to 4°C. Muscles that are still attached are cleaned and washed again with a physiological solution. The following is a method of sterilization and preservation that has been previously studied by Lima-Junior *et al.*<sup>7</sup>

The fish skin was placed in a sterile container containing chlorhexidine gluconate 2% and left for 30 minutes. Then the fish skin was washed with physiological saline and soaked in chlorhexidine gluconate 4% for 30 minutes. The skin is rinsed, then put in a mixture of 50% glycerol and 50% normal saline. Furthermore, the skin is removed from the mixed solution and rinsed with 0.9% NaCl solution. Then put it in a container containing 75% and 100% glycerol, each successively massaged lightly for 5 minutes in the solution. Then the fish skin was stored in a sterile container at a temperature below 4° C.

All rats were shaved on their backs, then a full-thickness wound with a size of 2x3 cm was made by previously anesthetizing them with Ketamine 20-30 mg/kg intramuscularly. Wounds in group I was treated with tilapia skin, group II was treated with human amnion and group III was treated with tulle as a control. All

types of dressings were fixed to the edges of the wound using 5-0 nylon sutures, then covered with sterile gauze and adhesive without entangling. Each rat was placed in a separate cage to avoid aggressiveness between mice and damage to the wound dressing. After the action, all rats were given an injection of Amoxicillin 30 mg/kg intramuscularly and an analgesic injection of Flunixin 2.5 mg/kg intramuscularly.

Sampling was taken on the third and seventh days. Pictures were taken on the first day before the dressing was applied and on the seventh day after the dressing was removed. The wound area was observed and marked with the edges of the epithelium formed using the imitoMeasure application, and then the rate of epithelialization per day was calculated. This method is considered very useful because it is practical, effective, accurate and time-saving.<sup>9,10</sup>

On the third day, specimens of wound tissue were taken using a punch biopsy in the center and edges of the wound. This was done on half of the experimental animals from each treatment group. On the seventh day, the bandage was removed, and clinical photos were taken. Rats were sacrificed by decapitation, and the entire wound bed was excised. All specimens were stained with hematoxylin-eosin (HE) and Masson trichrome (MT) to examine granulation tissue thickness and collagen density.

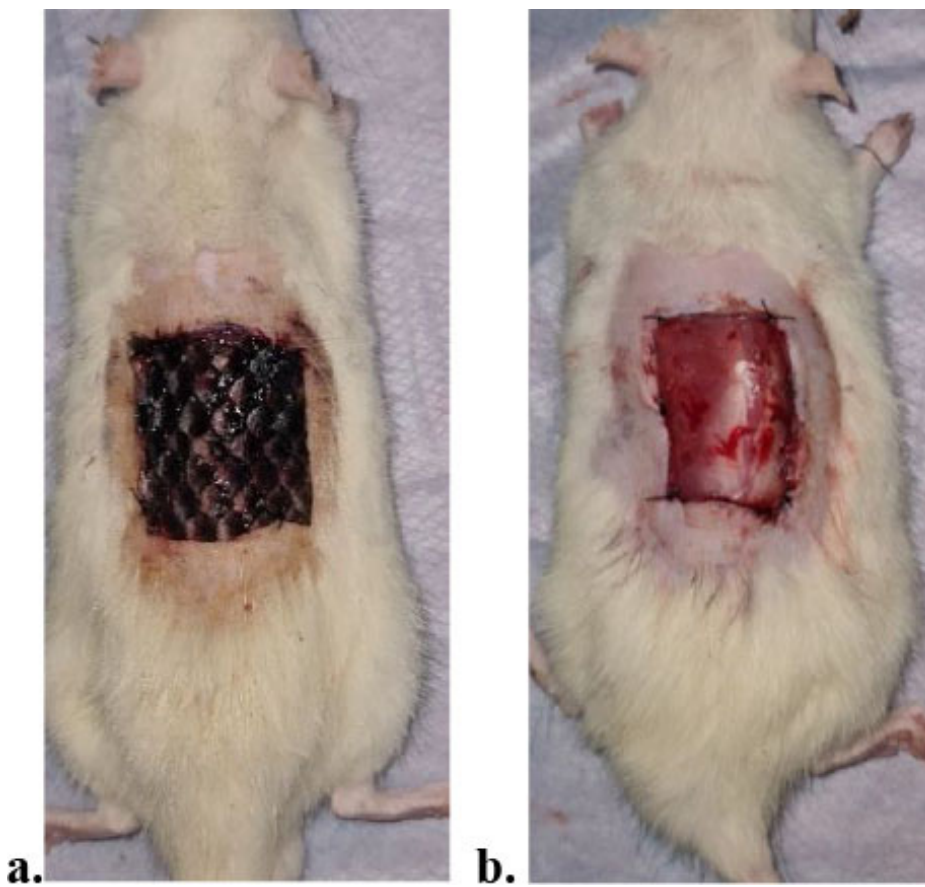
An inflammatory and proliferative process results in granulation tissue, which shows pink and granular color due to neovascularization or angiogenesis. Histologically, macrophages and fibroblasts are present in the tissue, which also play a role in forming the ECM.<sup>11</sup> An evaluation by an independent reviewer of granulation tissue thickness is based on the proportion of granulation tissue above the muscular layer to the entire thickness of the wound layer using a microscope with 100x magnification.

Fibroblast cells that are activated in the proliferative phase will begin the synthesis of thin type III collagen. This phase runs slowly, mediated by matrix metalloproteinase (MMP) enzymes secreted by macrophages. The fibers of collagen resemble colorless, wavy or straight threads of erratic length.<sup>12</sup>

Collagen density based on the calculation of one field of view at 400x microscope magnification is arranged based on scoring; 1 = low collagen fibril density (less than 10% in one visual field, 2 = moderate (10% - 50%), 3 = high (50% - 90%), 4 = very high (90% - 100%). Data were collected and processed using the analysis of variance (ANOVA) or Kruskal-Wallis methods using the Statistical Package for the Social Sciences (SPSS) software version 26.



**Figure 1.** Tilapia fish skin after preparation.



**Figure 2.** Full-thickness wounds on the backs of Wistar rats treated with tilapia skin (a), human amnion (b) on the first day.

## RESULTS

The research was conducted at the Experimental Animal Unit, Department of Physiology and Biochemistry, Faculty of Medicine, Airlangga University. Fish skin and amnion were applied to rat wounds after microbiological tests revealed no germ growth (Figures 1 and 2).

None of the experimental animals died during the study, but one wound infection was found in the amnion group, and it was excluded from the study and replaced.

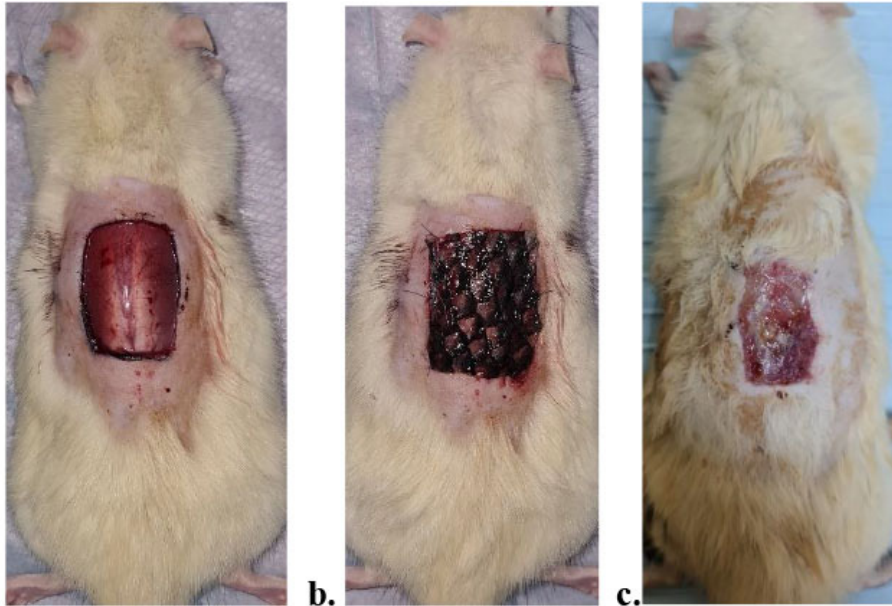
### Epithelialization rate

Observation of the speed of wound epithelialization was seen macroscopically. The surface area of the wound was observed visually using the imitoMeasure application version 2.0.0.18 on the first and seventh days (Figure 3). The calculation of the speed of epithelialization and the average for each treatment group was carried out and shown in the following figure.

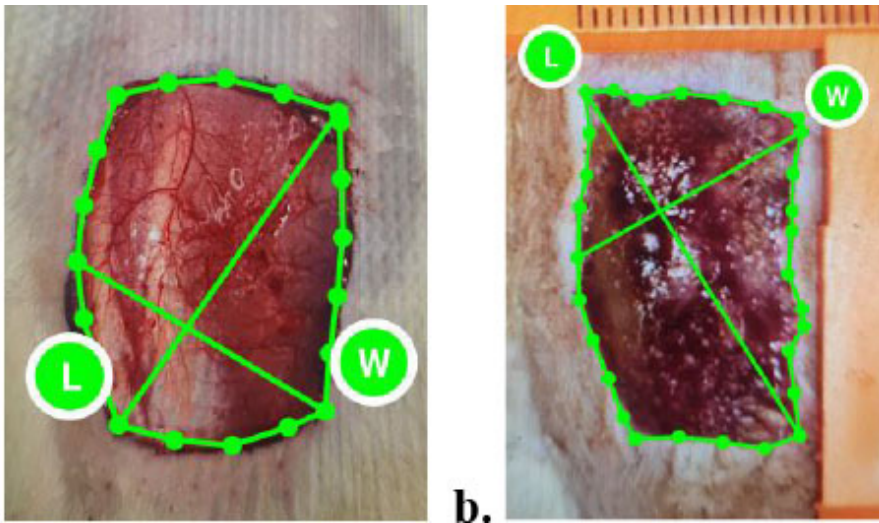
On the first day, the wound was measured, then the area was calculated in  $\text{cm}^2$  units (Figure 4). Of the three groups, the normality test was carried out with Shapiro-Wilk and found that groups I and II were not normally distributed ( $p = 0.016$  and  $0.045$ ). However, the non-parametric test with Kruskal-Wallis showed that the wound area data on the first day between the three groups were homogeneous. On the seventh day, the normality test with Shapiro-Wilk showed that the  $p$  values of the tilapia ( $0.294$ ), amnion ( $0.599$ ) and control ( $0.262$ ) groups were normally distributed. The test for differences between groups was carried out using One-Way ANOVA with a summary as follows (Table 1). The Post Hoc Test found that each group I and II had a significant difference when compared to group III ( $p = 0.033$  and  $0.002$ ), while between groups I and II (Tilapia vs. amnion), there was no significant difference ( $p = 0.197$ ).

Analysis of the average wound circumference of each group on the seventh day versus the first day using the paired T-test. The mean difference in the amnion group on the seventh day versus the first day was  $2.575$  cm, with an average

decrease in wound circumference of 3.67 mm/day (Table 2). This value was followed by the tilapia group, with an average decrease in wound circumference of 2.26 cm in seven days or 3.22 mm/day. In the control group, there was a decrease in circumference with an average of 1.67 cm for seven days or 2.3 mm/day.



**Figure 3.** Full-thickness wounds – Day 1 (a), after dressing – Day 1 (b), Day 7 after wound dressing removal (c).



**Figure 4.** Measurement of wound area on the first (a) and seventh (b) days with imitoMeasure.

**Table 1.** The mean difference in wound area between groups on the seventh day.

Group	N	Mean ± Standard Deviation (SD)	p	Tilapia vs control (p)	Amnion vs control (p)	Tilapia vs amnion (p)
I (Tilapia)	8	3.9038 ± 0.79022				
II (Amnion)	8	3.2663 ± 0.77268	0.006	0.033	0.002	0.197
III (Control)	8	5.0000 ± 1.23713				

Note: the difference is significant if p < 0.05

The speed of epithelialization per day was the fastest in group II, then group I and the last control group. The Shapiro-Wilk normality test on epithelialization rate showed a normal distribution with p-values for group I (0.210), group II (0.505) and group III (0.747). From these results, the One-Way ANOVA parametric test found a significant difference only in group II compared to group III (p = 0.002). The difference between groups I and II was not significant, with p = 0.065. From the post hoc statistical test results on the wound area on the seventh day, the speed of epithelialization showed that there was no significant difference between groups I (tilapia) and II (amnion) (Table 3).

**The thickness of granulation tissue**

Granulation tissue was stained with HE and assessed by an independent reviewer. The histopathological picture of granulation tissue is represented by the following figure (Figure 5). The proportion of granulation thickness obtained from the measurement of the granulation tissue over the muscle compared to the entire thickness of the wound layer on the preparation.

**Day 3**

The distribution of data on the proportion of granulation tissue thickness assessed on the third day from the edges in all groups using the Shapiro-Wilk test was found to be not normally distributed. Through the Kruskal-Wallis test, it was determined that p = 0.028, there was an effect of the treatment of the three groups on the thickness of the granulation tissue. There was a difference seen in the post hoc Mann-Whitney test between groups I and II when compared to group III by the value p = 0.047. While the group I compared to group II, p = 1. This means that the tilapia and amnion groups are considered the same. Table 4 below summarizes the description.

The thickness of the granulation tissue in the center of the wound by the Shapiro-Wilk test was also found to be not normally distributed. The Kruskal-Wallis test showed no significant difference in the thickness of the granulation tissue of the three groups (p = 0.573).

**Table 2.** Analysis of the decrease in mean wound circumference for each group on the seventh day versus the first day.

Group	N	Δ Mean difference circumference Day-1 vs Day-7 ± SD	p	Decrease in circumference per day
I (Tilapia)	8	2.2563 ± 0.8211	0.012	3.22
II (Amnion)	8	2.575 ± 0.78609	0.00	3.67
III (Control)	8	1.6725 ± 0.64276	0.00	1.67

Note: the difference is significant if  $p < 0.05$

**Table 3.** Speed of epithelialization between all groups.

Groups	N	Mean ± SD	p	Tilapia vs control (p)	Amnion vs control (p)	Tilapia vs amnion (p)
I (Tilapia)	8	5.9913 ± 1.74355				
II (Amnion)	8	7.6350 ± 1.56714	0.009	0.145	0.002	0.065
III (Kontrol)	8	4.7125 ± 1.75020				

Note: the difference is significant if  $p < 0.05$

**Table 4.** The thickness of granulation tissue on the wound edge on the third day.

Group	N	Mean	Standard Deviation (SD)	p	Tilapia vs control (p)	Amnion vs control (p)	Tilapia vs amnion (p)
I (Tilapia)	4	1	0.00				
II (Amnion)	4	1	0.00	0.028	0.047	0.047	1
III (control)	4	0.53125	0.361935				

Note: the difference is significant if  $p < 0.05$

**Table 5.** The thickness of granulation tissue on the 7<sup>th</sup> day.

Group	N	Mean rank	p	Tilapia vs control (p)	Amnion vs control (p)	Tilapia vs amnion (p)
I (Tilapia)	8	13.50				
II (Amnion)	8	16.13	0.049	0.08	0.027	0.340
III (Control)	8	7.88				

Note: the difference is significant if  $p < 0.05$

**Table 6.** Collagen density between groups on the seventh day.

Group	N	Mean Rank	Standard Deviation (SD)	p	Tilapia vs Control (p)	Amnion vs control (p)	Tilapia vs amnion (p)
I (Tilapia)	8	8.25	0.00				
II (Amnion)	8	12.75	0.00	0.028	0.015	0.09	0.126
III (Control)	8	16.50	0.361935				

Note: the difference is significant if  $p < 0.0$

### Day 7

The first normality test was carried out with the Shapiro-Wilk, which showed that the study data were not normally distributed. The mean between groups was tested with the non-parametric Kruskal-Wallis test, with the result  $p = 0.049$ , so it was concluded that there was a difference in granulation thickness between the three groups. Between groups that are significant was tested by post hoc test with Mann-Whitney. From the test results, it was found that only group II compared to group III had significance ( $p = 0.027$ ), so it can be concluded that the granulation

thickness was significantly different in the amniotic group compared to the control. Meanwhile, between groups I and III, as well as groups I and II, each was not significant with  $p = 0.34$  and  $0.08$  (Table 5).

### Collagen Density Day 3

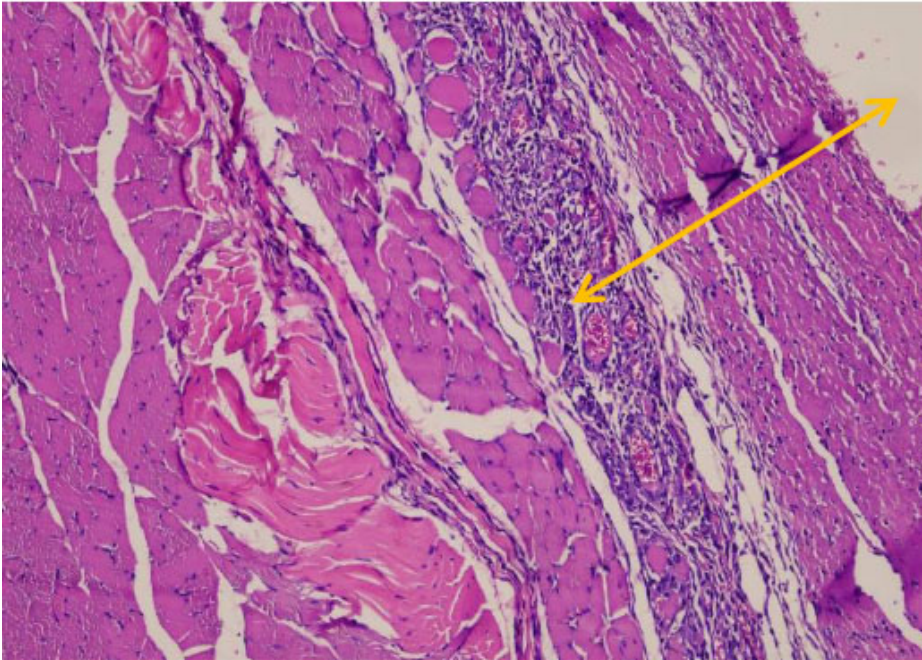
Collagen density is assessed using an ordinal scale between 0 and 4. Based on the mean ranking, a group I was denser in collagen than groups II and III at the wound edges (Figure 6). Meanwhile,

between groups I and II, the average rating was the same in the center of the wound. However, based on the Kruskal-Wallis statistical test, collagen density did not differ between the three groups both at the edges and in the center ( $p$ -value =  $0.097$  and  $0.253$ ).

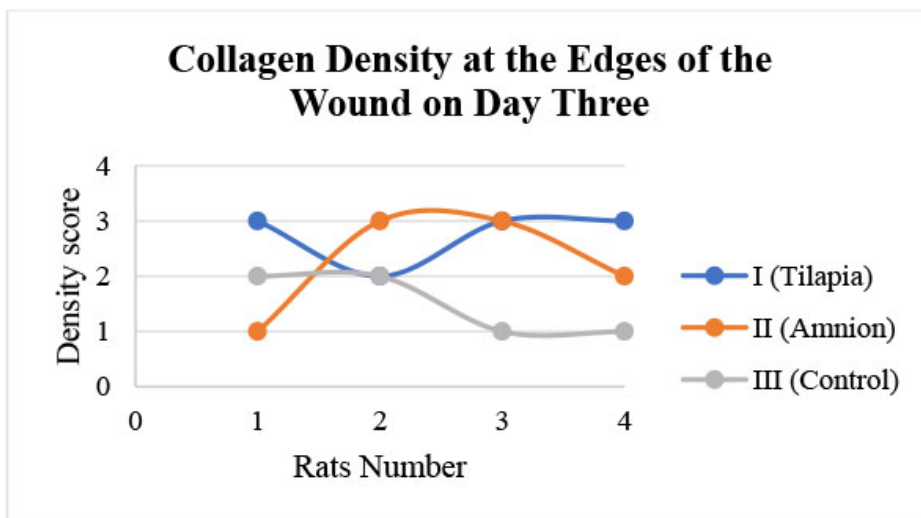
As illustrated in Figure 7 above, groups I and II have similar collagen densities in the center of the wound on the third day.

### Day 7

From the Kruskal-Wallis test, there was a significant difference in collagen density



**Figure 5.** Granulation tissue above the muscular layer (arrows), with an Olympus microscope type U-MDOB3, 100x magnification.



**Figure 6.** Diagram of collagen density at the wound edges on the third day.

between the three groups with a  $p$ -value = 0.028. The highest mean density was found in group III, followed by II and I. Differences between the two groups were tested using the post-hoc test with the Mann-Whitney test. Statistical tests concluded that there was a significant difference in collagen density between groups I and III ( $p = 0.015$ ). Insignificant results were shown in groups I and II ( $p$ -value = 0.126) and groups II and III ( $p = 0.09$ ) (Table 6). Accordingly, the density of collagen between the tilapia group and the amnion group, as well as between the

amnion group and the control group, is not significantly different.

Figure 8 provides a description of the collagen fibers found in the preparation based on their density as seen through a microscope at 400x magnification in one field of view.

## DISCUSSION

Re-epithelialization is a combination of the proliferative phase and cell migration at the edge of the wound. Tilapia fish skin and amnion work as biological dressings on rats' full-thickness wounds, both of

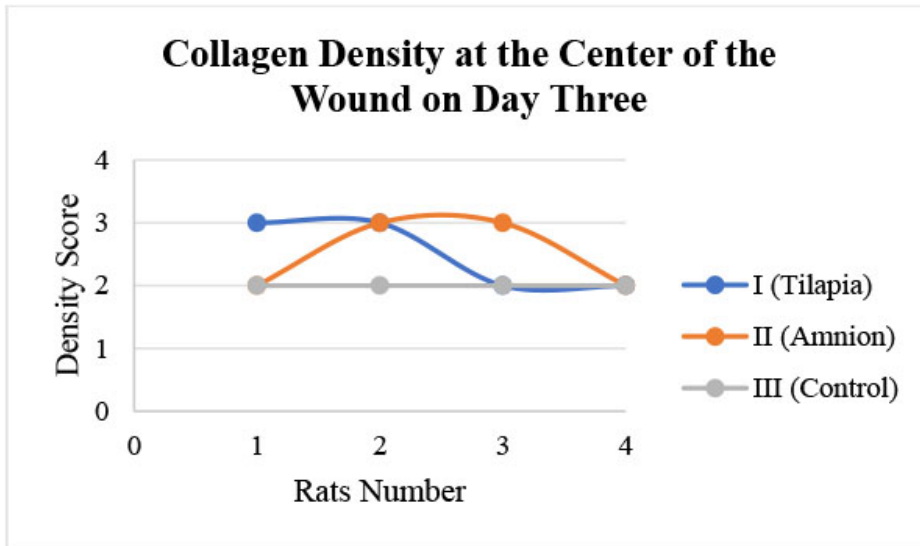
which have a high collagen content. The speed of wound epithelialization in seven days, based on average, was the fastest in the amnion group. On the third day, the rate of epithelialization was not assessed because the dressing was still attached to the wound.

However, the difference in the speed of epithelialization between tilapia and amnion groups was not statistically significant, so it means that there is a similarity between the two. A study by Hu *et al.* demonstrated that collagen peptides from tilapia skin proved to be effective in closing wounds and increasing wound healing in vitro and in vivo.<sup>13</sup> Another study used collagen extract from tilapia on rat skin wounds, which actually played a role in the wound healing process by increasing the expression of VEGF, FGF, and the alpha-smooth muscle actin ( $\alpha$ -SMA) gene.<sup>14</sup>

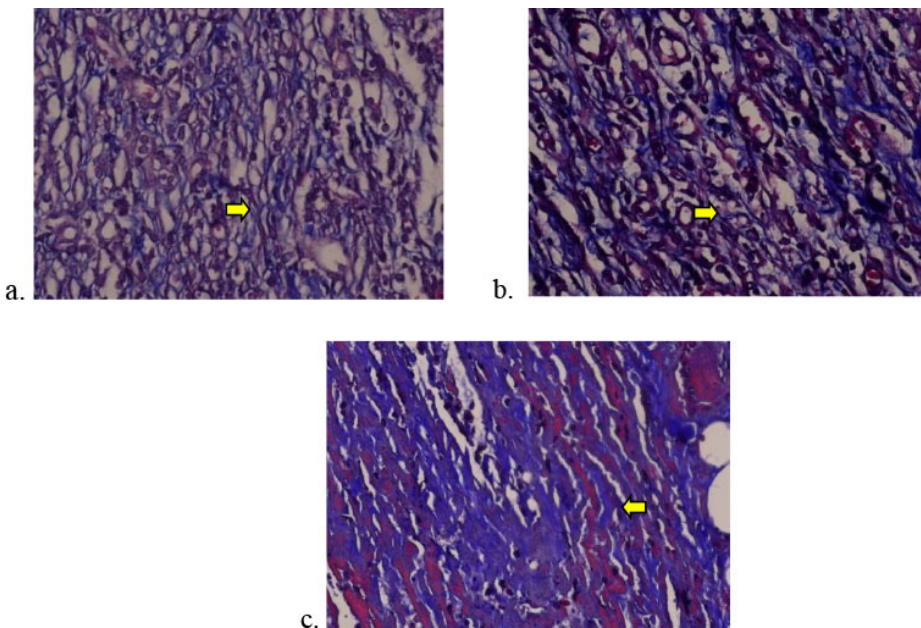
This study showed that wound circumference was reduced at an average rate of 3.2 mm/day with a tilapia skin treatment, 3.6 mm/day with wet amnion and 2.4 mm/day in the tulle treatment group. Biological dressing materials have been shown to accelerate rat wound healing with a faster epithelial healing rate than normal (1-2 mm/day).<sup>15</sup>

Granulation tissue is a component of the wound bed that consists of various cells that play a role in the healing phase. It contains new capillaries, inflammatory cells and macrophages, fibroblasts and keratinocytes. Its presence is essential for the formation of the extracellular matrix. In humans, the appearance of granulation tissue predominates on the fourth day of trauma, but in mice, its formation occurs more rapidly. On the third day of the study, granulation tissue formed both in the middle and on the edges of the wound. The thickness of granulation between the tilapia and amnion groups was found to be no different but better than the control at the edges of the wound. In the middle of the wound, there was no significant difference between the entire group.

On the seventh day after the injury, there was a significant difference in granulation thickness for the amnion group when compared to the controls. Tilapia and amnion fish groups are considered to have no different effect



**Figure 7.** Diagram of collagen density at the wound center on the third day.



**Figure 8.** Collagen fibers (arrows) show grade 1/ low density (a), grade 2/ moderate (b), and grade 3/ dense (c) with an Olympus microscope type U-MDOB3, 400x magnification.

on the formation of granulation tissue. A porosity study between tilapia skin and dry amnion showed that tilapia skin was superior in fibroblast cell growth. Antibacterial ability was also shown in the first 48-74 hours when bacterial colonies were added to the experimental medium.<sup>16</sup> This benefit is also in line with this study which found that there were no infected wounds in the tilapia skin group, whereas there was one infected wound in the wet amnion group.

Tilapia skin material containing high

amounts of collagen may induce the production of collagen by fibroblasts, which are also components of the extracellular matrix. Assessment of collagen density at both the periphery and center was found to be no difference between groups treated with tilapia skin, amnion and tulle on the third day. The tilapia skin group had the greatest collagen density value at the edges of the wound.

On the seventh day, the control group with the highest collagen density was obtained, and the lowest tilapia skin

group. However, the density difference between tilapia skin and amnion was not significant. This difference indicates the process is still running from the third to the seventh day. In tilapia skin treatment, fibroblasts and collagen cells are formed rapidly, but the synthesis is not excessive.

The application of tilapia fish skin to wounds that are not being treated right away but rather waiting for microbiological tests for five days can be highlighted in this study. The effect of chemical sterilization and storage at cold temperatures requires further investigation of collagen levels, although, from the literature, there is no fiber disorganization.<sup>17</sup> Additionally, no immune reactions were observed in mice, both treated with fish skin and human amnion. This is despite the literature stating that fish products have low allergic reactions after processing. This requires further research. The limitation of this research is the use of digital imaging tools to calculate the rate of epithelialization, which has not yet been verified.

## CONCLUSION

The effectiveness of tilapia skin in the treatment of full-thickness wounds in rats was not significantly different from wet human amniotic membranes. Specifically, the rate of epithelialization, the thickness of granulation tissue, and the density of collagen produced in full-thickness rats' wound healing did not differ between tilapia fish skin and amnion. Dressings made from Tilapia fish skin might be useful for wound care or situations in which the amnion is difficult to reach, but further research is necessary.

The next suggestion is to conduct further research over a longer period of time. In addition, there are studies that examine the collagen content of tilapia skin, the effect of sterilization on collagen levels, and allergic reactions to tilapia skin. Human application studies can be carried out in the future.

## RESEARCH ETHICS

This research has been approved by the Animal Care and Use Committee, Faculty of Veterinary Medicine, Universitas Airlangga, with ethic number No: 2.KEH.100.08.2022.

## CONFLICT OF INTEREST

There is no conflict of interest in writing this research report.

## FUNDING

This research was conducted without grants, sponsors, or other sources of funding.

## AUTHOR CONTRIBUTION

All authors have made the same contribution in writing the report on the results of this study, from the stage of proposal preparation, data search, and data analysis, to the interpretation of research data and presentation of the final report.

## REFERENCES

1. Schoukens, G. Bioactive dressings to promote wound healing. In S. Rajendran (Ed.), *Advanced Textiles for Wound Care*. Sawston: Woodhead Publishing. 2009. p114-152.
2. Dhivya S, Padma VV, Santhini E. Wound dressings - a review. *Biomedicine (Taipei)*. 2015;5(4):22. DOI:10.7603/s40681-015-0022-9.
3. Demidova-Rice TN, Hamblin MR, Herman IM. Acute and impaired wound healing: pathophysiology and current methods for drug delivery, part 1: normal and chronic wounds: biology, causes, and approaches to care. *Adv Skin Wound Care*. 2012;25(7):304-314. doi:10.1097/01.ASW.0000416006.55218.d0.
4. Mohammadi AA, Seyed Jafari SM, Kiasat M, et al. Effect of fresh human amniotic membrane dressing on graft take in patients with chronic burn wounds compared with conventional methods. *Burns*. 2013;39(2):349-353. doi:10.1016/j.burns.2012.07.010.
5. Castellanos G, Bernabé-García Á, Moraleda JM, Nicolás FJ. Amniotic membrane application for the healing of chronic wounds and ulcers. *Placenta*. 2017;59:146-153. doi:10.1016/j.placenta.2017.04.005.
6. Sitje TS, Grøndahl EC, Sørensen JA. Clinical innovation: fish-derived wound product for cutaneous wounds. *Wounds International*. 2018 Dec 10;9(4):44-50.
7. Lima-Junior, E.M. et al. The use of tilapia skin (*Oreochromis niloticus*), as an occlusive biological dressing, in the treatment of burn wounds. *Revista Brasileira de Queimaduras*. 2017;16(1). p10-17. DOI:10.33448/rsd-v10i8.17146.
8. Magnusson S, Baldursson BT, Kjartansson H, Rolfsson O, Sigurjonsson GF. Regenerative and Antibacterial Properties of Acellular Fish Skin Grafts and Human Amnion/Chorion Membrane: Implications for Tissue Preservation in Combat Casualty Care. *Mil Med*. 2017;182(S1):383-388. doi:10.7205/MILMED-D-16-00142.
9. Bodea IM, Dîrlea SA, Mureşan C, Fiş NI, Beteg FI. Clinical Benefits of Using a Smartphone Application to Assess the Wound Healing Process in a Feline Patient - A Case Report. *Top Companion Anim Med*. 2021;42:100498. doi:10.1016/j.tcam.2020.100498.
10. Biagioni RB, Carvalho BV, Manzioni R, Matielo MF, Brochado Neto FC, Sacilotto R. Smartphone application for wound area measurement in clinical practice. *J Vasc Surg Cases Innov Tech*. 2021;7(2):258-261. Published 2021 Feb 26. doi:10.1016/j.jvscit.2021.02.008.
11. Gurtner G and Wong V. Wound healing : normal and abnormal. In C. H. Thorne (Ed.), *Grabb and Smith's Plastic Surgery*. Philadelphia: Lippincot Williams & Wilkins. 2014. p13-19.
12. Oliveira GG, Gasparino E, Castilha LD, et al. Characterization and Strength Quality of the *Oryctolagus cuniculus* Leather Compared to *Oreochromis niloticus* Leather. *ScientificWorldJournal*. 2022;2022:4561404. Published 2022 Oct 14. doi:10.1155/2022/4561404.
13. Hu Z, Yang P, Zhou C, Li S, Hong P. Marine Collagen Peptides from the Skin of Nile Tilapia (*Oreochromis niloticus*): Characterization and Wound Healing Evaluation. *Mar Drugs*. 2017;15(4):102. Published 2017 Mar 30. doi:10.3390/md15040102.
14. Elbially ZI, Atiba A, Abdelnaby A, et al. Collagen extract obtained from Nile tilapia (*Oreochromis niloticus* L.) skin accelerates wound healing in rat model via up regulating VEGF, bFGF, and  $\alpha$ -SMA genes expression. *BMC Vet Res*. 2020;16(1):352. Published 2020 Sep 24. doi:10.1186/s12917-020-02566-2.
15. Dorsett MW and Wysocki A. Rat Models of Skin Wound Healing. In M. Conn (Ed.), *Sourcebook of Models for Biomedical Research*. New Jersey: Humana Press. 2008. p631-638.
16. Kirsner RS, Margolis DJ, Baldursson BT, et al. Fish skin grafts compared to human amnion/chorion membrane allografts: A double-blind, prospective, randomized clinical trial of acute wound healing. *Wound Repair Regen*. 2020;28(1):75-80. doi:10.1111/wrr.12761.
17. Alves APNN, Lima Júnior EM, Piccolo NS, et al. Study of tensiometric properties, microbiological and collagen content in Nile tilapia skin submitted to different sterilization methods. *Cell Tissue Bank*. 2018;19(3):373-382. doi:10.1007/s10561-017-9681-y.



This work is licensed under a Creative Commons Attribution