



HASIL VALIDASI DAN PENILAIAN
KARYA ILMIAH DOSEN FAKULTAS KEDOKTERAN UNIVERSITAS AIRLANGGA
(MEDIA PUBLIKASI KARYA ILMIAH : JURNAL ILMIAH INTERNASIONAL)
NOMOR : 035 /UN3.1.1/BPRE/ II /2023

FORM 15

A. Identitas Karya Ilmiah

- Judul Jurnal Ilmiah (Artikel) : **Skin graft as a modality reconstruction of post-burn contractures during pandemic area : case series**
- Jumlah penulis : 6 enam) penulis . Ulfa Elfiah, David Sontani P., Iswinarno Dosoaputra, I Nyoman Riasa, Loelita Marclia L, Muhammad Fahmi Naufal
- Status Pengusul : Penulis Ke. 3
- Identitas Jurnal Ilmiah
- Nama Jurnal : Bali Medical Journal (bali Medj)
 - Nomor ISSN : 2089-1180, E. 2302-2914
 - Volume, Nomor, bulan, tahun : 11 / 3 /2023 p. 1945-1952
 - Penerbit : Sanglah General Hospital
 - Doi : : <https://doi.org/10.15562/bmj.v12i1.4003>
 - Alamat web Jurnal :
<https://balimedicaljournal.org/index.php/bmj/article/view/4003>
 - Terindek di Scimagojr/Thomson Reuter ISI Knowledge atau di :
Web Of Science, Scopus, Proquest Central, Pubmed, Google Scholar
Q4 (2021), 0,11 H.Indeks : 2, Coverage 2020-2021

- B. Kategori Publikasi Karya Ilmiah (beri Y pada kategori yang tepat)**
- | | |
|-------------------------------------|---|
| <input checked="" type="checkbox"/> | Jurnal Ilmiah Internasional Bereputasi (SJR > 0,10) |
| <input type="checkbox"/> | Jurnal Ilmiah Internasional Bereputasi (SJR < 0,10) |
| <input type="checkbox"/> | Jurnal Ilmiah Internasional terindeks di Web of Science clarivate analytics / kelompok emerging sources citation indeks (tidak terindeks SJR) |


C. Hasil Validasi Ketua Departemen

Telah diperiksa dan divalidasi dengan baik, dan sampai pernyataan ini dibuat sebagai karya ilmiah **original / ~~plagiat~~***, sehingga kami turut bertanggung jawab bahwa karya ilmiah tersebut telah memenuhi syarat kaidah ilmiah, norma akademik, dan norma hukum, sesuai dengan Peraturan Menteri Pendidikan Nasional Nomor 17 Tahun 2010 tanggal 16 Agustus 2010 tentang Pencegahan dan Pananggulangan Plagiat di Perguruan Tinggi. Namun demikian, apabila di kemudian hari ternyata terbukti bahwa karya ilmiah tersebut merupakan karya Ilmiah Plagiat, maka akan menjadi tanggung jawab mutlak penulis tersebut di atas, baik secara perdata maupun pidana. Demikian surat pernyataan ini saya buat untuk dipergunakan sebagaimana mestinya

Surabaya, 10 Oktober 2022

Ketua Departemen
Bedah Plastik Rekonstruksi dan Estetik

Prof.Dr.David S. Perlanakusuma, dr.,SpBP-RE(K)
NIP. 19600305 198901 1 002



Form Penilaian Kualitas Karil dan Kesesuaian Bidang Ilmu

Profil Sinta : Link Sinta <https://sinta.kemdikbud.go.id/profile>

A		Identitas Karya Ilmiah
1	Judul :	Skin graft as a modality reconstruction of post-burn contractures during pandemic area : case series.
2	Nama Penulis :	Ulfa Elfiah, David Sontani P., Iswinarno Dosoaputra, I Nyoman Riasa, Loelita Marclia L, Muhammad Fahmi Naufal.
3	Nama Jurnal :	Bali Medical Journal (bali Medj)
B		Peng-index : Jurnal Internasional Bereputasi
		Q4 (2021) SJR : Coverage : Vol.12, No.,1, Tahun 2023 p.244-248 Penerbit : Sanglah General Hospital ISSN. 2089-1180, E. 2302-2914
C		Relevansi kompetensi dosen dengan substansi karya ilmiah
		<ol style="list-style-type: none"> 1. Artikel ini membahas tentang Skin graft sebagai modalitas rekonstruksi kontraktur pasca luka bakar pada area pandemi. Studi kasus ini bertujuan untuk mengevaluasi cangkok kulit sebagai modalitas rekonstruksi kontraktur pasca luka bakar di daerah pandemi. 2. Artikel ini sesuai dengan bidang keahlian pengusul yaitu Luka Bakar 3. Tidak ada keterkaitan dengan naskah Disertasi pengusul yang berjudul : Mekanisme Hambatan Deposisi Kolagen Tipe I pada Luka Bakar Derajat 2 Dalam Yang diberi Ekstrak Buah Delima Terstandar pada Tikus Putih (Rattus norvegicus)
D		Kesesuaian antara lingkup / subjek area jurnal dengan karya ilmiah yang diusulkan
		<ol style="list-style-type: none"> 1. Alamat Web Jurnal : https://balimedicaljournal.org/index.php/bmj/article/view/4003 2. Kebenaran ISSN : 2089-1180, E. 2302-2914 3. Termasuk "Predatory" tidak (jurnal; penerbit) : tidak masuk pada predatory 4. Syarat komposisi Editor Board : lebih dari negara 5. Syarat kontributor penulis artikel : Penulis anggota 6. Keberkalaan penerbitan : - terbitan pertahun 7. Subjek area dan katagori jurnal : Medicine (Miscellaneous)
E		Kepastian tidak ada pelanggaran integritas akademik
		<ol style="list-style-type: none"> 1. Indikasi plagiasi (lihat check similarity) : Similarity 6% 2. Artikel tidak ada indikasi plagiasi. 3. Fabrikasi : Tidak ada 4. Falsifikasi : Tidak ada 5. Praktek kepalsuan : Tidak ada
		Nilai pengusul (penulis pertama dan corespondensi 60%)
		Nilai pengusul (penulis pertama / penulis corespondensi masing - masing 40%)
		Nilai lainnya sesuai PO PAK 2019 dan suplemennya

Surabaya,
Penilai Angka Kredit 1

Nama :
NIP :
Bidang Ilmu :
Unit Kerja :

Skin graft as a modality reconstruction of post-burn contractures during pandemic area: case series



Ulfa Elfiah^{1,2}, David Sontani Perdanakusuma^{3*}, Iswinarno Dososaputra³,
I Nyoman Riasa⁴, Loelita Marcelia Lumintang⁵, Muhammad Fahmi Naufal⁶

ABSTRACT

Background: The Covid-19 pandemic causes the postponement of elective surgery. At the same time, patients with post-burn contractures require immediate operation due to impaired function that can lead to depression and disruption of daily life. Operations on contracture patients during a pandemic must be carried out using the principles of accuracy, speed, and safety. The skin graft is one of the most appropriate treatments modalities for releasing contractures. This case study aims to evaluate the skin graft as a modality reconstruction of post-burn contractures during pandemic area.

Case Presentation: We present three cases of post-burn contractures who underwent contracture release and skin graft surgery with a hospital stay of 3-5 days. Surgical results showed that graft take reached 90%-100% in all patients, and 100% epithelialization occurred at donor sites between 2-4 weeks postoperatively. There were no post-operative complications.

Conclusion: The skin graft is an effective and suitable technique for treating post-burn contractures in the pandemic era.

Keywords: Burn Wound, Contracture, Covid-19, Pandemic, Skin Graft.

Cite This Article: Elfiah, U., Perdanakusuma, D.S., Dososaputra, I., Riasa, I.N., Lumintang, L.M., Naufal, M.F. 2023. Skin graft as a modality reconstruction of post-burn contractures during pandemic area: case series. *Bali Medical Journal* 12(1): 244-248. DOI: 10.15562/bmj.v12i1.4003

¹Doctoral Program of Medical Science, Faculty of Medicine, Universitas Airlangga, Surabaya, Indonesia;

²Department of Reconstructive and Aesthetic Plastic Surgery, Dr. Soebandi Hospital, Faculty of Medicine, Universitas Jember, Jember, East Java, Indonesia;

³Department of Reconstructive and Aesthetic Plastic Surgery, Dr. Soetomo Hospital, Faculty of Medicine, Universitas Airlangga, Surabaya, Indonesia;

⁴Department of Reconstructive and Aesthetic Plastic Surgery, Prof. dr. I.G.N.G. Ngoerah Hospital, Faculty of Medicine, Universitas Udayana, Denpasar, Indonesia;

⁵Department of Reconstructive and Aesthetic Plastic Surgery, Sajiwani Hospital, Faculty of Medicine, Universitas Udayana, Denpasar, Indonesia;

⁶Faculty of Medicine, Universitas Jember, Jember, East Java, Indonesia;

*Corresponding author:

David Sontani Perdanakusuma;
Department of Reconstructive and Aesthetic Plastic Surgery, Dr. Soetomo Hospital, Faculty of Medicine, Universitas Airlangga, Surabaya, Indonesia;
dperdanakusuma@fk.unair.ac.id

Received: 2022-11-15

Accepted: 2022-12-18

Published: 2023-01-11

INTRODUCTION

The spread of the Covid-19 virus throughout the world has caused changes in the treatment system for patients. Various procedures and services, especially elective case operations, have been reduced or stopped.¹ This is because most hospital beds have been converted into isolation rooms and the relocation of human resources for the Covid-19 situation.² This treatment change is also felt by plastic surgery patients, including post-burn contracture patients. Patients cannot perform medical rehabilitation treatment optimally to increase the risk of impaired function. After two years of the pandemic, experts must consider strategies for handling non-covid patients to prevent more severe complications. The most straightforward operating technique, which is fast and beneficial, must be selected as the definitive treatment.

Defect closure of contracture cases aims to restore the function of body structures according to their anatomical position. Surgical techniques of wound closure are based on the algorithm of wound closure. However, during a pandemic, a surgical process shall not require prolonged physical contact with the patient. Therefore, the

considered. Sison-Williamson M et al. showed that axillary contracture surgery with skin grafts improved shoulder function in the short and long term.³

In line with Sison, Saaq M et al. stated that 191 patients with skin graft surgery showed satisfactory restoration of function.⁴ Fufa DT et al. found that 90% of post-burn contractures of the patient's hand undergoing complete scar excision and full-thickness skin graft (FTSG) can fully flex the metapalange (MP) within six months.⁵ In addition, Seo DK et al. showed a decrease in Vancouver scar scale (VSS) scores after one year of split-thickness skin graft (STSG) surgery with dermal substitutes. However, 27 of 28 patients showed excellent or good long term outcomes such as improved function and cosmetic skin texture.⁶

This report aims to present the method we use to release severe post-burn contracture without using a flap technique that takes longer time and increases the risk exposed to COVID-19.

CASE PRESENTATION

Case 1

A 35-year-old man was hospitalized one year ago due to an electrical burn at work. Surgery

and wound care were performed for 1 month, followed by physiotherapy for six months. However, due to the pandemic, the patient has never done therapy routinely. In the last three months, he complained of stiffness in the elbow joint and limited range of motion. The results of the local status examination on the patient's right superior extremity showed a hypertrophic scar that spread from the lateral side of the brachial to the ulnar side of the antebrachial. The appearance of a hypopigmented scar extends from the right anterior thorax to the antebrachial region, as seen in **Figure 1a**. Flexion and extension of the fingers are normal, and abduction and adduction movements of the axilla are also normal. The patient was diagnosed with severe contracture and decided to perform contracture release and closure of the defect with a skin graft by a plastic surgeon. For the optimization of post-operative function, physiotherapy is planned. During the operation, scars were as deep as the subcutis, and ankylosis was found in the joints when moved. Post-excision defects were approximately 20 x 15 cm in size and were covered with skin grafts from the right femur donor skin, as seen in **Figure 1b**. The total length of operation was one hour. The post-operative care was carried out for one day for post-operative pain after surgery, and the graft and treatment were evaluated five days after the patient left the hospital. This patient's total length of treatment consisted of one day for preparation for surgery, including a Polymerase Chain Reaction (PCR) examination, one day of surgery, and one day of post-operative care. The graft evaluation showed that 100% graft was taken, while the evaluation of the donor performed two weeks postoperatively showed 100% epithelialization. The patient could carry out daily activities well one month after surgery, as seen in **Figure 1c**. Physiotherapy continued after three months to get optimal results.

Case 2

A five-year-old child had a history of burns due to a hot water spill six months earlier. The patient had a history of refusing to treat wounds in a hospital and chose to be treated alone. The wound had not dried three months after treatment

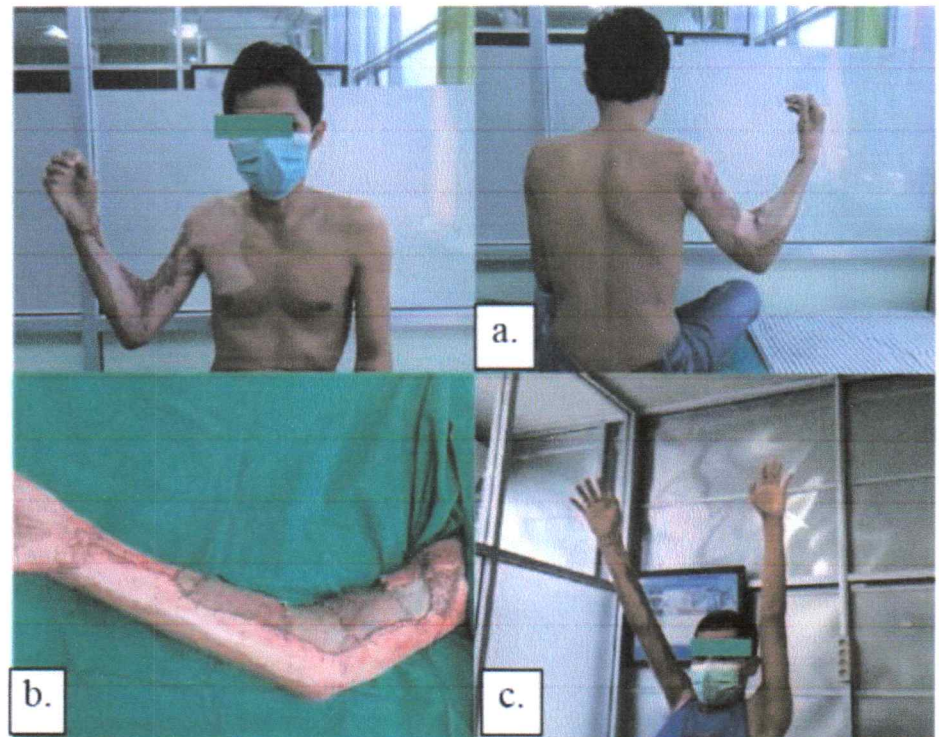


Figure 1. Contracture (a) preoperative: a hypertrophic scar with a hypopigmented scar that spread from the anterior thorax, lateral side of the brachial to the ulnar side of the antebrachial right; (b) post-operative: post-burn contracture was released and was covered with skin graft; (c) 1 month post-operative: the patient was able to carry out daily activities well.

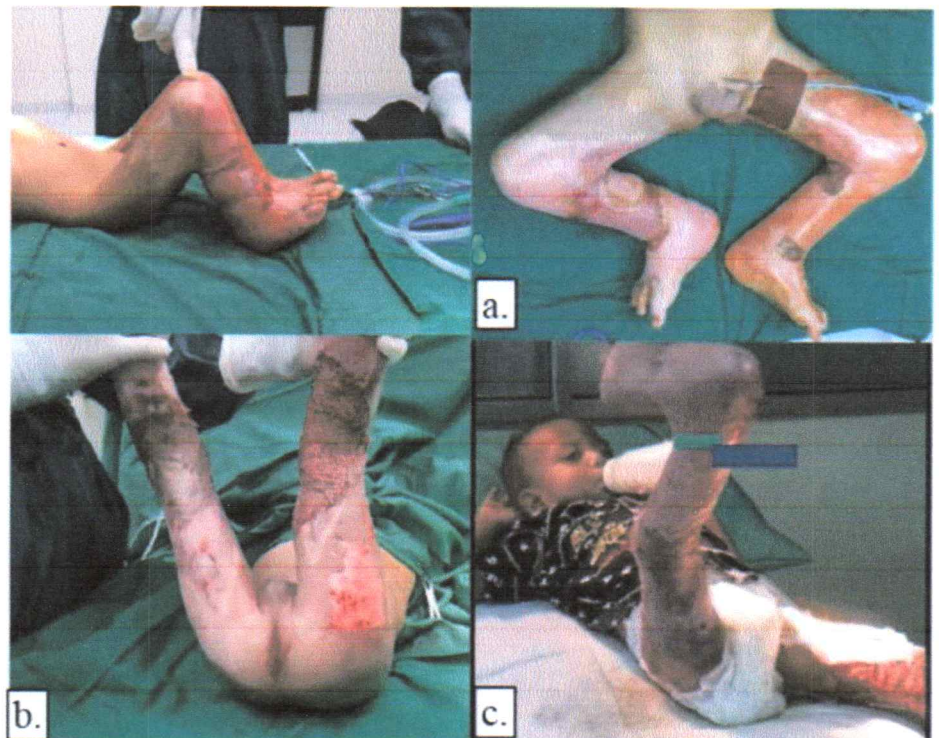


Figure 2. Contracture (a) preoperative: Thickened and widespread scar tissue on the right and left lower extremities; (b) post-operative: post-burn contracture was released and was covered with skin graft; (c) four weeks postoperatively, the patient can perform lower extremity elevation.

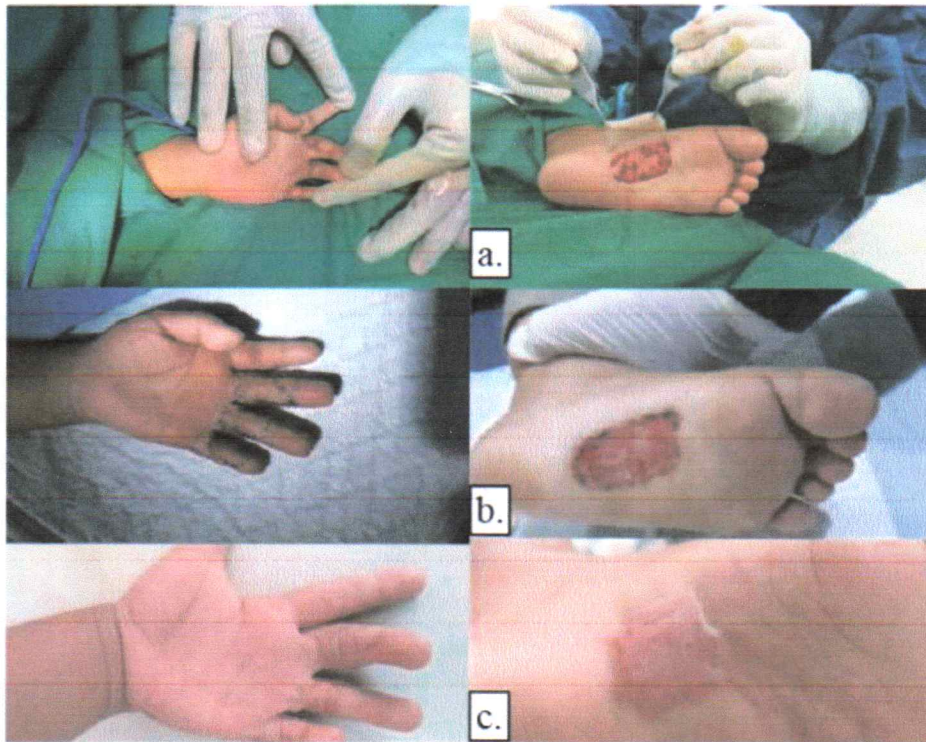


Figure 3. Contracture (a) preoperative: a linear scar from the dip joint to the pip joint digits three-five and donor removal from plantar pedis; (b) two weeks postoperatively: The grafts with 100% take results, and donor site showed a small slough and some epithelial; (c) The wound closed well 6 months after the surgery.

and showed signs of stiffness. Six months later, the patient's right and left legs and toes cannot be straightened, and the movement is limited. The results of the local status examination can be seen in **Figure 2**, on the right extremity showed thickened and widespread scars on the entire lower extremity, limited movement, flexion contractures in the genu region and dorsiflexion contractures on the dorsum pedis. The left extremity shows the same localized status as the right; only the scars arise from 1/3 of the femur to the toes. The patient was diagnosed with severe genu contracture, and a plastic surgeon performed a contracture release.

In this patient, the contracture release was carried out in some stages with consideration of pediatric patients and the pandemic situation. The first stage was in the right extremity, and the second was two weeks after the first operation. Operation preparation was conducted two days before surgery, including a PCR examination. During the operation, total scar excision in the genu area to the popliteal fossa area was as deep as the fascia so that the

genu ranged from 90° to a greater angle of $+140^{\circ}$. The defect was then closed with a skin graft with a donor from the right anterior femur. The total operation is about one hour. One day postoperatively, the patient was discharged, and an outpatient graft evaluation was performed on the 7th post-operative day. The results of the evaluation of the graft showed a take of 99%. Meanwhile, donor evaluation was carried out simultaneously with the second operation, which was carried out two weeks after the first operation.

The second stage of operation includes preparation for surgery which is carried out one day before surgery, and the operations are carried out for approximately two hours. This operation removes some scars from the genu area to the popliteal fossa with an incision as deep as the fascia. Scar liberation produces the same range of motion as the dextra extremity, from 90° to a larger angle of $+140^{\circ}$. Furthermore, the defect is closed with a skin graft with a donor from the left femur. Two days postoperatively, the patient was discharged, and the graft evaluation was performed

on the 5th post-hospital discharge day. The results of the graft evaluation showed that the graft take was 90%, and the donor evaluation was epithelialized on day 14th. The comprehensive treatment completing all stages of the operation takes about 1.5 months. Furthermore, the patient is suggested to follow the physiotherapy schedule for optimal results.

Case 3

A two-and-a-half-year-old child suffered burns on his left-hand fingers from burning plastic while playing. One month after treatment for burns, the injured third, fourth, and fifth fingers felt stiff to straighten, according to the patient's mother, and after three months, the fingers were hard to straighten. The examination results on the localized status showed a linear scar that was elongated and felt thick from the dip joint to the pip joint digits three-five. Subsequently, a plastic surgeon diagnosed the patient with a complete flexion contracture and a contracture release. Preparations were then carried out, including preparation for surgery and PCR one day before surgery. On the second day, the surgery was performed. During the operation, scar excision was performed on digit three-five as deep as the subcutis so the fingers could be extended maximally. The bulging defect was then closed with a graft with a donor from the left plantar pedis, as shown in **Figure 3**. The operation took approximately one hour. Then on the third day, the patient was sent home with education on grafts, and donor evaluation was carried out in an outpatient polyclinic. The results of the evaluation of grafts on the seventh day showed grafts with 100% take results. Donor evaluation was performed two weeks postoperatively, showing a small slough and some epithelial appearance. The donor wound healed within 4 weeks postoperatively. To optimize the results, physiotherapy was scheduled for up to three months, and the results were quite satisfactory, according to the parents.

DISCUSSION

The COVID-19 pandemic has disrupted routine physiotherapy procedures for burn patients. Physiotherapy is a component that can prevent scar formation and

contracture limitations.⁷ Post-burn contractures are a common complication in burn patients and usually involve moving parts of the body, such as the axilla and extremities. Extremity contractures after burns can significantly impact the quality of life by reducing the patient's ability to carry out his daily life, including at work.⁸ Persistent functional impairment indicates post-burn contracture treatment with surgical procedures.⁹ However, mature contracture scar tissue formation is considered a surgical procedure for contracture removal because releasing contractures in active scars can exacerbate contracture formation.¹⁰ In general, the principle of surgical management of post-burn contractures is to restore the shape and function to its original state as much as possible. Scar tissue that forms on the affected area should be removed and re-coated with soft tissue to allow proper movement and an aesthetic look.¹¹

Several methods can be used to reconstruct after the release of the contracture. A skin graft is still the most frequently used modality.¹¹ Skin grafting is a simple and efficient procedure for releasing the contracture scar. It is consistent with Bhatnagar and Singh's study, which stated that skin grafting is a simple, reliable, and safe operation technique with post-operative results both functionally and aesthetically.¹² Luo X et al. also stated that skin grafts have many advantages, such as easy manipulation, a small donor site, and a short duration of treatment.¹³ In line with Luo X et al., Samal CC et al. also stated that the average duration of the STSG fixation procedure was 34 minutes using the tie-over group method, it took seven minutes using a skin stapler, and 12 minutes for cyanoacrylate. In addition, the average graft reaches 90%.¹⁴ This advantage fits the pandemic atmosphere perfectly that requires medical personnel to minimize contact with patients.¹⁵

In India, 24 patients with post-burn contracture of fingers operated on using skin grafts showed good functional results and could return to work. However, patients who had finger flaps tended to be large and hyperpigmented. Therefore, Hariharan N et al. assume that skin grafts are better than flaps.¹⁶ Rajan M et al. stated

that 22 out of 25 cases who underwent skin graft for contracture release scar showed good surgical results. Three patients had minimal graft loss but did not require a surgical procedure and could heal the closure by dressings.^{17,18} Borse and Guin conducted a study of post-burn contractures in 38 patients who underwent skin grafting as a reconstruction modality in various body areas. A skin graft is an effective contracture treatment modality with a success rate of 89.5%. However, four cases experienced complications in the form of rejection and recontracture. Therefore, routine post-operative physiotherapy is needed because it helps prevent recontractures.¹⁹

Our limitations in these cases are the patients not fully compliant with the physiotherapy schedule. Sometimes patients obeyed the agenda, but others did not follow the physiotherapy plan. It could slow the healing process.

CONCLUSION

The case above shows that combining skin grafting and proper physiotherapy can be an effective post-burn contracture surgery technique suitable to be applied during the pandemic; that requires speed, accuracy, and safety and provides good results.

CONFLICT OF INTEREST

The authors declare that there is no conflict of interest.

ETHICAL CONSIDERATION

All of these patients signed the informed consent and were approved by The Ethical Committee of Jember Pulmonary Hospital No. 074/4033/102.6/2021.

FUNDINGS

This research didn't receive any specific grant from any funding agency in the public, commercial, or not-for-profit sectors.

AUTHOR CONTRIBUTION

Ulfa Elfiah acted as the main conceptor, organized the research method, wrote the main draft and evaluated it. David Sontani Perdanakusuma supported and developed the research methodology.

Iswinarno Doso Saputro supported the research method and edited the draft. Nyoman P Riasa supported the research method. Loelita M Lumintang supported the clinical aspect. Muhammad Fahmi Naufal supported the Ulfa Elfiah to treat the medication of the patient.

REFERENCES

1. Sarac BA, Schoenbrunner AR, Wilson SC, Chiu ES, Janis JE. The Impact of COVID-19-based Suspension of Surgeries on Plastic Surgery Practices: A Survey of ACAPS Members. *Plast Reconstr Surg - Glob Open*. 2020;8(8):1-6.
2. Fuertes V, Monclús E, Agulló A. Current impact of Covid-19 pandemic on Spanish plastic surgery departments: a multi-center report. *Eur J Plast Surg*. 2020;43(4):483-490.
3. Sison-Williamson M, Bagley A, Palmieri T. Long-term post-operative outcomes after axillary contracture release in children with burns. *J Burn Care Res*. 2012; 33(2):228-234.
4. Saaq M, Zaib S, Ahmad S. The menace of post-burn contractures: A developing country's perspective. *Ann Burns Fire Disasters*. 2012; 25(3):152-8.
5. Fufa DT, Chuang SS, Yang JY. Postburn contractures of the hand. *J Hand Surg Am*. 2014;39(9):1869-1876.
6. Seo DK, Kym D, Hur J. Management of neck contractures by single-stage dermal substitutes and skin grafting in extensive burn patients. *Ann Surg Treat Res*. 2014;87(5):253-259.
7. Walsh K, Nikkiah D, Dheansa B. Burn Scar Contractures & Their Management. *Plastic and Reconstructive Surgery*. 2013;3:25-31.
8. Pham TN, Goldstein R, Carrougher GJ, Gibran NS, Gerverman J, Esselman PC, et al. The impact of discharge contracture on return to work after burn injury: A Burn Model System investigation. *Burns*. 2020;46(3):539-545.
9. Dogra B, Kataria M, Kandari A, Ahmed S, Singh A, Virmani R. Management of postburn contractures of upper extremities: A general surgeon's perspective. *Indian J Burn*. 2016;24(1):29.
10. Hayashida K, Akita S. Surgical treatment algorithms for post-burn contractures. *Burn Trauma*. 2017;5:1-8.
11. Mujahid AM, Tarar FA, Khalid FA, Sajjad Y, Ishaque U, Tarar MN. Outcome of successful graft take of Integra and split thickness skin graft after the release of post-burn neck contracture. *Prof Med J*. 2021;28(01):106-112.
12. Bhatnagar A, Singh A. The postburn severe flexion contracture neck correction with split-thickness skin graft: Our experience. *Indian J Burn*. 2020;28(1):36.
13. Luo X, Liu F, Wang X, Yang Q, Wang S, Zhou X, et al. Region-oriented and staged treatment strategy in reconstruction of severe cervical contracture. *PLoS One*. 2015;10(4):e0122669.
14. Samal CC, Dash S, Agrawal K, Tandon R. Comparative evaluation of three methods of skin graft fixation for split thickness skin graft after release of post burn contracture of the neck. *Burns*. 2019;45(3):601-608.

15. Prabawa IMY, Silakarma D, Prabawa IPY, Manuaba IBAP. Physical Rehabilitation Therapy for Long COVID-19 Patient with Respiratory Sequelae: A Systematic Review. *Open Access Maced J Med Sci.* 2022;10(F):468-474.
16. Hariharan N, Sridhar R, Sankari B, Valarmathy VS, Asirvatham E, Geetha K. Reconstruction of postburn crippled hands: A study of functional outcome. *Indian J Burn.* 2018;26(1):9.
17. Rajan M, Tyagi A, Dvivedi S, Rawat KA. Management and outcome in patients with post burn contracture. *Int Surg J.* 2018;6(1):42.
18. Muhammad K, Prasetyo A, Prajoko YW, Najatullah N, Susilaningih N. Effectiveness of nanosilver collagen cream for healing deep dermal burns in Sprague Dawley rats: an overview of neutrophil counts and angiogenesis. *Bali Medical Journal.* 2021;10(2):648-652.
19. Borse HG, Guin AN. Study of Split Thickness Skin Grafting in Management of Post Burn Contracture. *MVP J Med Sci.* 2017;4:180-185.



This work is licensed under a Creative Commons Attribution

Skin graft as a modality reconstruction of post-burn contractures during pandemic area; case series

by Ulfa Elfiah

Submission date: 13-Feb-2023 10:39AM (UTC+0800)

Submission ID: 2012585386

File name: n_of_post-burn_contractures_during_pandemic_area_case_series.pdf (471.12K)

Word count: 3249

Character count: 17611

CASE REPORT

Bali Medical Journal (*Bali Med J*) 2023, Volume 12, Number 1: 244-248
P-ISSN:2089-1180, E-ISSN: 2302-2914



Skin graft as a modality reconstruction of post-burn contractures during pandemic era: case series



Ulfa Elfiah^{1,2}, David Sontani Perdanakusuma^{3*}, Iswinarno Dososaputra⁴,
I Nyoman Riasa⁴, Loelita Marcelia Lumintang⁵, Muhammad Fahmi Naufal⁶

ABSTRACT

Background: The Covid-19 pandemic causes the postponement of elective surgery. At the same time, patients with post-burn contractures require immediate operation due to impaired function that can lead to depression and disruption of daily life. Operations on contracture patients during a pandemic must be carried out using the principles of accuracy, speed, and safety. The skin graft is one of the most appropriate treatments modalities for releasing contractures. This case study aims to evaluate the skin graft as a modality reconstruction of post-burn contractures during pandemic era.

Case Presentation: We present three cases of post-burn contractures who underwent contracture release and skin graft surgery with a hospital stay of 3-5 days. Surgical results showed that graft take reached 90%-100% in all patients, and 100% epithelialization occurred at donor sites between 2-4 weeks postoperatively. There were no post-operative complications.

Conclusion: The skin graft is an effective and suitable technique for treating post-burn contractures in the pandemic era.

Keywords: Burn Wound, Contracture, Covid-19, Pandemic, Skin Graft.

Cite This Article: Elfiah, U., Perdanakusuma, D.S., Dososaputra, I., Riasa, I.N., Lumintang, L.M., Naufal, M.F. 2023. Skin graft as a modality reconstruction of post-burn contractures during pandemic era: case series. *Bali Medical Journal* 12(1): 244-248. DOI: 10.15562/bmj.v12i1.4003

¹Doctoral Program of Medical Science, Faculty of Medicine, Universitas Airlangga, Surabaya, Indonesia;

²Department of Reconstructive and Aesthetic Plastic Surgery, Dr. Soebandi Hospital, Faculty of Medicine, Universitas Jember, Jember, East Java, Indonesia;

³Department of Reconstructive and Aesthetic Plastic Surgery, Dr. Soetomo Hospital, Faculty of Medicine, Universitas Airlangga, Surabaya, Indonesia;

⁴Department of Reconstructive and Aesthetic Plastic Surgery, Prof. dr. I.G.N.G. Ngoerah Hospital, Faculty of Medicine, Universitas Udayana, Denpasar, Indonesia;

⁵Department of Reconstructive and Aesthetic Plastic Surgery, Sajiwani Hospital, Faculty of Medicine, Universitas Udayana, Denpasar, Indonesia;

⁶Faculty of Medicine, Universitas Jember, Jember, East Java, Indonesia;

*Corresponding author:
David Sontani Perdanakusuma;
Department of Reconstructive and Aesthetic Plastic Surgery, Dr. Soetomo Hospital, Faculty of Medicine, Universitas Airlangga, Surabaya, Indonesia;
dperdanakusuma@ff.unaii.ac.id

Received: 2022-11-15

Accepted: 2022-12-18

Published: 2023-01-11

INTRODUCTION

The spread of the Covid-19 virus throughout the world has caused changes in the treatment system for patients. Various procedures and services, especially elective case operations, have been reduced or stopped.¹ This is because most hospital beds have been converted into isolation rooms and the relocation of human resources for the Covid-19 situation.² This treatment change is also felt by plastic surgery patients, including post-burn contracture patients. Patients cannot perform medical rehabilitation treatment optimally to increase the risk of impaired function. After two years of the pandemic, experts must consider strategies for handling non-covid patients to prevent more severe complications. The most straightforward operating technique, which is fast and beneficial, must be selected as the definitive treatment.

Defect closure of contracture cases aims to restore the function of body structures according to their anatomical position. Surgical techniques of wound closure are based on the algorithm of wound closure. However, during a pandemic, a surgical process shall not require prolonged physical contact with the patient. Therefore, the skin graft technique of wound closure shall be

considered. Sison-Williamson M et al. showed that axillary contracture surgery with skin grafts improved shoulder function in the short and long term.³

In line with Sison, Saaq M et al. stated that 191 patients with skin graft surgery showed satisfactory restoration of function.⁴ Fufa DT et al. found that 90% of post-burn contractures of the patient's hand undergoing complete scar excision and full-thickness skin graft (FTSG) can fully flex the metapalange (MP) within six months.⁵

In addition, Seo DK et al. showed a decrease in Vancouver scar scale (VSS) scores after one year of split-thickness skin graft (STSG) surgery with dermal substitutes. However, 27 of 28 patients showed excellent or good long term outcomes such as improved function and cosmetic skin texture.⁶

This report aims to present the method we use to release severe post-burn contracture without using a flap technique that takes longer time and increases the risk exposed to COVID-19.

CASE PRESENTATION

Case 1

A 35-year-old man was hospitalized one year ago due to an electrical burn at work. Surgery

and wound care were performed for 1 month, followed by physiotherapy for six months. However, due to the pandemic, the patient has never done therapy routinely. In the last three months, he complained of stiffness in the elbow joint and limited range of motion. The results of the local status examination on the patient's right superior extremity showed a hypertrophic scar that spread from the lateral side of the brachial to the ulnar side of the antebrachial. The appearance of a hypopigmented scar extends from the right anterior thorax to the antebrachial region, as seen in [Figure 1a](#). Flexion and extension of the fingers are normal, and abduction and adduction movements of the axilla are also normal. The patient was diagnosed with severe contracture and decided to perform contracture release and closure of the defect with a skin graft by a plastic surgeon. For the optimization of post-operative function, physiotherapy is planned. During the operation, scars were as deep as the subcutis, and ankylosis was found in the joints when moved. Post-excision defects were approximately 20 x 15 cm in size and were covered with skin grafts from the right femur donor skin, as seen in [Figure 1b](#). The total length of operation was one hour. The post-operative care was carried out for one day for post-operative pain after surgery, and the graft and treatment were evaluated five days after the patient left the hospital. This patient's total length of treatment consisted of one day for preparation for surgery, including a Polymerase Chain Reaction (PCR) examination, one day of surgery, and one day of post-operative care. The graft evaluation showed that 100% graft was taken, while the evaluation of the donor performed two weeks postoperatively showed 100% epithelialization. The patient could carry out daily activities well one month after surgery, as seen in [Figure 1c](#). Physiotherapy continued after three months to get optimal results.

Case 2

A five-year-old child had a history of burns due to a hot water spill six months earlier. The patient had a history of refusing to treat wounds in a hospital and chose to be treated alone. The wound had not dried three months after treatment

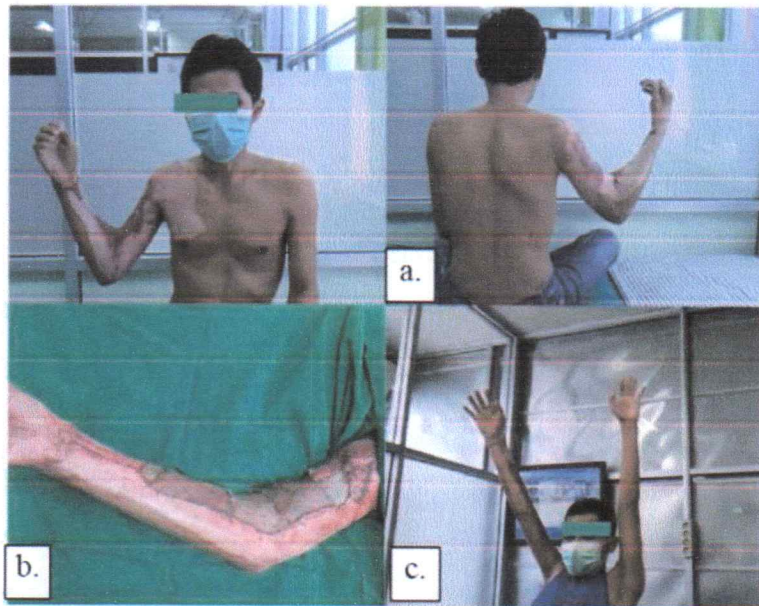


Figure 1. Contracture (a) preoperative: a hypertrophic scar with a hypopigmented scar that spread from the anterior thorax, lateral side of the brachial to the ulnar side of the antebrachial right; (b) post-operative: post-burn contracture was released and was covered with skin graft ; (c) 1 month post-operative: the patient was able to carry out daily activities well.

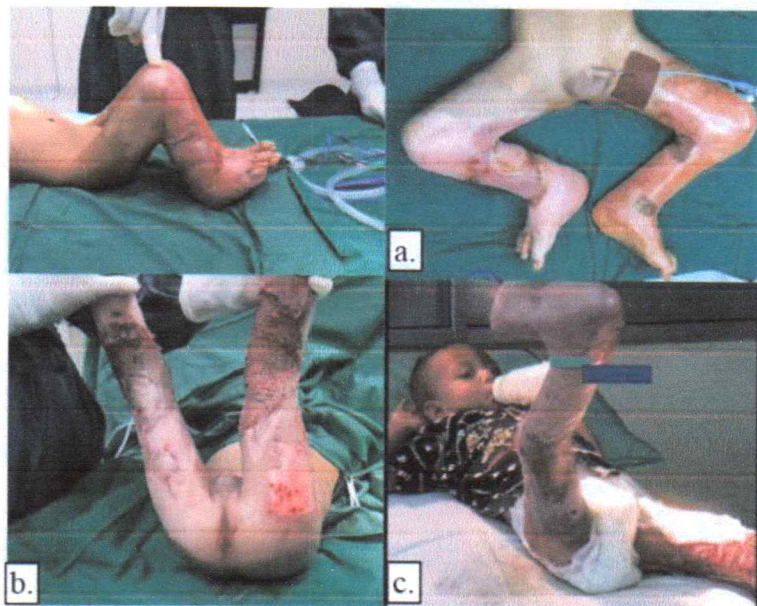


Figure 2. Contracture (a) preoperative: Thickened and widespread scar tissue on the right and left lower extremities; (b) post-operative: post-burn contracture was released and was covered with skin graft; (c) four weeks postoperatively, the patient can perform lower extremity elevation.

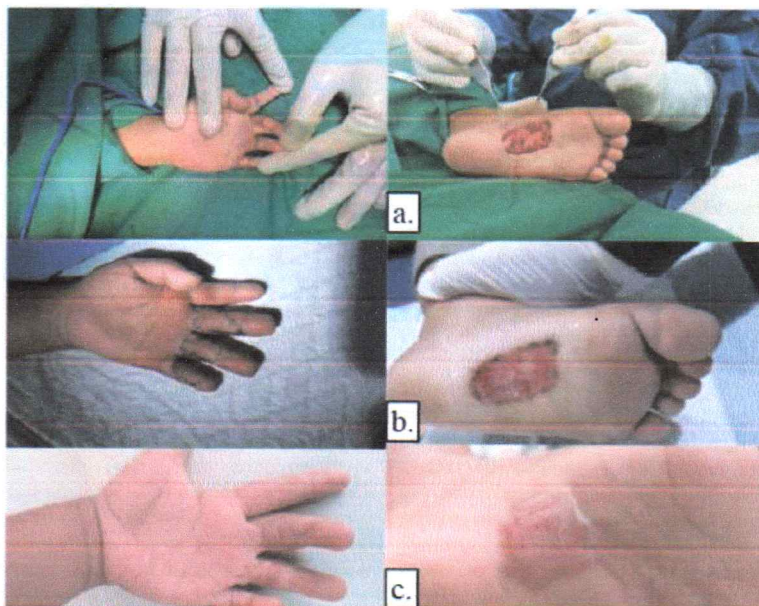


Figure 3. Contracture (a) preoperative: a linear scar from the dip joint to the pip joint digits three-five and donor removal from plantar pedis; (b) two weeks postoperatively: The grafts with 100% take results, and donor site showed a small slough and some epithelial; (c) The wound closed well 6 months after the surgery.

and showed signs of stiffness. Six months later, the patient's right and left legs and toes cannot be straightened, and the movement is limited. The results of the local status examination can be seen in [Figure 2](#), on the right extremity showed thickened and widespread scars on the entire lower extremity, limited movement, flexion contractures in the genu region and dorsiflexion contractures on the dorsum pedis. The left extremity shows the same localized status as the right; only the scars arise from 1/3 of the femur to the toes. The patient was diagnosed with severe genu contracture, and a plastic surgeon performed a contracture release.

In this patient, the contracture release was carried out in some stages with consideration of pediatric patients and the pandemic situation. The first stage was in the right extremity, and the second was two weeks after the first operation. Operation preparation was conducted two days before surgery, including a PCR examination. During the operation, total scar excision in the genu area to the popliteal fossa area was as deep as the fascia so that the

genu ranged from 90° to a greater angle of $+140^\circ$. The defect was then closed with a skin graft with a donor from the right anterior femur. The total operation is about one hour. One day postoperatively, the patient was discharged, and an outpatient graft evaluation was performed on the 7th post-operative day. The results of the evaluation of the graft showed a take of 99%. Meanwhile, donor evaluation was carried out simultaneously with the second operation, which was carried out two weeks after the first operation.

The second stage of operation includes preparation for surgery which is carried out one day before surgery, and the operations are carried out for approximately two hours. This operation removes some scars from the genu area to the popliteal fossa with an incision as deep as the fascia. Scar liberation produces the same range of motion as the dextra extremity, from 90° to a larger angle of $+140^\circ$. Furthermore, the defect is closed with a skin graft with a donor from the left femur. Two days postoperatively, the patient was discharged, and the graft evaluation was performed

on the 5th post-hospital discharge day. The results of the graft evaluation showed that the graft take was 90%, and the donor evaluation was epithelialized on day 14th. The comprehensive treatment completing all stages of the operation takes about 1.5 months. Furthermore, the patient is suggested to follow the physiotherapy schedule for optimal results.

Case 3

A two-and-a-half-year-old child suffered burns on his left-hand fingers from burning plastic while playing. One month after treatment for burns, the injured third, fourth, and fifth fingers felt stiff to straighten, according to the patient's mother, and after three months, the fingers were hard to straighten. The examination results on the localized status showed a linear scar that was elongated and felt thick from the dip joint to the pip joint digits three-five. Subsequently, a plastic surgeon diagnosed the patient with a complete flexion contracture and a contracture release. Preparations were then carried out, including preparation for surgery and PCR one day before surgery. On the second day, the surgery was performed. During the operation, scar excision was performed on digit three-five as deep as the subcutis so the fingers could be extended maximally. The bulging defect was then closed with a graft with a donor from the left plantar pedis, as shown in [Figure 3](#). The operation took approximately one hour. Then on the third day, the patient was sent home with education on grafts, and donor evaluation was carried out in an outpatient polyclinic. The results of the evaluation of grafts on the seventh day showed grafts with 100% take results. Donor evaluation was performed two weeks postoperatively, showing a small slough and some epithelial appearance. The donor wound healed within 4 weeks postoperatively. To optimize the results, physiotherapy was scheduled for up to three months, and the results were quite satisfactory, according to the parents.

DISCUSSION

The COVID-19 pandemic has disrupted routine physiotherapy procedures for burn patients. Physiotherapy is a component that can prevent scar formation and