



8

**UNIVERSITAS AIRLANGGA**  
**FAKULTAS KEDOKTERAN**  
**DEPARTEMEN BEDAH PLASTIK REKONSTRUKSI DAN ESTETIK**  
Jalan Mayjen.Prof.Dr.Moestopo 47 Surabaya 60131 Telp. (031) 5020251, Fax (031) 5022472 Website : <http://www.fk.unair.ac.id> – E-mail : [dekan@fk.unair.ac.id](mailto:dekan@fk.unair.ac.id)

**HASIL VALIDASI DAN PENILAIAN**  
**KARYA ILMIAH DOSEN FAKULTAS KEDOKTERAN UNIVERSITAS AIRLANGGA**  
**(MEDIA PUBLIKASI KARYA ILMIAH : JURNAL ILMIAH NASIONAL)**  
**NOMOR : 037 /UN3.1. 1/BPRE/ II / 2023**

**FORM 15**

**A. Identitas Karya Ilmiah**

Judul Jurnal Ilmiah (Artikel) : **Keloid and Hypertrophic Scar Post-Excision Recurrence : A Retrospective Study**

Jumlah penulis : 4 (empat) penulis , Alya Mutiara Azzahra<sup>1</sup>, David Sontani Perdanakusuma<sup>2,4\*</sup>, Diah Mira Indramaya<sup>3,4</sup> , Iswinarno Doso Saputro<sup>2,4</sup>

Status Pengusul : Penulis ke 4

Identitas Jurnal Ilmiah

- Nama Jurnal : Lingkar Studi Bedah Plastik Foundation
- Nomor ISSN : . 2089-9734, 2089-6497
- Volume, Nomor, bulan, tahun: 9 / 2 / September 2022
- Penerbit : FK Unair
- DOI artikel :
- Alamat web Jurnal :  
<https://www.jpjournal.com/index.php/jpr/article/view/343/260>

**B. Kategori Publikasi Jurnal Ilmiah**  
(beri ✓ pada kategori yang tepat)

<input type="checkbox"/>	Jurnal Nasional Terakreditasi (peringkat 1 dan 2)
<input type="checkbox"/>	Jurnal Nasional Bahasa Inggris terindeks (peringkat 3 dan 4)
<input type="checkbox"/>	Jurnal Nasional Bahasa Indonesia terindeks (peringkat 5 dan 6)
<input checked="" type="checkbox"/>	Jurnal Nasional (diluar peringkat 1-6)

**C. Hasil Validasi Ketua Departemen**

Telah diperiksa dan divalidasi dengan baik, dan sampai pernyataan ini dibuat sebagai karya ilmiah **original / ~~plagiat~~\***, sehingga kami turut bertanggung jawab bahwa karya ilmiah tersebut telah memenuhi syarat kaidah ilmiah, norma akademik, dan norma hukum, sesuai dengan Peraturan Menteri Pendidikan Nasional Nomor 17 Tahun 2010 tanggal 16 Agustus 2010 tentang Pencegahan dan Pananggulangan Plagiat di Perguruan Tinggi. Namun demikian, apabila di kemudian hari ternyata terbukti bahwa karya ilmiah tersebut merupakan karya Ilmiah Plagiat, maka akan menjadi tanggung jawab mutlak penulis tersebut di atas, baik secara perdata maupun pidana. Demikian surat pernyataan ini saya buat untuk dipergunakan sebagaimana mestinya.

Surabaya, 10 Februari 2023

Ketua Departemen  
Bedah Plastik Rekonstruksi dan Estetik

Prof.Dr.David S. Perdanakusuma, dr.,SpBP-RE(K)  
NIP. 19600305 198901 1 002

## Form Penilaian Kualitas Karil dan Kesesuaian Bidang Ilmu

Profil Sinta : Link Sinta <https://sinta.kemdikbud.go.id/profile>

A		Identitas Karya Ilmiah
1	Judul :	Keloid and Hypertrophic Scar Post-Excision Recurrence : A Retrospective Study
2	Nama Penulis :	Alya Mutiara Azzahra <sup>1</sup> , David Sontani Perdanakusuma <sup>2,4*</sup> , Diah Mira Indramaya <sup>3,4</sup> , Iswinarno Doso Saputro <sup>2,4</sup>
3	Nama Jurnal :	Jurnal Plastik Rekonstruksi
B		Peng-index : Jurnal Internasional Bereputasi
		Vol.9, No.2.,ISSN. 58-63 September 2022 Publisher : Lingkar Studi Bedah Plastik Foundation
C		Relevansi kompetensi dosen dengan substansi karya ilmiah
		<ol style="list-style-type: none"> <li>1. Artikel ini suatu studi deskriptif restrospektif yang mengevaluasi pasien bekas luka abnormal pasca eksisi dari tahun 2018 hingga 2020 dengan tujuan untuk menentukan kejadian kekambuhan skar abnormal untuk mendukung penelitian selanjutnya.</li> <li>2. Artikel ini sesuai dengan bidang keahlian pengusul yaitu <b>Luka Bakar</b></li> <li>3. Tidak ada keterkaitan dengan naskah Disertasi pengusul yang berjudul : <b>Mekanisme Hambatan Deposisi Kolagen Tipe I pada Luka Bakar Derajat 2 Dalam Yang diberi Ekstrak Buah Delima Terstandar pada Tikus Putih (Rattus norvegicus)</b></li> </ol>
D		Kesesuaian antara lingkup / subjek area jurnal dengan karya ilmiah yang diusulkan
		<ol style="list-style-type: none"> <li>1. Alamat Web Jurnal : <a href="https://www.jpjournal.com/index.php/jpr/article/view/343/260">https://www.jpjournal.com/index.php/jpr/article/view/343/260</a></li> <li>2. Kebenaran ISSN :</li> <li>3. Termasuk "Predatory" tidak (jurnal; penerbit) : <b>tidak masuk pada predatory</b></li> <li>4. Syarat komposisi Editor Board : - <b>lebih dari negara</b></li> <li>5. Syarat kontributor penulis artikel : <b>Penulis anggota</b></li> <li>6. Keberkalaan penerbitan : - terbitan pertahun</li> <li>7. Subjek area dan katagori jurnal : -</li> </ol>
E		Kepastian tidak ada pelanggaran integritas akademik
		<ol style="list-style-type: none"> <li>1. Indikasi plagiasi (lihat check similarity) : Similarity</li> <li>2. Artikel tidak ada indikasi plagiasi.</li> <li>3. Fabrikasi : <b>Tidak ada</b></li> <li>4. Falsifikasi : <b>Tidak ada</b></li> <li>5. Praktek kepalsuan : <b>Tidak ada</b></li> </ol>
		Nilai pengusul (penulis pertama dan corespondensi 60% )
		Nilai pengusul (penulis pertama / penulis corespondensi masing - masing 40%)
		Nilai lainnya sesuai PO PAK 2019 dan suplemennya

Surabaya,  
Penilai Angka Kredit 1

Nama :  
NIP :  
Bidang Ilmu :  
Unit Kerja :

Article

## KELOID AND HYPERTROPHIC SCAR POST-EXCISION RECURRENCE: A RETROSPECTIVE STUDY

Alya Mutiara Azzahra<sup>1</sup>, David Sontani Perdanakusuma<sup>2,4\*</sup>, Diah Mira Indramaya<sup>3,4</sup>, Iswinarno Doso Saputro<sup>2,4</sup>

1. Medical Program, Faculty of Medicine Universitas Airlangga, Surabaya, Indonesia

2. Department of Plastic, Reconstructive, and Aesthetic Surgery, Faculty of Medicine Universitas Airlangga, Surabaya, Indonesia

3. Department of Dermatology and Venearology, Faculty of Medicine Universitas Airlangga, Surabaya, Indonesia

4. Dr. Soetomo General Academic Hospital, Surabaya, Indonesia

### ABSTRACT

**Introduction :** Abnormal scar recurrence can occur and often be greater than pre-excision because the recurrence rate is giving a high percentage. Data about keloid and hypertrophic scar recurrence are rarely found in Indonesia. Therefore, it is necessary to conduct research related to abnormal scar, aims to determine the incidence of abnormal scar recurrence to support future research by giving valuable data.

**Method :** A retrospective descriptive study that evaluated post-excision abnormal scar patients from 2018 to 2020 using medical records.

**Result :** The sixteen cases had varied by age with the highest number of presentations in the late adolescence (17-25 years) (31%). Comparison of male (56%) and female (44%) patients were 1.28:1. The distribution of patients with recurrence of abnormal scars based on the type of abnormal scar found that 11 patients (69%) had keloids and the rest had hypertrophic scars with a total of 5 patients (31%) with predominantly ear (38%). Strategies of therapy most commonly excision only (50%), followed by excision with steroid injection combination (31%).

**Conclusion:** This exemplifies recurrence case in post-excision abnormal scar. Our findings indicate that there are differences in surgical strategy, such as wound closure techniques. Most of them were found with keloid scars and the incidence of recurrence was 11 cases and 5 cases experienced more than 1 recurrence. Furthermore, combination therapy, such as steroid injection, which is the most commonly used therapy after excision in this case, did not appear to prevent recurrence.

**Key Words:** Keloid; Cicatrix, Hypertrophic; Recurrence; Scar; Scar Revision

**Latar Belakang:** Kekambuhan bekas luka abnormal dapat terjadi dan seringkali lebih besar dari pra-eksisi karena tingginya tingkat kekambuhan. Data tentang keloid dan kekambuhan skar hipertrofi masih jarang ditemukan di Indonesia. Oleh karena itu, perlu dilakukan penelitian terkait skar abnormal, bertujuan untuk menentukan kejadian kekambuhan skar abnormal untuk mendukung penelitian selanjutnya dengan memberikan data yang berharga.

**Metodologi:** Sebuah studi deskriptif retrospektif yang mengevaluasi pasien bekas luka abnormal pasca eksisi dari tahun 2018 hingga 2020 menggunakan rekam medis.

**Hasil:** Enam belas kasus bervariasi berdasarkan usia dengan jumlah presentasi tertinggi pada remaja akhir (17-25 tahun) (31%). Perbandingan pasien laki-laki (56%) dan perempuan (44%) adalah 1,28:1. Distribusi pasien dengan kekambuhan skar abnormal berdasarkan jenis skar abnormal didapatkan 11 pasien (69%) mengalami keloid dan sisanya mengalami skar hipertrofik dengan total 5 pasien (31%) dengan area dominan telinga (38%). Strategi terapi yang paling banyak adalah eksisi saja (50%) dan diikuti eksisi dengan injeksi steroid kombinasi (31%).

**Kesimpulan:** Studi ini mencontohkan kasus kekambuhan pada bekas luka abnormal pascaeksisi. Temuan kami menunjukkan bahwa ada perbedaan dalam strategi bedah, seperti teknik penutupan luka. Sebagian besar ditemukan bekas luka keloid dan kejadian kekambuhan sebanyak 11 kasus dan 5 kasus mengalami kekambuhan lebih dari 1 kali. Selanjutnya, terapi kombinasi, seperti injeksi steroid, yang merupakan terapi yang paling umum digunakan setelah eksisi, tidak mencegah kekambuhan dalam kasus ini.

**Kata Kunci:** Keloid; Cicatrix, Hipertrofik; Kambuh; Bekas luka; Revisi Bekas Luka

### Conflicts of Interest Statement:

The author(s) listed in this manuscript declare the absence of any conflict of interest on the subject matter or materials discussed.

Received: 31-10-2022, Revised: 18-12-2022, Accepted: 25-12-2022

Copyright by Azzahra et al (2022). | P-ISSN 2089-6492; E-ISSN 2089-9734 | DOI: 10.14228/jprjournal.v9i2.343

Published by Lingkar Studi Bedah Plastik Foundation. This is an open-access article distributed under the terms of the Creative Commons Attribution-Non Commercial-No Derivatives License 4.0 (CCBY-NC-ND), where it is permissible to download and share the work provided it is properly cited. The work cannot be changed in any way or used commercially without permission from the journal. This Article can be viewed at [www.jprjournal.com](http://www.jprjournal.com)

## INTRODUCTION

The skin is the most traumatized or injured tissue. A trauma frequently results in scarring and incomplete restoration of the previous architecture. The skin's vulnerability to trauma makes the skin also vulnerable to the occurrence of a wound often referred to as scars. In scars, there are changes in the structure of the skin which include loss of pores, hair, and glands, followed by discoloration of hypopigmentation or hyperpigmentation.<sup>(1)</sup> Wounds that can leave scars are wounds that are deeper than the entire thickness of the skin (full thickness). Scarring is a normal physiological process that occurs in the body to repair the damage, but under certain conditions, an abnormal wound healing process can occur which results in an abnormal scar profile. The growth of abnormal scars can contribute to a decrease in the quality of life (QoL) of patients because they experience discomfort from the physical, aesthetic, and psychosocioeconomic aspects.

In developing countries, there are 100 million patients with complaints of abnormal scarring every year. Approximately 55 million cases of scarring occur due to elective surgeries and 25 million cases of scarring occur in trauma surgeries.<sup>(2)</sup> Any damage or abnormality in the wound healing process causes the abnormal scars. Clinically, scars are divided into two major categories: normal or normotrophic scars and abnormal or pathological scars, classified as hypertrophic scars and keloid.

Hypertrophic scars can be defined as abnormally large scars that are still confined to the traumatized area. While keloid scars are scars that are abnormally formed and grow horizontally, i.e., outside the boundaries of the wound or trauma experienced. Collagen synthesis is increased in keloids twenty times greater while hypertrophic scars are three times greater than normal physiological scars. Treatment of abnormal scars can be done with surgical and non-surgical therapies. Despite the differences in pathophysiological factors in the two types of abnormal scarring, keloids have a lower rate of repair and a higher rate of recurrence after treatment despite surgical excision and therefore need to be monitored closely. Excision therapy alone has recurrence rates of 50% and even 40-100%.<sup>(3)(4)</sup> The recurrence of abnormal scars can be minimized

by reducing preventable risk factors such as appropriate surgical techniques and/or multimodality therapies.

Data about keloid and hypertrophic scar recurrence are rarely found in Indonesia and until now, the incidence of recurrence in Dr. Soetomo General Hospital has not found any related research. This is important to be analyzed in order to achieve better scar management that will help reduce the recurrence that occurs in trauma patients, with or without abnormal scars, to prevent abnormal scars and support future researches by giving valuable data.

## METHOD

This was a descriptive study with a retrospective approach based on medical records in patients with abnormal scar recurrence in the Department of Plastic, Reconstructive, and Aesthetic Surgery, Dr. Soetomo General Hospital, and has been reviewed and approved by Dr. Soetomo General Hospital Ethical Committee (0644/LOE/301.4.2/X/2021). This study used a total sampling technique to collect data from a population that met the inclusion criteria by using medical record data from all patients with history of abnormal scars who had scar revision with surgical treatment at Dr. Soetomo General Hospital plastic surgery outpatient clinic from 2018 to 2020. Gender, age, recurrence, abnormal scar type, location, and therapy were the variables used in this study. All cases were obtained based on the variables studied, processed, and then presented as tables and subsequent diagrams in Microsoft Excel and descriptively analyzed.

## RESULTS

This research obtained 16 cases which were qualified for the inclusion criteria in total over the period of 2018–2020 in the Department of Plastic, Reconstructive, and Aesthetic Surgery, Dr. Soetomo General Hospital outpatient clinic.

Table 1 showed that the distribution of patients with recurrence of abnormal scarring by age category varied according to the Ministry of Health of the Republic of Indonesia in 2009. It was found that the mean age obtained was 29.6 which was included in early adulthood (26-35 years).

Most patients were in the late adolescent age (17-25 years) (31%). The lowest number in this study was in the age range of children (6-11 years) with 1 patient (6%). From the data studied, it was found that children aged 6 years was the youngest and adults aged 70 years was the oldest.

Table 1. Demographics of abnormal scar recurrence patients by age

Age Distributions	Frequency (n)	Percentage (%)
Toddler (0-5 years)	0	0
Children (6-11 years)	1	6
Early teens (12-16 years)	4	25
Late adolescence (17-25 years)	5	31
Early adulthood (26-35 years)	0	0
Late adulthood (36-45 years)	2	13
Early elderly (46-55 years)	1	6
Late elderly (56-65 years)	2	13
Seniors (>65 years)	1	6
Total	16	100

Figure 1 depicted the gender distribution of abnormal keloid scars and hypertrophic scars in this study mostly male patients with a slight difference between male (9 patients) and female (7 patients) with a ratio of 1.28:1.

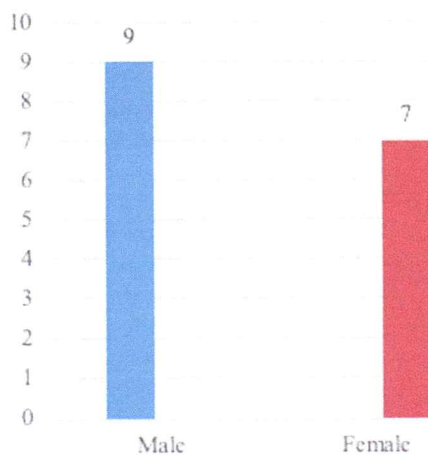


Figure 1. The gender distribution of abnormal scar recurrence patients

According to Table 2, the distribution of abnormal scar recurrence patients by abnormal scar type showed that keloids were observable in 8 of 13 patients (69%) and hypertrophic scars were presented in the remaining 5 patients (31%). Patients who had an abnormal scar recurrence

between 2018 and 2020 were more likely to develop keloid abnormal scar formation.

Table 2. Distribution of abnormal scar recurrence patients based on type of scar

Abnormal Scar Type	Frequency (n)	Percentage (%)
Hypertrophic scar	5	31
Keloid	11	69
Total	16	100

Table 3 showed that the ear had the most recurrence of abnormal scarring, with a total of six patients (38%) of the sixteen patients studied, and the least was one case on the arm, abdomen, and palm, respectively (6%).

Table 4 showed that 11 of 16 patients had abnormal scar recurrence after undergoing excisional therapy, and 5 of 16 patients had abnormal scar re-recurrence with 1 of 5 patients having at most 5 (five) recurrences after abnormal scar revision with a general surgeon in the previous hospital and at the same scar site.

Table 3. Distribution of abnormal scar locations in abnormal scar recurrence patients

Location	Frequency (n)	Percentage (%)
Face	4	25
Ear	6	38
Chest	3	19
Arm	1	6
Abdomen	1	6
Palm	1	6
Total	16	100

Table 4. Incidence of recurrence and re-recurrence of patients with abnormal scar

Recurrence Incidence	Frequency (n)	Percentage (%)
1x	11	69
>1x	5	31
Total	16	100

Table 5 showed the treatment strategies used are (i) excision alone (n = 8), (ii) excision with intralesional injection of triamcinolone acetonide/steroid (n = 5), (iii) excision with injection without data/nonspecific (n = 2), and (iv) excision with a combination of intralesional injection of triamcinolone acetonide, intralesional injection of 5-fluorouracil, and laser therapy. There were technical aspects of the surgical technique procedure with skin flap, split-thickness skin graft (STG), and full-thickness skin graft (FTG) in 4 out of 16 patient cases. A total of

12 of the 16 patients underwent abnormal scar excision procedures with a plastic surgeon at the Plastic, Reconstructive, and Aesthetic Surgery, Dr. Soetomo General Hospital polyclinic with the remaining two of the four other patients undergoing excision with a general surgeon at the previous hospital and the final two patients undergoing excision with no surgeon information at the previous hospital.

**Table 5.** Abnormal scar recurrence based on treatment group

Treatment Group	Frequency (n)	Percentage (%)
Excision only	8	50
Excision + Steroid	5	31
Excision + Injection (nonspecific)	2	13
Excision + Steroid + 5-FU	1	6
Injection + Laser		
Total	16	100

5-FU = 5-Fluorouracil

## DISCUSSION

Based on data collected in the Plastic Surgery Outpatient Unit at Dr. Soetomo General Hospital in Surabaya, Indonesia, between 2018 and 2020, male patients had more abnormal scars in this study, despite a slight difference between male and female patients with a ratio of 1.28:1. Male patients presented with abnormal scarring due to ear piercing, burns, work accidents, motorcycle accidents, or trauma to the face, according to the causes of abnormal scarring in the sixteen cases. Meanwhile, female patients are more likely to have abnormal scarring as a result of ear piercing and cosmetic needs. The findings of female and male are not significantly different.<sup>(2)(5)</sup>

The structure of the skin differs between male and female, as does the collagen thickness, which is more predominant in male.<sup>(6)</sup> This can support the percentage of male who are more prone to abnormal scarring than female. The abnormal scar formation process is based on an abnormal process of collagen formation in the skin, which causes collagen dysregulation, that further eventually leads to scarring.

In accordance to the research results, the highest number of patients were in late

adolescence, and the average number of patients aged 30 years was consistent with previous research, namely the highest prevalence was in patients under the age of 30 years.<sup>(2)(7)</sup> Adolescent skin is still relatively tense and has higher collagen synthesis than elderly.<sup>(7)</sup> The adolescent age range is included in the productive age range (15-65 years), indicating that patients in this age range are more likely to be curious, try new things, participate in activities, and work optimally. According to the case, most of the patients in this study developed abnormal scars as a result of burns caused by work accidents, ear piercing, or traffic accidents. The skin has a high level of elasticity in the adolescent age range, which will affect the high tension, which is also one of the causes of abnormal scars.

Keloids were found more frequently than hypertrophic scars in the results of this study, with 11 patients out of a total of 16 cases. The incidence of hypertrophic scars after surgery is around 39-68%,<sup>(2)</sup> whereas keloids can reach 40-100%.<sup>(4)</sup> Keloids have a high recurrence rate after attempted excision and are more difficult to treat than hypertrophic scars,<sup>(8)</sup> so they will be encountered frequently due to their very high recurrence rate and low therapeutic efficacy. One of the factors that contribute to the recurrence of abnormal scars is the abnormal location of the scar, which includes the ear and chest area.<sup>(2)(9)</sup>

The most typical places for keloids to appear are on the chest, face, and ears. Meanwhile, the arms, palms, and abdomen were the least affected. There is more collagen and extracellular matrix (ECM) at the keloid predilection site. Fibroblasts migrate by adhering to the ECM and then descending and reorienting it. During the fibroblast proliferation phase, skin defects will start appearing in the form of immature scars. At this stage, the cell components are dominated by fibroblasts, which will proliferate and synthesize collagen. A high concentration of collagen in the keloid predilection area can change the behaviour of fibroblasts, establishing the foundation for keloid formation and growth.

In this study, cases were chosen based on previous surgical excision of the keloid, so that all cases of the patient had undergone surgery.

This study discovered 11 patients who had one recurrence and 5 patients who had recurrences. There were 4 cases underwent revision scar surgery at the previous hospital before being referred to a plastic surgery unit at Dr. Soetomo General Hospital, and two of them contained information if they had undergone surgery with a general surgeon with three recurrences and five recurrences, respectively, which were the highest rates of recurrence of abnormal scars. This could be due to the operator's lack of attention to detail in technical aspects of the surgical procedure, such as technique and instrument selection, because it may contributed to the recurrence of abnormal scarring and simple excision procedure can stimulate additional collagen synthesis.<sup>(10)</sup>

Excision with corticosteroid injection was the most preferred therapy in this study, aside from excision alone. Triamcinolone acetonide (TAC), a corticosteroid, is thought to suppress inflammation, degeneration, and collagen production. Despite the easy of use and high tolerance level of TAC injection, it still has a recurrence rate of 9-50%.<sup>(10)</sup> In this study, one patient received multiple therapies, including TAC injection with a combination of 5-fluorouracil (FU) injection and Er:YAG laser. TAC and 5-FU injections increase the potency of corticosteroids in TAC injections, and the combination of laser and corticosteroids reduces recurrence rate to 16-74%.<sup>(2)</sup> In this study, the two treatment groups had no effect on the inhibition of recurrence in abnormal scars. Approximately 50% of keloids were steroid-resistant, and 9-50% of keloids that initially responded to TAC treatment eventually relapsed or recurred,<sup>(11)</sup> and patients who received surgical excision alone or surgical excision combined with other non-surgical treatment modalities had the same recurrence rate.<sup>(12)</sup>

## CONCLUSION

Treatment of abnormal scars after excision is a complex challenge with a high recurrence rate. According to our findings, patients with abnormal scar recurrence were more likely to be male, with mean age of 29.6, more likely to be in late adolescence, and the most common site for

abnormal scarring was in the ear, chest, and face. Data from this study had keloids rather than hypertrophic scars, with 11 recurrence incidents and 5 cases with multiple recurrences out of a total of 16 cases, and TAC was the most commonly used therapy after excision in this case. Data from this study suggest that there are differences between excision with a general surgeon and a plastic surgeon related to the surgical strategy, wound closure techniques, and surgical instruments. Future research will investigate into the role of abnormal scar scores, such as the Vancouver Scar Scale, in determining whether the therapy is effective. It would be plausible since it would be easier to assess what to intervene under certain patients with different risk factors.

## ACKNOWLEDGEMENT

The authors would like to thank the Director of Dr. Soetomo General Hospital and Department of Plastic Reconstructive and Aesthetic Surgery Dr. Soetomo General Hospital for supporting this research.

### Correspondence regarding this article should be addressed to:

David Sontani Perdanakusuma. Department of Plastic, Reconstructive, and Aesthetic Surgery, Faculty of Medicine, Universitas Airlangga, Surabaya, Indonesia  
E-Mail: dperdanakusuma@yahoo.com

## REFERENCES

1. Perdanakusuma DS. Scars, The Surgeons' Overlooked Threat From Hero to Zero. *J Plast Rekonstruksi*. 2013;2(3):110-3.
2. Perdanakusuma, D.S. *Penanganan Parut Hipertrofik dan Keloid*. 2nd ed. Surabaya: Airlangga University Press; 2017.
3. Froelich K, Staudenmaier R, Kleinsasser N, Hagen R. Therapy of auricular keloids: Review of different treatment modalities and proposal for a therapeutic algorithm. *Eur Arch Oto-Rhino-Laryngology*. 2007;264(12):1497-508.
4. Rasheed IA, Malachy AE. The Management of Helical Rim Keloids with Excision , Split Thickness Skin Graft and Intralesional Triamcinolone Acetonide. *J Cutan Aesthet Surg*. 2014;7(1):51-3.
5. Shaheen A, Khaddam J, Kesh F. Risk factors of keloids in Syrians. *BMC Dermatol*.



- 2016;16(13):1-11.
6. Thomason HA, Williams H, Hardman MJ. Sex and Sex Hormones Mediate Wound Healing. In: Klein SL, Roberts CW, editors. Sex and Gender Differences in Infection and Treatments for Infectious Diseases. Cham: Springer International Publishing Switzerland; 2015. p. 31-48.
  7. Abdallah M, Yassin M, Saber N. Dermoscopic Features of Keloid versus Hypertrophic Scar. Egypt J Hosp Med. 2018;70(January):622-4.
  8. Carswell L, Borger J. Hypertrophic Scarring Keloids [Internet]. StatPearls [Internet], editor. StatPearls. Treasure Island (FL): StatPearls Publishing; 2022.
  9. Butzelaar L, Niessen FB, Talhout W, Schooneman DPM, Ulrich MM, Beelen RHJ, et al. Different properties of skin of different body sites : The root of keloid formation? Wound Repair Regen. 2017;25(5):758-66.
  10. Khan FA, Drucker NA, Larson SD, Taylor JA, Islam S. Pediatric earlobe keloids: Outcomes and patterns of recurrence. J Pediatr Surg [Internet]. 2020;55(3):461-4.
  11. Hietanen KE, Järvinen TA, Huhtala H, Tolonen TT, Kuokkanen HO, Kaartinen IS. Treatment of keloid scars with intralesional triamcinolone and 5-fluorouracil injections – a randomized controlled trial. J Plast Reconstr Aesthetic Surg [Internet]. 2019;72(1):4-11.
  12. Akinbiyi T, Kozak GM, Davis HD, Barrette LX, Rios-Diaz AJ, Maxwell R, et al. Contemporary treatment of keloids: A 10-year institutional experience with medical management, surgical excision, and radiation therapy. Am J Surg [Internet]. 2021;221(4):689-96.