



HASIL VALIDASI DAN PENILAIAN
KARYA ILMIAH DOSEN FAKULTAS KEDOKTERAN GIGI UNIVERSITAS AIRLANGGA
(MEDIA PUBLIKASI KARYA ILMIAH : JURNAL ILMIAH NASIONAL)

Nomor : 66 /UN3.1.2. 5. 9 / PG /2023

A. Identitas Karya Ilmiah

- Judul Jurnal Ilmiah (Artikel) : Aesthetic consideration in patient management of severe periodontitis aggravated by oral dexamethasone
- Jumlah penulis : 9 (sembilan) orang
- Status Pengusul : Penulis Ke-5
- Identitas Jurnal Ilmiah : a. Nama Jurnal : Majalah Kedokteran Gigi (Dental Journal)
b. Nomor ISSN: 2442-9740, 1978-3728
c. Volume, Nomor, bulan, tahun : Volume 56 No.2 Tahun 2023, p.73-79
d. Penerbit : AUP
e. DOI artikel :
- f. Alamat web Jurnal : <https://e-journal.unair.ac.id/MKG/article/view/40987>

- B. Kategori Publikasi Jurnal Ilmiah : Jurnal Ilmiah Internasional Bereputasi (SJR > 0,10)
(beri lipada kategori yang tepat) : Jurnal Ilmiah Internasional Bereputasi (SJR < 0,10)
 Jurnal Ilmiah Internasional terindeks di Web of science clarivate analytics / kelompok emerging sources citation indeks (tidak terindeks SJR)

C. Hasil Validasi Ketua Departemen


Telah diperiksa dan divalidasi dengan baik, dan sampai pernyataan ini dibuat sebagai karya ilmiah **original** / ~~plagiat~~*, sehingga kami turut bertanggung jawab bahwa karya ilmiah tersebut telah memenuhi syarat kaidah ilmiah, norma akademik, dan norma hukum, sesuai dengan Peraturan Menteri Pendidikan Nasional Nomor 17 Tahun 2010 tanggal 16 Agustus 2010 tentang Pencegahan dan Pananggulangan Plagiat di Perguruan Tinggi.

Namun demikian, apabila di kemudian hari ternyata terbukti bahwa karya ilmiah tersebut merupakan karya Ilmiah Plagiat, maka akan menjadi tanggung jawab mutlak penulis tersebut di atas, baik secara perdata maupun pidana.

Demikian surat pernyataan ini saya buat untuk dipergunakan sebagaimana mestinya

Surabaya, 1 Maret 2023

Ketua Departemen,


Prof. Dr. Soegeng Wahlujo, drg, MKes, SpKGA.,
Supsp KKA(K)

NIP : 1954111019810301003

* Coret salah satu

Case report

Aesthetic consideration in patient management of severe periodontitis aggravated by oral dexamethasone

Irma Josefina Savitri¹, I Komang Evan Wijaksana¹, Okkinardo Arief², Muhammad Nur Falah³, Udijanto Tedjosasongko⁴, Olivia Bambang Siswanto², Kazuhisa Ouhara⁵, Hidemi Kurihara⁶, Noriyoshi Mizuno⁵

¹Department of Periodontics, Faculty of Dental Medicine, Universitas Airlangga, Surabaya, Indonesia

²Periodontology Specialist Program, Faculty of Dental Medicine, Universitas Airlangga, Surabaya, Indonesia

³Undergraduate student, Faculty of Dental Medicine, Universitas Airlangga, Surabaya, Indonesia

⁴Department of Pediatric Dentistry, Faculty of Dental Medicine, Universitas Airlangga, Surabaya, Indonesia

⁵Department of Periodontal Medicine, Graduate School of Biomedical and Health Sciences, Hiroshima University, Hiroshima, Japan

⁶Dental Academy, Higashiyanaagi, Kudamatsu City, Japan

ABSTRACT

Background: The treatment of severe periodontitis must consider immune responses and local conditions, including the aesthetical aspects. The tooth loss in the anterior area can lead to a psychological issue in some patients, and the daily use of dexamethasone contributes greatly to the severity of aesthetical aspects. Periodontal treatments must be cautious of these aesthetical effects.

Purpose: To report the aesthetical consideration in patient management of severe periodontitis aggravated by oral dexamethasone.

Case: The 44-year-old female patient reported having tooth mobility in the upper right and left central incisor and lower right and left posterior. Due to the condition, the central anterior needed to be extracted. The patient had seafood allergies and consumed oral dexamethasone periodically to prevent allergic reactions for two years. **Case management:** The initial periodontal therapy was designed prior to the tooth extraction, socket preservation, and immediate denture on teeth 11 and 21. A metal frame combined with an acrylic denture was designed to support the tooth splint and replace the teeth on the mandible. The patient was treated with 20 mg of sub-antimicrobial-dose doxycycline twice a day for three months, and vitamin E was prescribed once a day. Since dexamethasone may contribute to immune response and osteoclastogenesis, dexamethasone was replaced by cetirizine. **Conclusion:** The treatment of severe chronic periodontitis must consider immune responses, local conditions, and aesthetical aspects. In this case, the use of dexamethasone might worsen the periodontal breakdown. However, the periodontal treatment, use of host modulation therapy, and replacement of dexamethasone with cetirizine are expected to improve these conditions.

Keywords: aesthetic; host modulation therapy; medicine; periodontitis; oral dexamethasone

Article history: Received 29 November 2022; Revised 21 December 2022; Accepted 3 January 2023

Correspondence: Irma Josefina Savitri, Department of Periodontics, Faculty of Dental Medicine, Universitas Airlangga. Jl. Mayjen Prof. Dr. Moestopo 47 Surabaya, 60132, Indonesia. Email: irma-j-s@fkg.unair.ac.id

INTRODUCTION

Periodontitis is a common disease in the oral cavity consisting of slow irreversible damage of the periodontal supporting tissue over a period of time.¹ It has been shown that deep periodontal pockets as a result of alveolar bone destruction are associated with an increase in tooth loss.^{2–4} Tooth loss, especially in the anterior area, can lead to psychological issues in some patients.⁵ Aesthetical aspects must be taken into account during periodontal treatment.⁶

Periodontitis is an inflammatory disease caused by microorganisms and characterized by the progressive destruction of periodontal tissue.⁷ The pathogenesis of the destructive periodontal disease is currently understood as the response given by an individual to the bacterial challenge of subgingival dental biofilm.⁴ This response is modulated by different mechanisms, including environmental and acquired factors.^{8,9} The variety of environmental and acquired factors, including genetics, comorbid, local and dental factors, and medicine, modify the condition of periodontal disease patients.^{9–11}

To the best of the authors' knowledge, there is no clear epidemiological data regarding the number of periodontitis patients using dexamethasone. However, several studies explained a strong relationship between the effect of dexamethasone and tissue destruction in periodontitis. Previous studies analyzed the role of synthetic glucocorticoids, including dexamethasone, and found that it has direct effects on osteoblast, osteocyte, and osteoblast function resulting in reduced remodeling and possible diminished repair of microdamage of bone.¹¹ Glucocorticoid-induced inhibition of osteoblast differentiation via extracellular signal-regulated kinase (ERK) signaling,¹² and it also induced osteoporosis through the Runx2 signaling pathway.¹³ Dexamethasone, a steroidal inflammatory drug, clearly demonstrated the capability to modulate the inflammatory process in periodontal tissue.¹⁴ It reportedly decreased the bone mineral density and mineralized matrix.^{12,13,15} This study reports the aesthetical consideration in patient management of severe periodontitis aggravated by oral dexamethasone.

CASE

The 44-year-old, systemically healthy, seafood-allergic, nonsmoking female patient was diagnosed with generalized periodontitis stage IV Grade C. For two years, the patient has consumed oral dexamethasone periodically to prevent allergic reactions. The patient did not reveal any severe periodontal destruction or early tooth loss in her family history, and there were no external abnormalities found (Figure 1). The patient has not received any periodontal treatment in the past. The patient expressed her concern about aesthetics.

Extraoral and intraoral images with the periodontal chart and a radiographic of the patient were taken before periodontal treatment. The oral examination showed severe calculus and teeth mobility in several areas, measured using Miller's tooth mobility index.¹⁶ Grade three of Miller's index was found in the upper right and left central incisors, grade two was found in teeth 44, 43,

42, 41, 31, 32, and grade one was found in teeth 33, 34, and 35. Gingival recession and periodontal pockets up to 9mm were found in most of the teeth (Figures 2 and 3). A radiograph examination revealed severe bone loss in the upper right and left central incisor. Bone loss also occurs in other areas (Figure 4).

The initial periodontal therapy was designed prior to the tooth extraction, socket preservation, and immediate denture on teeth 11 and 21. A metal frame combined with an acrylic denture was designed to support the tooth splint and replace the teeth on the mandible.¹⁷ To modulate the immune system, the patient was treated with host modulation therapy.¹⁸ Twenty mg of sub-antimicrobial-dose doxycycline was prescribed twice a day for three months and vitamin E was prescribed once a day.^{19–21} A periodontal flap surgery combined with a bone graft augmentation was planned to regenerate periodontal tissues.²² In addition, the patient was referred to an internist to replace the steroidal inflammatory drugs.

CASE MANAGEMENT

At the first visit, the patient was treated by scaling, root planning, and a fiber splint on teeth 44, 43, 42, 41, 31, 32, 33, 34, and 35 (Figures 3 and 5A). An immediate denture for the maxilla and a metal frame denture for the mandible were designed (Figure 6). The patient was prescribed 20 mg of doxycycline and vitamin E twice a day for three months for host modulation therapy^{19,21,23} and was referred to an internist for a medical assessment.

A laboratory assessment shows that the fasting glucose level was 89 mg/dl (normal: 70–115 mg/dl), the two-hour glucose level was 135 mg/dl (normal: <200 mg/dl), and the HBA1C was 4.5% (normal: 5.7%; pre-diabetes: 5.7–6.4%; diabetes: ≥6.5%). Dexamethasone was replaced with cetirizine dihydrochloride, another anti-histamine, to prevent an allergic reaction.

During the second visit, one week after periodontal splint treatment, the patient came to control her condition and continued the treatment. There were abscesses on teeth 34, 33, 32, 31, 41, 42, 43, 44, and 45. Plaque and debris

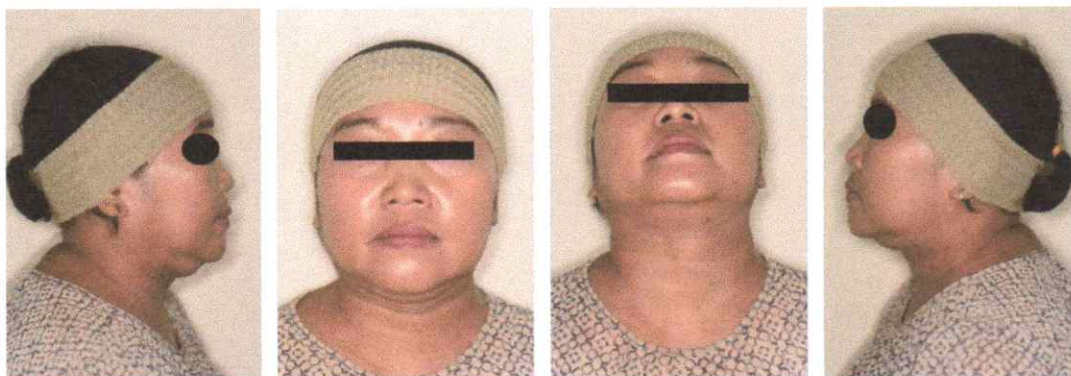

Figure 1. Extra oral image of the patient.

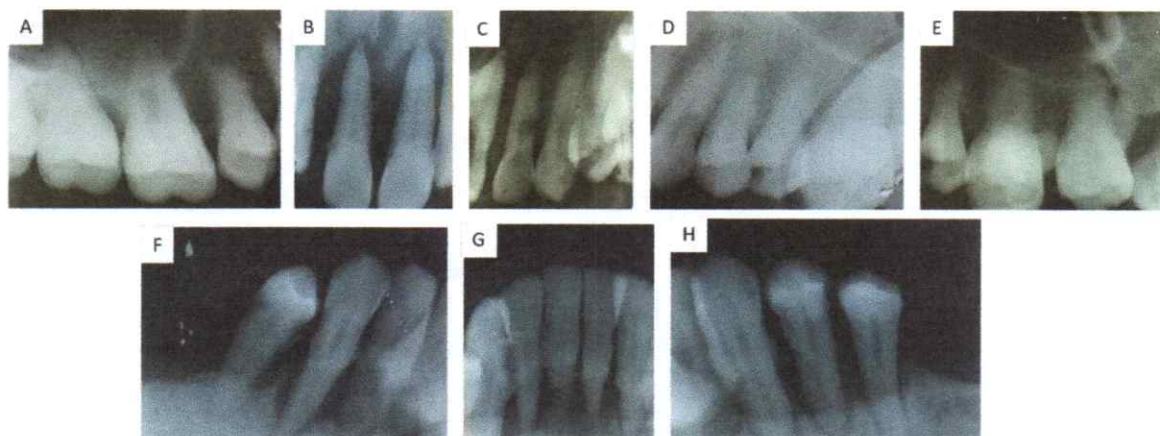


Figure 4. (A) X-ray image of teeth 17, 16, and 15; (B) X-ray image of teeth 11 and 21; (C) X-ray image of teeth 2, 2, 3, and 24; (D) X-ray image of teeth 23, 24, and 25; (E) X-ray image teeth 25, 26, and 27; (F) X-ray image of teeth 44, 43, and 42; (G) X-ray image of teeth 42, 41, 31, and 32; (H) X-ray image of teeth 33, 34, and 35.

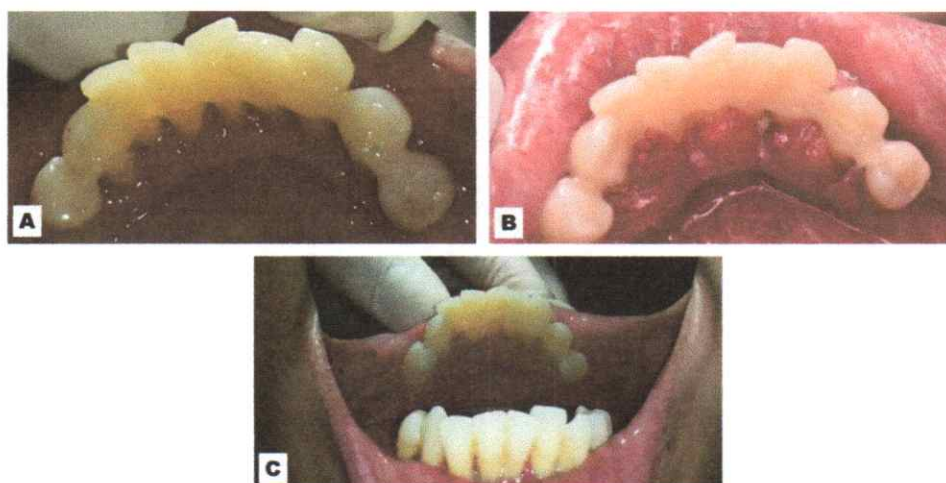


Figure 5. A fiber splint on teeth 34–45 (A), a periodontal abscess on teeth 34–45 (B), and an abscess healing on teeth 34–45 (C).

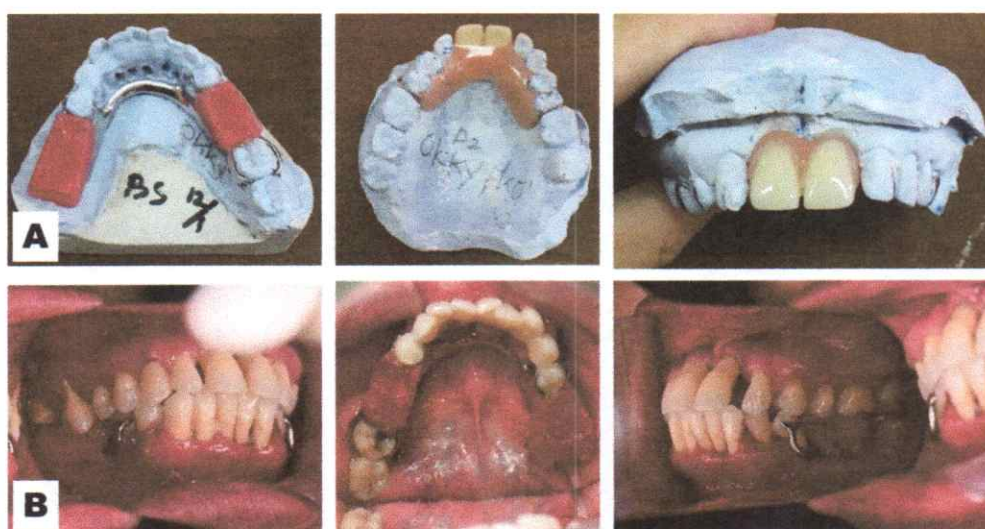


Figure 6. The lower arch metal frame design and immediate denture on teeth 11 and 21 (A). Fitting the metal frame and searching the bite for denture (B).

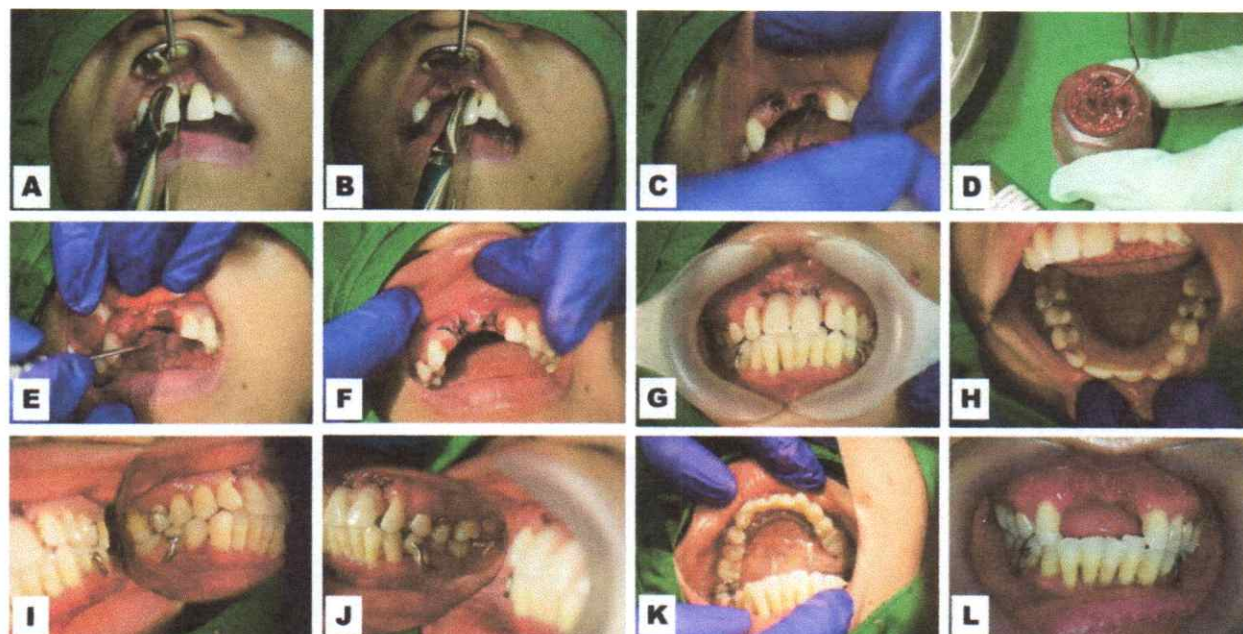


Figure 7. Asepsis technique using povidone-iodine to prevent infection and mepivacaine 2% with epinephrine 1:100.000 (Scandonest 2% special) was administered for the surgery. (A) The extraction of tooth 11; (B) The extraction of tooth 21; (C) socket debridement of teeth 11 and 21; (D) PRF was mixed with bone graft (Batan Research Tissue Bank); (E) bone graft application in socket 11 and 21; (F) The socket was sutured with braided non-absorbable silk 4.0 (Mersilk); (G) Buccal side of immediate denture 11 and 21; (H) Occlusal side of immediate denture 11 and 21; (I) and (J) Sagittal view of the removable metal frame partial denture on the mandible; (K) Occlusal view of the removable metal frame partial denture on the mandible; (L) The wound healing after two weeks socket preservation surgery.

were also found in the oral cavity (Figure 5B). 500 mg of Amoxicillin combined with 500 mg of Metronidazole were prescribed for three days, and oral hygiene instructions were given to the patient for abscess treatment. A metal frame was tried on the mandible and occlusion was adjusted (Figure 6B).

During the third visit, the abscess was healing in teeth 34, 33, 32, 31, 41, 42, 43, 44, and 45 (Figure 5C). The surgical procedure for socket preservation on teeth 11 and 21 was performed. To replace the edentulous, an immediate denture on the maxilla and a metal frame on the mandible were inserted. Socket preservation was performed on teeth 11 and 21, followed by an immediate denture carried out under a local anesthetic drug, and the insertion of a removable metal frame. The surgical steps were explained briefly in Figure 7. Under aseptic and anesthetic procedures, teeth 11 and 21 were extracted. Socket debridement was performed, and a bone graft mixed with PRF was applied. The socket was sutured by braided-non absorbable silk 4.0. An immediate denture was inserted on the maxilla to replace teeth 11 and 12, and a metal frame was inserted on the mandible to replace edentulous. Occlusal evaluation was performed to avoid trauma from occlusal. The patient was instructed to keep the immediate denture in for 24 hours. 500 mg of Paracetamol and 25 mg of Kalium Diclofenac three times a day were prescribed for three days. Two weeks after the surgery, the wound showed signs of healing (Figure 7L).

DISCUSSION

This case presents the aesthetical consideration in patient management with severe periodontitis. Prolong inflammatory process leads to tissue destruction in the periodontal tissue.^{24,25} Loss of anterior teeth, particularly in adolescents, increases the demand for tissue maintenance and aesthetics.²⁶ Substituting hopeless teeth with dentures in one visit could provide a solution for the patient. Some previous studies reported that the alternative treatment of a single-visit replacement of the central maxillary was the insertion of an immediate denture²⁷ and fiber-reinforced composite resin.²⁶

Since periodontitis causes tissue destruction and tooth mobility, the treatment started with teeth splinting of 34, 33, 32, 31, 41, 42, 43, 44, and 45 to maintain the stability of the abutment.²⁸ Previous studies suggested that a variety of periodontal splinting, including a removable partial denture, was designed to stabilize the mobility tooth. They recommend particular designs of partial dentures to enforce the abutment.^{28–30}

A removable metal frame partial denture is the ideal prosthesis for a patient with a periodontal problem. It provides better stability because of the rigidity. This prosthesis could prevent mesial and distal displacement of teeth and lateral pressure and may prevent dental extrusion. Furthermore, a removable partial denture made from a metal frame returns the efficiency of overall mastication. They

might divide the masticatory load and give stabilization force with a splint mechanism so that the natural teeth can function well.¹⁷

Socket preservation in teeth 11 and 21 was performed with demineralized freeze-dried bone xenograft (DFDBX) (Batan Research Tissue Bank) and platelet-rich fibrin (PRF). Xenograft in socket preservation techniques delayed socket healing. However, it will help to conserve the anatomy of the bone. Xenografts are considered the most used bone fillers in socket preservation procedures due to their osteoconductive matrix framework that enhances the growth of new bone around it.³¹

PRF consists of an autologous leukocyte-platelet-rich fibrin matrix, composed of a tetra molecular structure, with cytokines, platelets, and stem cells within it. PRF acts as a biodegradable scaffold that favors the development of micro vascularization and can guide epithelial cell migration to its surface. PRF has great potential for bone and soft tissue regeneration without inflammatory reactions and may be used alone or in combination with bone grafts. The advantages of these techniques are promoting homeostasis and enhancing bone growth and maturation.³²

The patient was referred to an internist due to suspicions of a systemic problem that may cause severe bone and clinical attachment loss in many teeth. Dexamethasone was replaced by cetirizine dihydrochloride. Dexamethasone may impair wound healing and diminish bone mineralization. An experimental study in an animal periodontal model revealed that dexamethasone causes more attachment loss and made a bone more easily fractured compared to controls. The anti-inflammatory effect of dexamethasone can minimize clinical signs of inflammation at first by reducing the host response. An impaired host response could be responsible for more tissue breakdown.¹⁴ Through the inhibition of osteoblast differentiation via the ERK pathway and Runx2 signaling, dexamethasone may cause osteoporosis and may decrease bone mineral density.^{12,13,15}

Different results were shown by Metzger et al's study.³³ A periapical lesion was induced in rats by occlusal exposure of their first molar. However, systemic dexamethasone downregulates bone resorption in periapical inflammatory lesions.³³

Cetirizine dihydrochloride is an antihistamine used to relieve allergy symptoms such as watery eyes, runny noses, itching eyes/nose, sneezing, hives, and itching. It works by blocking the histamine that the body makes during an allergic reaction. The adverse effects of cetirizine generally being of mild to moderate intensity is comparable with other antihistamines such as astemizole, ebastine, fexofenadine, loratadine, mizolastine, or terfenadine.³⁴

Cetirizine is an antagonist of the TLR2 and TLR4 receptors. The suppressive effect on TLR2 and TLR4 will decrease the production of IL-8 as a pro-inflammatory cytokine and CCL20 as a macrophage inflammatory protein. This experiment confirmed the addition of cetirizine one hour before stimulation in human gingival fibroblast by using TLR2 and TLR4 ligand and histamine

to downregulate the production of IL-8 and CCL20. In addition to TLR2 and TLR4, cetirizine also blocks the histamine link with a histamine-1 receptor (H1R) in human gingival fibroblasts.³⁵

We assumed that dexamethasone and cetirizine display different effects in periodontal tissue. The mechanism of action of these steroidal anti-inflammatory drugs remains unclear. Dexamethasone caused bone destruction in the animal periodontal model. On other hand, cetirizine may regulate the inflammatory process in human gingival cells. Further study will be needed to discuss the effect of steroidal anti-inflammatory drugs on periodontal tissue. However, we suggest cetirizine dihydrochloride is an ideal treatment for allergies in patients with periodontal disease.

20 mg of Doxycycline twice a day for three months is a subantimicrobial-dose doxycycline. Doxycycline was the most potent tetracycline in the inhibition of collagenolytic activities. Elavarasu et al.³⁶ in 2012 reported that this property of doxycycline provided the pharmacological rationale for the use of a low or subantimicrobial dose of doxycycline, which was shown to be efficient in inhibiting mammalian collagenase activity without developing antibiotic resistance.

Periodontal treatment aims to prevent further disease progression, minimize tooth loss, restore periodontal tissue destruction, and maintain a healthy periodontium. Previous studies explain that no particular periodontal treatment is more important than others.^{37,38} The combination of non-surgery³⁸ and surgery periodontal therapy³⁷ might relieve several unfavorable effects of severe periodontitis. Adequate periodontal therapy may decrease the risk of systemic conditions, such as cardiovascular disease by continuous bacteremia.³⁹ Furthermore, gram-negative strictly anaerobic bacteria may cause the induction of inflammatory cytokine.⁴⁰ However, periodontal therapy might regulate these inflammatory cytokines.^{41,42}

In conclusion, the treatment of severe chronic periodontitis must consider the immune response and local conditions, including the aesthetic aspects. In this case, the use of Dexamethasone might worsen the periodontal breakdown. However, adequate surgery and non-surgery therapy, such as host modulation therapy and replacement of dexamethasone with cetirizine, are expected to improve these conditions.

ACKNOWLEDGMENT

This research was supported by a Grant from the Ministry of National Education, Indonesia, with contract number 597/UN3.14/LT/2017.

REFERENCES

1. Wulandari P, Widkaja D, Nasution AH, Syahputra A, Gabrina G. Association between age, gender and education level with the severity of periodontitis in pre-elderly and elderly patients. *Dent. J.* 2022; 55(1): 16–20.

2. Andriani I, Medawati A, Humanindito MI, Nurhasanah M. The effect of antimicrobial peptide gel RISE-API2 on decreasing neutrophil and enhancing macrophage in nicotine-periodontitis Wistar rat model. *Dent. J.* 2022; 55(2): 93–8.
3. Li A, Chen L, Thomas RZ, van der Velden U, Amaliya A, van der Sluis LWM, Schuller AA, Tjakkes G-HE. Periodontal breakdown inter-tooth relationships in estimating periodontitis-related tooth loss. *J Dent.* 2021; 112: 103755.
4. Mombelli A. Microbial colonization of the periodontal pocket and its significance for periodontal therapy. *Periodontol* 2000. 2018; 76(1): 85–96.
5. Roohafza H, Afghari P, Keshteli AH, Vali A, Shirani M, Adibi P, Afshar H. The relationship between tooth loss and psychological factors. *Community Dent Health.* 2015; 32(1): 16–9.
6. Al Baker A, Habib SR, Al Amri MD. Preserving esthetics, occlusion and occlusal vertical dimension in a patient with fixed prostheses seeking dental implant treatment. *Saudi Dent J.* 2016; 28(4): 203–8.
7. Tonetti MS, Greenwell H, Kornman KS. Staging and grading of periodontitis: Framework and proposal of a new classification and case definition. *J Periodontol.* 2018; 89(Suppl 1): S159–72.
8. Jepsen S, Caton JG, Albandar JM, Bissada NF, Bouchard P, Cortellini P, Demirel K, de Sanctis M, Ercoli C, Fan J, Geurs NC, Hughes FJ, Jin L, Kantarci A, Lalla E, Madianos PN, Matthews D, McGuire MK, Mills MP, Preshaw PM, Reynolds MA, Sculean A, Susin C, West NX, Yamazaki K. Periodontal manifestations of systemic diseases and developmental and acquired conditions: Consensus report of workgroup 3 of the 2017 World Workshop on the Classification of Periodontal and Peri-Implant Diseases and Conditions. *J Periodontol.* 2018; 89(Suppl 1): S237–48.
9. Loos BG, Van Dyke TE. The role of inflammation and genetics in periodontal disease. *Periodontol* 2000. 2020; 83(1): 26–39.
10. Petersen PE, Bourgeois D, Ogawa H, Estupinan-Day S, Ndiaye C. The global burden of oral diseases and risks to oral health. *Bull World Health Organ.* 2005; 83(9): 661–9.
11. Chen S-M, Peng Y-J, Wang C-C, Su S-L, Salter DM, Lee H-S. Dexamethasone down-regulates osteocalcin in bone cells through leptin pathway. *Int J Med Sci.* 2018; 15(5): 507–16.
12. Yu W, Zhu C, Xu W, Jiang L, Jiang S. Neuropeptide Y1 receptor regulates glucocorticoid-induced inhibition of osteoblast differentiation in murine MC3T3-E1 cells via ERK signaling. *Int J Mol Sci.* 2016; 17(12).
13. Zhang X, Chen K, Wei B, Liu X, Lei Z, Bai X. Ginsenosides Rg3 attenuates glucocorticoid-induced osteoporosis through regulating BMP-2/BMPRII/Runx2 signaling pathway. *Chem Biol Interact.* 2016; 256: 188–97.
14. Cavagni J, Soletti AC, Gaio EJ, Rösing CK. The effect of dexamethasone in the pathogenesis of ligature-induced periodontal disease in Wistar rats. *Braz Oral Res.* 2005; 19(4): 290–4.
15. Kim H-J, Zhao H, Kitaura H, Bhattacharyya S, Brewer JA, Muglia LJ, Patrick Ross F, Teitelbaum SL. Glucocorticoids and the osteoclast. *Ann N Y Acad Sci.* 2007; 1116: 335–9.
16. Wu C-P, Tu Y-K, Lu S-L, Chang J-H, Lu H-K. Quantitative analysis of Miller mobility index for the diagnosis of moderate to severe periodontitis - A cross-sectional study. *J Dent Sci.* 2018; 13(1): 43–7.
17. Friel T, Waia S. Removable Partial Dentures for Older Adults. *Prim Dent J.* 2020; 9(3): 34–9.
18. Sulijaya B, Takahashi N, Yamazaki K. Host modulation therapy using anti-inflammatory and antioxidant agents in periodontitis: A review to a clinical translation. *Arch Oral Biol.* 2019; 105: 72–80.
19. Preshaw PM, Novak MJ, Mellonig J, Magnusson I, Polson A, Giannobile W V, Rowland RW, Thomas J, Walker C, Dawson DR, Sharkey D, Bradshaw MH. Modified-release subantimicrobial dose doxycycline enhances scaling and root planing in subjects with periodontal disease. *J Periodontol.* 2008; 79(3): 440–52.
20. Emingil G, Atilla G, Sorsa T, Savolainen P, Baylas H. Effectiveness of adjunctive low-dose doxycycline therapy on clinical parameters and gingival crevicular fluid laminin-5 gamma2 chain levels in chronic periodontitis. *J Periodontol.* 2004; 75(10): 1387–96.
21. Shadisvaaran S, Chin K-Y, Shahida M-S, Ima-Nirwana S, Leong X-F. Effect of vitamin E on periodontitis: Evidence and proposed mechanisms of action. *J oral Biosci.* 2021; 63(2): 97–103.
22. Nibali L, Koidou VP, Nieri M, Barbato L, Pagliaro U, Cairo F. Regenerative surgery versus access flap for the treatment of intra-bony periodontal defects: A systematic review and meta-analysis. *J Clin Periodontol.* 2020; 47 Suppl 2(S22): 320–51.
23. Caton J, Ryan ME. Clinical studies on the management of periodontal diseases utilizing subantimicrobial dose doxycycline (SDD). *Pharmacol Res.* 2011; 63(2): 114–20.
24. Savitri IJ, Ouhara K, Fujita T, Kajiya M, Miyagawa T, Kittaka M. Irsogladine maleate inhibits *Porphyromonas gingivalis*-mediated expression of toll-like receptor 2 and interleukin-8 in human gingival epithelial cells. *J Periodontol Res.* 2015; 50(40): 486–93.
25. Shindo S, Savitri IJ, Ishii T, Ikeda A, Pierrelus R, Heidari A, Okubo K, Nakamura S, Kandalam U, Rawas-Qalaji M, Leon E, Pastore MR, Hardigan P, Kawai T. Dual-function semaphorin 4D released by platelets: Suppression of osteoblastogenesis and promotion of osteoclastogenesis. *Int J Mol Sci.* 2022; 23(6).
26. Turker SB, Sener ID. Replacement of a maxillary central incisor using a polyethylene fiber-reinforced composite resin fixed partial denture: a clinical report. *J Prosthet Dent.* 2008; 100(4): 254–8.
27. Yilmaz B, Ozelik TB, McGlumphy E. Using the “final-on-four” concept to deliver an immediate metal-resin implant-fixed complete dental prosthesis. *J Prosthet Dent.* 2015; 114(2): 161–6.
28. Berthold C, Thaler A, Petschelt A. Rigidity of commonly used dental trauma splints. *Dent Traumatol.* 2009; 25(3): 248–55.
29. Itoh H, Caputo AA, Wylie R, Berg T. Effects of periodontal support and fixed splinting on load transfer by removable partial dentures. *J Prosthet Dent.* 1998; 79(4): 465–71.
30. Chalifoux PR. Periodontal splinting of anterior teeth. *Pract Periodontics Aesthet Dent.* 1991; 3(6): 21–8.
31. Serrano Méndez CA, Lang NP, Caneva M, Ramírez Lemus G, Mora Solano G, Botticelli D. Comparison of allografts and xenografts used for alveolar ridge preservation. A clinical and histomorphometric RCT in humans. *Clin Implant Dent Relat Res.* 2017; 19(4): 608–15.
32. Mohan SP, Jaishangar N, Devy S, Narayanan A, Cherian D, Madhavan SS. Platelet-rich plasma and platelet-rich fibrin in periodontal regeneration: A review. *J Pharm Bioallied Sci.* 2019; 11(Suppl 2): S126–30.
33. Metzger Z, Klein H, Klein A, Tagger M. Periapical lesion development in rats inhibited by dexamethasone. *J Endod.* 2002; 28(9): 643–5.
34. Zhang L, Cheng L, Hong J. The clinical use of cetirizine in the treatment of allergic rhinitis. *Pharmacology.* 2013; 92(1–2): 14–25.
35. Dommisch H, Chung WO, Plötts S, Jepsen S. Influence of histamine on the expression of CCL20 in human gingival fibroblasts. *J Periodontol Res.* 2015; 50(6): 786–92.
36. Elavarasu S, Sekar S, Murugan T. Host modulation by therapeutic agents. *J Pharm Bioallied Sci.* 2012; 4(Suppl 2): S256–9.
37. Graziani F, Karapetsa D, Alonso B, Herrera D. Nonsurgical and surgical treatment of periodontitis: how many options for one disease? *Periodontol* 2000. 2017; 75(1): 152–88.
38. Haas AN, Furlaneto F, Gaio EJ, Gomes SC, Palioto DB, Castilho RM, Sanz M, Messori MR. New tendencies in non-surgical periodontal therapy. *Braz Oral Res.* 2021; 35(Suppl 2): 1–18.
39. Priyamvara A, Dey AK, Bandyopadhyay D, Katikineni V, Zaghlool R, Basyal B, Barssoum K, Amarin R, Bhatt DL, Lavie CJ. Periodontal inflammation and the risk of cardiovascular disease. *Curr Atheroscler Rep.* 2020; 22(7): 28.
40. Pan W, Wang Q, Chen Q. The cytokine network involved in the host immune response to periodontitis. *Int J Oral Sci.* 2019; 11(3): 30.
41. Balta MG, Papathanasiou E, Blix IJ, Van Dyke TE. Host modulation and treatment of periodontal disease. *J Dent Res.* 2021; 100(8): 798–809.
42. Kim J-Y, Kim H-N. Changes in inflammatory cytokines in saliva after non-surgical periodontal therapy: A systematic review and meta-analysis. *Int J Environ Res Public Health.* 2020; 18(1): 1–16.