



# Source details

## Open Access Macedonian Journal of Medical Sciences

Formerly known as: Macedonian Journal of Medical Sciences

Scopus coverage years: from 2014 to 2022

(coverage discontinued in Scopus)

Publisher: Scientific Foundation SPIROSKI

E-ISSN: 1857-9655

Subject area: Medicine: General Medicine

Source type: Journal

CiteScore 2021

1.3



SJR 2021

0.257



SNIP 2021

0.603



[View all documents >](#)

[Set document alert](#)

[Save to source list](#)

[CiteScore](#) [CiteScore rank & trend](#) [Scopus content coverage](#)

### i Improved CiteScore methodology



CiteScore 2021 counts the citations received in 2018-2021 to articles, reviews, conference papers, book chapters and data papers published in 2018-2021, and divides this by the number of publications published in 2018-2021. [Learn more >](#)

CiteScore 2021

$$1.3 = \frac{4,420 \text{ Citations 2018 - 2021}}{3,303 \text{ Documents 2018 - 2021}}$$

Calculated on 05 May, 2022

### CiteScore rank 2021

Category	Rank	Percentile
Medicine		
General Medicine	#416/826	49th

[View CiteScore methodology >](#) [CiteScore FAQ >](#) [Add CiteScore to your site](#)

---

## About Scopus

[What is Scopus](#)

[Content coverage](#)

[Scopus blog](#)

[Scopus API](#)

[Privacy matters](#)

## Language

[日本語版を表示する](#)

[查看简体中文版本](#)

[查看繁體中文版本](#)

[Просмотр версии на русском языке](#)

## Customer Service

[Help](#)

[Tutorials](#)

[Contact us](#)

---

## ELSEVIER

[Terms and conditions](#) ↗ [Privacy policy](#) ↗




Copyright © Elsevier B.V. ↗. All rights reserved. Scopus® is a registered trademark of Elsevier B.V.

We use cookies to help provide and enhance our service and tailor content. By continuing, you agree to the use of cookies ↗.





## BMJ Case Reports

<p><b>COUNTRY</b></p> <p><a href="#">United Kingdom</a></p> <div data-bbox="119 667 351 707">  Universities and research institutions in United Kingdom         </div> <div data-bbox="119 730 351 770">  Media Ranking in United Kingdom         </div>	<p><b>SUBJECT AREA AND CATEGORY</b></p> <p><a href="#">Medicine</a></p> <ul style="list-style-type: none"> <li><a href="#">Medicine (miscellaneous)</a></li> </ul>	<p><b>PUBLISHER</b></p> <p><a href="#">BMJ Publishing Group</a></p> <div data-bbox="850 667 1082 707">  BMJ Group in Scimago Institutions Rankings         </div>	<p><b>H-INDEX</b></p> <p><b>31</b></p>
<p><b>PUBLICATION TYPE</b></p> <p>Journals</p>	<p><b>ISSN</b></p> <p>1757790X</p>	<p><b>COVERAGE</b></p> <p>2008-2021</p>	<p><b>INFORMATION</b></p> <p><a href="#">Homepage</a></p> <p><a href="#">How to publish in this journal</a></p> <p><a href="#">Contact</a></p>

### SCOPE

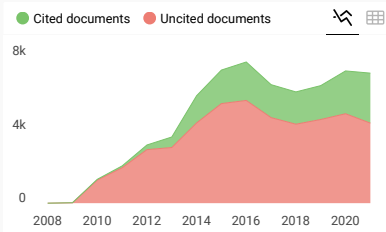
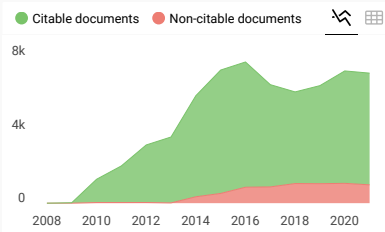
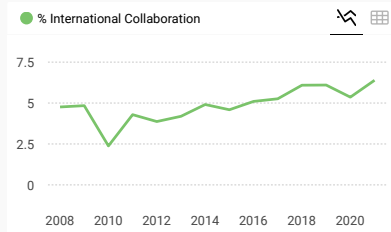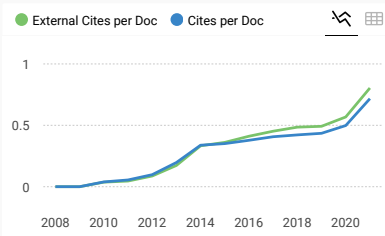
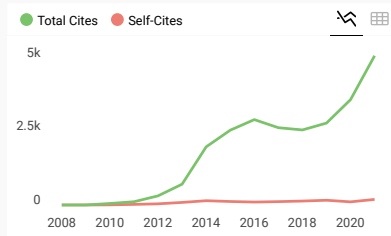
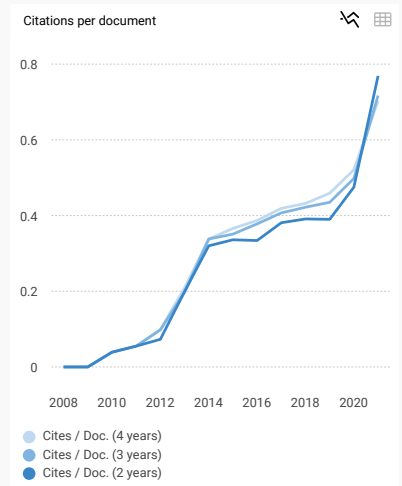
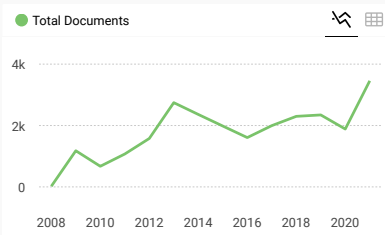
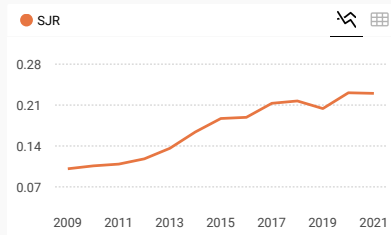
BMJ Case Reports is an important educational resource offering a high volume of cases in all disciplines so that healthcare professionals, researchers and others can easily find clinically important information on common and rare conditions. All articles are peer reviewed and copy edited before publication. BMJ Case Reports is not an edition or supplement of the BMJ.

 [Join the conversation about this journal](#)

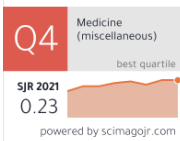
FIND SIMILAR JOURNALS ⓘ

options ⋮

<p>1 <b>Journal of Medical Case Reports</b> GBR</p> <p><b>82%</b> similarity</p>	<p>2 <b>American Journal of Case Reports</b> USA</p> <p><b>78%</b> similarity</p>	<p>3 <b>Case Reports in Medicine</b> USA</p> <p><b>69%</b> similarity</p>	<p>4 <b>Oxford Medical Case Reports</b> USA</p> <p><b>65%</b> similarity</p>	<p>5 <b>Clinical Case Reports</b> GBR</p> <p><b>65%</b> similarity</p>
--	---	---	--	--



**BMJ Case Reports**




Show this widget in your own website

Just copy the code below and paste within your html code:

```
<a href="https://www.scimagojr.com">
```

**SCImago Graphica**

Explore, visually communicate and make sense of data with our [new data visualization tool](#).



Metrics based on Scopus® data as of April 2022



**Dr Hasan** 2 years ago

Is bmj case reports indexed in sci or sci-expanded? How can i understand any journal is indexed in sci-e? Thank you very much

reply



**Melanie Ortiz** 2 years ago

SCImago Team

Dear Dr Hasan,  
Thank you for contacting us.  
SJR is a portal with scientometric indicators of journals indexed in Elsevier/Scopus.  
Unfortunately, we cannot help you with your request referring to the index status. We suggest you consult Scopus database (see the current status of the journal) or the mentioned database for further information.  
Best Regards, SCImago Team



**Elli** 4 years ago

Hi  
I want to know how much is your publishing fees per article?  
thanks

← reply



**Elena Corera** 4 years ago

SCImago Team

Dear Elli,  
thank you very much for your comment, unfortunately we cannot help you with your request. We suggest you look for author's instructions in the journal's website.  
Best Regards,  
SCImago Team

**Leave a comment**

Name

Email

(will not be published)

Submit

The users of Scimago Journal & Country Rank have the possibility to dialogue through comments linked to a specific journal. The purpose is to have a forum in which general doubts about the processes of publication in the journal, experiences and other issues derived from the publication of papers are resolved. For topics on particular articles, maintain the dialogue through the usual channels with your editor.

Developed by:



Powered by:



Follow us on @ScimagoJR

Scimago Lab, Copyright 2007-2022. Data Source: Scopus®

EST MODUS IN REBUS

Horatio (Satire 1.1,106)

[Edit Cookie Consent](#)



# Table of contents

◀ Prev issue

Next issue ▶

## January 2020 - Volume 13 - 1

Case report: Rifampicin induced shock during re-exposure for treatment of latent tuberculosis (2 February, 2020)  
Christopher Francis Harlow, Jamilah Meghji, Laura Martin, Timothy Harris, Onn Min Kon

Case report: Mesenteric panniculitis in a patient with new onset dermatomyositis (2 February, 2020)  
Pankaj Bansal, Emily L Gilbert, Rodrigo Otavio Lami Pereira, Andrew R Virata

Case report: Unusual presentation of left ventricular rupture (2 February, 2020)  
Amarbir S Bhullar, Charnjeet Singh Sandhu, Manminder S Bhullar, Ankit Rathod

Spontaneous extensive pneumocephalous as a rare manifestation of *Escherichia coli* suppurative meningitis in Diabetic ketoacidosis (29 January, 2020) FREE  
Abhishek Dhir, Swati Dahiya, Nidhi Bhardwaj, Monica Gupta

Case report: Torsion of undescended abdominal testicle in a 16-year-old and its management (29 January, 2020)  
Muhamamd Isfandyar Khan Malik, Joshua Abbas, Shariq Sabri, George Michael, Simon Ellenbogen

Case report: Pulmonary haemorrhage in Weil's disease (29 January, 2020)   
Emma Boertjes, Stefanie Hillebrand, Janneke Elisabeth Bins, Laurien Oswald

Case report: Primary malignant melanoma of the vagina (29 January, 2020)   
Emily Jamaer, Zach Liang, Brendan Stagg

Case report: Internal herniation following laparoscopic pancreatoduodenectomy (29 January, 2020)   
David Jan Brinkman, Jony Van Hilst, Misha D Luyer

Case report: Grief-induced reversible cerebral vasoconstriction syndrome (RCVS) (29 January, 2020)   
Pooja Rao, Michael Francis McCullough, Jessica Stevens, Matthew A Edwardson

Contralateral sandwich myocutaneous anterolateral thigh flap for salvage of femoral artery repair in an infected groin wound: an innovative technique (29 January, 2020) FREE  
Ravikiran Naalla, Ashish Dhanraj Bichpuriya, Maneesh Jain, Maneesh Singhal

Eagle's syndrome: an unusual cause of recurrent neck pain in a child (28 January, 2020) FREE  
Arun Kumar, Indar Kumar Sharawat, Lesa Dawman

I Accept

### Cookies and privacy

Case report: Rare case of acute on chronic hepatic failure in a patient with multiple myeloma-associated amyloidosis (28 January, 2020)

We and our partners store and/or access information on a device, such as unique IDs in cookies to process personal data. You may accept or manage our cookies by clicking on the 'I Accept' button, or you may visit our privacy policy page for more information.

Show Purposes

These choices will be signaled to our partners and will not affect browsing data. [Cookie policy](#)

Case report: Rapidly progressing HELLP syndrome and massive liver destruction in a 22-year-old female pregnant with monochorionic diamniotic gemelli (28 January, 2020)

We and our partners process data to provide: Personalised ads and content, ad and content measurement, audience insights and product development, Use precise geolocation data, Actively scan device characteristics for identification

List of Partners (vendors)

Case report: Hepatic epitheloid haemangioendothelioma: a rare malignant tumour (28 January, 2020)

Case report: Severe early-onset ovarian hyperstimulation syndrome with liver dysfunction in an IVF segmentation cycle (26 January, 2020)

Neeta Singh, Yogita Dogra, Monika Saini, Matheswari Govindarajan

Case report: When systemic lupus erythematosus affects vision: a rare presentation of this condition (26 January, 2020)

Tiago Gama Ramires, Luísa Vieira, Nuno Riso, Maria Francisca Moraes-Fontes

Case report: Management of a trichobezoar caused by consumption of artificial hair extensions (26 January, 2020)

Ria Emma Smith, Jaideep Singh Rait, Amira Said, Shwetal Dighe

Case report: *Pneumocystis jirovecii* pneumonitis: cause of acute hypercalcaemia in chronic haemodialysis patient (26 January, 2020)

Florian Garo, Cedric Aglae, Pedram Ahmadpoor, Olivier Moranne

Case report: Primary spinal epidural lymphoma: a rare entity with an ambiguous management (26 January, 2020)

João Páscoa Pinheiro, Joana Rato, Olinda Rebelo, Gonçalo Costa

Puffy hands and periosteal hyperostosis from inhalant abuse (26 January, 2020) FREE

Chen Xie, Meika Fang



## CONTENT

[Latest content](#)

[Archive](#)

[Global Health](#)

[Browse by collection](#)

[Responses](#)

## JOURNAL

[About](#)

[Editorial board](#)

[Thank you to our reviewers](#)

[Sign up for email alerts](#)

[Fellowships](#)

## AUTHORS

[Instructions for authors](#)

[FAQs](#)

[Submit a paper](#)

[Editorial policies](#)

[Open Access at BMJ](#)

[BMJ Author Hub](#)

[Cookies and privacy](#)

We and our partners store and/or access information on a device, such as unique IDs in cookies to process personal data. You may accept or reject our Page your choices by clicking below, including your right to object where legitimate interest is used, or at any time in the privacy policy page.

These choices will be signaled to our partners and will not affect browsing data. [Cookie policy](#)

[Contact us](#)

[We and our partners process data to provide:](#)

[Reprints](#)

Store and/or access information on a device, Personalised ads and content, ad and content measurement, audience insights and product

[Permissions](#) development, Use precise geolocation data, Actively scan device characteristics for identification

[Advertising](#) (vendors)

[I Accept](#)

[Show Purposes](#)



[Website Terms & Conditions](#)

[Privacy & Cookies](#)

[Contact BMJ](#)

[Cookie settings](#)

Online: ISSN 1757-790X

Copyright © 2023 BMJ Publishing Group Ltd. All rights reserved.

**BMJ Global Health**  
**BMJ**

Share your research with the world  
**Submit your paper today** ▶

## Cookies and privacy

We and our partners store and/or access information on a device, such as unique IDs in cookies to process personal data. You may accept or manage your choices by clicking below, including your right to object where legitimate interest is used, or at any time in the privacy policy page. These choices will be signaled to our partners and will not affect browsing data. [Cookie policy](#)

### We and our partners process data to provide:

Store and/or access information on a device, Personalised ads and content, ad and content measurement, audience insights and product development, Use precise geolocation data, Actively scan device characteristics for identification

[List of Partners \(vendors\)](#)

[I Accept](#)

[Show Purposes](#)





(https://www.facebook.com  
/BMJCaseReports/)

(https://twitter.com  
/BMJCaseReports)

(https://blogs.bmj.com  
/case-reports/)

• **Subscribe**

(https://casereports.bmj.com/pages  
/fellowships/)

• Log In  
(/user)

(https://casereports.bmj.com/pages)



Latest content (/content/current)

Archive (/content/by/year)

Global health (https://casereports.bmj.com/pages/global-health/)

For authors (/pages/authors)

About (https://casereports.bmj.com/pages/about/)

Help (https://casereports.bmj.com/pages/contact-us/)

**Subscribe** (https://casereports.bmj.com/pages/fellowships/)

Log In (/user)

Email alerts (https://myaccount.bmj.com/myaccount/signup.html?regService=etoc-alerts&corpusCode=bmjcr&fwdUrl=https://casereports.bmj.com/)

## Cookies and privacy

I Accept

We and our partners store and/or access information on a device, such as unique IDs in cookies to process personal data. You may accept or manage your choices by clicking below, including your right to object where legitimate interest is used, or at any time in the privacy policy page. These choices will be signaled to our partners and will not affect browsing data. [Cookie policy \(https://www.bmj.com/company/legal-information/bmj-cookie-policy/\)](https://www.bmj.com/company/legal-information/bmj-cookie-policy/)

[Show Purpos](#)

### We and our partners process data to provide:

Store and/or access information on a device, Personalised ads and content, ad and content measurement, audience insights and product development, Use precise geolocation data, Actively scan device characteristics for identification

### List of Partners (vendors)

(<https://www.facebook.com/BMJCaseReports/>)

## Cookies and privacy

We and our partners store and/or access information on a device, such as unique IDs in cookies to process personal data. You may accept or manage your choices by clicking below, including your right to object where legitimate interest is used, or at any time in the privacy policy page. These choices will be signaled to our partners and will not affect browsing data. [Cookie policy \(https://www.bmj.com/company/legal-information/bmj-cookie-policy/\)](https://www.bmj.com/company/legal-information/bmj-cookie-policy/)

### We and our partners process data to provide:

Store and/or access information on a device, Personalised ads and content, ad and content measurement, audience insights and product development, Use precise geolocation data, Actively scan device characteristics for identification

### List of Partners (vendors)

I Accept

[Show Purpos](#)

(<https://twitter.com/BMJCaseReports>)



(<https://blogs.bmj.com/case-reports/>)

- Latest content (</content/current>)
- Archive (</content/by/year>)
- **Cookies and privacy** (<https://casereports.bmj.com/pages/global-health/>)

**I Accept**

- For authors (</pages/authors>)
- We and our partners store and/or access information on a device, such as unique IDs in cookies to process personal data. You may accept or manage your choices by clicking below, including your right to object where legitimate interest is used, or at any time in the privacy policy page. These choices will be
- About (<https://casereports.bmj.com/pages/about/>)
- Help (<https://casereports.bmj.com/pages/contact-us/>)

**Show Purpos**

signaled to our partners and will not affect browsing data. **Cookie policy (<https://www.bmj.com/company/legal-information/bmj-cookie-policy/>)**

Home (/) / Editorial Board

**We and our partners process data to provide:**

Store and/or access information on a device, Personalised ads and content, ad and content measurement, audience insights and product development, Use precise geolocation data, Actively scan device characteristics for identification Email alerts

**List of Partners (vendors)**

(<https://myaccount.bmj.com>)

# Editorial Board

*BMJ Case Reports* Editorial Board members have agreed and adhere to the BMJ Editor Roles and Responsibilities guidelines (<https://authors.bmj.com/policies/editor-roles-responsibilities/>); including our Editor policy on competing interests (<https://authors.bmj.com/policies/editor-roles-responsibilities/#Competing%20interests>).

Editor-in-Chief

**Seema Biswas** PhD, FRCS

Declaration of Interests (<http://casereports.bmj.com/pages/wp-content/uploads/sites/69/2022/11/BMJCR-SeemaBiswas-15-10-22-WITHOUT-SIG.pdf>)

Department of Surgery B, Galilee Medical Center

Associate Editors

**Rui Amaral Mendes**

Competing interests >> (<https://casereports.bmj.com/pages/wp-content/uploads/sites/69/2018/08/Amaral-Mendes-Rui.pdf>)

Professor of Oral and Maxillofacial Medicine

Case Western Reserve University

Department of Oral and Maxillofacial Medicine and Diagnostic Sciences

Cleveland, Ohio, USA

**Joseph Francis Sebastian** FRCS

General Surgeon

East Kent Hospitals University, NHS Foundation Trust

Global Health Associate Editors

**Nathan Douthit**

Brookwood Baptist Health Medical Education, Alabama, United States

**Royson Dsouza**

Christian Medical College, Vellore, India

Rural Hospital Network, India

**Chloe Pinto**

Ben Gurion University of the Negev, Beersheba, Israel

**Erez Shir-On**

Ben-Gurion University, Israel

Editor at large

**Dean Jenkins** MB BCh, PgDip(Med Ed), FRCP

Medical Education Advisor On Examination / BMJ Learning

Honorary Senior Lecturer (Diabetes), Cardiff University, UK

Honorary Consultant Physician, Royal Cornwall Hospitals NHS Trust, UK

We and our partners store and/or access information on a device, such as unique IDs in cookies to enhance navigation, improve site usage, and assist in our marketing efforts. You may accept or manage your choices by clicking below, including your right to delete or request that we delete your personal data. You may accept or manage your choices by clicking below, including your right to delete or request that we delete your personal data. You may accept or manage your choices by clicking below, including your right to delete or request that we delete your personal data.

Editorial process personal data. You may accept or manage your choices by clicking below, including your right to delete or request that we delete your personal data. You may accept or manage your choices by clicking below, including your right to delete or request that we delete your personal data.

**Shadab Ahmed** Nassau University United States  
object where legitimate interest is used, or at any time in the privacy policy page. These choices will be signaled to our partners and will not affect browsing data. [Cookie policy \(https://www.bmj.com/company/legal-information/bmj-cookie-policy/\)](https://www.bmj.com/company/legal-information/bmj-cookie-policy/)

**Marco Allinovi** Meyer Children's Hospital, Italy  
device characteristics for identification

**Sambandam Anand** Oxford Radcliffe NHS Trust  
List of Partners (vendors)

device characteristics for identification

Italy measurement, audience insights and product development, Use precise geolocation data, Actively scan

device characteristics for identification

**Sambandam Anand** Oxford Radcliffe NHS Trust  
List of Partners (vendors)

I Accept

Show Purpos

United Kingdom

**Elia Ascer**

University of Sao Paulo  
Brazil

**Carlos Guillen Astete**

Hospital Universitario Ramón y Cajal  
Spain

**Nasuhi Engin Aydin**

Katip Çelebi University  
Turkey

**Cátia Azenha**

Hospital de Braga  
Portugal

**Saumendra Bandyopadhyay**

Calcutta Medical College  
India

**David Barnes**

RPAH Medical Centre  
Australia

**Bruce J Barron**

Emory University Hospital  
United States

**Grant Benfield**

Ysbyty Gwynedd  
United Kingdom

**Julio Benitez**

Infanta Cristina University Hospital & Medical School Badajoz  
Spain

**Peter Berlit**

Alfried-Krupp Hospital  
Germany

**Goran Bicanic**

University of Zagreb School of Medicine  
Croatia

**Marta Biedka**

University of Nicolaus  
Poland

**Michael Binder**

Medical University of Vienna  
Austria

**I Accept**

**Show Purpos**

**Cookies and privacy**

We and our partners store and/or access information on a device, such as unique IDs in cookies to process personal data. You may accept or manage your choices by clicking below, including your right to object where legitimate interest is used, or at any time in the privacy policy page. These choices will be signaled to our partners and will not affect browsing data. [Cookie policy \(https://www.bmj.com/company/legal-information/bmj-cookie-policy/\)](https://www.bmj.com/company/legal-information/bmj-cookie-policy/)

**Rakesh Biswas**

IQ City Medical College and Narayana Hospital  
India

**David Borowski**

Welwitschia Hospital  
Namibia

**We and our partners process data to provide:**

Store and/or access information on a device, Personalised ads and content, ad and content measurement, audience insights and product development, Use precise geolocation data, Actively scan device characteristics for identification

**Patrick Bradley**

University of Nottingham  
United Kingdom

**List of Partners (vendors)**

**JC Brust**

New York Neurological Institute  
United States

**Javier Caballero-Villarraso**  
Reina Sofía University Hospital  
Spain

**Carlos Calderon-Ospina**  
Universidad del Rosario  
Colombia

**Carlo Capra**  
Hospital of Saronno  
Italy

**Andrew Clark**  
University of Hull  
United Kingdom

**Andrew Conway Morris**  
University of Cambridge  
United Kingdom

**Francesca D'Auria**  
Medical University of Rome  
Italy

**Beryl De Souza**  
Chelsea and Westminster Hospital  
United Kingdom

**Fahad Farooqi**  
King George Hospital  
United Kingdom

**Philip Finny**  
Duncan Hospital  
India

**Vaidyanathan Gowri**  
Sultan Qaboos University  
Oman

**Slobodan Grebeldinger**  
Institute of Health Care of Children and Adolescents of Vojvodina  
Serbia

**Ewen Griffiths**  
University Hospitals Birmingham NHS Foundation Trust  
United Kingdom

**Simona Gurzú**  
University of Medicine and Pharmacy of Tirgu-Mures  
Romania

**Akira Hokama**  
University of the Ryukyus  
Japan

**Jee-Fu Huang**  
Kaohsiung Medical University Hospital  
Taiwan

**Tudor Hughes**  
University of California  
United States

## Cookies and privacy

We and our partners store and/or access information on a device, such as unique IDs in cookies to process personal data. You may accept or manage your choices by clicking below, including your right to object where legitimate interest is used, or at any time in the privacy policy page. These choices will be signaled to our partners and will not affect browsing data. [Cookie policy \(https://www.bmj.com/company/legal-information/bmj-cookie-policy/\)](https://www.bmj.com/company/legal-information/bmj-cookie-policy/)

## We and our partners process data to provide:

Store and/or access information on a device, Personalised ads and content, ad and content measurement, audience insights and product development, Use precise geolocation data, Actively scan device characteristics for identification

## List of Partners (vendors)

I Accept

[Show Purpos](#)

**Radwan Kassir**

CHU NORD

France

**Michael Kelly**

Frenchay Hospital

United Kingdom

**Martin Keuchel**

Bethesda Krankenhaus Bergedorf

Germany

**Sri Kollepara**

St John Providence

United Sates

**Pedro Leão**

University of Minho

Portugal

**Jennifer Martin**

Newcastle University

Australia

**Erik Mayer**

Imperial College London

United Kingdom

**Colin Murphy**

Galway University Hospitals

Ireland

**Rosete Nogueira**

University of Minho

Portugal

**David O'Connell**

Redland Hospital

Australia

**Iordanis Papadopoulos**

National and Kapodistrian University of Athens

Greece

**Pallavi Patil**

Brown University

United States

**Francesco Pelliccia**

University Sapienza

Italy

**I Accept**

## **Cookies and privacy**

**Gautam Reddy**

West of Alabama at Birmingham

United States

**Jonathan Rees**

University of Bristol

United Kingdom

### **We and our partners process data to provide:**

**Laurence Solomon**

Royal Preston Hospital

United Kingdom

**Luis Ricardo Souto**

Universidade de Marília (UNIMAR)

### **List of Partners (vendors)**

We and our partners use cookies and/or access information on a device, such as unique IDs in cookies to process personal data. You may accept or manage your choices by clicking below, including your right to object where legitimate interest is used, or at any time in the privacy policy page. These choices will be signaled to our partners and will not affect browsing data. [Cookie policy \(https://www.bmj.com/company/legal-information/bmj-cookie-policy/\)](https://www.bmj.com/company/legal-information/bmj-cookie-policy/)

<https://www.bmj.com/company/legal-information/bmj-cookie-policy/>

United Kingdom

Personalised ads and content, ad and content

management, audience insights and product development, Use precise geolocation data, Actively scan

device characteristics for identification

Brazil

**Jim Thornton**

University of Nottingham  
United Kingdom

**Patrick Twomey**

The Ipswich Hospital  
United Kingdom

**Taro Shimizu**

Dokkyo Medical University Graduate School of Medicine  
Japan

# Publishing team

**Publisher:** Kelly Turner

**Director of Publishing Strategy & Transformation:** Claire Rawlinson

## CONTENT

- Latest content (</content/current>)
- Current issue (</content/current>)
- Archive (</content/by/year>)
- Top cited articles (<https://casereports.bmj.com/pages/top-cited-articles/>)
- Global Health (<https://casereports.bmj.com/pages/global-health/>)
- Browse by collection (<https://casereports.bmj.com/pages/browse-by-topic/>)
- Responses (</eletters>)

## Cookies and privacy

We and our partners store and/or access information on a device, such as unique IDs in cookies to process personal data. You may accept or manage your choices by clicking below, including your right to object where legitimate interest is used, or at any time in the privacy policy page. These choices will be signaled to our partners and will not affect browsing data. [Cookie policy \(https://www.bmj.com/company/legal-information/bmj-cookie-policy/\)](https://www.bmj.com/company/legal-information/bmj-cookie-policy/)

### We and our partners process data to provide:

Store and/or access information on a device, Personalised ads and content, ad and content measurement, audience insights and product development, Use precise geolocation data, Actively scan device characteristics for identification

### List of Partners (vendors)

I Accept

[Show Purpos](#)



(rss-feeds/)

## JOURNAL

- About (<https://casereports.bmj.com/pages/about/>)
- Editorial board (<https://casereports.bmj.com/pages/editorial-board/>)
- Thank you to our reviewers (<https://casereports.bmj.com/pages/thank-you-to-our-reviewers/>)
- Sign up for email alerts (<https://myaccount.bmj.com/myaccount/signup.html?regService=etoc-alerts&corpusCode=bmjcr&fwdUrl=https://casereports.bmj.com/>)
- Fellowships (<https://casereports.bmj.com/pages/fellowships/>)
- COVID-19: a message from BMJ >> (<https://authors.bmj.com/policies/covid-19/>)

I Accept

## Cookies and privacy

**AUTHORS**  
We and our partners store and/or access information on a device, such as unique IDs in cookies to enhance navigation, analyze site usage, assist in our marketing efforts, and help in our marketing efforts. You can control how these cookies are used by adjusting your preferences in your browser settings or by using our Cookie Policy page. These choices will be stored on your device and will not affect your browsing experience. [Cookie policy \(https://www.bmj.com/policies/\)](https://www.bmj.com/policies/)

Show Purpos

- Open Access at BMJ (<https://openaccess.bmj.com/>)
- BMJ Author Hub (<https://authors.bmj.com/>)

**HELP**  
Store and/or access information on a device, Personalised ads and content, ad and content measurement, audience insights and product development, Use precise geolocation data, Actively scan device characteristics for identification

- Contact us (<https://casereports.bmj.com/pages/contact-us/>)
- Reprints (<https://journals.bmj.com/cgi/reprintform>)

- Permissions (<https://www.bmj.com/company/products-services/rights-and-licensing/permissions>)
- Advertising (<https://www.bmj.com/company/for-advertisers-and-sponsor/>)
- Feedback form (<https://myaccount.bmj.com/myaccount/customerservice/salesforce-form.html>)



(<http://www.bmj.com/company>)

- Website Terms & Conditions (<http://www.bmj.com/company/legal-information/>)
- Privacy & Cookies (<http://www.bmj.com/company/your-privacy/>)
- Contact BMJ (<http://www.bmj.com/company/contact-us/>)

[Cookie settings](#)

Online ISSN: 1757-790X

Copyright © 2023 BMJ Publishing Group Ltd. All rights reserved.

## Cookies and privacy

We and our partners store and/or access information on a device, such as unique IDs in cookies to process personal data. You may accept or manage your choices by clicking below, including your right to object where legitimate interest is used, or at any time in the privacy policy page. These choices will be signaled to our partners and will not affect browsing data. [Cookie policy \(https://www.bmj.com/company/legal-information/bmj-cookie-policy/\)](https://www.bmj.com/company/legal-information/bmj-cookie-policy/)

### We and our partners process data to provide:

Store and/or access information on a device, Personalised ads and content, ad and content measurement, audience insights and product development, Use precise geolocation data, Actively scan device characteristics for identification

### List of Partners (vendors)

I Accept

[Show Purpos](#)



OPEN ACCESS

Case report

# Takayasu arteritis in a rural hospital in Indonesia

Michael Lusida ,<sup>1</sup> Mohammad Zakky Kurniawan,<sup>2</sup> Johanes Nugroho<sup>3</sup><sup>1</sup>General Practice and Primary Care, RSUD Dr R Soedarsono, Pasuruan, Indonesia<sup>2</sup>Cardiology, RSUD Dr R Soedarsono, Pasuruan, Indonesia<sup>3</sup>Cardiology, RSUD Dr Soetomo, Surabaya, Surabaya, Indonesia**Correspondence to**Michael Lusida;  
michaellusida@gmail.com

Accepted 28 December 2019

**SUMMARY**

Takayasu arteritis (TA) is a rare chronic granulomatous inflammation of the aorta or its branches and is prevalent all around the world. It causes stenosis of large arteries and ischaemic damage to target organs. There is usually a delay in recognising TA because of the rarity and unfamiliarity with the disease, unspecific early symptoms and lack of diagnostic equipment for early diagnosis. In this report, we present a case of an 18-year-old woman from Pasuruan, East Java, Indonesia, with recurrent fever, headache, claudication of extremities and postprandial abdominal pain. She was diagnosed clinically with suspicion of TA and was sent to a tertiary hospital to confirm the diagnosis. Arteriography revealed that the patient had narrowing of the thoracic and abdominal aorta until the level of the aortic bifurcation. The patient was started on high-dose corticosteroid, cyclosporine A and diltiazem. The patient then showed improvement in her symptoms.

**BACKGROUND**

Takayasu arteritis (TA) is a rare systemic disease more frequently found in Asian countries but is prevalent all over the world. In Japan, 100–200 new cases of TA are found every year. In the United States, the incidence for TA is only approximately 2.6 cases per million people every year.<sup>1–4</sup> To the author's knowledge, there has not been any case report or studies published to date regarding the epidemiology of TA in Indonesia.

TA is a disease that can cause debilitating complications if left untreated. Therefore, early recognition and prompt treatment are key to managing patients with TA.<sup>2–4</sup> Early diagnosis, however, is challenging because of the disease's unspecific early signs and symptoms, especially in locations where medical professionals are not familiar with the disease. Diagnosis of TA becomes more challenging in rural areas where diagnostic arteriography is not available. Herein, we present a case of an 18-year-old woman from Pasuruan, East Java, Indonesia, who was diagnosed with TA.

**CASE PRESENTATION**

An 18-year-old Japanese woman presented to the cardiology office with a 2-year history of chronic recurrent fever and malaise. These episodes of fever were accompanied by headaches and discomfort in her arms and legs, which became more severe with physical activity. She also frequently reported abdominal discomfort after eating. The patient had previously seen a primary care physician and was diagnosed with typhoid fever and was given

antipyretics and antibiotics; however, the symptoms persisted. The patient had a history of uncontrolled hypertension, which was known since she was 7 years old.

During the physical examination, there was a remarkable blood pressure discrepancy between the right and left arms. Blood pressure was 120/90 mm Hg in the left arm and was 142/76 mm Hg in the right arm. The left and right radial pulses were hard to palpate, and the lower extremities were cold and clammy. Her heart rate was 110 beats/min, and her body temperature was 37°C. There was conjunctival pallor and a II/III systolic murmur at the apex. There was also bruit over the left and right carotid and subclavian artery.

**INVESTIGATIONS**

Chest radiography and ECG showed no abnormality. Transthoracic echocardiography showed mitral regurgitation and pulmonic valve prolapse. The abdominal ultrasound showed signs of bilateral renal artery stenosis.

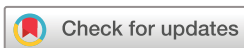Significant laboratory findings included elevated erythrocyte sedimentation rate (ESR) (120 mm/2 hours) and hypochromic microcytic anaemia. The renal and liver function tests were normal.

A tentative diagnosis of TA was made, and the patient was then referred to a tertiary hospital due to limitations of diagnostic equipment in our hospital.

**OUTCOME AND FOLLOW-UP**

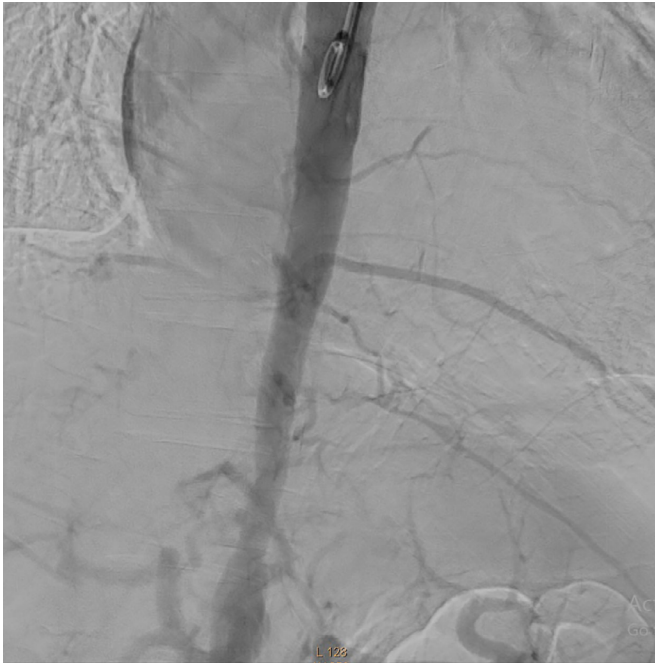In the follow-up, the patient was asymptomatic. Her blood pressure was 120/90 mm Hg in the left arm and 140/90 mm Hg in the right arm. The ESR was 30 mm/2 hours. Transthoracic echocardiography showed mild mitral regurgitation and trivial aortic regurgitation. Aortic catheterisation and digital subtraction angiography (figure 1) had been performed in the tertiary hospital and showed a narrowing of the thoracic and abdominal aorta until the level of aortic bifurcation, with the highest degree of stenosis up to 60% proximal to the branching out of renal arteries (video 1). Subsequent duplex ultrasound showed some stenosis of the right common carotid artery with increased intimamedia thickness (figure 2). Ultrasound of the subclavian and axillary arteries was normal.

The patient received treatment from the tertiary hospital, which comprised oral methylprednisolone (40 mg/day), oral cyclosporine (50 mg/day) and oral diltiazem (100 mg/day). Methylprednisolone was then gradually tapered to 8 mg/day. With the



© BMJ Publishing Group Limited 2020. Re-use permitted under CC BY-NC. No commercial re-use. See rights and permissions. Published by BMJ.

**To cite:** Lusida M, Kurniawan MZ, Nugroho J. *BMJ Case Rep* 2020;**13**:e230884. doi:10.1136/bcr-2019-230884




**Figure 1** The digital subtraction angiography of the thoracic and the abdominal aorta.

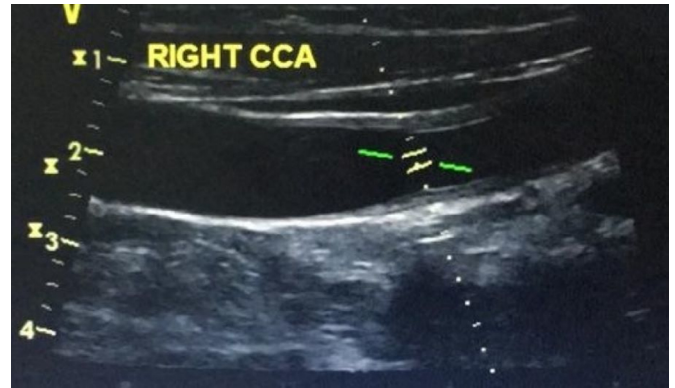
treatment, the patient remains asymptomatic until the writing of this case report.

## DISCUSSION

In our case, an 18-year-old woman presented with recurrent fever, claudication of limbs, postprandial abdominal pain, a difference of >10 mm Hg in systolic blood pressure between arms and bruits that could be heard along both the carotid and subclavian arteries. These were caused by the narrowing of the subclavian artery and the abdominal aorta and reflected



**Video 1** The digital subtraction angiography showing a narrowed thoracic and abdominal aorta.



**Figure 2** The duplex ultrasound of the right common carotid artery showing narrowing and increased intima-media thickening (1.79 mm).

end-organ ischaemia. Even without arteriography, the clinical findings in our patient met four out of six TA criteria defined by the American College of Rheumatology.<sup>1 3 5 6</sup> The presence of three or more out of the six criteria is known to have a sensitivity of 90.5% and specificity of 97.8%.<sup>5 6</sup> Our patient also met all the clinical criteria European League Against Rheumatism/Pediatric Rheumatology International Trials Organization/Pediatric Rheumatology European Society criteria for childhood TA, which has a sensitivity and specificity of 100% and 99.9%.<sup>6 7</sup> TA was then suspected, and the narrowing of the blood vessel was then confirmed by digital subtraction arteriography and duplex ultrasound done in the tertiary hospital.

Differential diagnoses, in this case, include other primary vasculitides, which can manifest as constitutional symptoms, joint pain and muscle weakness. These vasculitides include giant cell arteritis, polyarteritis nodosa, Henoch-Schonlein purpura, granulomatosis with polyangiitis (GPA) and eosinophilic granulomatosis with polyangiitis (EGPA). Giant cell arteritis usually manifests in older women and can be ruled out due to the early age of onset of the disease.<sup>8</sup> Polyarteritis nodosa usually manifests as renal insufficiency, neuropathy, with alternating microaneurysm and constriction of the affected blood vessels in arteriography.<sup>9</sup> The absence of renal insufficiency, neuropathy and imaging findings rules out this disease. Henoch-Schonlein purpura is a small vessel vasculitis that usually affects children. It manifests as palpable purpura on the lower half of the body and glomerulonephritis, the absence of which rules out the disease.<sup>10</sup> Microscopic polyangiitis and GPA are small to middle size vessel vasculitides that usually manifest as haematuria and haemoptysis.<sup>11</sup> EGPA is similar to GPA with the addition of >10% eosinophilia and a history of asthma.<sup>12</sup> These three vasculitides are known for their association with positive serum antineutrophilic antibodies (ANCA).<sup>11 12</sup> While a test for serum ANCA was not available in our hospital, our patient did not have the usual findings attributed to these diseases, such as skin lesion, haemoptysis and renal insufficiency. None of the vasculitides mentioned above has a discrepancy of blood pressures between the right and the left arm as a clinical finding.<sup>8-12</sup>

In our patient, the disease affected both the superior branches of the aorta, as supported by the physical examination, and the abdominal aorta, with the highest degree of stenosis in the abdominal aorta. This clinical presentation matches type V TA, as classified in the Takayasu Conference in 1994.<sup>13</sup>

The treatment for TA consists of immunosuppressant therapy. High-dose corticosteroid is the mainstay of the therapy, although tapering of the dose can sometimes cause relapses of the disease.

It is recommended to add a second immunosuppressive agent such as methotrexate, cyclosporine A, tacrolimus, azathioprine, cyclophosphamide and mycophenolate mofetil.<sup>3 13 14</sup> In this patient, diltiazem is also added to manage hypertension.

Multiple studies have shown the benefit of stenting or surgery to correct severe stenosis.<sup>14 15</sup> Indications for surgery include uncontrolled hypertension as a consequence of renal artery stenosis, severe symptomatic coronary artery or cerebrovascular disease, severe aortic regurgitation or coarctation, stenotic or occlusive lesions resulting in critical limb ischaemia and aneurysms at risk of rupture.<sup>15</sup>

As noted above, TA is a disease of chronic granulomatous inflammation of the aorta or its branches. This inflammation will eventually cause fibrinoid necrosis, and fibrosis, narrowing and aneurysm of the vessel wall.<sup>1 13</sup> TA manifestation can be divided into two phases: an initial phase of unspecific findings, for example, fever, malaise and headache, and a late stenotic phase characterised by findings such as hypertension, claudication, pulselessness, bruit and angina.<sup>1 13 14 16 17</sup> If left untreated, TA will eventually cause irreversible target organ damage and severe morbidity.

The diagnosis of TA has always been a challenge. Multiple case reports and studies have shown that the diagnosis of TA is usually delayed 10 months to 12 years, with 91% of patients reporting having seen at least one physician before diagnosis.<sup>15 18 19</sup> By the time of diagnosis, the patient usually has already suffered significant morbidity. In our case, the diagnosis was delayed by 2 years. However, the disease may have existed for a longer period since it cannot be ascertained whether the patient's childhood hypertension had been a result of TA progression.

This delay of diagnosis can be attributed to a few factors. First, both the early and late manifestation of TA is not specific.<sup>17 19</sup> Laboratory findings include acute-phase reactant markers or ESR, which are not specific for TA.<sup>13–15 18</sup> The advent of non-invasive imaging modalities, for example, MR arteriography (MRA), CT angiography (CTA) and positron emission tomography with <sup>18</sup>F-FDG (FDG-PET), have helped diagnose TA even in the prestenotic phase.<sup>15 18–20</sup> FDG-PET is a functional imaging tool that can detect inflammation in the vessel wall and has a demonstrated pooled sensitivity of 87% and specificity of 73% for the assessment of TA. MRA and CTA are usually used in conjunction with FDG-PET to detect structural changes and complications.<sup>20</sup> These tools, however, are not readily available in rural hospitals. They are also very expensive and are not covered by the Indonesian government health insurance programme, which is the primary method of payment used in rural areas. Therefore, the most crucial factor of early diagnosis is the physician's awareness of the clinical findings.<sup>15 18 19</sup>

Although not specific, duplex ultrasound can provide evidence of stenosis in the arteries affected by TA.<sup>21</sup> In our patient, duplex ultrasound performed in the tertiary hospital showed stenosis in the right common carotid artery with increased intimamedial thickness (figure 2). The classic finding of TA in ultrasound is stenosis with a homogeneous hypoechoic circumferential thickening of the intimamedia complex, also known as the macaroni sign. This finding is absent in our patient, most likely due to the ultrasound being performed after months of treatment.

Another cause of delay in this patient lies in the unfamiliarity of physicians with the disease.<sup>18 19</sup> Indonesia is a tropical country and is endemic to many infectious diseases, such as enteric fever. Therefore, it is more likely that infectious disease is suspected first in a patient with fever.<sup>22</sup> Another cause of unfamiliarity with TA is the rarity of the disease and the lack of case reports or studies about TA in Indonesia.

### Box 1 Red flag findings for Takayasu arteritis in patients under the age of 40 years

Carotidynia  
Angina  
Limb claudication  
Absent/weak peripheral pulses  
Hypertension  
Discrepant blood pressure in the upper limbs (>10 mm Hg)  
Arterial bruits  
Aortic regurgitation  
Unexplained acute-phase response (elevated erythrocyte sedimentation rate or C-reactive protein)

Since the most important factor for early diagnosis of TA is the physician's awareness of the findings, Nazareth and Mason proposed 'red flag' signs and symptoms that should direct physicians' suspicion to TA (box 1).<sup>18</sup> In this patient, seven out of nine findings were found in our patient.

### Learning points

- ▶ Early diagnosis is paramount in managing Takayasu arteritis (TA) to prevent morbidity
- ▶ In tropical areas, physicians should always consider TA in a patient with recurrent fever and increased acute-phase reactants, while eliminating infection as a possible cause.
- ▶ Difficulties of diagnosing TA in rural setting includes the rarity and unfamiliarity with the disease, unspecific early symptoms and lack of diagnostic equipment for early diagnosis.
- ▶ More studies should be done regarding TA in Indonesia.

**Contributors** ML is responsible for the acquisition of the clinical information of the patient and drafting the manuscript. MZK is responsible for the conception, revision and the approval of the manuscript. JN contributed to the revision and the approval of the manuscript and provided the image and video used in the manuscript.

**Funding** The authors have not declared a specific grant for this research from any funding agency in the public, commercial or not-for-profit sectors.

**Competing interests** None declared.

**Patient consent for publication** Obtained.

**Provenance and peer review** Not commissioned; externally peer reviewed.

**Open access** This is an open access article distributed in accordance with the Creative Commons Attribution Non Commercial (CC BY-NC 4.0) license, which permits others to distribute, remix, adapt, build upon this work non-commercially, and license their derivative works on different terms, provided the original work is properly cited and the use is non-commercial. See: <http://creativecommons.org/licenses/by-nc/4.0/>.

### ORCID iD

Michael Lusida <http://orcid.org/0000-0002-0172-3329>

### REFERENCES

- 1 Hall S, Barr W, Lie JT, et al. Takayasu arteritis. A study of 32 North American patients. *Medicine* 1985;64:89–99.
- 2 Jain S, Kumari S, Ganguly NK, et al. Current status of Takayasu arteritis in India. *Int J Cardiol* 1996;54(Suppl):S111–6.
- 3 Johnston SL, Lock RJ, Gompels MM. Takayasu arteritis: a review. *J Clin Pathol* 2002;55:481–6.
- 4 Numano F, Kobayashi Y. Takayasu arteritis—beyond pulselessness. *Intern Med* 1999;38:226–32.
- 5 Arend WP, Michel BA, Bloch DA, et al. The American College of rheumatology 1990 criteria for the classification of Takayasu arteritis. *Arthritis Rheum* 1990;33:1129–34.
- 6 de Souza AWS, de Carvalho JF. Diagnostic and classification criteria of Takayasu arteritis. *J Autoimmun* 2014;48:49:79–83.



- 7 Ozen S, Pistorio A, Iusan SM, *et al.* EULAR/PRINTO/PRES criteria for Henoch-Schönlein purpura, childhood polyarteritis nodosa, childhood Wegener granulomatosis and childhood Takayasu arteritis: Ankara 2008. Part II: final classification criteria. *Ann Rheum Dis* 2010;69:798–806.
- 8 Alberts M. Temporal arteritis: improving patient evaluation with a new protocol. *Perm J* 2013;17:56–62.
- 9 He Q, Shu J, Chen F, *et al.* Analysis of the clinical characteristics and follow-up study of children with cutaneous polyarteritis nodosa. *Curr Neurovasc Res* 2019;16:208–14.
- 10 Hetland LE, Susrud KS, Lindahl KH, *et al.* Henoch-Schönlein purpura: a literature review. *Acta Derm Venereol* 2017;97:1160–6.
- 11 Lutalo PMK, D’Cruz DP. Diagnosis and classification of granulomatosis with polyangiitis (AKA Wegener’s granulomatosis). *J Autoimmun* 2014;48-49:94–8.
- 12 Groh M, Pagnoux C, Baldini C, *et al.* Eosinophilic granulomatosis with polyangiitis (Churg-Strauss) (EGPA) consensus Task force recommendations for evaluation and management. *Eur J Intern Med* 2015;26:545–53.
- 13 Mann DL, Zipes D, Libby P, *et al.*, eds. *Braunwald’s heart disease: a textbook of cardiovascular medicine, single volume*. 10th edn. Philadelphia, PA: Elsevier/Saunders, 2015.
- 14 Keser G, Direskeneli H, Aksu K. Management of Takayasu arteritis: a systematic review. *Rheumatology* 2014;53:793–801.
- 15 Perera AH, Mason JC, Wolfe JH. Takayasu arteritis: criteria for surgical intervention should not be ignored. *Int J Vasc Med* 2013;2013:8.
- 16 Espinoza JL, Ai S, Matsumura I. New insights on the pathogenesis of Takayasu arteritis: revisiting the microbial theory. *Pathogens* 2018;7:E73.
- 17 Lee S-H, Lee MJ, Kang B, *et al.* A case report of patient with Takayasu’s arteritis complicated by reversible cerebral vasoconstriction syndrome. *J Rheum Dis* 2013;20:194.
- 18 Nazareth R, Mason JC. Takayasu arteritis: severe consequences of delayed diagnosis. *QJM* 2011;104:797–800.
- 19 Watson L, Brogan P, Peart I, *et al.* Diagnosis and assessment of disease activity in Takayasu arteritis: a childhood case illustrating the challenge. *Case Rep Rheumatol* 2014;2014:6.
- 20 Slart RHJA, Writing group, Reviewer group. FDG-PET/CT(A) imaging in large vessel vasculitis and polymyalgia rheumatica: joint procedural recommendation of the EANM, SNMMI, and the PET Interest Group (PIG), and endorsed by the ASNC. *Eur J Nucl Med Mol Imaging* 2018;45:1250–69.
- 21 Siepmann T, Bodechtel U. Teaching NeuroImages: macaroni sign. *Neurology* 2014;83:e11.
- 22 Purba I, Wandura T, Nugrahini N, *et al.* Program Pengendalian Demam Tifoid di Indonesia: Tantangan DAN Peluang. *Media Penelitian dan Pengembangan Kesehatan* 2016;26.

Copyright 2020 BMJ Publishing Group. All rights reserved. For permission to reuse any of this content visit <https://www.bmj.com/company/products-services/rights-and-licensing/permissions/>  
 BMJ Case Report Fellows may re-use this article for personal use and teaching without any further permission.

Become a Fellow of BMJ Case Reports today and you can:

- ▶ Submit as many cases as you like
- ▶ Enjoy fast sympathetic peer review and rapid publication of accepted articles
- ▶ Access all the published articles
- ▶ Re-use any of the published material for personal use and teaching without further permission

### Customer Service

If you have any further queries about your subscription, please contact our customer services team on +44 (0) 207111 1105 or via email at [support@bmj.com](mailto:support@bmj.com).

Visit [casereports.bmj.com](http://casereports.bmj.com) for more articles like this and to become a Fellow