

Acute Limb Ischemia in the Young: A Rare Case of Essential Thrombocytosis

by Johannes Nugroho

Submission date: 22-Jan-2023 03:02PM (UTC+0800)

Submission ID: 1996838643

File name: 01ACUT_1.PDF (1.27M)

Word count: 2665

Character count: 15204

Case Report

Acute Limb Ischemia in the Young: A Rare Case of Essential Thrombocytosis

Johanes Nugroho^{1,2} and Ruth Gunadi²

¹Department of Cardiology and Vascular Medicine, Faculty of Medicine, Universitas Airlangga, Surabaya, Indonesia

²Dr. Soetomo General Hospital, Surabaya, Indonesia

Correspondence should be addressed to Johannes Nugroho; j.nugroho.eko@fk.unair.ac.id

Received 27 June 2021; Accepted 3 November 2021; Published 20 November 2021

Academic Editor: Yigit Canga

Copyright © 2021 Johannes Nugroho and Ruth Gunadi. This is an open access article distributed under the Creative Commons Attribution License, which permits unrestricted use, distribution, and reproduction in any medium, provided the original work is properly cited.

Acute limb ischemia (ALI) is rarely observed in young populations. The hypercoagulable state is a notable cause of ALI other than artery disease progression and cardiac embolization. A hypercoagulable state occurs in essential thrombocytosis because of the overproduction of hematopoietic cells secondary to the mutation of the JAK2, CALR, or MPL genes. We report a rare case of a 37-year-old woman presenting with Rutherford IIA ALI in the left lower extremity. Laboratory data revealed she had a platelet count reaching up to 1.38 mil/ μ L, with other blood profiles being normal. A JAK2 mutation examination was later performed and proved positive. After careful management with catheter-directed thrombolysis, surgical thrombectomy, and cytoreductive therapy using hydroxyurea, the symptoms subsided and eventually restored the patient to physical activity in less than one month.

1. Introduction

Patients with peripheral arterial disease (PAD) are at risk for ischemic events, which can cause significant morbidity and reduce functional status and the quality of life. Acute limb ischemia (ALI), which results from a sudden decrease in limb perfusion, can cause tissue death and threaten limb viability [1]. Sudden decreased perfusion can be caused either by progressive arterial disease, cardiac embolization, hypercoagulable disease, or complications related to vascular procedures [2]. A part of the hypercoagulation spectrum is essential thrombocytosis (ET). The incidence of ET increases with age, with most patients presenting between the ages of 50 and 60 years [3]. There have been previous case reports of cardiovascular involvement with ET in the fourth decade but not ALI with ET [4]. Hence, a young woman presenting with a complication of ET is considered rare.

2. Case Presentation

A 37-year-old female patient presented with a chief complaint of pain in the toes of her left foot since approximately 1-week prior to hospitalization. She complained of persistent

pain which was aggravated with mobilization. In addition, her left toes often felt numb accompanied by a tingling sensation, with a bluish and pale colorization. She denied any current use of medication or prior hospitalizations, and her past medical history was otherwise unremarkable. She had two biological children, both born per vaginam. On physical examination, she had tachycardia with an initial heart rate of 102 beats per minute. Left inferior extremity assessment revealed a weakened pulsation in her left femoral artery, an absence of distal pulsations, and dry, cold, and pale digits (first to fifth) (Figure 1). Motoric abilities were unimpaired, but sensory impairment (numbness) was observed in her left foot.

Electrocardiogram, chest radiograph, and transthoracic echocardiography revealed no abnormality or intracardiac thrombus. Doppler ultrasound of the lower extremity arteries revealed triphasic waves in the right superficial femoral artery. For the left inferior extremity, a thrombus was documented in the common femoral artery (CFA); hence, arterial flow from the CFA towards the distal end was difficult to evaluate.

The patient's initial platelet count was $812 \times 103/\mu$ L, while other routine blood profiles were within normal limits. A blood smear test showed thrombocytosis with giant platelets, leukocytosis, and immature granulocytes. Subsequently,

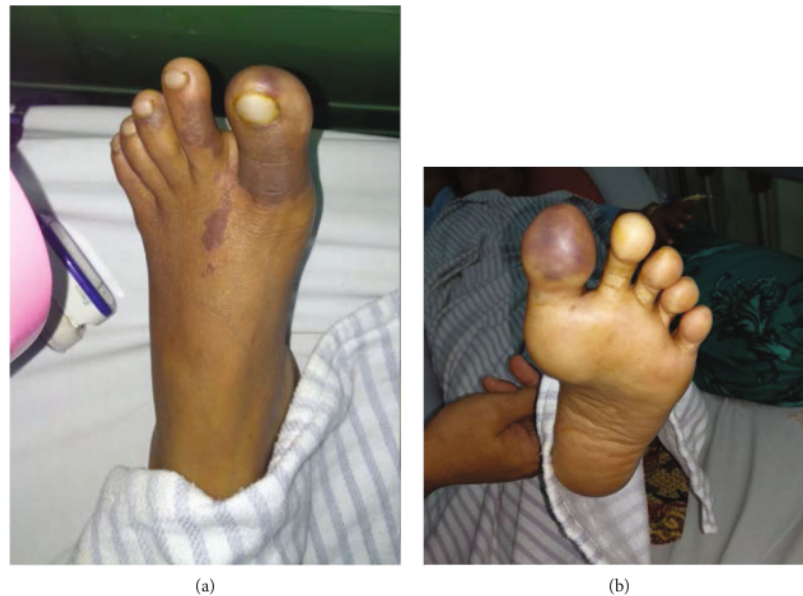

FIGURE 1: Image of dorsal (a) and ventral (b) views of the left foot in the initial settings with bluish pale area mostly distributed in digits I and II.

a JAK-2 mutase examination was performed based on the suspicion of ET.

She then underwent an arteriography (Figure 2) with catheter-directed thrombolysis (CDT). A 6-French pigtail catheter was inserted through the right femoral artery and directed towards the left femoral artery. Digital subtraction cineangiography was performed using an injection of 10 mL of contrast with an anteroposterior projection. Arteriography revealed a thrombus that was as high as the left distal CFA. A total of 100,000 units of Fibrion (Streptokinase) was injected into the left femoral artery. No complications occurred during or after the procedure.

After the procedure, the patient was admitted to the intensive cardiac care unit and administered 100,000 units/hour of streptokinase via CDT, with hourly clinical evaluation and monitoring. At clinical evaluation 2 hours postarteriography, she complained of severe pain in her left lower leg. Accordingly, the patient was scheduled for emergency surgical thrombectomy. Antegrade and retrograde surgical thrombectomy of the posterior tibial artery was performed, with results of restored flow of the left popliteal artery and posterior tibial artery. During inpatient treatment, the platelet count increased drastically (from $812 \times 103/\mu\text{L}$ to $1.380 \times 103/\mu\text{L}$).

Once the diagnosis of ET was established, medical therapy was started immediately with hydroxyurea and clopidogrel once daily at doses of 1,000 mg and 75 mg, respectively. At the one-month follow-up, her platelet count had decreased by half to $434 \times 103/\mu\text{L}$ with improved clinical results. At the six-month follow-up, a marked reduction in cyanotic areas was observed throughout the first and second digits, with improved mobility and daily performance (Figure 3).

3. Discussion

Along with revascularization, etiological evaluation of ALI has become a priority, especially if the patient belongs to a young demographic, considering that the incidence of ALI occurs mostly in the elderly with various comorbidities. In the present case, the patient was a young woman who had no prior history of comorbidities; thus, an event such as ALI warrants considerations of etiologies beyond the more common ones.

Progressive arterial disease deemed unlikely due to her young age and no intracardiac thrombus on echocardiography. Hence, differential diagnoses include hypercoagulable states and myeloproliferative (MPN) disorders, which can manifest in thrombosis and symptoms of ALI in the young population. Since our patient's hematology data suggested high platelet levels in three separate occasions, with other hematology profile to be normal, our suspicion was focused on MPN disorders. According to recent observational studies, there were three common MPN disorders in the young: polycythemia vera (PV), essential thrombocytosis (ET), and primary myelofibrosis (PMF) [5, 6]. Since our patient's Hb and Hct levels were normal, PV became less suspicious. In PMF, although sharing a common JAK2, CALR, or MPL mutation, anemia is typically present and increases over time accompanied by mild to moderate leukocytosis, mild to marked thrombocytosis, abnormal cytokine expression, cachexia, and hepatosplenomegaly [7, 8]. With clinical signs and symptoms suggestive of ET, supported by positive JAK2 V617F mutation, the diagnosis of ET was established.

The incidence of ET varies from 1.0 to 2.5 per 100,000 individuals/year, with a prevalence of 38–57 per 100,000 individuals reported between 2008 and 2010, mostly among

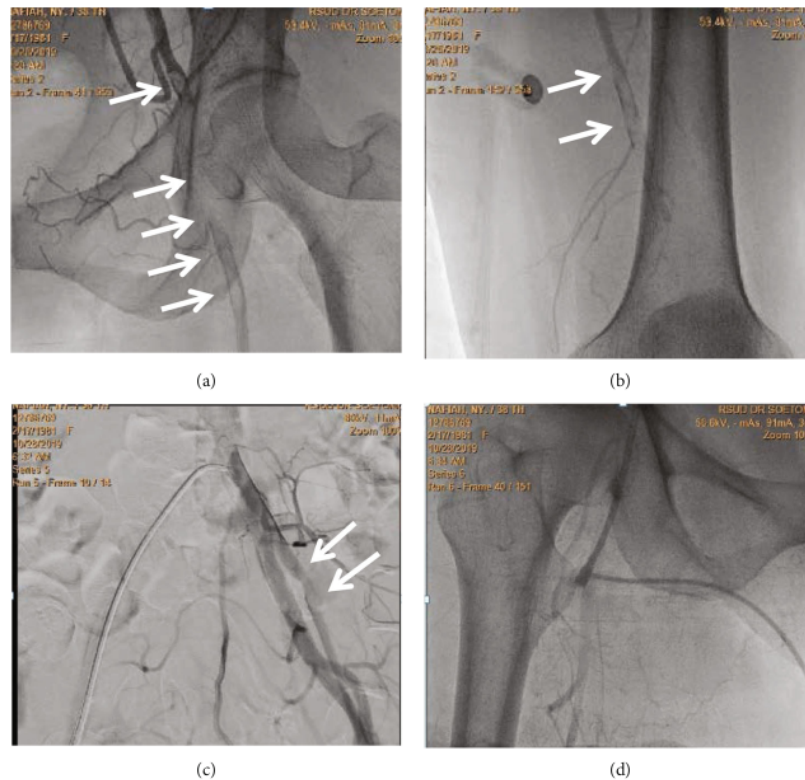


FIGURE 2: Arteriographic findings of the inferior extremities show that diffuse thrombus was visualized in the left common femoral artery (a) continuing until the superficial femoral artery and distal femoral artery (b). A thrombus appears on left external iliac artery (c). Contrast flow is normal in the right inferior limb (d).

women [3, 9]. According to the World Health Organization, ET is a disease that occurs when the platelet count is more than $450 \times 10^3/\mu\text{L}$ with proven mutations in Janus kinase 2 (JAK2) and calreticulin (CALR), or mutations in the oncogene leukemia myeloproliferative oncogene (MPL) virus, with exclusion of clonal disease or reactive causes [10]. Approximately 50% of patients with ET have JAK2 mutations [3].

Thrombosis is the most common cause of mortality and morbidity in patients with ET. The incidence of thrombosis is approximately 20%, followed by the incidence of bleeding (10%), and the estimated incidence of conversion (from thrombosis to hemorrhage) is less than 1% [9, 11]. In general, the management of ET includes control of cardiovascular risk factors and cytoreductive therapy, for example, hydroxyurea, in patients who are at high risk of thrombotic events [12]. Treatment with low-dose acetylsalicylic acid (aspirin) is crucial for the prevention of primary and secondary thrombosis in this patient group [13]. However, in patients with ALI, single antiplatelet therapy (SAPT) with clopidogrel is the preferred choice [2]. Hydroxyurea 500–1000 mg once daily is the first line of choice in most patients because of its effective thrombotic reduction profile with minimal side effects [14]. The aim of the treatment is to

maintain a platelet count of $<400 \times 10^3/\mu\text{L}$ [13, 14]. Although the patient in the present case achieved a platelet count as low as $434 \times 10^3/\mu\text{L}$, the therapy target was not achieved due to poor regular intake of hydroxyurea, as the patient lived in a rural area and had limited access to cytoreductive drugs.

Long-term anticoagulant therapy may be combined with SAPT when a revascularization procedure is performed. Treatment using anticoagulants and SAPT can be considered for more than 1 month in patients with high ischemic risk or when there are other strong indications for long-term SAPT [2]. ET combined with ALI is classified in the high ischemic risk group; thus, it is advisable to administer SAPT and oral anticoagulants for >1 month, and doses should be monitored with a target International Normalized Ratio of 2.0–2.5 [2, 15]. Thus, our patient had increased mobile activity in less than two months after receiving proper revascularization and medication. ET is an indolent disease with a good prognosis. The reported life expectancy is 33 years, and in younger patients, it is 60 years [16]. Although indolent, ET patients have poorer life expectancy than the general population due to thrombotic events that may complicate the disease [17].

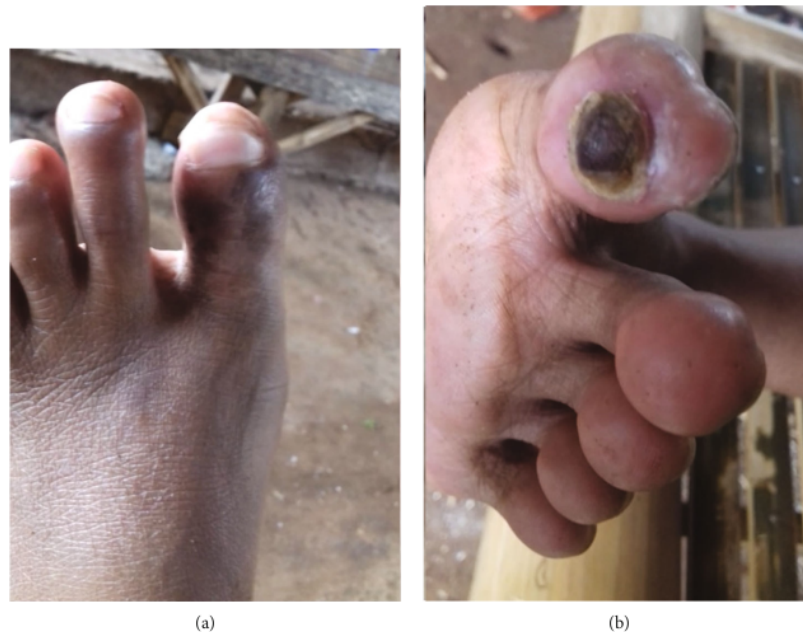

FIGURE 3: Image of dorsal (a) and ventral (b) views of the left foot in the six-month follow-up, with significant clearing of cyanotic area.

In cases of ALI associated with neurological deficits, immediate revascularization is mandatory; investigations and imaging should not delay patient revascularization interventions [13]. Various revascularization modalities can be applied, including percutaneous CDT, percutaneous mechanical thrombus extraction or thrombus aspiration (with or without thrombolytic therapy), and surgical thrombectomy, bypass, and/or arterial repair. The choice of a revascularization strategy will depend on the presence of a neurologic deficit, duration of ischemia, localization, comorbidity, type of blood vessel (artery or graft), and therapy-related risk and outcome. Because of favorable morbidity and mortality rates, endovascular therapy is often preferred by clinicians, especially in patients with severe comorbidities [1, 18].

The modern concept of combined intraarterial thrombolysis and catheter-based clot removal can achieve an amputation rate of <10% within 6 months [1]. In the present case, due to a moderate neurological deficit, percutaneous CDT was performed immediately as soon as the ALI diagnosis was established. However, during follow-up, the patient's condition did not improve and prompted surgical thrombectomy. Subsequently, combined with adequate antithrombotic and hydroxyurea, her clinical condition and performance allowed her to be discharged after 10 days of hospitalization.

4. Conclusion

Cases of acute limb ischemia (ALI) in the young population are rare and should trigger investigations to determine the underlying cause. A frequently overlooked etiology of ALI is hypercoagulability, including essential thrombocytosis, which may cause extreme thrombocytosis, bleeding, or

progressive arterial damage due to erythromelalgia. Revascularization interventions and medical therapy must be performed according to clinical protocols and indications. Long-term cytoreductive therapy with hydroxyurea is usually sufficient to control platelet count and prevent complications of thrombocytosis in patients with essential thrombocytosis.

Data Availability

The data supporting this case report are from previously reported studies and datasets, which have been cited.

Disclosure

This work did not receive specific funding but was performed as part of Johannes Nugroho's employment at the Department of Cardiology and Vascular Medicine, Universitas Airlangga/ Dr. Soetomo General Hospital, East Java, Indonesia.

Conflicts of Interest

The authors declare that the research was conducted in the absence of any commercial or financial relationships that could be considered a potential conflict of interest.

References

- [1] C. N. Hess, Z. Huang, M. R. Patel et al., "Acute limb ischemia in peripheral artery disease," *Circulation*, vol. 140, no. 7, pp. 556–565, 2019.
- [2] V. Aboyans, J. B. Ricco, M. E. L. Bartelink et al., "2017 ESC guidelines on the diagnosis and treatment of peripheral arterial

- diseases, in collaboration with the European Society for Vascular Surgery (ESVS): document covering atherosclerotic disease of extracranial carotid and vertebral, mesenteric, renal, upper and lower extremity arteries endorsed by: the European Stroke Organization (ESO). The task force for the diagnosis and treatment of peripheral arterial diseases of the European Society of Cardiology (ESC) and of the European Society for Vascular Surgery (ESVS)," *European Heart Journal*, vol. 39, no. 9, pp. 763–816, 2018.
- [3] J. Nangalia and A. R. Green, "Myeloproliferative neoplasms: from origins to outcomes," *Hematology 2014, the American Society of Hematology Education Program Book*, vol. 2017, no. 1, pp. 470–479, 2017.
- [4] P. Sharma, S. Gupta, P. Patel, Y. Zhang, and S. Peles, "Acute ST-segment elevation myocardial infarction as the first manifestation of essential thrombocytosis," *Cureus*, vol. 11, no. 2, article e4032, 2019.
- [5] Gruppo Italiano Studio Policitemia, "Polycythemia vera: the natural history of 1213 patients followed for 20 years," *Annals of Internal Medicine*, vol. 123, no. 9, pp. 656–664, 1995.
- [6] A. Alvarez-Larrán, F. Cervantes, B. Bellosillo et al., "Essential thrombocythemia in young individuals: frequency and risk factors for vascular events and evolution to myelofibrosis in 126 patients," *Leukemia*, vol. 21, no. 6, pp. 1218–1223, 2007.
- [7] L. A. Raedler, "Diagnosis and management of polycythemia vera," *American health & drug benefits*, vol. 7, 7 supplement 3, pp. S36–S47, 2014.
- [8] A. Tefferi, "Primary myelofibrosis: 2019 update on diagnosis, risk-stratification and management," *American Journal of Hematology*, vol. 93, no. 12, pp. 1551–1560, 2018.
- [9] B. Meier and J. H. Burton, "Myeloproliferative disorders," *Hematology/Oncology Clinics of North America*, vol. 31, no. 6, pp. 1029–1044, 2017.
- [10] A. Tefferi, J. Thiele, A. Orazi et al., "Proposals and rationale for revision of the World Health Organization diagnostic criteria for polycythemia vera, essential thrombocythemia, and primary myelofibrosis: recommendations from an ad hoc international expert panel," *Blood*, vol. 110, no. 4, pp. 1092–1097, 2007.
- [11] M. C. Soucy-Giguère, P. Y. Turgeon, and M. Sénéchal, "What cardiologists should know about essential thrombocythemia and acute myocardial infarction: report of two cases and advanced heart failure therapies considerations," *International medical case reports journal*, vol. 12, pp. 253–259, 2019.
- [12] F. Cervantes, "Management of essential thrombocythemia," *Hematology. American Society of Hematology. Education Program*, vol. 2011, no. 1, pp. 215–221, 2011.
- [13] N. Hiranuma, "TCTAP C-193 Critical Lower Limb Ischemia Due to Essential Thrombocytosis," *Journal of the American College of Cardiology*, vol. 71, no. 16, pp. S265–S266, 2018.
- [14] C. N. Harrison, P. J. Campbell, G. Buck et al., "Hydroxyurea compared with anagrelide in high-risk essential thrombocythemia," *The New England Journal of Medicine*, vol. 353, no. 1, pp. 33–45, 2005.
- [15] J. S. Bleeker and W. J. Hogan, "Thrombocytosis: diagnostic evaluation, thrombotic risk stratification, and risk-based management strategies," *Thrombosis*, vol. 2011, Article ID 536062, 16 pages, 2011.
- [16] A. Tefferi, P. Guglielmelli, D. R. Larson et al., "Long-term survival and blast transformation in molecularly annotated essential thrombocythemia, polycythemia vera, and myelofibrosis," *Blood*, vol. 124, no. 16, pp. 2507–2513, 2014.
- [17] L. Falchi, H. M. Kantarjian, and S. Verstovsek, "Assessing the thrombotic risk of patients with essential thrombocythemia in the genomic era," *Leukemia*, vol. 31, no. 9, pp. 1845–1854, 2017.
- [18] E. A. Natelson, "Extreme thrombocytosis and cardiovascular surgery: risks and management," *Texas Heart Institute Journal*, vol. 39, no. 6, pp. 792–798, 2012.

Acute Limb Ischemia in the Young: A Rare Case of Essential Thrombocytosis

ORIGINALITY REPORT

10%

SIMILARITY INDEX

5%

INTERNET SOURCES

8%

PUBLICATIONS

1%

STUDENT PAPERS

PRIMARY SOURCES

- 1 "27th Annual Meeting Chicago, Illinois May 12-15, 2004", *Journal of General Internal Medicine*, 01/2004
Publication 1%
- 2 Mari Kondo, Haruka Okazaki, Kei Nakayama, Hirofumi Hohjoh, Kimie Nakagawa, Eri Segi-Nishida, Hiroshi Hasegawa. "Characterization of Astrocytes in the Minocycline-Administered Mouse Photothrombotic Ischemic Stroke Model", *Neurochemical Research*, 2022
Publication 1%
- 3 www.dovepress.com
Internet Source 1%
- 4 www.science.gov
Internet Source 1%
- 5 www.medrxiv.org
Internet Source 1%
- 6 Submitted to Nanyang Polytechnic
Student Paper 1%

- 7 Spyridon G Deftereos, Dimitrios A Vrachatis, Christos Tolis, Georgios Giannopoulos. "Invasive treatment in peripheral artery disease", *Current Opinion in Pharmacology*, 2018
Publication 1 %
-
- 8 www.jstage.jst.go.jp
Internet Source 1 %
-
- 9 "Abstracts from the 30th Annual Meeting of the Society of General Internal Medicine", *Journal of General Internal Medicine*, 2007
Publication <1 %
-
- 10 Soedarsono Soedarsono, Anna Febriani, Helmia Hasan, Anita Widyoningroem. "Management of severe COVID-19 patient with negative RT-PCR for SARS-CoV-2: Role of clinical, radiological, and serological diagnosis", *Radiology Case Reports*, 2021
Publication <1 %
-
- 11 Weingarten, Toby N., Ryan E. Hofer, Barrett J. Ahle, Keri M. Kemp, Jacinta A. Nkwonta, Bradly J. Narr, Animesh Pardhanani, Darrell R. Schroeder, and Juraj Sprung. "Perioperative blood product administration and thromboembolic events in patients with treated polycythemia vera: a case-control study : Polycythemia and Bleeding", *Transfusion*, 2015. <1 %

12 www.karger.com <1 %
Internet Source

13 www.medicopublication.com <1 %
Internet Source

14 Barbui, T, J Thiele, A M Vannucchi, and A Tefferi. "Rationale for revision and proposed changes of the WHO diagnostic criteria for polycythemia vera, essential thrombocythemia and primary myelofibrosis", Blood Cancer Journal, 2015.
Publication

15 J. J. Michiels, T. Barbui, G. Finazzi, S. M. Fuchtman, J. Kutti, J. D. Rain, R. T. Silver, A. Tefferi, J. Thiele. "Diagnosis and Treatment of Polycythemia Vera and Possible Future Study Designs of the PVSG", Leukemia & Lymphoma, 2009
Publication

16 Jörn F. Dopheide, Lucija Papac, Marc Schindewolf, Iris Baumgartner, Heinz Drexel. "Poor attainment of lipid targets in patients with symptomatic peripheral artery disease", Journal of Clinical Lipidology, 2018
Publication

Exclude quotes Off

Exclude matches Off

Exclude bibliography On

Acute Limb Ischemia in the Young: A Rare Case of Essential Thrombocytosis

GRADEMARK REPORT

FINAL GRADE

/100

GENERAL COMMENTS

Instructor

PAGE 1

PAGE 2

PAGE 3

PAGE 4

PAGE 5
