

Jugular Vein Aneurysm: When We Have to Do Surgery

by Rizki Amalia


Submission date: 23-Jan-2023 05:19PM (UTC+0800)

Submission ID: 1997618122

File name: 25._Jugular_Vein_Aneurysm_When_We_Have_to_Do_Surgery.pdf (282.85K)

Word count: 2467

Character count: 13593



Bioscientia Medicina: Journal of Biomedicine & Translational Research

Journal Homepage: www.bioscmed.com

Jugular Vein Aneurysm: When We Have to Do Surgery?

Rizki Amalia^{1,2}, Johannes Nugroho^{2*}, Ivana Purnama Dewi^{1,2,3}

¹Faculty of Medicine, Airlangga University, Surabaya, Indonesia

²Cardiology and Vascular Medicine Department, Dr. Soetomo General Hospital, Surabaya, Indonesia

³Faculty of Medicine, Duta Wacana Christian University, Yogyakarta, Indonesia

ARTICLE INFO

Keywords:

Jugular Vein Aneurysm

Management

Surgical

*Corresponding author:

Johannes Nugroho

E-mail address:

j.nugroho.eko@fk.unair.ac.id

All authors have reviewed and approved the final version of the manuscript.

<https://doi.org/10.32539/bsm.v5i8.401>

ABSTRACT

Background: The most common lesions of jugular vein dilatation are aneurysms and ectasia. A jugular vein aneurysm is less common compare to an arterial aneurysm in adults. Because of the rare incidence, treatment guidelines primarily associated with the timing of surgery are not clearly established. Proper treatment can reduce patient complaints without excessive intervention. **Case report:** A 54 years old woman complained of swelling in the right neck that started three years ago and cephalgia for two years. From CT angiography, we obtained a jugular vein dilatation of 2.3 cm. During periodic evaluation from ultrasonography doppler, there is no increase in the size of the jugular vein. **Conclusion:** Jugular vein aneurysm presenting in adults is an infrequent phenomenon. It is a benign condition, and conservative observation is advised. It should be operated only if symptomatic or progressive enlarging. A periodic examination must be done to evaluate the size of the jugular vein before a surgical decision

1. Introduction

Jugular venous aneurysm (JVA) is a rare condition¹. It occurs equally between man and woman. Approximately 75% of cases are diagnosed in children². The dilatation of the jugular vein can be fusiform or saccular without torsion in the jugular vein wall³. Some authors often use "ectasia" to explain fusiform dilatations and "aneurysms" for saccular ones. However, both of them are commonly used as synonyms².

A clear etiology has not yet been established. The pathology is relatively benign, depending on the localization, and can lead to severe complications such as thrombosis, pulmonary embolism, rupture, bleeding, or pressure over neighboring structures. To prevent those complications, some clinicians do surgery. However, treatment guidelines especially

associated with the time of surgery, are not established⁴.

2. Case report

A 54-year-old woman came to the emergency unit with a painless mass involving the right neck since three years ago. Initially, the swelling used to appear on coughing or loud speaking. However, the node became firm and did not reduce spontaneously later. She denied any history of trauma or other chronic diseases except hypertension. She also complained about intermittent cephalgia. There was no stridor, dysphagia, hoarseness, vomiting, dyspnea, neck pain, and chest pain.

From the physical examination, we found 1.5×2 cm, soft swelling in the right lower neck, near the clavicle,

extending to the anterior. The swelling is pulsating. There was no enlargement of the lymph node. Her blood pressure is 170/100mmHg. She has bad compliance to come to the hospital regularly, and in three consecutive visits at the hospital, she has uncontrolled hypertension. The CT scan angiography revealed that dilatation of the right internal jugular vein was approximately 23mm as high as the right thyroid level.

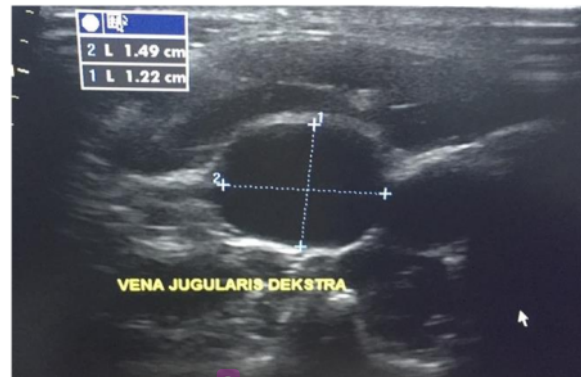

Figure 1. Short axis view shows the diameter of the right internal jugular vein

From the follow-up after a year, the size of the right internal jugular vein was not increased, and no thrombus formation. The chief complaint was just intermittent cephalgia without vomiting or intracranial extension sign. She has uncontrolled hypertension and shoulder pain that can indicate neuromuscular problems as other possibilities of cephalgia's reason. The cephalgia was not increased for a year. We consulted the neurology department and got cervical root syndrome dextra and nerve irritation C5, C6, and C7 dextra demyelinating sensory mononeuropathy. She did not bother with the cosmetic aspect of the neck swelling. Conservative therapy was decided because of the minimum symptoms and neither high-risk complications found in her jugular vein aneurysm. Periodic observation with US Doppler every three months was planned to evaluate the internal jugular vein aneurysm progression. We also optimize her antihypertensive therapy to control blood pressure.

3. Discussion

A jugular vein aneurysm is a rare condition. However, it is the most often venous deformity affecting the neck veins⁵. JVA is commonly from the internal

Meanwhile, the left internal jugular vein was normal. The patient was lost to follow up for a year. When she revisits the hospital, we do ultrasound (US) Doppler for evaluation. Figure 1 shows the result in which the right internal jugular vein was not enlarged compared to CT scan results with a diameter of 14.9x12.9mm and no thrombus formation.

jugular vein. It can also involve the external jugular vein, and the rarest affects the anterior one¹. Paleri et al. stated that up to 10% percent of the jugular aneurysms could be bilateral. The cause of this disorder is still unclear, but several factors are suspected as predisposing factors⁶. The lack of elasticity of the vein wall is mentioned as the possible cause and commonly the dilatation in fusiform type or "ectasia"⁵. Meanwhile, saccular dilatation or aneurysms are caused secondary to tumors, inflammation, or trauma, although they can also appear spontaneously¹. Other predisposing factors of JVA are elevated pressure in the internal jugular vein, compression between the cervical pleura and head of the clavicle, mechanical obstruction of the lower neck and upper mediastinum, thoracic outlet syndrome, and anterior scale compression. JVA is generally seen in the right jugular vein in children because the right side lung dome is higher than the left one. So, it makes the right jugular vein more susceptible to increased intrathoracic pressure^{7,8}. Another possible cause is the right internal jugular vein valves which are placed higher than the left one. On the contrary, in adults, JVA is mainly acquired and usually on the left side. It has

been related to elderly hypertensive patients because of compression to the left innominate vein by the atherosclerotic aorta³.

The most clinical manifestation of the venous aneurysm is soft compressible swelling, commonly appearing along the vein axis⁹. It is usually asymptomatic, but the main problem that patients often complain about is the cosmetic aspect. Other rare presentations reported were atypical chest pain. In cases of JVA with malignancy, symptoms of dysphonia are usually found⁵. JVA complications can be hoarseness of voice or Horner's syndrome and can be complicated by thrombosis. When an asymptomatic JVA starts causing symptoms such as pain, we should suspect thrombosis. According to the literature, the risk of thrombosis in an internal jugular vein aneurysm is less than 1%⁹⁻¹⁰. JVA usually does not grow progressively and rapidly. Until now, there has never been a spontaneous rupture of the swelling reported. Another less frequent manifestation but ever reported is the intracranial extension. It can be accompanied by CNS involvement or not^{8,11}.

Other diagnoses of neck swelling include a laryngocele, brachial cyst, cavernous hemangioma, superior mediastinal cyst, or cystic hygroma¹². In this case, the swelling is painless and pulsating. In the beginning, we think about the carotid artery aneurysm, but after we do CT angiography, there is dilatation of the internal jugular vein confirmed by ultrasound doppler. To distinguish between both structures, we performed a Doppler examination. We get dilatation from the venous structure from the US doppler, which is an internal jugular vein.

Computed tomography, MRI, and ultrasound can also exclude other diseases such as dermoid cyst, cervical adenitis, bronchogenic cyst, metastatic adenopathy, or thyroglossal duct cyst. US Doppler imaging is the cheapest non-invasive diagnostic examination to differentiate between cystic and solid or vascular and non-vascular lesions. Sometimes, JVA cannot be diagnosed by a CT scan, moreover, in the case of mild internal JVA. US doppler is preferred because dilatation of the internal jugular vein can be interpreted dynamically by comparing the size of the

vein at rest and the Valsalva manoeuvre. However, the CT scan is usually used to exclude any causative structural lesion. So, both imaging tests can be used to complement each other¹³. Color doppler of both lower limbs and abdominal ultrasonography to see the great veins should be done to rule out any other venous malformations¹⁴. A good clinical examination and US Doppler can diagnose this condition accurately and help differentiate it from other neck swellings¹⁵.

Surgery indications are still debated because most JVAs are benign and asymptomatic lesions that can be conservative with regular follow-up and reassurance¹. However, if it has been decided on a patient not to undergo surgery, the clinician must periodically observe the lesion for changes and progressions that maybe occur. Besides, patients should be protected from all trauma to prevent bleeding and infection^{5,16}.

The cosmetic aspect is often used as the reason for surgery in the case of JVA. It is also indicated if an aneurysm becomes painful due to thrombosis or phlebitis from the jugular venous system. However, such complication was infrequent, so prophylactic anticoagulation therapy was not routinely given^{17,18}. Another indication of surgery is Horner's syndrome, intractable cough, congestive cardiac failure, massive hemorrhage secondary to trauma, and spontaneous rupture¹⁹. Surgical resection eliminates the theoretical risk of those complications. Embolism or rupture of a venous aneurysm may appear in several locations resulting in emergency surgery or death. This circumstance occurs in some cases of deep venous aneurysms in the abdomen and lower extremities. Although there were no reports of life-threatening complications for JVA, most clinicians choose surgical treatment in saccular aneurysm cases. On the contrary, surgical treatment is only done in fusiform dilatation if the lesions are symptomatic or progressive enlarging⁷. It is usually managed by a conservative and rarely needs surgery⁹.

In the setting of our case, the patient had fusiform dilatation of the jugular vein without such complications. Follow-up evaluation after a year did not show any progression of the disease. The only symptom that complained is cephalgia. Most literature did not

mention cephalgia as the clinical manifestation of JVA. Even intracranial extension of JVA can be excluded because we did not get CNS involvement. By contrast, cephalgia is often described in jugular vein compression as the manifestation of mechanical obstruction of intracranial vein drainage^{8,11}.

4. Conclusion

Jugular vein aneurysm presenting in adults is a very rare phenomenon. It is a benign condition, and conservative observation is advised. The surgery indicates a cosmetic or physiological concern, painful aneurysm secondary to thrombosis or phlebitis, other complications such as Horner's syndrome, intractable cough, congestive cardiac failure, massive hemorrhage secondary to spontaneous trauma rupture. Surgery is also preferred if the lesion is symptomatic, enlarging, or disfiguring. Therefore, if conservative management is decided, it needs periodic follow-up to observing the lesion for any changes and recording the natural course.

5. Conflicts of interest

The authors certify that there is no conflict of interest with any financial organization regarding the material discussed in the manuscript.

6. Funding

The authors report no involvement in the research by the sponsor that could have influenced the outcome of this work.

7. Authors' contributions

RA has given substantial contributions to the conception of the design of the manuscript. MP and JN were major contributors in writing the manuscript. IPD was editing the manuscript for publications. All authors have participated in drafting the manuscript, JN revised it critically. All authors read and approved the final version of the manuscript.

8. Acknowledgments

Not applicable.

9. Consent for publication

Written informed consent was taken from the patient to use medical data for academic and research purposes, including publication.

10. References

1. Garg P, Tandon A, Mohanty D, and Jain B. External jugular venous aneurysm: A clinical curiosity. *Journal of Natural Science, Biology and Medicine*. 2013; 4: 223.
2. Adenauer Marinho De Oliveira Goes Junior. Internal Jugular Vein Aneurysm Presenting after Emesis Episode. *Angiology: Open Access* 2014; 2.
3. Alur I. Surgical treatment of an isolated left jugular vein aneurysm: a case report. *Cardiovascular Surgery and Interventions*. 2014; 1: 38–40.
4. Koçak H E. How To Approach Internal Jugular Vein Aneurysm; A Rare Cause of Neck Mass *Biomedical Journal of Scientific & Technical Research* 1. 2017.
5. Alenezi M, Alaglan A, Almutairi A, Alanazy S and Wutayd O A. Unilateral internal jugular vein phlebectasia in an adult: Management and one year follow-up. *SAGE Open Medical Case Reports*. 2019; 7.
6. Paleri V, Gopalakrishnan S, Jugular phlebectasia: theory of pathogenesis and review of literature. *Int J Pediatr Otorhinolaryngol*. 2001; 57(2): 155-9.
7. Bhattacharya D, Endrakanti M and Kumar R. Right Internal Jugular Vein Phlebectasia: A Rare Cause of Neck Swelling. *Case Reports in Pediatrics*. 2017; 17:1–3.
8. Hopsu E, Tarkkanen J, Vento SI, and Pitkäranta, An Acquired Jugular Vein Aneurysm, *International Journal of Otolaryngology*. 2009; 9:1–4.
9. Gallien S, Rollot F, Caron B, Moachon L, Bienvenu B, et al. Pulmonary embolism and deep jugular venous thrombosis resulting from compression by a lipoma. *Dermatol Online J*. 2006; 12 (2):13.

10. Ascher E, Salles-Cunha S, and Hingorani A. Morbidity and Mortality Associated with Internal Jugular Vein Thromboses. *Vascular and Endovascular Surgery*. 2005; 39: 335–9.
11. Malik V, Murthy T, and Kumari A. Unusual case of focal neck swelling: Phlebectasia of internal jugular vein with intracranial extension. *International Journal of Applied and Basic Medical Research*. 2015; 5: 58.
12. Kloppenburg GTL, Vries JP PMD, Schuurman JP, Koelemij R, and Wille J. Current Perspectives on Management of Congenital Jugular Vein Aneurysms. *Vascular and Endovascular Surgery*. 2011; 45: 237–40.
13. Cheah SC, Wong HT, and Lau CY. Rare left-sided presentation of internal jugular vein ectasia in an adult. *Annals of Saudi Medicine*. 2018; 38: 381–2.
14. Nina MS, Vishal SS, Dalal PR, Mishra P. A Pseudoaneurysm of the External Jugular vein—a case report. *Gujarat Medical Journal*. 2016; 70: 2.
15. Agrawal R. Left External Jugular Phlebectasia: Rare Presentation in Adults; Sign of a Deep, Dangerous Lesion? *Exp Rhinol* 2/3 *Otolaryngol*. 2018; 2: 5
16. Vasisth G P, Bindal S, and Chibber P. Phlebectasia of Internal Jugular Vein *Journal of Surgical Technique and Case Report*. 2012; 4:103.
17. Calligaro KD, Ahmad S, Dandora R, Dougherty MJ, Savarese RP, Doerr KJ, Mcaffee S and Delaurentis DA. Venous aneurysms: Surgical indications and review of the literature *Surgery*. 1995; 11:71–6.
18. Phookan S, Strickland PT, Hanna B, Hartlage GR, Parikh A, and Clements SD. Internal Jugular Venous Pseudoaneurysm in a Patient with Heart Failure and Severe Tricuspid Regurgitation. *Case Reports in Vascular Medicine*. 2017; 17: 1–3.
19. Togo S, Ouattara MA, Koumaré S, Camara MA, and Yena S. Right Internal Jugular Vein Ectasia in African Woman: A Report of 2 Cases. *Surgical Science*. 2015; 6: 437–41.

Jugular Vein Aneurysm: When We Have to Do Surgery

ORIGINALITY REPORT

17%

SIMILARITY INDEX

12%

INTERNET SOURCES

15%

PUBLICATIONS

6%

STUDENT PAPERS

PRIMARY SOURCES

1	he02.tci-thaijo.org Internet Source	8%
2	Yuko Omata, Yoshiko Takahashi, Tomoko Nakazawa, Taku Omata. "Paediatric primary cough headache with internal jugular phlebectasia", BMJ Case Reports, 2021 Publication	1%
3	www.jurnalkedokteranunsri.id Internet Source	1%
4	M Peters. "Superior vena cava thrombosis causing respiratory obstruction successfully resolved by stenting in a small bowel transplant candidate", Archives of Disease in Childhood, 2000 Publication	1%
5	crimsonpublishers.com Internet Source	1%
6	docksci.com Internet Source	1%
7	doi.org	

Internet Source

1 %

8

e-sciencecentral.org

Internet Source

1 %

9

Submitted to Universitas Airlangga

Student Paper

1 %

10

Xiang Liu, Chang-zhi Sun, Hua Zou, Ren-zhong Luo. "Jugular vein phlebectasia in paediatric patients with vocal fold nodules", *European Journal of Pediatrics*, 2013

Publication

1 %

11

Eleni E. Drakonaki, Emmanouil K. Symvoulakis, Anthoula Fachouridi, Dimitrios Kounalakis, Emmanouil Tsafantakis. "External Jugular Vein Aneurysm Presenting as a Cervical Mass", *International Journal of Otolaryngology*, 2011

Publication

<1 %

12

Zhaoli Meng, Fei Chen, Yao Huo, Haocheng Sun, Yun Zheng. "Pulsatile Tinnitus Caused by Internal Jugular Phlebectasia in an Adult", *Journal of Craniofacial Surgery*, 2020

Publication

<1 %

13

Eun Young Rha, Ik Kyun Choi, Jun Hee Byeon. "Internal Jugular Phlebectasia in a Patient with Facial Trauma", *Archives of Plastic Surgery*, 2013

<1 %

14

H Lau. "Extrahepatic portal vein aneurysm: a case report and review of the literature", *Cardiovascular Surgery*, 2002

Publication

<1 %

15

Hu, X.. "Congenital jugular vein phlebectasia", *American Journal of Otolaryngology--Head and Neck Medicine and Surgery*, 200505/06

Publication

<1 %

16

Kloppenborg, G. T. L., J.-P. P. M. de Vries, J.-P. Schuurman, R. Koelemij, and J. Wille. "Current Perspectives on Management of Congenital Jugular Vein Aneurysms", *Vascular and Endovascular Surgery*, 2011.

Publication

<1 %

17

amhsjournal.org

Internet Source

<1 %

18

tgkdc.dergisi.org

Internet Source

<1 %

Exclude quotes Off

Exclude matches Off

Exclude bibliography On

Jugular Vein Aneurysm: When We Have to Do Surgery

GRADEMARK REPORT

FINAL GRADE

/100

GENERAL COMMENTS

Instructor

PAGE 1

PAGE 2

PAGE 3

PAGE 4

PAGE 5
