

# Henoch-Schonlein Purpura (Childhood Immunoglobulin A VAsculitis) Caused by Dental Infection in One of Fraternal Twins A Case Report

*by* Sindy Cornelia Nelwan

---

**Submission date:** 16-Apr-2022 08:09PM (UTC+0800)

**Submission ID:** 1812010837

**File name:** by\_Dental\_Infection\_in\_One\_of\_Fraternal\_Twins\_A\_Case\_Report.pdf (917.94K)

**Word count:** 2797

**Character count:** 15754

# Henoch-Schönlein Purpura (Childhood Immunoglobulin A Vasculitis) Caused by Dental Infection in One of Fraternal Twins: A Case Report

Sindy Cornelia Nelwan, DDS, PhD, Mega Moeharyono Puteri, DDS, PhD,  
Udijanto Tedjosongko, DDS, PhD, Tania Saskianti, DDS, PhD and Devi Dharmawan, DDS

Department of Pediatric Dentistry, Faculty of Dental Medicine, Universitas Airlangga, Surabaya, Indonesia

## ABSTRACT

Henoch-Schönlein purpura (HSP) is the most common form of vasculitis in children that is clinically characterized by the classic triad of palpable purpura, joint symptoms, and abdominal pain. A 6-year-old girl, one of fraternal twins, was admitted to the Pediatric Department, Universitas Airlangga with fever, rashes on legs and arms and intermittent mild abdominal pain. She had multiple purpuric rashes on her extremities, abdomen and buttocks. Laboratory investigation revealed immunoglobulin A level of 289.6 mg/dL. The patient was diagnosed as HSP vasculitis according to EULAR criteria and treated with intravenous methylprednisolone. She was discharged after three days with normal physical examination and laboratory findings. Intraoral examination showed dental infection in the upper tooth region. The paediatrician suspected a correlation between HSP and her dental infection. The dental infection and genetic susceptibility may be the stimulant factors for the autoimmune reactions that caused HSP vasculitis. Hence, it might be useful to investigate the presence of dental infection in the etiology of HSP cases.

*Key Words: Henoch-Schönlein purpura, dental infection, fraternal twins*

## INTRODUCTION

Henoch-Schönlein Purpura (HSP) is a form of vasculitis involving small blood vessels (capillaries), characterized by purpura without thrombocytopenia, joint swellings, abdominal pain, and kidney abnormalities.<sup>1</sup> The annual incidence of HSP is estimated to be 13–20 cases per 100,000 population and 10–90% of all cases of vasculitis mainly occur in children.<sup>2</sup> In Asia, HSP incidence is 70/100,000, with a peak in the 7–10 years age group (average age, 6.4 years) and is more common in boys than girls (2:1). Various infections are reported to cause HSP, including upper respiratory tract infections (14.4%) and dental infections (13.3%).<sup>3</sup> The possible etiology of HSP is unknown (48.4%) but can be the response of the immune system to some triggers.<sup>3</sup> The disease can be worsened by an active intraoral infection.

Inoue et al. reported that dental caries (70%) along with apical periodontitis (53%) were found in HSP cases and concluded that early treatment for these cases may prevent complications of HSP disease.<sup>4</sup> Some skin or autoimmune diseases associated with odontogenic infectious diseases, such as Burger's disease had been linked to periodontitis, palmoplantar pustulosis and chronic pigmented purpura correlation with an oral focal infection. Jinous et al. reported a HSP case that developed after endodontic treatment.<sup>5</sup>

Paper presented in the *Pertemuan Ilmiah Nasional 13 Bali* on March 14, 2020 at the *Discovery Kartika Plaza Hotel* in Bali, Indonesia.

Corresponding author: Sindy Cornelia Nelwan, DDS, PhD  
Department of Pediatric Dentistry  
Faculty of Dental Medicine,  
Universitas Airlangga, Surabaya, Indonesia  
Email: Sindy-c-n@fkg.unair.ac.id

**Table 1.** Laboratory test examination

Examination type	Result	Reference value	Unit	Method
Immunoglobulin A (IgA) (mg/dl)	289.6	27.0-195.0		Immunoturbidimetry
Hemoglobin (g/dL)	11.8	11-13		
Leukocytes (μl)	10.760	4.500-13.500		
Thrombocytes (mcL)	286.000	450.000		
Total immunoglobulin E	22.68	20		

**Table 2.** Urine test examination

Urine profile/routine	Result
Turbidity	Clear
Color	Yellow
PH	6.0
BJ	1.015
Protein (mg/dl)	Negative
Glucose (mg/dl)	Negative
Ketone	Negative
Bilirubin (mg/dl)	Negative
Urobilin (mg/dl)	Normal
Nitrate	Negative
Eri (/hpf)	1
Leko (/hpf)	1
Epithel (/hpf)	1
Cylinder (/hpf)	-
Bacteria	-
Crystal 1	-
Crystal 2 (/hpf)	-
Cells (/hpf)	-

The root canal treatment was not recommended because of streptococcal bacteremia that changed the microbiological flora in the root canal triggering HSP.

We report the case of a 6-year-old girl, one of fraternal twins, with dental infection triggering Henoch-Schönlein purpura disease. The purpose of this case report is to describe the dental management of a patient with HSP related to genetic susceptibility.

### CASE REPORT

A 6-year-old girl, one of fraternal twins, was admitted to our pediatric department with fever, rashes on legs and arms and intermittent mild abdominal pain. There were multiple purpuric rashes on her extremities, abdomen and buttocks. Laboratory investigations revealed immunoglobulin A level of 289.6 mg/dL (Table 1). Other laboratory test results such as hemoglobin, leukocytes, total immunoglobulin E showed normal levels. There was no protein, glucose, bilirubin, urobilin, nitrite, and ketones in the urine (Table 2). The patient was diagnosed as HSP vasculitis according to EULAR criteria and treated with



**Figure 1.** Extraoral photograph showed no facial abnormalities.

intravenous methylprednisolone. She was discharged after three days with normal physical examination and laboratory findings. She was prescribed with intravenous injection of methylprednisolone 2 x 100 mg for 3 days as anti-inflammatory drug. The other viral and bacterial investigations showed negative results. The paediatrician suspected a correlation between HSP and her dental infection.

The physical and extraoral examination showed pain in the joints, palpable non-tender, reddish clearly demarcated marks on the extremities, and no facial asymmetry (Figures 1 and 2). Intraoral examination showed 51, 61 gangrene radix with an abscess (Figure 3). Panoramic radiographs showed 51, 61 gangrene radix (Figure 4). The patient weighed 20 kg, with a height of 136 cm. Genetic counselling was conducted. This patient is a twin and has never developed an autoimmune disease such as HSP. Before the HSP disease appeared, there was no history of upper respiratory tract infection or other diseases.

On the first visit at Universitas Airlangga, promotive and preventive treatments such as dental health education, fissure sealant, glassionomer filling, and instructions for continuing medication from paediatrician were conducted. Extraction of 51, 61 teeth radix gangrene could not be conducted because there was still an abscess and patient was on prednisone treatment.

On the second visit 51, 61 teeth were extracted by using local infiltration techniques to prevent recurrent infections

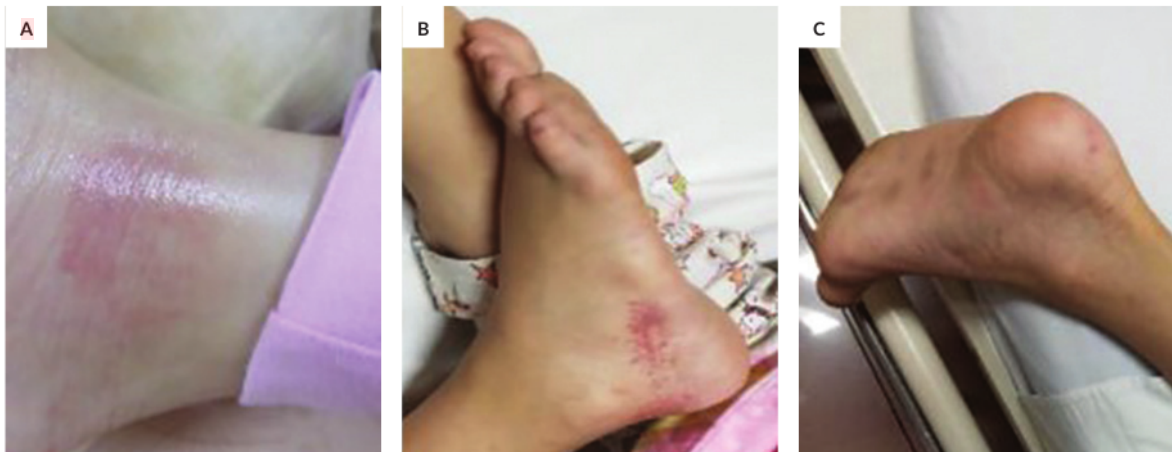

Figure 2. Reddish palpable purpura lesions at right and left lower extremities.

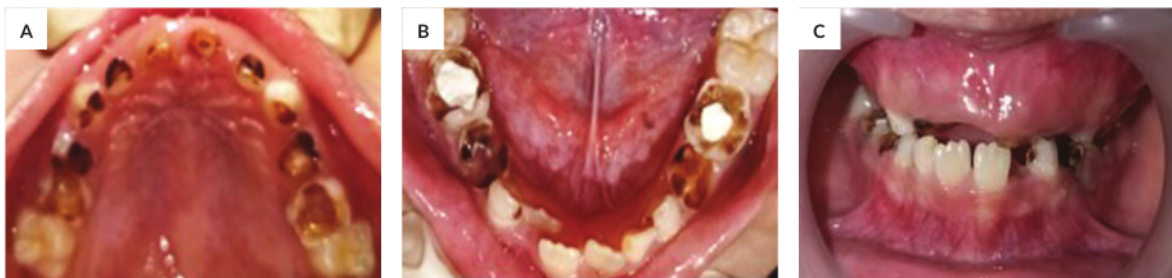

Figure 3. Pre-treatment clinical intraoral image of maxilla and mandible showed teeth 51, 61 gangrene radix with abscess.

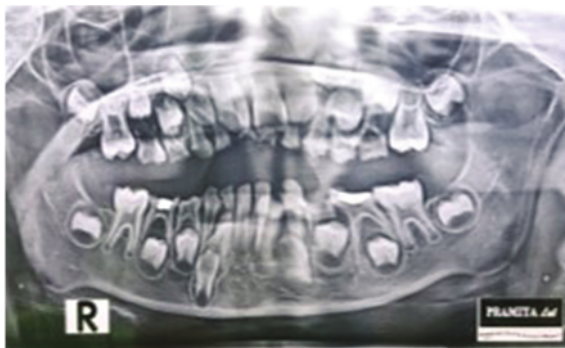


Figure 4. Panoramic radiograph at initial examination revealing 51 and 61 gangrene radix.

and HSP disease within 6 weeks. After the first and second month of examination, there was good health condition and there was no recurrence of Henoch-Schönlein purpura (Figure 5). The patient and her parents were very satisfied with the treatment.

## DISCUSSION

<sup>17</sup> Henoch-Schönlein purpura (HSP) is a systemic autoimmune disease in the form of small blood vessel vasculitis that mainly attacks children.<sup>4</sup> Although the incidence of HSP is lower in adults, studies suggest that adults have more renal complications.<sup>6</sup> Infectious pathogens have been reported to cause HSP, such as group A Streptococci.<sup>4</sup> In addition, *Porphyromonas gingivalis* pathogens, commonly found in the oral cavity, influence the development of poor oral hygiene which is one of the contributing factors to dental infections in children.<sup>7</sup>

*Porphyromonas gingivalis* evade from the host immune responses in many ways — by significantly changing their lipopolysaccharide (LPS) and cell walls in order not only to affect its virulence but also to escape from the host immune responses.<sup>8</sup> Odontogenic infections may arise from a tooth or its supporting structures. It commonly occurs secondarily to dental caries, periodontal disease, or pericoronitis and is caused by different types of bacteria. If the primary source of the infection is not eliminated, inflammation may develop and result in severe (local as well



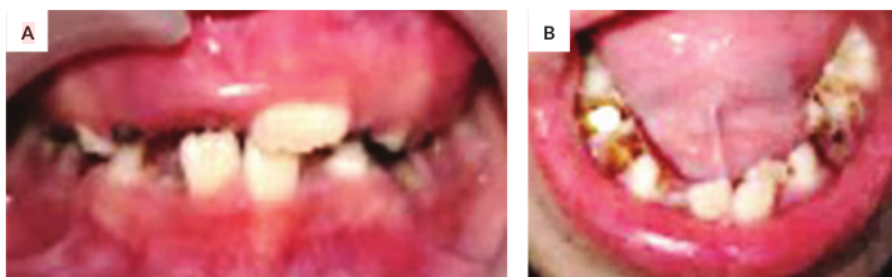

Figure 5. Intraoral condition after one month of treatment.

as systemic) complications.<sup>9</sup> The main biological concept in the treatment of dental abscess is based on the reduction of the causative agents, followed by the stimulation and the support of the regeneration of the damaged tissues.<sup>10</sup>

In this case report, we suspected a correlation between Henoch-Schönlein purpura and the dental infection (gangrene radix 51, 61 with abscess). In addition, the family history showed that the patient was one of fraternal twins, which made susceptibility to the disease greater. In previous studies, patients with an autoimmune disease had a strong genetic component. The immune system represents a barricade against the microbial infections, but it is not fail-safe. Microorganisms provoke the robust immune responses that are mostly specific for their programmed antigens. Nevertheless, microbial agents could trigger responses against self-antigens, leading to the activation and that clonal expansion of autoreactive T and B cells, which is the hallmark of autoimmunity. This may be the reason why microbial infections have been considered the main environmental culprits for some autoimmune processes.

The prevalence of genetic susceptibility in identical twins/monozygotes (35-50%), versus 5-6 % in non-identical/dizygotic twins, might be the stimulant factor for causing HSP. In this case, the patient was a non-identical twin, in which case most autoimmune diseases are polygenic and the affected individual inherits several polymorphisms that contribute to the susceptibility of an autoimmune disease.<sup>11</sup> It is believed that the product of this polymorphic gene influenced the development of self-healing and the expression of individuals to defend themselves. Accumulating evidence clearly suggest that a common genetic component underlie the different autoimmune diseases. PTPN22/CSK pathway had been postulated as a potential common genetic factor shared by different autoimmune disorders. Although their complex etiologies are far from being completely understood, genetic factors appear to influence the development of this condition.<sup>12</sup>

The genetic regulation of the endothelial function, such as polymorphisms in genes coding and vascular endothelial growth factor, could also confer an effect on HSP. Fraternal twins have a tendency to develop autoimmune diseases, especially those with dental infections (due to poor oral

hygiene of the patient) that commonly causes HSP. Preventive and promotive dentistry is the thrust of dentists, whether patients have HSP or not. Paediatric dentists should know the manifestation of dental infection as an autoimmune disease and should be aware of children with genetic susceptibility.

An et al. studied the association between C1GALT1 polymorphisms, a gene coding an enzyme important for kidney homeostasis, and the risk of HSP in a Chinese population. They postulated that under certain environmental influences or following an infection, individuals with a particular genotype would be predisposed to develop HSP.<sup>6</sup> Furthermore, several studies revealed the relevant role of some genetic variants (including those located in the human leukocyte antigen (HLA) system) in both susceptibility and HSP clinical heterogeneity. The HLA region includes a group of genes located in chromosome 6 (6p21) that encode for proteins on the surface of the cells that are responsible for regulation of the immune system in human beings. HLA has been described as a common genetic component that underlie the immune-mediated diseases, being associated with more diseases than any other region of the human genome.<sup>13</sup>

Interaction between multiple genes and environmental factors was identified to be an important factor in 50% of HSP cases.<sup>14</sup> In addition to the infection, certain genetic variations have been associated with susceptibility and pathogenesis of HSP. The role of the genetic predisposition to HSP was suggested by epidemiologic differences across different ethnic groups, and familial aggregation of HSP. Major histocompatibility complex (MHC) and non-MHC genes, proinflammatory cytokines genes, endothelial nitric oxide synthase (eNOS), matrix metalloproteinase (MMPs), MEFV gene, and many others have been implicated as the possible predisposing or protective factors in the pathogenesis of HSP.<sup>6</sup>

Many studies suggest that disease concordance in monozygotic twins (that is, genetically identical individuals, who share the same alleles) is significantly higher than that observed for dizygotic twins (who share one-half of their alleles). For example, monozygotic twins exhibit 25% concordance, whereas dizygotic twins had 5.4% concordance.

Additionally, the risk of autoimmune disease in siblings of an affected individual was significantly higher than that of the general population, as measured by sibling recurrence. In HSP, IgA complexes are formed and deposited in the skin, digestive tract and glomeruli, causing a local inflammatory response. Normally, IgA is found in serum and in the mucosal fluid.<sup>15</sup>

Most cases of HSP are self-limiting and do not require treatment other than symptomatic treatment, but recurrence of symptoms occur in about 33 % of cases. Recurrence often occurs between 2 weeks to 18 months after the initial resolution of symptoms, with children with symptoms of kidney involvement more likely to have a recurrence. In this case we decided to extract the infected teeth as soon as possible to avoid recurrence of HSP. For some patients, nephritis occur due to the deposition of IgA in the kidney mesangium. More serious complications such as central nervous system involvement, kidney failure, and the presence of nephritic or nephrotic syndrome are related to a poor prognosis.

## CONCLUSION

The main factors for HSP are unknown, but possible triggers that contribute to autoimmune diseases are genetic susceptibility (for example, in twins) and environmental factors, such as infection. In this case, the patient was a non-identical twin where most autoimmune diseases are polygenic and the affected individual inherits several polymorphisms that contribute to susceptibility to an autoimmune disease. Dental infection may have been the stimulant factor for the autoimmune reactions that led to HSP vasculitis. Close interaction between patients, parents, pediatrician, and paediatric dentist would result in the best treatment decision. Hence, it might be useful to investigate dental infection in the etiology of HSP cases.

## Acknowledgment

The authors are thankful to the patient for permitting the publication of this case report.

## Statement of Authorship

All authors participated in the data collection and analysis and approved the final version submitted.

## Author Disclosure

All authors declared no conflicts of interest.

## Funding Source

The study was personally funded.

## REFERENCES

- Oktaria D, Rini DA, Chintihia T. A 13 year old girl with Henoch Schönlein purpura ( HSP ). *Fak Kedokteran, Univ Lampung* 2017; 4:62-5.
- Prameswari R, Indramaya D, Sandhika W. The immunopathogenesis of leukocytoclastic vasculitis in Henoch-Schönlein purpura. *Berk Ilmu Kesehatan Kulit dan Kelamin J* 2012; 24:185-91.
- Ghrahani R, Ledika MA, Sapartini G, Setiabudiawan B. Age of onset as a risk factor of renal involvement in Henoch-Schönlein purpura. *Asia Pac Allergy* 2014; 4:42.
- Pertiwi ASP. Henoch-Schönlein purpura in children: its relation to oral and to oral and oral and dental health. *Dent J (Majalah Kedokt Gigi)* 2012; 45:127.
- Abe M, Mori Y, Saijo H, Hoshi K, Ohkubo K, Ono T, et al. The efficacy of dental therapy for an adult case of Henoch-Schönlein purpura. *Oral Sci Int* 2012; 9:59-62.
- Tang C, Scaramangas-Plumley D, Nast CC, Mosenifar Z, Edelstein MA, Weisman M. A case of Henoch-Schönlein purpura associated with rotavirus infection in an elderly Asian male and review of the literature. *Am J Case Rep* 2017; 18:136-42.
- Nelwan SC, Nugraha RA, Endaryanto A, Meizarini A, Tedjosongko U, Pradopo S, et al. Converging findings from linkage between periodontal pathogen with atopic and allergic immune response. *Cytokine* 2019; 113:89-98.
- Rosalin Hongsathavijl , Yosvimol Kuphasuk1 KR. Effectiveness of platelet-rich fibrin in the management of pain and delayed wound healing. *Eur J Dent* 2017; 11:192-5.
- Doll C, Carl F, Neumann K, Voss JO, Hartwig S, Waluga R, et al. Odontogenic abscess-related emergency hospital admissions: a retrospective data analysis of 120 children and young people requiring surgical drainage. *Biomed Res Int* 2018;2018.
- Zarban A, Ebrahimipour S, Sharifzadeh GR, Rashed-Mohassel A, Barkooi M. Comparison of salivary antioxidants in children with primary tooth abscesses before and after treatment in comparison with healthy subjects. *Asian Pacific J Cancer Prev* 2017; 18:3315-8.
- Gan L, O'Hanlon TP, Lai Z, Fannin R, Weller ML, Rider LG, et al. Gene expression profiles from disease discordant twins suggest shared antiviral pathways and viral exposures among multiple systemic autoimmune diseases. *PLoS One* 2015; 10:1-15.
- López-Mejías R, Genre F, Remuzgo-Martínez S, Pérez BS, Castañeda S, Llorca J, et al. Role of PTPN22 and CSK gene polymorphisms as predictors of susceptibility and clinical heterogeneity in patients with Henoch-Schönlein purpura (IgA vasculitis). *Arthritis Res Ther* 2015; 17.
- López-Mejías R, Genre F, Pérez BS, Castañeda S, Ortego-Centeno N, Llorca J, et al. Association of HLA-B\*41:02 with Henoch-Schönlein Purpura (IgA Vasculitis) in Spanish individuals irrespective of the HLA-DRB1 status. *Arthritis Res Ther* 2015 ;17:4-9.
- Zhang X, Wu L, Chai M, Huang X, Zhu J, Li S, et al. Angiotensin-converting enzyme insertion/deletion polymorphism and susceptibility to Henoch-Schönlein purpura: a meta-analysis. *JRAAS - J Renin-Angiotensin-Aldosterone Syst* 2019; 20:1-6.
- Nakaseko H, Uemura O, Nagai T, Yamakawa S, Hibi Y, Yamasaki Y, et al. High prevalence of sinusitis in children with Henoch-Schönlein purpura. *Int J Pediatr* 2011; 2011:1-3.

# Henoch-Schonlein Purpura (Childhood Immunoglobulin A Vasculitis) Caused by Dental Infection in One of Fraternal Twins A Case Report

## ORIGINALITY REPORT

14%

SIMILARITY INDEX

9%

INTERNET SOURCES

11%

PUBLICATIONS

2%

STUDENT PAPERS

## PRIMARY SOURCES

- 1** [www.sciencegate.app](http://www.sciencegate.app) 1%

Internet Source
- 2** Masanobu Abe, Yoshiyuki Mori, Hideto Saijo, Kazuto Hoshi, Kazumi Ohkubo, Takehito Ono, Tsuyoshi Takato. "The efficacy of dental therapy for an adult case of Henoch-Schönlein purpura", Oral Science International, 2012 1%

Publication
- 3** Submitted to Universitas Airlangga 1%

Student Paper
- 4** [journals.lww.com](http://journals.lww.com) 1%

Internet Source
- 5** Hugh J. McCarthy. "Clinical practice: : Diagnosis and management of Henoch-Schönlein purpura", European Journal of Pediatrics, 12/12/2009 1%

Publication

6	Xuelian He, Chunhua Yu, Peiwei Zhao, Yan Ding, Xiaohui Liang, Yulan Zhao, Xin Yue, Yanxiang Wu, Wei Yin. "The genetics of Henoch–Schönlein purpura: a systematic review and meta-analysis", <i>Rheumatology International</i> , 2013 Publication	1 %
7	repository.unair.ac.id Internet Source	1 %
8	www.omicsonline.org Internet Source	1 %
9	apallergy.org Internet Source	1 %
10	journals.sagepub.com Internet Source	1 %
11	J A Gomez-Puerta. "Coeliac disease associated with systemic sclerosis", <i>Annals of the Rheumatic Diseases</i> , 2004 Publication	1 %
12	Alexander K.C. Leung, Benjamin Barankin, Kin Fon Leong. "Henoch-Schönlein Purpura in Children: An Updated Review", <i>Current Pediatric Reviews</i> , 2021 Publication	1 %
13	Germán Puerta, David De Paz, David Aguirre-Valencia, Fabián Ahumada, Nhora Silva, Juan	1 %



C. Bravo, Alex Echeverri. "TAFRO syndrome mimicking systemic lupus erythematosus: Case report and literature review", Revista Colombiana de Reumatología, 2021

Publication

---

14

Sindy Cornelia Nelwan, Ricardo Adrian Nugraha, Anang Endaryanto, Asti Meizarini et al. "Converging findings from linkage between periodontal pathogen with atopic and allergic immune response", Cytokine, 2019

Publication

---

1 %

15

[www.science.gov](http://www.science.gov)

Internet Source

---

1 %

16

Lin-Hao Zhang, Tian Lan, Du He, Shi-Lei Wen, Huan Tong. "A challenging case on diagnosing Henoch–Schönlein purpura", European Journal of Inflammation, 2020

Publication

---

<1 %

17

[www.alliedacademies.org](http://www.alliedacademies.org)

Internet Source

---

<1 %

18

[www.wjgnet.com](http://www.wjgnet.com)

Internet Source

---

<1 %

19

Shuo-Hsun Hung. "Clinical predictors of self-limited urinalysis abnormality in childhood Henoch-Schönlein purpura nephritis", Acta Paediatrica, 3/1/2006

Publication

---

<1 %

---

Exclude quotes      On

Exclude matches      Off

Exclude bibliography      On

# Henoch-Schonlein Purpura (Childhood Immunoglobulin A Vasculitis) Caused by Dental Infection in One of Fraternal Twins A Case Report

---

GRADEMARK REPORT

---

FINAL GRADE

**/100**

GENERAL COMMENTS

**Instructor**

---

PAGE 1

---

PAGE 2

---

PAGE 3

---

PAGE 4

---

PAGE 5

---