



HASIL VALIDASI DAN PENILAIAN
KARYA ILMIAH DOSEN FAKULTAS KEDOKTERAN GIGI UNIVERSITAS AIRLANGGA
(MEDIA PUBLIKASI KARYA ILMIAH : JURNAL ILMIAH INTERNASIONAL)

Nomor : 62 /UN3.1.2. 5.9 / PJ /2023

A. Identitas Karya Ilmiah

Judul Jurnal Ilmiah (Artikel) : **Henoch-Schonlein Purpura (Childhood Immunoglobulin A Vasculitis) Caused by Dental Infection in One of Fraternal Twins: A Case Report**

Jumlah penulis : 5 (lima) orang
Status Pengusul : Penulis Ke-3
Identitas Jurnal Ilmiah : a. Nama Jurnal : Acta Medica Philippina
b. Nomor ISSN: 00016071-20949278
c. Volume, Nomor, bulan, tahun : Vol. 56, No. 17, tahun 2022
d. Penerbit : the University of the Philippines Manila
e. DOI artikel : -
f. Alamat web Jurnal :
<https://actamedicaphilippina.upm.edu.ph/index.php/acta/article/view/2185>
g. Terindeks di SCOPUS Q4, SJR: 0,13

B. Kategori Publikasi Jurnal Ilmiah
(beri pada kategori yang tepat)

- Jurnal Ilmiah Internasional Bereputasi (SJR > 0,10)
 Jurnal Ilmiah Internasional Bereputasi (SJR < 0,10)
 Jurnal Ilmiah International terindeks di Web of science clarivate analytics / kelompok emerging sources citation indeks (tidak terindeks SJR)

C. Hasil Validasi Ketua Departemen

Telah diperiksa dan divalidasi dengan baik, dan sampai pernyataan ini dibuat sebagai karya ilmiah **original/ plagiat***, sehingga kami turut bertanggung jawab bahwa karya ilmiah tersebut telah memenuhi syarat kaidah ilmiah, norma akademik, dan norma hukum, sesuai dengan Peraturan Menteri Pendidikan Nasional Nomor 17 Tahun 2010 tanggal 16 Agustus 2010 tentang Pencegahan dan Pananggulangan Plagiat di Perguruan Tinggi. Namun demikian, apabila di kemudian hari ternyata terbukti bahwa karya ilmiah tersebut merupakan karya Ilmiah Plagiat, maka akan menjadi tanggung jawab mutlak penulis tersebut di atas, baik secara perdata maupun pidana. Demikian surat pernyataan ini saya buat untuk dipergunakan sebagaimana mestinya

Surabaya, 5 Januari 2023
Ketua Departemen,

Prof. Dr. Soegeng Wahlujo, drg, MKes, SpKGA.,
Supsp KKA(K)
NIP : 1954111019810301003

* Coret salah satu

Form Penilaian Kualitas Karil dan Kesesuaian Bidang Ilmu

Profil Sinta : Link Sinta <https://sinta.kemdikbud.go.id/profile>

A	Identitas Karya Ilmiah	
1	Judul: Henoch-Schonlein Purpura (Childhood Immunoglobulin A Vasculitis) Caused by Dental Infection in One of Fraternal Twins: A Case Report	
2	Nama Penulis : 1. Sindy Cornelia Nelwan; 2. Mega Moeharyono Puteri; 3. Udijanto Tedjosasongko; 4. Tania Saskianti; 5. Devi Dharmawan	
3	Nama Jurnal : Acta Medica Philippina	
B	Peng-index: SCOPUS Q4, SJR: 0,13; Google Scholar, Asean Citation Index (ACI), Western Pacific Region Index Medicus (WPRIM) and Herdin Plus	
C	Relevansi kompetensi dosen dengan substansi karya ilmiah	<ol style="list-style-type: none"> 1. Artikel ini Adalah suatu laporan kasus tentang penyakit autoimun sistemik berupa vasculitis pembuluh darah kecil yang menyerang anak-anak (Henoch-Schonlein purpura (HSP) yang disebabkan oleh Infeksi Gigi pada Kembar Fratesnal. 2. Artikel ini sesuai dengan bidang keahlian pengusul yaitu Cariology. 3. Tidak ada keterkaitan dengan naskah Disertasi pengusul yang berjudul: Initial acquisition and transmission of Mutans Streptococci in children at day nursery
D	Kesesuaian antara lingkup / subjek area jurnal dengan karya ilmiah yang diusulkan	<ol style="list-style-type: none"> 1. Alamat Web Jurnal : https://actamedicaphilippina.upm.edu.ph/index.php/acta/article/view/2185 2. Kebenaran ISSN : 00016071-20949378 3. Termasuk "Predatory" tidak (jurnal; penerbit) : tidak masuk pada predatory 4. Syarat komposisi Editor Board : Negara 5. Syarat kontributor penulis artikel : Penulis ke-3 6. Keberkalaan penerbitan : ... terbitan pertahun 7. Subjek area dan katagori jurnal :
E	Kepastian tidak ada pelanggaran integritas akademik	<ol style="list-style-type: none"> 1. Indikasi plagiasi (lihat check similarity) : 20% 2. Fabrikasi : tidak ada 3. Falsifikasi : tidak ada 4. Praktek kepalsuan : tidak ada
	Nilai pengusul (penulis pertama dan corespondensi 60%) =	
	Nilai pengusul (penulis pertama / penulis corespondensi masing - masing 40%)	
	Nilai lainnya sesuai PO PAK 2019 dan suplemennya	

Surabaya,
Penilai Angka Kredit 1

Nama :
NIP :
Bidang Ilmu :

Henoch-Schönlein Purpura (Childhood Immunoglobulin A Vasculitis) Caused by Dental Infection in One of Fraternal Twins: A Case Report

Sindy Cornelia Nelwan, DDS, PhD, Mega Moeharyono Puteri, DDS, PhD,
Udijanto Tedjosongko, DDS, PhD, Tania Saskianti, DDS, PhD and Devi Dharmawan, DDS

Department of Pediatric Dentistry, Faculty of Dental Medicine, Universitas Airlangga, Surabaya, Indonesia

ABSTRACT

Henoch-Schönlein purpura (HSP) is the most common form of vasculitis in children that is clinically characterized by the classic triad of palpable purpura, joint symptoms, and abdominal pain. A 6-year-old girl, one of fraternal twins, was admitted to the Pediatric Department, Universitas Airlangga with fever, rashes on legs and arms and intermittent mild abdominal pain. She had multiple purpuric rashes on her extremities, abdomen and buttocks. Laboratory investigation revealed immunoglobulin A level of 289.6 mg/dL. The patient was diagnosed as HSP vasculitis according to EULAR criteria and treated with intravenous methylprednisolone. She was discharged after three days with normal physical examination and laboratory findings. Intraoral examination showed dental infection in the upper tooth region. The paediatrician suspected a correlation between HSP and her dental infection. The dental infection and genetic susceptibility may be the stimulant factors for the autoimmune reactions that caused HSP vasculitis. Hence, it might be useful to investigate the presence of dental infection in the etiology of HSP cases.

Keywords: Henoch-Schönlein purpura, dental infection, fraternal twins

INTRODUCTION

Henoch-Schönlein Purpura (HSP) is a form of vasculitis involving small blood vessels (capillaries), characterized by purpura without thrombocytopenia, joint swellings, abdominal pain, and kidney abnormalities.¹ The annual incidence of HSP is estimated to be 13–20 cases per 100,000 population and 10–90% of all cases of vasculitis mainly occur in children.² In Asia, HSP incidence is 70/100,000, with a peak in the 7–10 years age group (average age, 6.4 years) and is more common in boys than girls (2:1). Various infections are reported to cause HSP, including upper respiratory tract infections (14.4%) and dental infections (13.3%).³ The possible etiology of HSP is unknown (48.4%) but can be the response of the immune system to some triggers.³ The disease can be worsened by an active intraoral infection.

Inoue et al. reported that dental caries (70%) along with apical periodontitis (53%) were found in HSP cases and concluded that early treatment for these cases may prevent complications of HSP disease.⁴ Some skin or autoimmune diseases associated with odontogenic infectious diseases, such as Burger's disease had been linked to periodontitis, palmoplantar pustulosis and chronic pigmented purpura correlation with an oral focal infection. Jinous et al. reported a HSP case that developed after endodontic treatment.⁵

Paper presented in the Pertemuan Ilmiah Nasional 13 Bali on March 14, 2020 at the Discovery Kartika Plaza Hotel in Bali, Indonesia.

Corresponding author: Sindy Cornelia Nelwan, DDS, PhD
Department of Pediatric Dentistry
Faculty of Dental Medicine
Universitas Airlangga, Surabaya, Indonesia
Email: Sindy-c-n@fkg.unair.ac.id

Table 1. Laboratory test examination

Examination type	Result	Reference value	Unit	Method
Immunoglobulin A (IgA) (mg/dl)	289.6	27.0-195.0		Immunoturbidimetry
Hemoglobin (g/dL)	11.8	11-13		
Leukocytes (μl)	10.760	4.500-13.500		
Thrombocytes (mcL)	286.000	450.000		
Total immunoglobulin E	22.68	20		

Table 2. Urine test examination

Urine profile/routine	Result
Turbidity	Clear
Color	Yellow
PH	6.0
BJ	1.015
Protein (mg/dl)	Negative
Glucose (mg/dl)	Negative
Ketone	Negative
Bilirubin (mg/dl)	Negative
Urobilin (mg/dl)	Normal
Nitrate	Negative
Eri (/hpf)	1
Leko (/hpf)	1
Epithel (/hpf)	1
Cylinder (/hpf)	-
Bacteria	-
Crystal 1	-
Crystal 2 (/hpf)	-
Cells (/hpf)	-

The root canal treatment was not recommended because of streptococcal bacteremia that changed the microbiological flora in the root canal triggering HSP.

We report the case of a 6-year-old girl, one of fraternal twins, with dental infection triggering Henoch-Schönlein purpura disease. The purpose of this case report is to describe the dental management of a patient with HSP related to genetic susceptibility.

CASE REPORT

A 6-year-old girl, one of fraternal twins, was admitted to our pediatric department with fever, rashes on legs and arms and intermittent mild abdominal pain. There were multiple purpuric rashes on her extremities, abdomen and buttocks. Laboratory investigations revealed immunoglobulin A level of 289.6 mg/dL (Table 1). Other laboratory test results such as hemoglobin, leukocytes, total immunoglobulin E showed normal levels. There was no protein, glucose, bilirubin, urobilin, nitrite, and ketones in the urine (Table 2). The patient was diagnosed as HSP vasculitis according to EULAR criteria and treated with



Figure 1. Extraoral photograph showed no facial abnormalities.

intravenous methylprednisolone. She was discharged after three days with normal physical examination and laboratory findings. She was prescribed with intravenous injection of methylprednisolone 2 x 100 mg for 3 days as anti-inflammatory drug. The other viral and bacterial investigations showed negative results. The paediatrician suspected a correlation between HSP and her dental infection.

The physical and extraoral examination showed pain in the joints, palpable non-tender, reddish demarcated marks on the extremities, and no facial asymmetry (Figures 1 and 2). Intraoral examination showed 51, 61 gangrene radix with an abscess (Figure 3). Panoramic radiographs showed 51, 61 gangrene radix (Figure 4). The patient weighed 20 kg, with a height of 136 cm. Genetic counselling was conducted. This patient is a twin and has never developed an autoimmune disease such as HSP. Before the HSP disease appeared, there was no history of upper respiratory tract infection or other diseases.

On the first visit at Universitas Airlangga, promotive and preventive treatments such as dental health education, fissure sealant, glassionomer filling, and instructions for continuing medication from paediatrician were conducted. Extraction of 51, 61 teeth radix gangrene could not be conducted because there was still an abscess and patient was on prednisone treatment.

On the second visit 51, 61 teeth were extracted by using local infiltration techniques to prevent recurrent infections

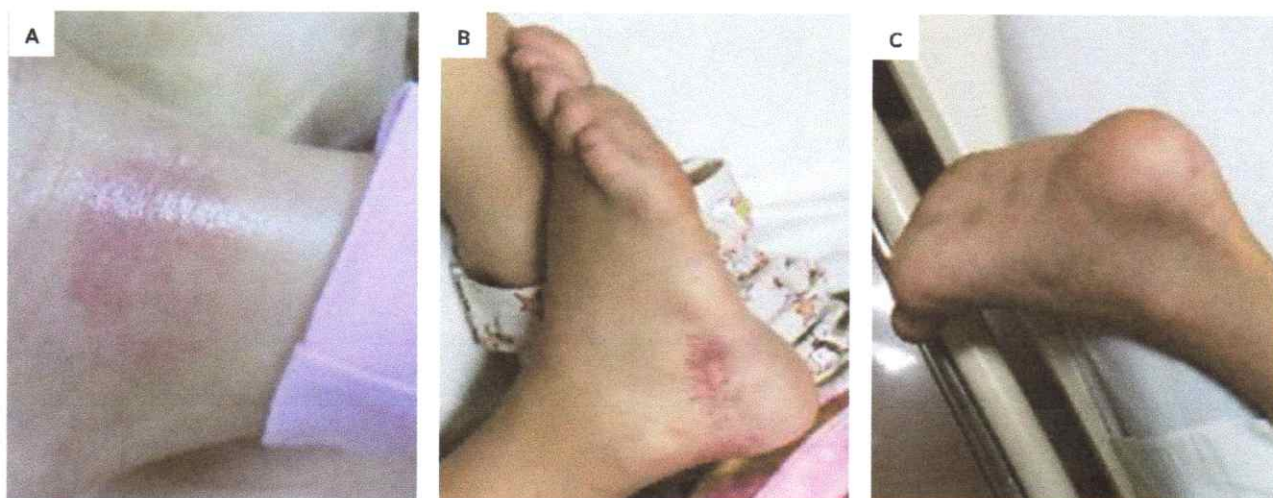

Figure 2. Reddish palpable purpura lesions at right and left lower extremities.

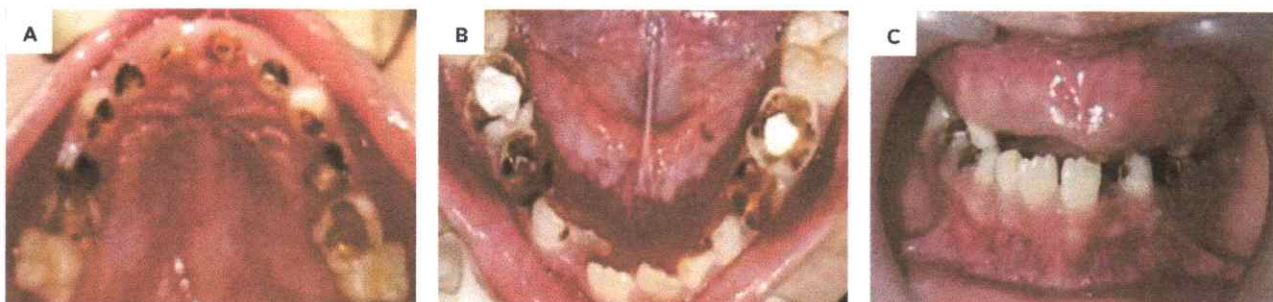

Figure 3. Pre-treatment clinical intraoral image of maxilla and mandible showed teeth 51, 61 gangrene radix with abscess.

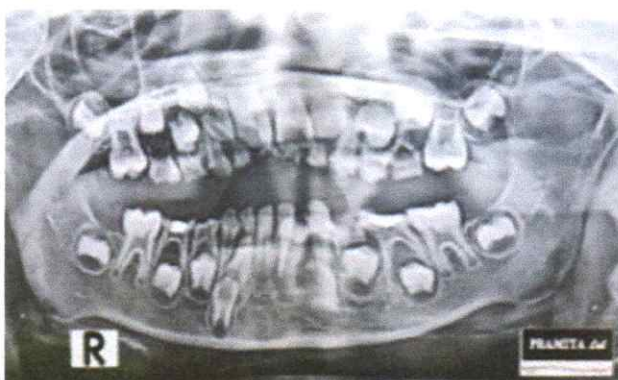


Figure 4. Panoramic radiograph at initial examination revealing 51 and 61 gangrene radix.

and HSP disease within 6 weeks. After the first and second month of examination, there was good health condition and there was no recurrence of Henoch-Schönlein purpura (Figure 5). The patient and her parents were very satisfied with the treatment.

DISCUSSION

Henoch-Schönlein purpura (HSP) is a systemic autoimmune disease in the form of small blood vessel vasculitis that mainly attacks children.⁴ Although the incidence of HSP is lower in adults, studies suggest that adults have more renal complications.⁶ Infectious pathogens have been reported to cause HSP, such as group A Streptococci.⁴ In addition, *Porphyromonas gingivalis* pathogens, commonly found in the oral cavity, influence the development of poor oral hygiene which is one of the contributing factors to dental infections in children.⁷

Porphyromonas gingivalis evade from the host immune responses in many ways — by significantly changing their lipopolysaccharide (LPS) and cell walls in order not only to affect its virulence but also to escape from the host immune responses.⁸ Odontogenic infections may arise from a tooth or its supporting structures. It commonly occurs secondarily to dental caries, periodontal disease, or pericoronitis and is caused by different types of bacteria. If the primary source of the infection is not eliminated, inflammation may develop and result in severe (local as well

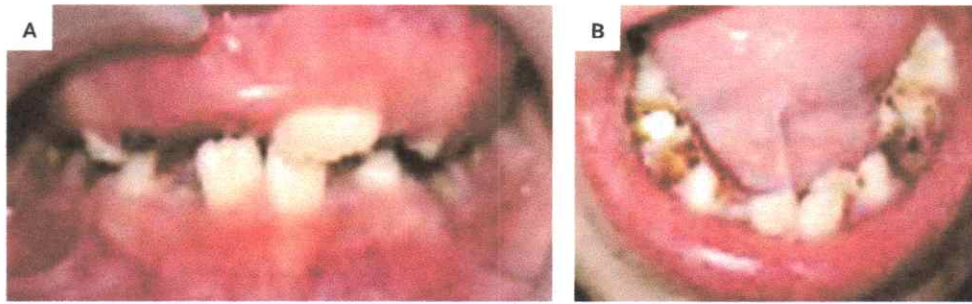


Figure 5. Intraoral condition after one month of treatment.

as systemic) complications.⁹ The main biological concept in the treatment of dental abscess is based on the reduction of the causative agents, followed by the stimulation and the support of the regeneration of the damaged tissues.¹⁰

In this case report, we suspected a correlation between Henoch-Schönlein purpura and the dental infection (gangrene radix 51, 61 with abscess). In addition, the family history showed that the patient was one of fraternal twins, which made susceptibility to the disease greater. In previous studies, patients with an autoimmune disease had a strong genetic component. The immune system represents a barricade against the microbial infections, but it is not fail-safe. Microorganisms provoke the robust immune responses that are mostly specific for their programmed antigens. Nevertheless, microbial agents could trigger responses against self-antigens, leading to the activation and that clonal expansion of autoreactive T and B cells, which is the hallmark of autoimmunity. This may be the reason why microbial infections have been considered the main environmental culprits for some autoimmune processes.

The prevalence of genetic susceptibility in identical twins/monozygotes (35-50%), versus 5-6 % in non-identical/dizygotic twins, might be the stimulant factor for causing HSP. In this case, the patient was a non-identical twin, in which case most autoimmune diseases are polygenic and the affected individual inherits several polymorphisms that contribute to the susceptibility of an autoimmune disease.¹¹ It is believed that the product of this polymorphic gene influenced the development of self-healing and the expression of individuals to defend themselves. Accumulating evidence clearly suggest that a common genetic component underlie the different autoimmune diseases. PTPN22/CSK pathway had been postulated as a potential common genetic factor shared by different autoimmune disorders. Although their complex etiologies are far from being completely understood, genetic factors appear to influence the development of this condition.¹²

The genetic regulation of the endothelial function, such as polymorphisms in genes coding and vascular endothelial growth factor, could also confer an effect on HSP. Fraternal twins have a tendency to develop autoimmune diseases, especially those with dental infections (due to poor oral

hygiene of the patient) that commonly causes HSP. Preventive and promotive dentistry is the thrust of dentists, whether patients have HSP or not. Paediatric dentists should know the manifestation of dental infection as an autoimmune disease and should be aware of children with genetic susceptibility.

An et al. studied the association between C1GALT1 polymorphisms, a gene coding an enzyme important for kidney homeostasis, and the risk of HSP in a Chinese population. They postulated that under certain environmental influences or following an infection, individuals with a particular genotype would be predisposed to develop HSP.⁶ Furthermore, several studies revealed the relevant role of some genetic variants (including those located in the human leukocyte antigen (HLA) system) in both susceptibility and HSP clinical heterogeneity. The HLA region includes a group of genes located in chromosome 6 (6p21) that encode for proteins on the surface of the cells that are responsible for regulation of the immune system in human beings. HLA has been described as a common genetic component that underlie the immune-mediated diseases, being associated with more diseases than any other region of the human genome.¹³

Interaction between multiple genes and environmental factors was identified to be an important factor in 50% of HSP cases.¹⁴ In addition to the infection, certain genetic variations have been associated with susceptibility and pathogenesis of HSP. The role of the genetic predisposition to HSP was suggested by epidemiologic differences across different ethnic groups, and familial aggregation of HSP. Major histocompatibility complex (MHC) and non-MHC genes, proinflammatory cytokines genes, endothelial nitric oxide synthase (eNOS), matrix metalloproteinase (MMPs), MEFV gene, and many others have been implicated as the possible predisposing or protective factors in the pathogenesis of HSP.⁶

Many studies suggest that disease concordance in monozygotic twins (that is, genetically identical individuals, who share the same alleles) is significantly higher than that observed for dizygotic twins (who share one-half of their alleles). For example, monozygotic twins exhibit 25% concordance, whereas dizygotic twins had 5.4% concordance.

Additionally, the risk of autoimmune disease in siblings of an affected individual was significantly higher than that of the general population, as measured by sibling recurrence. In HSP, IgA complexes are formed and deposited in the skin, digestive tract and glomeruli, causing a local inflammatory response. Normally, IgA is found in serum and in the mucosal fluid.¹⁵

Most cases of HSP are self-limiting and do not require treatment other than symptomatic treatment, but recurrence of symptoms occur in about 33 % of cases. Recurrence often occurs between 2 weeks to 18 months after the initial resolution of symptoms, with children with symptoms of kidney involvement more likely to have a recurrence. In this case we decided to extract the infected teeth as soon as possible to avoid recurrence of HSP. For some patients, nephritis occur due to the deposition of IgA in the kidney mesangium. More serious complications such as central nervous system involvement, kidney failure, and the presence of nephritic or nephrotic syndrome are related to a poor prognosis.

CONCLUSION

The main factors for HSP are unknown, but possible triggers that contribute to autoimmune diseases are genetic susceptibility (for example, in twins) and environmental factors, such as infection. In this case, the patient was a non-identical twin where most autoimmune diseases are polygenic and the affected individual inherits several polymorphisms that contribute to susceptibility to an autoimmune disease. Dental infection may have been the stimulant factor for the autoimmune reactions that led to HSP vasculitis. Close interaction between patients, parents, pediatrician, and paediatric dentist would result in the best treatment decision. Hence, it might be useful to investigate dental infection in the etiology of HSP cases.

Acknowledgment

The authors are thankful to the patient for permitting the publication of this case report.

Statement of Authorship

All authors participated in the data collection and analysis and approved the final version submitted.

Author Disclosure

All authors declared no conflicts of interest.

Funding Source

The study was personally funded.

REFERENCES

- Oktaria D, Rini DA, Chintihia T. A 13 year old girl with Henoch Schönlein purpura (HSP). *Fak Kedokteran, Univ Lampung* 2017; 4:62-5.
- Prameswari R, Indramaya D, Sandhika W. The immunopathogenesis of leukocytoclastic vasculitis in Henoch-Schönlein purpura. *Berk Ilmu Kesehat Kulit dan Kelamin J* 2012; 24:185-91.
- Ghrahani R, Ledika MA, Sapartini G, Setiabudiawan B. Age of onset as a risk factor of renal involvement in Henoch-Schönlein purpura. *Asia Pac Allergy* 2014; 4:42.
- Pertiwi ASP. Henoch-Schönlein purpura in children: its relation to oral and to oral and oral and dental health. *Dent J (Majalah Kedokt Gigi)* 2012; 45:127.
- Abe M, Mori Y, Saijo H, Hoshi K, Ohkubo K, Ono T, et al. The efficacy of dental therapy for an adult case of Henoch-Schönlein purpura. *Oral Sci Int* 2012; 9:59-62.
- Tang C, Scaramangas-Plumley D, Nast CC, Mosenifar Z, Edelstein MA, Weisman M. A case of Henoch-Schönlein purpura associated with rotavirus infection in an elderly Asian male and review of the literature. *Am J Case Rep* 2017; 18:136-42.
- Nelwan SC, Nugraha RA, Endaryanto A, Meizarini A, Tedjosongko U, Pradopo S, et al. Converging findings from linkage between periodontal pathogen with atopic and allergic immune response. *Cytokine* 2019; 113:89-98.
- Rosalin Hongsathavijl, Yosvimol Kuphasukl KR. Effectiveness of platelet-rich fibrin in the management of pain and delayed wound healing. *Eur J Dent* 2017; 11:192-5.
- Doll C, Carl F, Neumann K, Voss JO, Hartwig S, Waluga R, et al. Odontogenic abscess-related emergency hospital admissions: a retrospective data analysis of 120 children and young people requiring surgical drainage. *Biomed Res Int* 2018;2018.
- Zarban A, Ebrahimipour S, Sharifzadeh GR, Rashed-Mohassel A, Barkooi M. Comparison of salivary antioxidants in children with primary tooth abscesses before and after treatment in comparison with healthy subjects. *Asian Pacific J Cancer Prev* 2017; 18:3315-8.
- Gan L, O'Hanlon TP, Lai Z, Fannin R, Weller ML, Rider LG, et al. Gene expression profiles from disease discordant twins suggest shared antiviral pathways and viral exposures among multiple systemic autoimmune diseases. *PLoS One* 2015; 10:1-15.
- López-Mejías R, Genre F, Remuzgo-Martínez S, Pérez BS, Castañeda S, Llorca J, et al. Role of PTPN22 and CSK gene polymorphisms as predictors of susceptibility and clinical heterogeneity in patients with Henoch-Schönlein purpura (IgA vasculitis). *Arthritis Res Ther* 2015; 17.
- López-Mejías R, Genre F, Pérez BS, Castañeda S, Ortego-Centeno N, Llorca J, et al. Association of HLA-B*41:02 with Henoch-Schönlein Purpura (IgA Vasculitis) in Spanish individuals irrespective of the HLA-DRB1 status. *Arthritis Res Ther* 2015;17:4-9.
- Zhang X, Wu L, Chai M, Huang X, Zhu J, Li S, et al. Angiotensin-converting enzyme insertion/deletion polymorphism and susceptibility to Henoch-Schönlein purpura: a meta-analysis. *JRAAS - J Renin-Angiotensin-Aldosterone Syst* 2019; 20:1-6.
- Nakaseko H, Uemura O, Nagai T, Yamakawa S, Hibi Y, Yamasaki Y, et al. High prevalence of sinusitis in children with Henoch-Schönlein purpura. *Int J Pediatr* 2011; 2011:1-3.