

# Management of Lobular Capillary Hemangioma on Upper Lip Aggravated with Lip Biting Habit in Uncooperative Children: A Case Report

*by Udijanto Tedjosongko*

---

**Submission date:** 05-Dec-2022 01:49PM (UTC+0800)

**Submission ID:** 1971708372

**File name:** 57-D22\_1856\_Reninditha\_Hanna\_Busroni\_Indonesia.pdf (1.22M)

**Word count:** 2400

**Character count:** 13630

## Management of Lobular Capillary Hemangioma on Upper Lip Aggravated with Lip Biting Habit in Uncooperative Children: A Case Report

Udijanto Tedjosasongko<sup>1\*</sup>, Reninditha Hanna Busroni<sup>1</sup>, Seno Pradopo<sup>1</sup>, Amalia Wimarizky<sup>1</sup>, Siti Nur Lestari<sup>2</sup>, Firi Cahaya Khairani<sup>2</sup>, Brian Maulani<sup>1</sup>, Achmad Nadian Permana<sup>1</sup>

1. Department of Pediatric Dentistry, Faculty of Dentistry, Universitas Airlangga, Surabaya-Indonesia.  
2. Pediatric Clinic of the Hajj General Hospital, Surabaya-Indonesia.

### Abstract

A lobular capillary haemangioma is a benign vascular lesion. It is a reactional response to constant minor trauma or irritation that caused overgrowth of the oral mucosa precipitated by poor oral hygiene, local infection, hormones, and steroid drugs.

This paper reports a case of a Lobular capillary haemangioma in the right upper lip mucosa of a 10 years old boy. Clinical examination revealed a red smooth flat surface papule in size 3mm transform into a 5mm white lobulated surface pustule and became a 7mm pedunculated nodule in less than 4 weeks of observation suspected aggravated with lip-biting habit. FNAB was performed and the provisional diagnosis was benign fibrohistiocytic tumor. The nodule was removed by surgical excision using electrocautery and sutured under general anaesthesia. Microscopic analysis from the excision showed a definitive diagnosis was Lobular capillary haemangioma.

The diagnosis of oral lesions in children is complex, especially with various clinical findings, and leads the dentist to consider distinct lesions with different diagnostic methods and treatment should be done and give non-traumatic experience to children.

Case report (J Int Dent Med Res 2022; 15(3): 1326-1329)

Keywords: Lobular Capillary Haemangioma, Benign Vascular Lesion, Pyogenic Granuloma.

Received date: 20 May 2022

Accept date: 16 July 2022

### Introduction

Lobular capillary haemangioma (LCH) is a benign vascular lesion. It is a reactional response to constant irritation or minor trauma that caused overgrowth of the oral mucosa. It can be precipitated by poor oral hygiene, local infection, steroids hormones, cheek or lip biting habits, and steroids drugs.<sup>6,7,10</sup> LCH can be found at any age but is more commonly seen in children and young adults, in a pediatric study, this lesion occurred at the average age of 6 to 10 years, with 1:1,5 preponderance females slightly more affected than males. The lesions are more common on the maxillary than on the mandible, and the anterior areas are more frequently

affected than the posterior ones. LCH can occur on cutaneous or mucosal sites. Cutaneous lesions occur more frequently than mucosal lesions and their occurrence in the oral cavity is common. Gingiva is the most commonly affected site in the oral cavity, calculated for 75% of all cases. Although the occurrence of these lesions on the lips, tongue, oral mucosa, and palate have also been reported, the labial mucosa is still rare.<sup>1,2,3,9</sup>

LCH is typically present as an asymptomatic, painless, single exophytic lesion with a diameter that varies from a few millimetres for small lesions to several centimetres for larger lesions then evolves slowly or rapidly over weeks to months. The colour may vary from pink, red to reddish-brown or purple depending on the age of the lesion, with young LCH being highly vascular, and matured lesions tend to become collagenized and pink. Mature lesions are a polypoid or pedunculated and sessile types of lesions are rare. The surface is smooth and sometimes lobulated and friable. LCH can show profuse bleeding with even minor trauma. When ulcerated, the surface of the lesion is covered with fibrin. Older lesions may present areas of

#### \*Corresponding author:

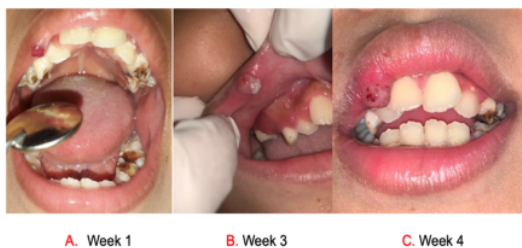
Udijanto Tedjosasongko,  
Department of Pediatric Dentistry,  
Faculty of Dental Medicine, Universitas Airlangga.  
Jl. Prof. Dr. Moestopo No 47  
Surabaya-Indonesia.  
E-mail: udijanto.tedjosasongko@gmail.com

fibrosis.<sup>1,2,4,6</sup> LCH is microscopically characterized by marked vascular proliferation granulation tissue and chronic inflammatory infiltrate. So much variety in clinical findings makes it difficult to assess a definitive diagnosis and needed different diagnostic methods before we decided on the optimal treatment.<sup>1</sup>

### Case Report

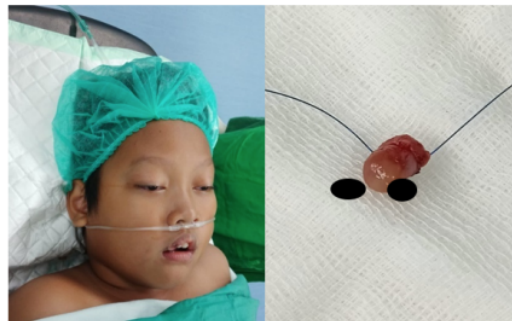A 10 years old boy came to Pediatric Dentist Clinic at Rumah Sakit Umum Haji Surabaya-East Java with the chief complaint of painless little swelling on his upper right lip mucosa which sometimes bleeds. The patient's medical and family history was non-contributory, and a general physical examination revealed no other abnormalities. The patient has poor oral hygiene and unknown lip biting habit.

Intraoral on the first visit (Figure 1A) examination revealed a solitary 3mm exophytic red smooth surface papule. Because of the uncooperative patient reasons and the poor oral hygiene, dental health education, scaling, and followed by applying OXYFRESH™ ointment to deodorize the lesion was done during the first visit. On the second visit examination, a week from the first visit (Figure 1B), the lesion was transforming into a 5 mm pustule and white lobulated surface. the lesion was suspected as a fistula from the nearest necrosed teeth. Cavity opening of necrosed teeth suspected as the source of infection was done because the lesion was still there.



**Figure 1.** Intra-oral examination revealed red smooth surface sized 3mm lesion at first visit (week 1) (A) into 5 mm pustule and white lobulated surface at second visit (week 3) (B), and then became 7mm pedunculated firm consistency nodule (week 4) (C).

Necrosed teeth extraction was done at the third visit (Figure 1C) followed by applying OXYFRESH™ ointment to enhance healing nevertheless the lesion was still there and then becoming a 7mm pedunculated firm consistency nodule in 4 weeks of observation. Although the patient denied any history of trauma to the upper lip and also when asked, the patient also denied the habit of biting on his upper lip, as we do the examination, we saw the patient unconsciously biting the lip and the lesion too, which made the determination of a traumatic etiological conclusive. In the 4<sup>th</sup> week, FNAB was taken from the lesion to establish the provisional diagnosis as a preparation for the surgical excision to make sure that there is no malignancy in the lesion because the size of the lesion was progressive. The FNAB result was a benign fibrohistiocytic tumor.

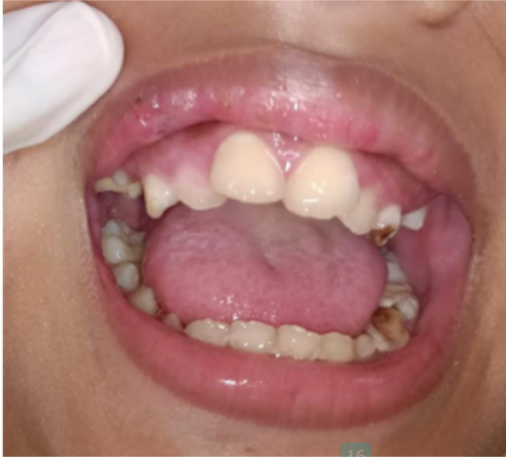

**Figure 2.** Surgical excision under general anaesthesia and the excised tissue was sent for histologic examination.

Complementary blood tests, complete blood count, erythrocyte sedimentation rate, and radiography of the pulmonary fields were also done and the result was within normal limits and was able to exclude non-dental infectious diseases and as preparation for the surgical excision under general anaesthesia. The nodule was removed by surgical excision using electrocautery and sutured under general anaesthesia because of the uncooperative patient (Figure 2). The excised tissue was sent for histologic examination. Microscopic analysis of the excisional lesion showed a squamous epithelium, the proliferation of small blood vessels lined by fibrous connective tissue stroma with inflammatory cells infiltration of lymphocytes, histiocytes, and neutrophils resulting definitive



diagnosis are Lobular capillary haemangioma. One week postoperatively, there was no complaint from the patient. The surgical site healed well and the sutures were removed (Figure 3).



**Figure 3.** Day 7 post-operative. The surgical site healed well and the sutures were removed.

### Discussion

Lobular capillary haemangioma is also known as vascular epulis, benign vascular tumor, or haemangiomatous granuloma. Various factors are implicated in etiopathogenesis. but trauma and hormonal imbalance have been suggested as potential contributing factors.<sup>7</sup> Few lesions caused by direct trauma but mostly due to constant irritation, minor or micro trauma and add on with precipitating factors such as chronic irritation due to exfoliation of deciduous teeth, sharp tooth, the eruption of permanent teeth, faulty filling, food impaction, bad tooth brushing technique, and malocclusion teeth may result in excessive tissue repair response.<sup>2,3,6</sup>

In this present case, lip-biting habit and poor oral hygiene was the probable etiology. It triggers and eventually enhanced lesion enlargement at the same time. Lip biting caused microtrauma that triggers inflammation and biomolecular tissue repair. Lip biting provides a stimulus for the excessive proliferation of the vascular type of connective tissue.<sup>6</sup> histologically, the proliferation of granulation tissue with chronic inflammatory infiltrate mostly lymphocytes, plasma cells, and neutrophils. Incorporates the

emigration of inflammatory cells, exodus, and proliferation of vascular endothelial cells and fibroblasts cells, and formation of extracellular matrix. Poor oral hygiene provides a pathway for invasion of the tissue by nonspecific microorganisms. Certain authors have suggested bacteria streptococcus or staphylococci bacilli in the lesion from oral microflora, relatively because it was depicted that these microorganisms could develop colonies with a fungus-like appearance.<sup>3,7,8</sup>

Clinical features of Lobular capillary haemangioma had various sizes, forms, colours, and periods time of growth that we can find in clinical examination. The initial lesion is usually a few millimetres in size, presenting as a papule or nodule, although cases with sizes up to a few centimetres have also been reported with colors starting from red to reddish-brown and become pale because immature LCH are highly vascular in appearance and composed predominantly of hyperplastic granulation tissue in which the capillaries are prominent. The vascularity decreases and the clinical appearance is more collagenous and pinker. In approximately 4 weeks the lesions are matured, sessile, pedunculated, and had a fibrin leukocytic surface membrane. This clinical transformation makes it hard to establish a diagnosis at the first visit and needed other examination.<sup>2,9</sup>

To reach an accurate diagnosis it is important to observe clinical signs as well as ascertain the detailed clinical history of the patient's systemic circumstances, as well as of local factors which might stimulate tissue response and subsequent formation of Lobular capillary haemangioma. Clinical diagnosis must always be confirmed with the histological examination that is supposed to show a highly vascular proliferation that resembles granulation tissue. Numerous small and larger endothelium-lined channels are formed, that are engorged with red blood cells. These vessels are sometimes organized in lobular aggregates.<sup>9</sup>

According to what was observed in the present case, one of the most important contributing factors to be considered is oral hygiene, therefore, Dental health education and treatment than enhanced good oral hygiene must be considered the first step in Lobular capillary haemangioma treatment and to minimize the effect of untreated lesion that might lead to secondary infections complication.<sup>5,6</sup> Definitive

diagnosis cannot be achieved only by clinical findings, many differential diagnoses may resemble. In this case, a preliminary histopathologic examination was done. Although provisional and definitive can differ, FNAB is done to exclude malignancies such as Kaposi's sarcoma, angiosarcoma, and non-Hodgkin's. Spindle cells with round and smooth nuclei were found, a few histiocytes, lymphocytes, and erythrocytes were seen and the provisional diagnosis was benign. A blood test is done to exclude conventional granulation tissue and fistula.<sup>1</sup>

The selection of a treatment modality should be based on consideration of an improvement in esthetic appearance and the function of soft tissues with minimal invasion. The treatment of LCH consists of conservative surgical excision as the most common treatment. Surgical excision suppresses the 16% recurrence rate that might be caused by the herpes virus, or arteriovenous malformation. The surgical excision procedure was simple and essential for definitive diagnosis.<sup>4,5,6</sup> Oral and Dental management should include behaviour management.<sup>11</sup> In the case of the uncooperative patient, behaviour management needs more effort and Surgical excision treatment is chosen under general anaesthesia. And the use of an electrocutter for minimized the bleeding for better wound healing. Excision should be given with 2 mm margins at its periphery and to a distance inward of the mucosa to minimize the recurrence rate and non-traumatic experience to the children.<sup>5,6</sup>

### Conclusions

The management of lobular capillary haemangioma on the upper lip aggravated with lip-biting habit treated with surgical excision using electrocautery under general anaesthesia had given good results and non-traumatic experiences to the children

### Acknowledgements

The authors are grateful to the Faculty of Dental Medicine, Universitas Airlangga, Surabaya, East Java, Indonesia, and the Pediatric Clinic of the Hajj General Hospital, Surabaya-Indonesia for the support and the facilities.

### Declaration of Interest

The authors report no conflict of interest.

### References

1. Gonçalves, E. S., Damante, J. H., Rubira, C. M. F., & Taveira, L. A. D. A. Lobular capillary hemangioma on the upper lip: an unusual location. *Journal of Applied Oral Science*. 2010; 18: 538-541.
2. Parajuli, R., & Maharjan, S. Unusual presentation of oral pyogenic granulomas: a review of two cases. *Clinical Case Reports*. 2018; 6(4): 690.
3. Sharma, S., Chandra, S., Gupta, S., & Srivastava, S. Heterogeneous conceptualization of etiopathogenesis: Oral pyogenic granuloma. *National Journal of Maxillofacial Surgery*. 2019; 10(1): 3.
4. Sharma, S., Singh, S., Yadav, L., & Tyagi, S. Pyogenic granuloma: A case report and a comprehensive review. *Journal of Oral Research and Review*. 2021; 13(1): 53.
5. Gadea Rosa, C., Cartagena Lay, A., & Cáceres La Torre, A. Oral pyogenic granuloma diagnosis and treatment: a series of cases. *Revista odontológica Mexicana*. 2017; 21(4): 253-261.
6. Samieifar M, Hematzadeh S, Esmaeilnejad A. Nonsurgical Management of Rapidly Recurrent Gingival Pyogenic Granuloma: A Case Report and Review of Literature. *Journal of International Dental and Medical Research*. 2018; 11(3): 1076-81.
7. Canivell-Zabaleta, M., Martin-Lozano, G., Olmos-Juarez, E., Fontillon-Alberdi, M., & Infante-Cossio, P. Extralingival pregnancy pyogenic granuloma on the lip. *Journal of Craniofacial Surgery*. 2018; 29(1): 49-50.
8. Asha, V., Dhanya, M., Patil, B. A., & Revanna, G. An unusual presentation of pyogenic granuloma of the lower lip. *Contemporary clinical dentistry*. 2014; 5(4): 524.
9. Kamala, K. A., Ashok, L., & Sujatha, G. P. Pyogenic granuloma on the upper labial mucosa: a case report. *Journal of clinical and diagnostic research*. 2013; 7(6): 1244.
10. Sharma S, Chandra S, Gupta S, Srivastava S. Heterogeneous conceptualization of etiopathogenesis: Oral pyogenic granuloma. *Natl J Maxillofac Surg*. 2019; Jan-Jun;10(1): 3-7.
11. Babaji P, Prashant MA, Manjunath BC, RM VR, Sharma N. Sturge-Weber Syndrome in Association with Pyogenic Granuloma. *Journal of International Dental and Medical Research*. 2012; 5(1): 41-4.

# Management of Lobular Capillary Hemangioma on Upper Lip Aggravated with Lip Biting Habit in Uncooperative Children: A Case Report

## ORIGINALITY REPORT

20%

SIMILARITY INDEX

14%

INTERNET SOURCES

15%

PUBLICATIONS

3%

STUDENT PAPERS

## PRIMARY SOURCES

- 1 Ramesh Parajuli, Sushna Maharjan. "Unusual presentation of oral pyogenic granulomas: a review of two cases", *Clinical Case Reports*, 2018  
Publication 3%
- 2 [www.karyailmiah.trisakti.ac.id](http://www.karyailmiah.trisakti.ac.id)  
Internet Source 2%
- 3 P Balaji, S Latha, Usha Jambunath, MB Sowbhagya. "Pyogenic Granuloma of Buccal Mucosa: An Unusual Presentation", *Journal of Health Sciences & Research*, 2015  
Publication 2%
- 4 H. N. Santosh, Tejavathi Nagaraj, Aditi Bose. "Oral pyogenic granuloma of upper labial mucosa: An unusual case presentation", *International Journal of Medical & Dental Case Reports*, 2015  
Publication 2%
- 5 [www.jids.org.in](http://www.jids.org.in)

Internet Source

2%

6

[austinpublishinggroup.com](http://austinpublishinggroup.com)

Internet Source

1%

7

[kclpure.kcl.ac.uk](http://kclpure.kcl.ac.uk)

Internet Source

1%

8

[www.birpublications.org](http://www.birpublications.org)

Internet Source

1%

9

[idoc.pub](http://idoc.pub)

Internet Source

1%

10

[njbcs.net](http://njbcs.net)

Internet Source

1%

11

[rep.nacd.in](http://rep.nacd.in)

Internet Source

1%

12

Assim Banjar, Abrar Abdrabuh, Manaf Al - Habshi, Mohamed Parambil, Pedro Bastos, Hassan Abed. "Labial pyogenic granuloma related to trauma: A case report and mini - review", Dental Traumatology, 2020

Publication

1%

13

Submitted to Universitas Airlangga

Student Paper

1%

14

[www.thieme-connect.com](http://www.thieme-connect.com)

Internet Source

1%

[mafiadoc.com](http://mafiadoc.com)

15

Internet Source

1 %

16

Boffeli, Troy J., and Kyle W. Abben. "Acral Fibrokeratoma of the Foot Treated with Excision and Trap Door Flap Closure: A Case Report", *The Journal of Foot & Ankle Surgery*, 2013.

Publication

<1 %

17

[meddocsonline.org](http://meddocsonline.org)

Internet Source

<1 %

18

[pubs.sciepub.com](http://pubs.sciepub.com)

Internet Source

<1 %

19

[www.actascientific.com](http://www.actascientific.com)

Internet Source

<1 %

Exclude quotes    On

Exclude matches    Off

Exclude bibliography    On



# Management of Lobular Capillary Hemangioma on Upper Lip Aggravated with Lip Biting Habit in Uncooperative Children: A Case Report

---

GRADEMARK REPORT

---

FINAL GRADE

**/0**

GENERAL COMMENTS

**Instructor**

---

PAGE 1

---

PAGE 2

---

PAGE 3

---

PAGE 4

---