

# Modified Closed Cap Splint for Symphysis/Parasymphysis Mandibular Fracture Management: A Case Report

*by Udijanto Tedjosasongko*

---

**Submission date:** 27-Feb-2023 01:28PM (UTC+0800)

**Submission ID:** 2024014252

**File name:** 56-D22\_1826\_Tania\_Saskianti\_Indonesia.pdf (2.74M)

**Word count:** 3271

**Character count:** 17992

## Modified Closed Cap Splint for Symphysis/Parasymphysis Mandibular Fracture Management: A Case Report

Tania Saskianti<sup>1\*</sup>, Aisyah Marwah<sup>1</sup>, Udijanto Tedjosasongko<sup>1</sup>, Ardianti Maartrina Dewi<sup>1</sup>,  
Brian Maulani<sup>1</sup>, Luluk Rahmawati<sup>1</sup>

1. Department of Pediatric Dentistry, Faculty of Dental Medicine, Universitas Airlangga, Surabaya - Indonesia.

### Abstract

The most common type of fracture in children is a mandibular fracture with an incidence rate of 56%, followed by symphysis/parasymphysis fractures which occur 15-20% of the time. Repositioning of teeth and jaws is necessary to restore function, aesthetics, and prevent pathological conditions of bone structure. A 9-year-old boy was referred to the Universitas Airlangga Hospital with oral bleeding, tooth mobility, and a shift in lower jaw position after an accident. Fractures and abnormalities in the position of the symphysis/parasymphysis were discovered, along with avulsion of teeth. Wound cleaning and suturing were performed on the mandibular symphysis/parasymphysis fracture segment, followed by the placement of a modified closed cap splint on the 7th day. Modified closed cap splint is safe and effective for pediatric mandibular fractures, especially in the symphysis/parasymphysis region.

Case report (J Int Dent Med Res 2022; 15(3): 1320-1325)

**Keywords:** Symphysis Fracture, Parasymphysis Fracture, Good Health and Well-Being, Modified Closed Cap Splint.

Received date: 14 April 2022

Accept date: 19 May 2022

### Introduction

Dentoalveolar trauma is the most pressing issue affecting today's children. Because it occurs on a rapidly growing bone, pediatric bone fracture is a unique disease.<sup>1</sup> Trauma can cause fractures, displacement and loss of front teeth, which results in changes in function, aesthetics, speech disturbances, and psychological effects that can reduce quality of life.<sup>2</sup> In pediatric patients, symphysis/parasymphysis fractures account for 15 to 20 percent of all fractures.<sup>3</sup> The treatment options for children mandibular fractures are dissimilar to those for adults. The existence of a relatively flexible elastic bone, instability of deciduous or mixed dentition, and the patient's level of cooperation all contribute to these variances. In pediatric instances, open reduction with rigid fixation is not commonly used

due to the risk of interrupting the periosteum and inducing tooth germ destruction.<sup>4</sup> The goal of treating these fractures is to restore the bone architecture to a stable position with as little invasiveness as possible to restore aesthetic appeal.<sup>5</sup> Hence, it should be managed carefully. The aim of the reported case is to give pediatric dentists a better understanding regarding the management of mandibular fractures in children and to help them manage this unique and highly specialized area of traumatology.

### Case Report

A 9-year-old boy was referred to the Universitas Airlangga Hospital with oral bleeding, tooth mobility, a shift in lower jaw position after an accident, and and felt that there was a loose tooth at the time of the incident. The patient is conscious, there is no history of fainting, no history of nausea and vomiting, the patient remembers the incident. The patient did not feel dizzy after the incident, and there was no bleeding from the nose and ears. There is no limitation in opening and closing the mouth. Fractures of the symphysis/ parasymphysis were found in teeth region #32, #31, #41 with avulsion on teeth #42, #73, #83. Bleeding was still visible (Fig.1). OPG x-ray examination showed a

#### \*Corresponding author:

Tania Saskianti,  
Department of Pediatric Dentistry, Faculty of Dental Medicine,  
Universitas Airlangga  
Prof. Dr. Moestopo No 47  
Surabaya-Indonesia.  
E-mail: [tania-s@fkg.unair.ac.id](mailto:tania-s@fkg.unair.ac.id)

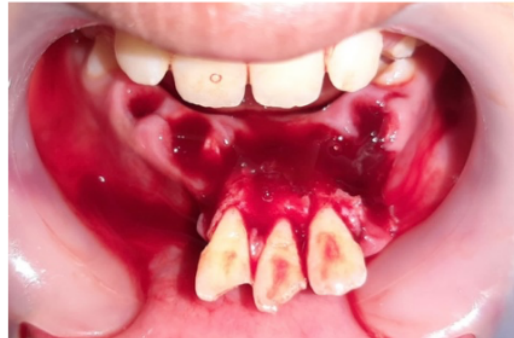horizontal fracture line in the region of teeth #41, #31, #32 and an edentulous ridge in the region of teeth #42, #73, #83. Based on clinical and radiological examination, it led to the diagnosis of a symphysis/ parasymphysis fracture (Fig.2). We decided to do fixation with a modified closed cap acrylic splint in the fracture area as the treatment approach for this patient. Reposition, debridement, and irrigation with sterile Pz were performed the first time the patient came in, followed by bleeding control with gauze. On day 1, suture the anterior mandibular region with up to 7 sutures to stabilize the symphysis/parasymphysis fracture area before making an impression for the acrylic cap splint (Fig. 3). Post-treatment instruction is to consume a soft, high-carbohydrate, high-protein diet. Patients were also given amoxicillin antibiotics, paracetamol anti-pain medication, and aloclair mouthwash.

On day 6 follow-up visit, the gingiva was considerably red, and there was food debris in the suture areas. The patient's parents reported that they had carefully followed all of the operator's directions. We do elastomer impressions of the maxillary and mandibular teeth to create a modified closed cap splint.

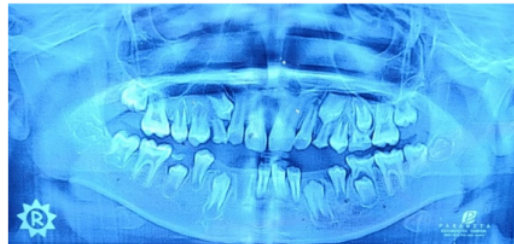
The patient had no concerns at the follow-up appointment on day 13. The symphysis/parasymphysis area relatively stable. However, there was still some swaying in fracture area. Modified closed cap splint was inserted on the mandible, with fixation using the GIC luting in the molar area (Fig. 4). On follow-up appointment day 25, the patient felt that the modified closed cap splint started to loosen, and there was a sensitive area in the lower right region. Based on the intra-oral condition, the cap splint was blocking tooth #44, which was erupting. As a result, the modified cap splint of tooth #44 was expanded, the teeth were debrided and scaled, and the modified cap splint cap was reinserted.

The modified cap splint was removed during the day 34 follow-up appointment. The symphysis/ parasymphysis was found to be significantly more stable, no sign of inflammation and healthy healing was observed. Mobility of fragmented segments was not elicited, teeth #41, #31, #32 had proper occlusion and no movement, and the patient was more comfortable (Fig. 5). Postoperative OPG (Fig.6), Showing the development of the root #32, #31, #41, showing

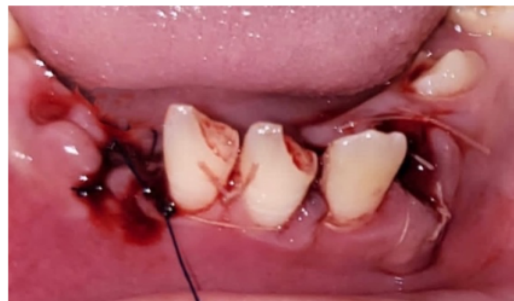the teeth's response to therapy in comparison to their initial status. The presence of radiolucent images on the apical teeth #32 #31 #41 indicates inflammation as a healing response, and a decrease in periodontal ligament's broadening. The patient was prescribed celecoxib as an anti-inflammatory and to accelerate the healing of the alveolar bone.



**Figure 1.** Intra-oral examination revealed symphysis/parasymphysis fractures in the dentoalveolar region #32, #31, #41 with avulsion on tooth #42, #73, #83.



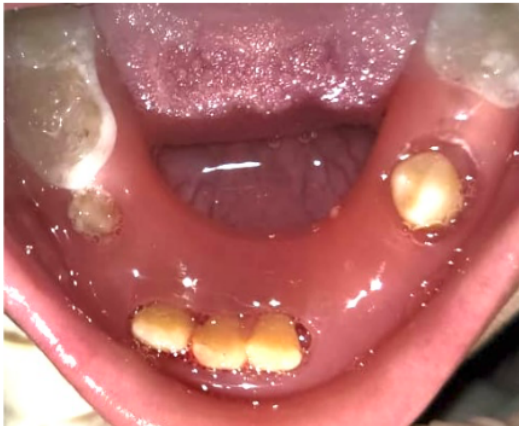**Figure 2.** Preoperative OPG. horizontal fracture line in the region of teeth #41 #31 #32.



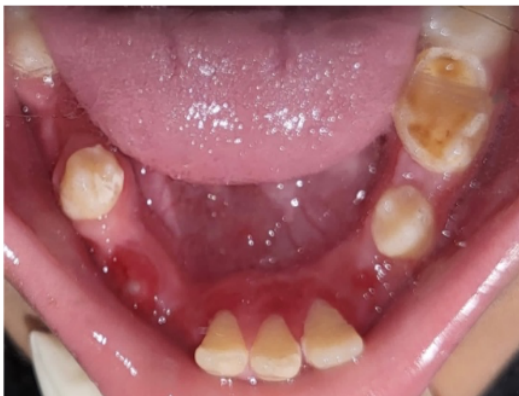**Figure 3.** Suturing the front mandibular region.

A month after the splint cap was removed, a follow-up visit was conducted; there were no subjective complaints, and the symphysis/

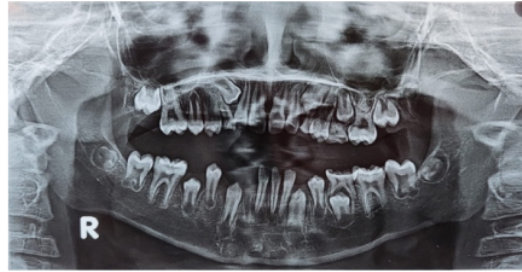
parasymphysis fractures were shown to be healing. The bones and teeth have no swelling, redness, or movement. The condition of the anterior teeth were vital, there are no abnormalities during percussion and druk tests, and no mobility. Composite filling were performed on teeth #31 and #41. (Fig. 7). The apical tooth #32, #31, #41 has closed, and the radiolucent appearance on apical #32, #31, #41 seems faint in an OPG x-ray, indicating periodontal regeneration. Treatment results show good healing of soft tissue and hard tissue injury.



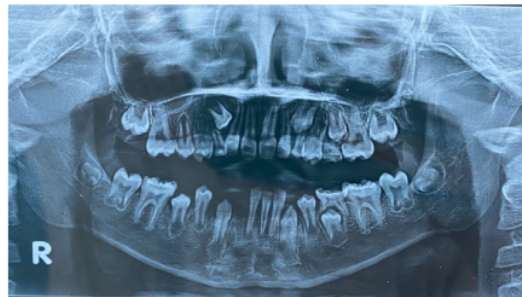**Figure 4.** Modified closed cap splint was inserted in the mandible, with fixation using the GIC luting in the molar area.



**Figure 5.** Day 34. Modified closed cap splint has removed. The symphysis/parasymphysis area substantially more stable, there is still redness of the gingiva due to the compression of the cap splint.



**Figure 6.** Postoperative OPG on day 34. Showing the development of the root #32 #31 #41.



**Figure 7.** OPG after 1 month follow-up after the modified cap splint was removed. The apical area of tooth #32, #31, #41 has closed, and the apical tooth's radiolucent appearance has diminished.

## Discussion

Treatment of dentoalveolar fractures in children differs from that of adults, mostly because of the potential for growth interruption. The final result in children is dictated not merely by the initial therapy, but also by the effect of growing on form and function.<sup>6</sup> Fracture fragments must be diminished<sup>7</sup> and fixed immediately to allow for efficient healing and return to normal function. Also, pediatric facial fractures must be managed as early as possible to allow for normal growth and development of the dentofacial complex. As an outcome, the goal is to reestablish skeletal structure as early as effective ways to reduce morbidity in terms of form and function and to get the tooth and digestive organs back to its normal.<sup>7,8</sup>

The treatment of pediatric mandibular fractures is also depending on the patient's cooperation.<sup>5</sup> When determining on a treatment method, children have a higher osteogenic

potential and a faster rate of recovery than adults, anatomic reduction should be accomplished earlier in children, and immobilization times should be shorter, i.e. 2-3 weeks compared 4-6 weeks in adults.<sup>9</sup> In adults, absolute fracture reduction and fixation is recommended, whereas in children, closed reduction and minimal facial skeleton modification is required.<sup>10</sup>

Some of patient's permanent and primary teeth were avulsed. Because the patient's parents do not bring their permanent tooth, it cannot be reimplanted. The deciduous tooth was also not reimplanted because it has the potential to alter the succedaneous tooth significantly. Dilacerations, enamel hypoplasia, impactions, and deviation from the normal eruption path are all potential consequences. Radicular cysts have also been linked to replanted primary teeth in other studies.<sup>11</sup>

Trauma treatment is divided into two stages: emergency treatment and therapy for dental or alveolar bone fractures caused by trauma.<sup>8</sup> According to the case report section, the patient came with intraoral bleeding condition caused by trauma resulting in symphysis/parasymphysis fracture. Wound debridement, antibiotics, and analgesics are the first treatments used to relieve the pain. Antibiotics are prescribed since dental infections can be caused by dental trauma and periodontal diseases, which could have devastating effects that affect both the soft and hard tissues of the oral cavity.<sup>12</sup>

Treatment options for mandibular fractures include closed reduction with intermaxillary fixation (IMF), open reduction with intraosseous wires, and internal rigid fixation by miniplates and screws. Some of the additional treatments include tape muzzles, circumferential wire, acrylic splints, percutaneous skeletal fixation, nickel titanium staples, orthodontic resin, modified orthodontic brackets, and rubber elastics.<sup>5</sup> According to a study by Kocabay et al, IMF is not well tolerated by children because it blocks mandibular movements, causing discomfort and anxiety; additionally, it is important to the child's quality of life because a liquid diet reduces nutritional intake and should be used with caution because it can cause TMJ ankylosis. The main disadvantage of rigid splints is gingival stress, increased force transmission to the fracture fragment, and a long procedure.<sup>9</sup>

The following are some of the most

commonly advised treatments for treating mandibular fractures:<sup>3</sup>

0 to 2 years: edentulous problems are treated with a MacLennan style of splint.

2 to 4 years: If well formed sound deciduous teeth eyelet wiring can be used, cap splint

5 to 8 years: Cap splints, MacLennan,

9 to 11 years: Cap Splints, arch bars, plating or trans- osseous wiring at the lower border.

The most common paediatric fractures are green stick or non-displaced, and the most common effective treatments are observation or conservative closed reduction.<sup>13</sup> The treatment of the reported case is a modified closed cap splint, this method is used when a patient has displaced fractures but not enough teeth to require dentition wire, or if there is a risk of iatrogenic trauma to growing tooth buds and partially erupted teeth. It can be used as dentoalveolar fracture immobilization tool.<sup>14</sup> Modified closed cap splint is more reliable than circum-mandibular wiring with cap splint, open reduction, or intermaxillary fixation because it is simple, easy to make, and less time consuming. Other benefits include simplicity of application and removal, reduced time commitment, cost effectiveness, good stability during the healing period, and minimum harm to adjacent tissues. This material can be easily applied and is beneficial in emergency of dentoalveolar fracture. As a result, the modified closed cap splint should be a reliable method in pediatric patients with minimally displaced mandibular fractures. A modified closed cap splint can be made and cemented with luting cement to preserve the stability.<sup>5</sup> In this present case, the modified closed cap splint was fabricated and cemented with GIC luting cement.

Splinting is recommended for periodontal therapy for 2-4 weeks, in some cases that lose periodontal support or marginal bone damage should be increased to 8 weeks. A periodontal ligament typically takes four months to heal effectively.<sup>8</sup> In the present case, a modified closed cap splint was used for 3 weeks. The symphysis/ parasymphysis was found to be significantly more stable, no sign of inflammation and healthy healing was observed. Mobility of fragmented segments was not elicited, teeth #41, #31, #32 had proper occlusion and no movement.

Our study found no evidence of tissue intolerance, growth constraints, or occlusal anomalies, and the occlusal connection could be restored. The advantages to children are obvious,

as patient comfort is increased. This result is in line with the statement that children's bones repair rapidly, due to their thicker, extremely osteogenic periosteum. The patient's age has a direct impact on how fast a fracture heals: the younger the child, the speedier the fracture heals. As a child grows older, the periosteum thins it becomes less osteogenic. Physeal injuries heal for around 3 weeks in substantially all regions of the body.<sup>15</sup>

The prevention of complications following the treatment of mandible fractures is also critical. Complication rates are closely proportional to the type of injury and the location of the fracture, regardless of whether open or closed reduction is used. Complications include infection, osteomyelitis, nonunion, malunion, and wound dehiscence.<sup>16</sup> In our study, infection was not detected in any of the patients in the follow-up period.

Thus, the clinical success of the modified closed cap splint in the present case of symphysis/parasymphysis shows that it is an efficient method. Long-term monitoring is required to check for developmental issues in the growing permanent tooth bud involved in the fracture location, as well as to monitor the patient's facial growth.<sup>17</sup> The disadvantage of wearing an acrylic splint is the retention of food debris on the appliance's body and base<sup>18</sup>, which is difficult to clean and can cause gingival or mucosal inflammation, but this can be avoided by teaching the patient's parents to help with dental hygiene.

Parents and society should be reminded of the importance of preventive measures. Coaches, administrators, teachers, and parents, as well as any concerned supervisory persons, should be educated. Because of the frequency and severity of sports-related injuries and injuries caused by motor vehicle accidents, children should be encouraged to establish good habits. Protective helmets, seat restraints, standard seat belts, mouth guards, and other items, along with good parental supervision, can prevent injuries in children.<sup>9</sup>

## Conclusions

The modified closed cap splint, which is easy, effective, and minimally invasive, is one of the treatments of choice for treating symphysis/parasymphysis fractures in children. The splint

was stable enough to allow for initial bone repair of the mandible. The cap splint's stability was adequate for fracture fixing, according to our findings. Our investigation found no tissue intolerance, growth constraints, or occlusal anomalies, and the occlusal connection could be restored in all cases. The advantages for children are obvious, as patient comfort is increased.

## Acknowledgements

The authors are grateful to the Faculty of Dental Medicine, Universitas Airlangga, Surabaya, East Java, Indonesia for the support and the facilities.

## Declaration of Interest

The authors report no conflict of interest.

## References

1. Nur Cahyo DS, Widyastuti MG, Rahajoe PS. Pengelolaan Fraktur Dentoalveolar pada Anak-Anak dengan Cap Splint Akrilik. *Maj Kedokt Gigi Indones*. 2015;20(2):216.
2. Bourguignon C, Cohenca N, Lauridsen E, Flores MT, O'Connell AC, Day PF, et al. International Association of Dental Traumatology guidelines for the management of traumatic dental injuries: 1. Fractures and luxations. *Dent Traumatol*. 2020;36(4):314–30.
3. Sharma R, Sharma A, Khairwa A. Management of Symphysis and Parasymphysis Mandibular Fractures in Children Treated with MacLennan Splint: Stability and Early Results. *Int J Clin Pediatr Dent*. 2015;8(2):127–32.
4. Chakravarthy C, Gupta NC, Patil R. A Simplified Digital Workflow for the Treatment of Pediatric Mandibular Fractures Using Three-Dimensional (3D) Printed Cap Splint: A Case Report. *Craniofacial Trauma Reconstr*. 2019;3(1):s0039-1694765.
5. Kumar N, Richa, Gauba K. Modified closed cap splint: Conservative method for minimally displaced pediatric mandibular fracture. *Saudi Dent J [Internet]*. 2018;30(1):85–8. Available from: <https://doi.org/10.1016/j.sdentj.2017.11.002>
6. Yadav R, Verma U, Tiwari R, Article O. Heterogeneous conceptualization of etiopathogenesis: Oral pyogenic granuloma. *Natl J Maxillofac Surg*. 2019;10(1):3–7.
7. Vidhya R, Madhu S, Vadakkepurayil K, V AKT. Management of Maxillary Dento Alveolar Fracture with A Modified Splinting Method : A Case Report. 2017;16(12):51–4.
8. W F, E S. Management of dentoalveolar fracture by using rigid wire and composite splint: A case report. *Intisari Sains Medis*. 2018;9(2):85–8.
9. Murthy PS, Shaik N, Deshmukh S. A conservative approach to pediatric mandibular dentoalveolar fracture and its management: A case report. 2017;9(12):63453-63455.
10. Kushalappa KM, Shet DR, Khalid I, Surgery M, Arabia S, Dentistry P. Vacuum Formed Closed Cap Splint as Treatment Modality for Paediatric Mandibular Fracture – A Case Report. 2020;5(1):194–202.
11. Thakur A, Thakur S. Management of a Complex Dentoalveolar Traumatic Injury with Multiple Avulsions. *Case Report in Dentistry*. 2021;2021(6):1-6.
12. Ahmadi H, Ebrahimi A, Ahmadi F. Antibiotic Therapy in Dentistry. *International Journal of Dentistry*. 2021;2021:1-10.
13. Dentistry P, Surgery M, Dentistry P, Surgery M, Surgery M, Dentistry P, et al. Role of Cap Splints in the Management of

- Paediatric Mandibular Fractures- a Case. 2020;07(11):5886-5897.
14. Jamal S, Motiwala MA, Ghafoor R. Conventional and contemporary approaches of splinting traumatized teeth: A review article. *J Pak Med Assoc.* 2020;70(2):S53–9.
15. Frick SL. Skeletal Growth, Development, and Healing as Related to Pediatric Trauma. Sixth Edit. *Green's Skeletal Trauma in Children: Fifth Edition.* Elsevier Inc.; 2015. 1–15. <https://doi.org/10.1016/B978-0-323-61336-1.00001-7>
16. Oruç M, Işık VM, Kankaya Y, Gürsoy K, Sungur N, Aslan G, et al. Analysis of fractured mandible over two decades. *J Craniofac Surg.* 2016;27(6):1457–61.
17. Nezam S, Kumar A, Shukla J, Khan S. Management of mandibular fracture in pediatric patient. *Natl J Maxillofac Surg.* 2018;9(1):106.
18. Bartlett D, Carter N, Felton D, Goffin G, Kawai Y, Muller F. White paper on guidelines for the use of denture adhesives and their benefits for oral and general health. *Oral Heal Found* .2019;(June):1–56. <https://www.dentalhealth.org/Handlers/Download.ashx?IDMF=aa48e389-9c7f-40b1-9d47-ac1dcb599897>.

# Modified Closed Cap Splint for Symphysis/Parasymphysis Mandibular Fracture Management: A Case Report

## ORIGINALITY REPORT

20%

SIMILARITY INDEX

16%

INTERNET SOURCES

12%

PUBLICATIONS

0%

STUDENT PAPERS

## PRIMARY SOURCES

1	Rajesh Sharma, Manohar Bhat, Anupama Sharma, Abhishek Khairwa. "Management of Symphysis and Parasymphysis Mandibular Fractures in Children Treated with MacLennan Splint: Stability and Early Results", International Journal of Clinical Pediatric Dentistry, 2015 Publication	3%
2	isainsmedis.id Internet Source	2%
3	www.thieme-connect.com Internet Source	2%
4	www.journalcra.com Internet Source	2%
5	www.jrmds.in Internet Source	1%
6	contempclindent.org Internet Source	1%



7

Internet Source

1 %

8

Nanik Zubaidah, Dian Dwi Pratiwi, Maria Margaretha S. Nogo Masa, Ernie Maduratna Setiawatie, Sri Kunarti. "The Osteogenesis Mechanisms of Dental Alveolar Bone Socket Post Induction with Hydroxyapatite Bovine Tooth Graft: An Animal Experimental in Rattus norvegicus Strain Wistar", European Journal of Dentistry, 2022

Publication

1 %

9

[ecommons.aku.edu](https://ecommons.aku.edu)

Internet Source

1 %

10

[scholarhub.ui.ac.id](https://scholarhub.ui.ac.id)

Internet Source

1 %

11

[www.science.gov](http://www.science.gov)

Internet Source

1 %

12

Bruce Lin, Rong Li, Thomas N.G. Handley, John D. Wade, Wenyi Li, Neil M. O'Brien-Simpson. "Cationic Antimicrobial Peptides Are Leading the Way to Combat Oropathogenic Infections", ACS Infectious Diseases, 2021

Publication

1 %

13

[actamedicaphilippina.upm.edu.ph](https://actamedicaphilippina.upm.edu.ph)

Internet Source

1 %

14

[journals.sagepub.com](https://journals.sagepub.com)

Internet Source

<1 %

15

Alexander Patera Nugraha, Ida Bagus Narmada, Diah Savitri Ernawati, Aristika Dinaryanti et al. "Bone alkaline phosphatase and osteocalcin expression of rat's Gingival mesenchymal stem cells cultured in platelet-rich fibrin for bone remodeling (in vitro study)", European Journal of Dentistry, 2019  
Publication

<1 %

16

Steven L. Frick. "Skeletal Growth, Development, and Healing as Related to Pediatric Trauma", Elsevier BV, 2015  
Publication

<1 %

17

[consortiumpublisher.ca](http://consortiumpublisher.ca)  
Internet Source

<1 %

18

[downloads.hindawi.com](http://downloads.hindawi.com)  
Internet Source

<1 %

19

[www.jisppd.com](http://www.jisppd.com)  
Internet Source

<1 %

20

Anita Thakur, Seema Thakur. "Management of a Complex Dentoalveolar Traumatic Injury with Multiple Avulsions", Case Reports in Dentistry, 2021  
Publication

<1 %

21

[jurnal.pdgi.or.id](http://jurnal.pdgi.or.id)  
Internet Source

<1 %

---

22

[www.njms.in](http://www.njms.in)

Internet Source

<1 %

---

23

Arti Dolas, Anand Shigli, Nupur Ninawe, Ritesh Kalaskar. "Management of Mandibular Fracture in Pediatric Patient Using Vacuum-Formed Splint: A Case Report", Dental Journal of Advance Studies, 2018

Publication

<1 %

---

---

Exclude quotes      Off

Exclude matches      Off

Exclude bibliography      On

# Modified Closed Cap Splint for Symphysis/Parasymphysis Mandibular Fracture Management: A Case Report

---

GRADEMARK REPORT

---

FINAL GRADE

**/0**

GENERAL COMMENTS

**Instructor**

---

PAGE 1

---

PAGE 2

---

PAGE 3

---

PAGE 4

---

PAGE 5

---

PAGE 6

---