

## Mucocele Excision Using Electrocautery in Pediatric Patient: A Case Report

Felita Putri Sutjipto<sup>1</sup>, Ardianti Maartrina Dewi<sup>1\*</sup>, Siti Nur Lestari<sup>2</sup>, Firli Cahaya Khairani<sup>2</sup>,  
Udijanto Tedjosasonko<sup>1</sup>, Soegeng Wahlujo<sup>1</sup>, Ilvana Ardiwirastuti<sup>1</sup>, Alit Rahma Estu<sup>1</sup>,  
Achmad Nadian Permana<sup>1</sup>, Puspita Ayuningtyas<sup>1</sup>

1. Department of Pediatric Dentistry, Faculty of Dental Medicine Universitas Airlangga.  
2. Pediatric Dentistry Department RSUD Haji Provinsi Jawa Timur.

### Abstract

Mucocele is the most common type of oral mucosal lesion. It is caused by an accumulation of mucous secretion as a result of trauma, lip biting habits, or a modify in the minor salivary gland.

Mucocele can occur anywhere in the oral mucosa, including the lip, cheeks, and floor of the mouth. It can be treated by a number of approaches. These include excision by scalpel, electrosurgery, laser ablation and intralesional corticosteroid injections. With advancements in pediatric dentistry, especially when treating young children, it is critical to plan treatment that gives the minimum amount of discomfort.

Electrocautery can be the treatment of choice for mucocele as it can alleviate the patient's anxiety and discomfort. It results in minimal bleeding and tissue damage.

Case report (J Int Dent Med Res 2022; 15(2): 680-684)

**Keywords:** Children, Mucocele, Electrocautery.

**Received date:** 12 April 2022

**Accept date:** 09 May 2022

### Introduction

Mucocele is a term derived from the Latin words mucus and cocele, which mean mucus and cavity.<sup>1</sup> It is the 15th most common oral mucosal lesion, with an estimated prevalence of 2.4 cases per 1000 people. Jones and Franklin's study of 4.406 pediatric patients revealed that the most common lesion was mucocele (16%).<sup>2</sup> Mucoceles are classified clinically into two types: extravasation and retention. Extravasation cysts are typically found in minor salivary glands and form as a result of fluid leakage from the salivary gland ducts and acini into the surrounding soft tissue, whereas retention cysts form as a result of salivary gland duct obstruction and are thus commonly found in major salivary gland ducts.<sup>3</sup>

Mucocele is distinguished by a rounded, well-circumscribed appearance. They are mostly soft and fluctuate when palpated, asymptomatic swellings ranging in color from deep blue to the color of the oral mucosa.<sup>4</sup> The blue color is caused by vascular congestion and tissular

cyanosis in the tissue.<sup>5</sup> The duration of a lesion varies from a few days to three years.<sup>6</sup>

Yamasoba *et al.* identify two important etiological factors in mucocele: traumatism and salivary gland duct obstruction.<sup>2</sup> There is no gender predilection, and it can occur at any age, but some studies indicate that the second decade has the highest incidence.<sup>7</sup> Although the majority of cases are asymptomatic, functional disturbances such as feeding difficulties and dietary habits may necessitate immediate surgical intervention.<sup>2</sup> Mucocele is primarily diagnosed based on history and clinical appearance, which includes rapid appearance, specific location, history of trauma, bluish color, soft consistency, and fluctuation.<sup>8</sup> An accurate assessment and anamnesis should be performed. The histopathological examination provides the final diagnosis.<sup>4</sup>

Some mucoceles rupture and heal on their own, but in many cases, local surgical excision is required which can be difficult, particularly in children and patients with behavioral issues.<sup>9</sup> The standard treatment for mucocele is surgical removal of the responsible minor salivary gland. Laser ablation, electrosurgery and intralesional corticosteroid injections are other treatment options. Although the prognosis is excellent, some lesions may relapse depending on the treatment approach

#### \*Corresponding author:

Ardianti Maartrina Dewi  
Department of Pediatric Dentistry, Faculty of Dental Medicine  
Universitas Airlangga, Indonesia.  
E-mail: [ardianti-m-d@fkg.unair.ac.id](mailto:ardianti-m-d@fkg.unair.ac.id)

used.<sup>10</sup> Limited study<sup>11</sup> on mucocele removal using electrocautery on pediatric patient have been published and it reported that using electrocautery is a faster, simpler with minimal postoperative discomfort than conventional surgical excision. Therefore this case report aims to report clinical cases of mucocele excision using electrocautery in pediatric patient in order to minimize trauma and pain in pediatric patient.

### Case Report

#### Case 1

A ten years old girl was brought to Pediatric Dentistry Department RSUD Haji Provinsi Jawa Timur with a chief complaint swelling present in the inner aspect of the lower lip in 41 42 region for the past three months. The child had also reported has lip biting habit. Swelling was painless and no past medical history like fever or malaises was present. On examination of the lesion, it was soft, fluctuant and palpable with the diameter 5 mm. The parent reported difficulty of eating and talking because of the lesion.

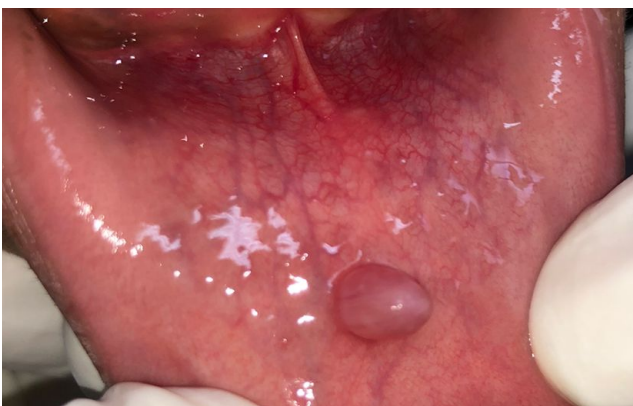

Figure 1. Lower lip view.

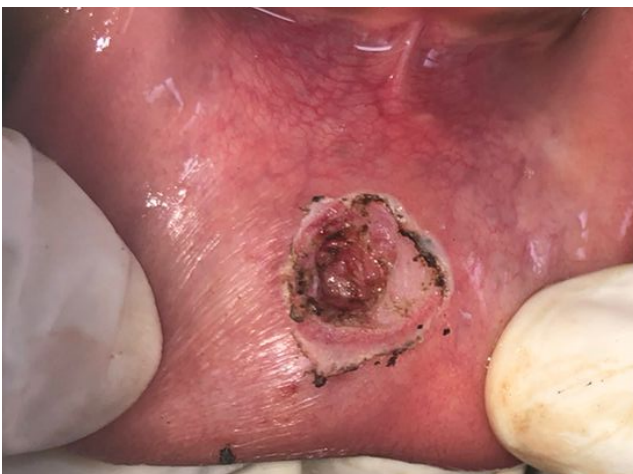

Figure 2. After excision by electrocautery.

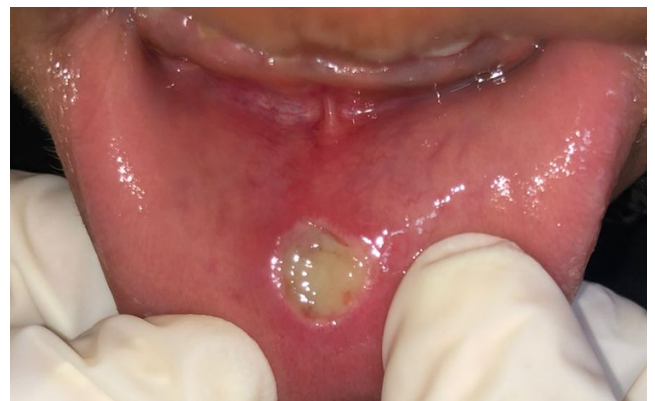

Figure 3. Seven days postoperative extra oral view.

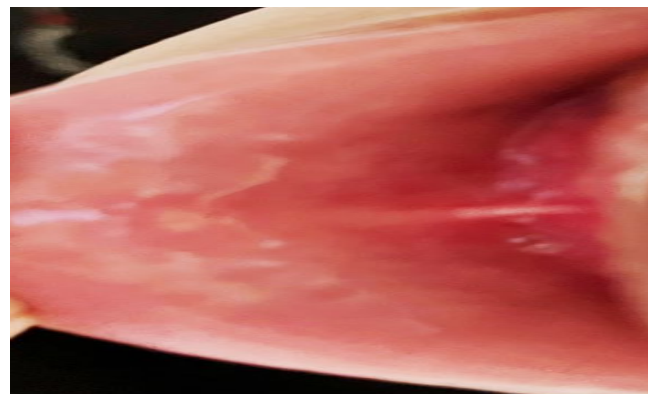


Figure 4. Three weeks postoperative extra oral view.

Finally, the case was diagnosed as a mucocele on the basis of the history of lip biting habit and clinical features. The treatment was planned and explained to the parents. Once obtains parent concern treatment was perform Considering the size of the swelling and the functional disturbances associated with it, the treatment plan was aimed for a complete surgical excision using electrocautery. Electrocautery was performed under local anesthesia administrated through local infiltration on the lower lip. The electrocautery set to mode cut + coagulant 1, with speed 5 and tip number T2 to remove the mucocele. The ideal way to obliging the lesion is to start at the peripheral margin of the lesion in circular motion. The excised lesion was stored in 10% formalin and sent to the Department of Oral Pathology at Rumah Sakit Haji. Post operative instructions recommended to the patient to avoid lip biting and spicy food. During and postoperative bleeding was very minimal and no sutures were necessary. Patient was prescribed with alloclair gel to relieve postoperative discomfort. The healing stage observed 7 days

after excision of the mucocele without any complains. After 21 days the tissue is completely healed.

#### Case 2

A 9 years old girl was brought to Pediatric Dentistry Department Rumah Sakit Haji Surabaya. On examination, a localized intra oral swelling was noticed on the left side of lower lip in 31 32 regions, measuring around 7mm.

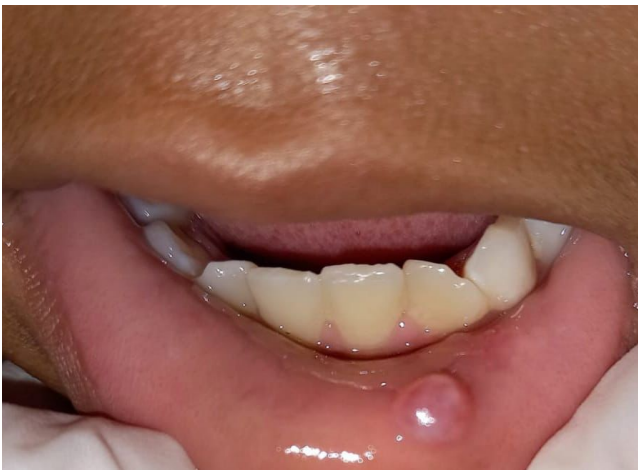

Figure 5. Lower lip view.

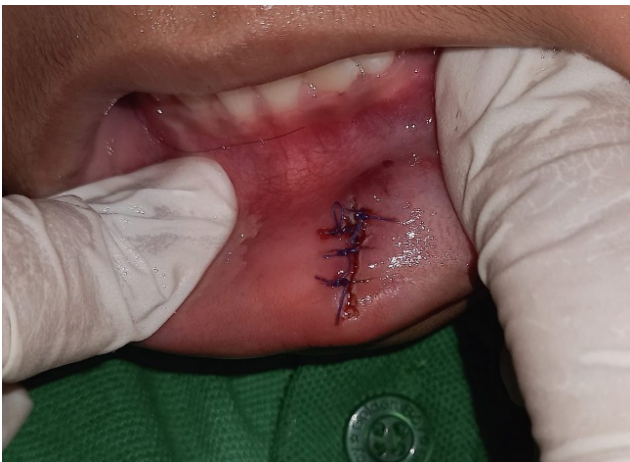

Figure 6. Suturing.

The parent reported the daughter has lip biting habit. A well circumscribed, transparent, swelling was seen. The swelling was flaccid and painless, with a smooth surface. Based on the history and clinical features, the lesion was provisionally diagnosed as mucocele. Given the size of the swelling and lack of cooperation with the patient, the treatment plan called for a complete surgical excision with electrocautery. Local anesthesia was administered via local

infiltration on the lower lip before electrocautery was performed. To remove the mucocele, the electrocautery was set to mode cut + coagulant 1, speed 5, and tip number T2. Lesion was sutured with 4-0 silk suture. The excised lesion was stored in 10% formalin and sent to the Department of Oral Pathology at Rumah Sakit Haji. Post operative instructions recommended to the patient to avoid lip biting and spicy food and was prescribed with aloclair gel to relieve postoperative discomfort. After a week the suture was removed. The lesion healed and no complaint from the patient.

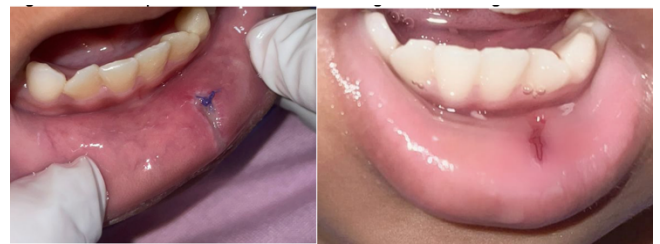

Figure 7. Seven days postoperative extra oral view.

#### Discussion

Clinically, oral mucosal lesions are highly variable and have distinct characteristics.<sup>12</sup> Mucocele are an oral pathological condition that, while not associated with significant morbidity, can cause discomfort and relapse.<sup>10</sup> According to the research, the recurrence rate is around 14%.<sup>13</sup> Oral habits such as lip biting/sucking are one of the etiologic factors for oral lesions such as mucocele. Continuous physical trauma can result in a leakage of salivary secretion into the surrounding submucosal tissue.<sup>4</sup> To avoid relapse the salivary gland tissue involved in the mucocele must be removed completely and break the habit of lip biting.<sup>14</sup>

In these two cases both mucoceles were caused by lip biting habit which may be related to psychological stress. Lip biting habit may occur as a result of a demanding environment in which a child is expected to understand his or her responsibility, control his or her childish behavior, and follow some rules, which may cause the child to feel frustrated and depressed.<sup>15</sup> This lip biting habit may arise because of the child anxiety over school. Covid 19 causes school to be online so that children can't meet their friend nor their teacher. This can cause psychological stress in children.

The size of mucocele ranges from 1-2 mm to several centimeters.<sup>10</sup> Clinical features such as external swelling and interference with mastication, swallowing, and speech, as well as discomfort, may occur depending on the size and location of the mucoceles.<sup>13</sup> Chi et al reported that the lower lip was the most common site for mucoceles (81.9 %), followed by the floor of the mouth (5.8%), and the ventral surface of the tongue (5%).<sup>16</sup> The cause of the proclivity of mucoceles to occur on the lower lip is unknown, but several studies have reported possible causes, including parafunctional habits (such as lip biting), differences in the mobility of the upper and lower lips, and differences in salivary gland density.<sup>17</sup> In this case report both lesions are on the lower lip that closely related to the lip biting habit. Lower lip mucocele treatment options include scalpel incision, electrocautery, laser ablation, and intralesional corticosteroid injections.<sup>13</sup>

Scalpel is one of the most-often used methods of excising a mucocele. It does not require extensive equipment, has negligible cost and can be performed by most trained dentists. It does require great precision and detailed knowledge of the mucocele and the surrounding anatomy. It also requires great control of the instrument, with accurate tactile awareness. The drawbacks of this technique are delayed postoperative healing, greater bleeding and postoperative discomfort.<sup>11</sup> A study by Foroughiasl comparing mucocele excision using scalpel and laser proved that postoperative bleeding is greater using scalpel than laser, as is the possibility of a more ulcerative appearance and a longer healing period.<sup>18</sup> With advancements in pediatric dentistry, especially when treating young children it is critical to plan treatment that gives the minimum amount of discomfort.<sup>19</sup>

Steroids play an important role in the treatment of Mucocele; a single intralesional steroid injection can be performed, followed by aspiration of the cyst fluid. It causes the pseudocyst wall to collapse and causes a severe inflammatory reaction in the wall, resulting in significant fibrosis.<sup>11</sup>

Lasers are frequently used in oral soft tissue surgery. Because this laser is strongly absorbed by water, its effect is limited to the surface of the soft tissues and its action is essentially confined to the surface of the soft

tissues.<sup>20</sup> High power lasers such as CO<sub>2</sub> lasers, Erbium family lasers, Nd:YAG lasers, and diode lasers are the most commonly used lasers in oral surgery. When compared to a conventional scalpel, laser offers numerous advantages such as less intraoperative bleeding, less swelling of the area, better coagulation and scarring, no need for suture, shorter surgical time, and less postoperative pain. In contrast, diode laser caused more tissue damage than conventional scalpel and the cost required is also higher.<sup>19</sup>

In this case report, we opted mucocele excision using electrocautery. Electrocautery is a high precision instrument that has some advantages over a scalpel.<sup>19</sup> When the device is properly set, the electrode cuts on both sides and the tip are easily made. Although electrocautery improves hemostasis, the mechanisms involved differ from those of laser. Despite the thermal damage it causes, it improves hemostasis by sealing blood vessels prior to cutting. A monopolar electrical current heat up a metal probe, which is then applied to the tissue, promoting coagulation and cutting. Because no heat can reach deeper tissues, electrocautery is better suited for destroying superficial tissue layers. Despite being less precise than laser cutting, electrocautery is not only faster and less expensive, but it also provides better hemostasis.<sup>21</sup> A case report conduct by Gautam *et al* on excision using electrocautery indicate that the electrode cuts on both sides and the tip, cuts are made easily when the device is set correctly, hemostasis is immediate and consistent, the wound is nearly painless, and the tip is self-infecting.<sup>11</sup> On this consideration we prefer mucocele excision using electrocautery.

The elimination of factors that cause decrease or their transformation into harmless habits is the foundation for treating bad habits.<sup>22</sup> After complete excision it is important to give post operative instruction to eliminate lip biting habit. Furthermore, awareness education for children and parents is required to break the habit of lip-biting. If the practice continues as a result of a child's anxiety, it is essential to learn more about the etiology of the addiction and consult with a professional psychologist.

## Conclusions

Mucocele are mostly benign and self-limiting nature, primarily diagnosed based on

clinical findings followed by definitive diagnosis based on histopathological result. Minimum discomfort is the most important aspect when treating young children. Electrocautery can be the treatment of choice for mucocele as it can alleviate the patient's anxiety and discomfort. It results in minimal bleeding and tissue damage.

### Declaration of Interest

The authors report no conflict of interest.

### References

1. Parkavi A, Baburaj MD. Oral mucocele: a case report. *International Journal of Applied Dental Sciences*. 2018; 4(4):332-335.
2. Kumar SA, Ramakrishnan M. Mucocele in lower lip as a result of improper use of feeding bottle: a case report. *Case Report in Dentistry*. 2013;2013(1):1-3.
3. Aulakh AK, Brar RS, Azad A, Sharma S, Anand A, Jyoti B. Cryotherapy for treatment of mouth mucocele. *Nigerian Journal of Surgery*. 2016;22(2):130-133.
4. Nallasivam KU, Sudha BR. Oral Mucocele : Review of literature and a case report. *Journal of Pharmacy and Bioallied Sciences*. 2015;7(2):731-733.
5. Saskia T, Kartono AF, Rifki A, Fitriani Y, Kurnia PA. Oral mucocel and its surgical approach as treatment: case series. *Acta Medica Philippina*. 2021;55(8):816-822.
6. Ata-Ali J, Carrillo C, Bonet C, Balaguer J, Peñarrocha Diago M, Peñarrocha M. Oral mucocele: review of the literature. *J Clin Exp Dent*. 2010;2(1):18-21.
7. Wu CW, Kao YH, Chen CM, Hsu HJ, Chen CM, Huang IY. Mucoceles of the oral cavity in pediatric patients. *The Kaohsiung Journal of Medical Sciences*. 2011;27(7):276-279.
8. Sinha R, Sarkar S, Khaitan T, Kabiraj A, Maji A. Nonsurgical management of oral mucocele by intralesional corticosteroid therapy. *Int J Dent*. 2016;2016(1):1-5.
9. Mortazavi H, Baharvand M, Alirezaei S, Noor-Mohammadi R. Combination therapy in a large lower lip mucocele: a non-invasive recommended technique. *Dental hypotheses*. 2014;5(3):127-129.
10. Katta, N, KM S, Arekal S. Two different methods of oral mucocele management in pediatric patients: a case report. *Journal of Dentistry Indonesia*. 2018;25(2):121-124.
11. Gautam Y, Srivastava M. Mucocele in paediatric patients: a case series with review. *Int J Appl Dent Sci*. 2018;4(2):100-3.
12. Amhta R, Gunardi I, Cheong SC, Zain RB. Oral mucosal lesion detection accuracy post lectures and test in clinical dental students. *J Int Dent Med Res*. 2018;9(1):101-106.
13. Chaitanya P, Praveen D, Reddy M. Mucocele on lower lip: a case series. *Indian Dermatol Online Journal*. 2017; 8(3):205-207.
14. Biswal BN, Das SN, Das BK, Rath R. Alteration of cellular metabolism in cancer cells and its therapeutic prospect. *J Oral Maxillofac Pathol*. 2017;21(2):244-251.
15. Gartika M. The effect of oral habits in the oral cavity of children and its treatment. *Padjadjaran J Dent*. 2008;20(2):123-9.
16. Chi AC, Lambert PR 3rd, Richardson MS, Neville BW. Oral mucoceles: a clinicopathologic review of 1,824 cases, including unusual variants. *J Oral Maxillofac Surg*. 2011;69(4):1086-93.
17. Abe A, Kurita K, Hayashi H, Minagawa M. Multiple mucocele of the lower lip: a case report. *Clin Case Report*. 2019;7(7):1388-1390.
18. Foroughiasl P. Cautery versus laser excision of oral mucocele. *J Pediatric Surgery Case Report*. 2019;47(1):1-3.
19. Ortega-Concepcion D, Cano Duran JA, Pena-Cardeles, JF, Paredes Rodriguez VM, Gonzalez-Serrano J, Lopez-Quiles J. The application of diode laser in the treatment of oral soft tissue lesions. a literature review. *Journal of Clinical and Experimental Dentistry*. 2017;9(7): 925-928.
20. Yagüe-García J, España-Tost AJ, Berini-Aytés L, Gay-Escoda Cosme. Treatment of oral mucocele - scalpel versus CO2 laser. *Med Oral Patol Cir Bucal*. 2009;14(9):469-74.
21. de Jesus AO, Matias MDP, de Arruda JAA, Aires AV, Gomes IP, Souza LN, et al. Diode laser surgery versus electrocautery in the treatment of inflammatory fibrous hyperplasia: a randomized double-blind clinical trial. *Clin Oral Investig*. 2020;24(12):4325-4334.
22. Bilgic F, Arslanoglu Z, Altan H, Yilmaz H, Sozer OA. The role of overflow filling to occur orthodontic bad habit: a rare case report. *J Int Dent Med Res*. 2016;9(1):86-88.

PEMERINTAH PROVINSI JAWA TIMUR  
RUMAH SAKIT UMUM HAJI  
Jl. Manyar Kertoadi - Telp. (031) 5924000 Surabaya


SURAT PERSETUJUAN TINDAKAN KHUSUS


KAKAK

Saya yang bertanda tangan di bawah ini, Suami / Istri / Ayah / Ibu / Anak \*) dari penderita atau penderita sendiri bernama [REDACTED] menerangkan bahwa setelah mengetahui tujuan dari tindakan khusus berupa PKKRI Mesele menyatakan tidak berkeberatan untuk dilakukan tindakan tersebut diatas setelah mendapat keterangan secukupnya tentang faedah dan juga akibat-akibatnya yang mungkin akan terjadi karenanya.

Surabaya, 21 Oktober 2021  
Yang memberi pernyataan,

Dokter RSU Haji

  
drg. Siti Nur Lestari, Sp.KGA  
SIP. 503/446/0183/IP.DGS/436.7.2/2021

  
[REDACTED]

\*) Coret yang tidak perlu

PEMERINTAH PROVINSI JAWA TIMUR  
RUMAH SAKIT UMUM HAJI  
Jl. Manyar Kertoadi - Telp. (031) 5924000 Surabaya


SURAT PERSETUJUAN TINDAKAN KHUSUS

Saya yang bertanda tangan di bawah ini, Suami / Istri / Ayah / Ibu / Anak \*) dari penderita atau penderita sendiri bernama [REDACTED] menerangkan bahwa setelah mengetahui tujuan dari tindakan khusus berupa PKKRI Mesele menyatakan tidak berkeberatan untuk dilakukan tindakan tersebut diatas setelah mendapat keterangan secukupnya tentang faedah dan juga akibat-akibatnya yang mungkin akan terjadi karenanya.

Surabaya, 18 Januari 2022  
Yang memberi pernyataan,

Dokter RSU Haji

  
drg. Siti Nur Lestari, Sp.KGA  
SIP. 503/446/0183/IP.DGS/436.7.2/2021

  
[REDACTED]

\*) Coret yang tidak perlu