

# Mucogingival surgery with SureDerm application for gingival recession treatment in periodontics clinic University of Airlangga in 2022

*by* Shafira Kurnia

---

**Submission date:** 09-Jan-2023 12:46PM (UTC+0800)

**Submission ID:** 1990028987

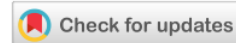**File name:** WJARR-2022-1145.pdf (853.15K)

**Word count:** 1918

**Character count:** 10879



(CASE REPORT)



## Mucogingival surgery with SureDerm application for gingival recession treatment in periodontics clinic University of Airlangga in 2022

Shafira Kurnia <sup>1,\*</sup>, Mulyati <sup>2</sup> and Lubna <sup>1</sup>

<sup>1</sup> Department of Periodontology, Faculty of Dentistry, Airlangga University, Surabaya, Indonesia.

<sup>2</sup> Faculty of Dentistry, Airlangga University, Surabaya, Indonesia.

World Journal of Advanced Research and Reviews, 2022, 16(02), 335–340

Publication history: Received on 29 September 2022; revised on 05 November 2022; accepted on 08 November 2022

Article DOI: <https://doi.org/10.30574/wjarr.2022.16.2.1145>

### Abstract

**Background:** Gingival recession has become a serious problem since it has a high prevalence among the 88% population of the world. Various mucogingival therapy becomes treatment of choice for gingival recession, such as sub epithelial connective tissue graft, coronally positioned flap, an acellular dermal matrix application. SureDerm as an acellular dermal matrix can be used for gingival recession treatment.

**Case:** A 22-year old male patient came to Periodontics Specialist Clinic in Dental Hospital Universitas Airlangga with the chief complaint of dental hypersensitivity on the left mandibular posterior molar teeth when stimulates with heat or cold sensation.

**Methods and Treatment Results:** Coronally Advanced Flap with Tunnelling technique was conducted using a scalpel and, TKN (Tunnelling Knife), with the additional use of acellular dermal matrix (Surederm). The success of this treatment depends on the technique and procedure used in this treatment, and is measured by the absence of further complaints and the correction of gingival recession.

**Conclusion:** Coronally Advanced Flap management is related with pre-evaluation before surgical procedure and the basic of surgical procedure that is being used.

**Keywords:** Gingival recession; Mucogingival Surgery; SureDerm; Acellular dermal matrix; Alograft; Membrane.

### 1. Introduction

Gingival recession is a clinical condition in which the gingival margin migrates apically due to a pathological process causing the tooth roots to open<sup>1</sup>. The treatment of gingival recession can be divided into 2 (two), namely surgical and non-surgical therapy<sup>3, 4, 5, 6</sup>. Surgical treatment of gingival recession is promising, but the success rate varies, ranging from 29-90% (long-term retrospective study)<sup>7</sup>. Surederm is one of the acellular dermal matrices that is often used for gingival augmentation. However, until now, especially in the Dental Hospital Universitas Airlangga, there has been no research on how effectively this material can be used to treat gingival recession.

### 2. Case Report

A 22-year-old male patient visited Periodontics Specialist Clinic in Dental Hospital Universitas Airlangga to have tartar removed and his left lower back tooth evaluated, which frequently suffers when exposed to cold or hot food stimuli. A

\*Corresponding author: Shafira Kurnia

Department of Periodontology, Faculty of Dentistry, Airlangga University, Surabaya, Indonesia.

month earlier, the patient also had his tartar removed with scaling procedure. The patient denied having a history of systemic illnesses (such diabetes and hypertension) or drug and food sensitivities, nor did they smoke or had a bruxism while they slept. Clinical examination performed outside the mouth did not find any anomalies. Upon intra-oral clinical examination, the patient exhibited BOP (+) in the posterior portion of the maxillary and mandibular teeth and plaque over the entire maxillary and mandibular region.

Clinical examination using a periodontal probe revealed gingival recession in the area of tooth 34 with a length of 2 mm and a thin gingival phenotype. The probing depth is around 2 mm, while the gingiva has a keratinization width of about 4 mm. There were no abnormalities in the periodontal tissues, according to a radiographic examination. Based on clinical and radiographic examination, the clinical diagnosis was Gingival Health on reduced periodontium non-periodontal patient. A phase I procedure using Dental Health Education (DHE) and scaling and root planing was performed based on the clinical findings. Then, an evaluation was conducted before moving on to a phase II procedure using mucogingival surgery and a coronally advanced flap in the tooth area 34 with tunnelling method. The entire procedure of treatment is informed to the patient before the action is carried out, and the patient gives their consent to the treatment plan that will be followed.

### 3. Case Management

Phase I treatment was carried out by scaling and root planing, and dental health education was carried out to the patient in order to always maintain a good oral hygiene. After evaluation, a phase II procedure in the form of a coronally advance flap was performed.

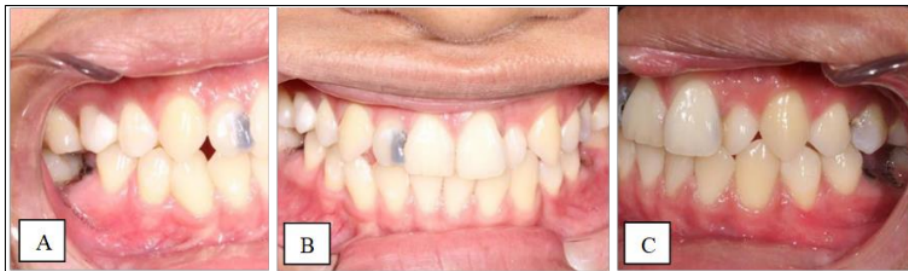

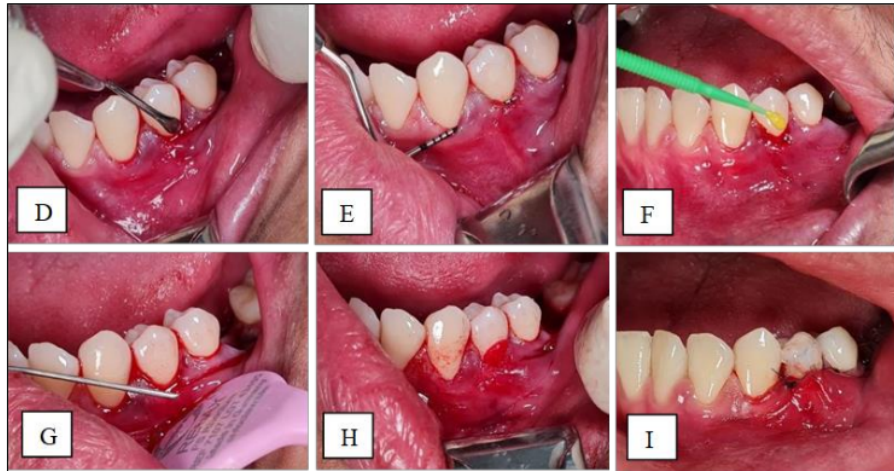
Figure 1 Pre-operative clinical photograph (A) Right lateral view, (B) Frontal view, (C) Left lateral view

The patient was first given asepsis with povidone iodine before having a local anesthetic infiltrated with Septocaine on the mucobuccal fold of teeth 34 and 35. A sterile surgical draping is used to cover the patient and surrounding areas to maintain a sterile field during the surgery. A surcular incision was carried out with a 15c blade, on the facial side of teeth 33, 34, and 35 without involving any interdental tissue.

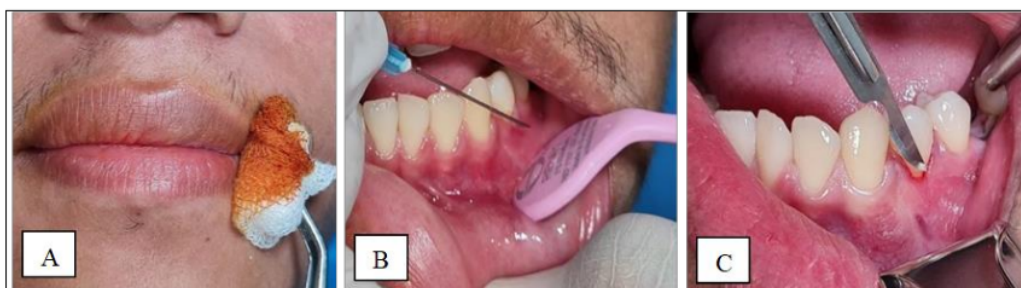

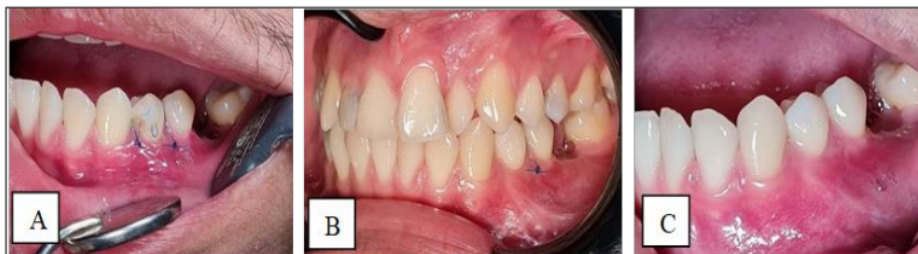Figure 2 Coronally Advanced Flap Procedure: (A) Extra oral asepsis, (B) Infiltration local anesthesia on teeth 34 and 35, (C) Surcular incision

Following the sulcular incision, a TKN knife was used to separate the connective tissue and periosteum in regions 33, 34, and 35 in order to gain access to the tunnel. After the tissue has been divided, a probe is used to verify tunneling access. The following step involved tetracycline application as a biomodification of the tooth roots, followed by saline irrigation. On the buccal portion of tooth 34, the Surederm membrane was then applied and sutured using the coronally positioned suture technique, and fixed horizontally using a composite (composite button).



**Figure 3** Coronally Advanced Flap Procedure: (D) Tunneling Flap using TKN Knife (E) Tunneling access examination (F) Tetracycline application (G) Saline irrigation, (H) Surederm application, (I) Suturing

The patient was given analgesic mefenamic acid 500 mg twice daily for three days, as well as betadine mouthwash twice daily after brushing his teeth. Patients were advised to practice good dental hygiene at all times and to stay away from spicy and acidic foods. The patient was then evaluated for 1 week and 2 weeks.



**Figure 4** Control Post Coronally Advanced Flap: (A) One week post-operative (B) Two weeks post-operative, removal of sutures (C) Five weeks post-operative

#### 4. Discussion

17  
With the addition of acellular dermal matrix, the healing phase of gingival recession can be explained as follows: On days 0-3, the plasmic circulation phase takes place, during which fibrin threads start to develop between the acellular dermal matrix and the gingiva as a result of the suturing procedure. The gingiva appears reddish and edematous at this time, and the patient may also experience subjective problems. At this time, an inflammatory process also takes place, causing a diffusion and osmosis process from the acellular dermal matrix and the gingiva. Revascularization takes place on days 4 through 9, and inflammation symptoms including redness, edema, and discomfort start to subside. The acellular dermal matrix will adhere to the gingiva on days 10 to 14 and epithelial proliferation will occur. New epithelium and bone will be formed as a result of this epithelial proliferation. The maturation phase, which includes the development of epithelial cells and keratinization, will also begin on day 14 and takes place gradually until day 428,9.



Surederm serves as a scaffold in the process of regeneration of periodontal tissue. It contains a lot of collagen, especially type I and type III collagen which is needed in the process of regeneration of periodontal tissue<sup>10</sup>. When managing cases of root covering or other periodontal surgery, mucoderm is frequently employed.

The pictures taken after surgery showed a significant result compared to the pictures taken before the surgery. There is no recession following the treatment, and the gingiva seems thicker. Additionally, the patient no longer experiences subjective symptoms, such as the discomfort experienced frequently after drinking cold beverages. Periodontal tissue can heal and regenerate with the help of good oral hygiene and the absence of underlying illnesses.

Tooth malposition causes the gingival region around the malpositioned tooth to be thinner than the gingiva in general, allowing the gingiva to rupture easily<sup>11</sup>. Rotational teeth exhibited an instance of recession, according to Pai et al. (2013). Pai et al., performed surgical therapy with a semilunar flap technique on 2 (two) rotating dental elements. The attached gingiva must be wide and thick enough to reposition the flap in place, provide adequate vascularity, and minimal occlusal contact in order for treatment of recession in a rotated tooth to be successful<sup>12</sup>. Collagen and fibroblasts are crucial for the regeneration and repair of the gingiva.

Surederm is an ideal material for tissue augmentation material because of its great predictability and outstanding biocompatibility with host tissues<sup>14</sup>. Gingival recession can also be successfully treated with non-invasive mucogingival surgical therapy because the healing and regeneration processes are improved when there is less tissue damage and intervention on the tissue<sup>8</sup>. The combination of Surederm and minimally invasive mucogingival surgical procedure provides effective results for the management of gingival recession.

---

## 5. Conclusion

Based on this report, surgical mucogingival therapy with the addition of mucoderm is effective for the treatment of gingival recession.

---

## Compliance with ethical standards

### Acknowledgments

The author thanks the reviewer for their insightful suggestions.

### Disclosure of conflict of interest

No conflict of interest.

### Statement of informed consent

Informed consent was obtained from all individual participants included in the study.

---

## References

- [1] Marini MG, Greggi SLA, Passanezi E, Sant'ana ACP, 2004, Gingival Recession: Prevalence, Extension and Severity in Adults, Journal of Applied Oral Science 12(3).
- [2] Pradeep K, Rajababu P, Satyanarayana D, Sagar V, 2012, Gingival Recession: Review and Strategies in Treatment of Recession, Case Reports in Dentistry, Hindawi.
- [3] Allen R, 2011, Treating Gingival Recession, Irish dental Journal.
- [4] Jawale MR, Chaurasia RKR, Chaurasia VR, Masamatti VS, Sharma AM, 2014 Gingival Epithesis : An Esthetic Solution in Periodontally Compromised Patients, International Journal of Applied Dental Sciences 1(1).
- [5] Krismariono A, 2014 Prinsip Dasar Perawatan Resesi Gingiva (Basic Principle in the Treatment of Gingival Recession), Dentika Dental Journal 18(1).
- [6] Ulfah N, Augustina EF, 2010, Perawatan Resesi Gingiva dengan Bedah dan Non-Bedah, Dentofasial 9(1).
- [7] Chao JC, 2012 A Novel Approach to Root Coverage: The Pinhole Surgical Technique, The International Journal of Periodontics & Restorative Dentistry, 32(5)

- [8] Flanagan M., 2000 The Physiology of Wound Healing, Journal of Wound Care.
- [9] Rosmelita D., Nurul D., 2003, Perawatan Resesi Giniva dengan Bedah Plastik Periodontal Teknik Langer Jurnal Kedokteran Gigi Universitas Indonesia, 10(2003)
- [10] Taylor JB., Taylor JB., Gerlach RC., Herold RW., Bisch FC., Dixon DR., 2010, A Modified Tensionless Gingival Grafting Technique Using Acellular Dermal Matrix, The International Journal of Periodontics & Restorative Dentistry 30(5).
- [11] Newman, M.G., Takei, H.H., Klokkevold, P.R., & Carranza, F.A., 2006, Carranza's Clinical Periodontology, 10th ed., Mosby Elsevier, St. Louis.
- [12] Pai BSJ., Rajan SA., Padma R., Suragimath G., Annaji S., Kamath KV., 2013, Modified Semilunar Coronally Advanced Flap : A Case Series, Journal of Indian Society of Periodontology 17(1).
- [13] Foster TD., 2002, Buku Ajar Orthodonsi, Penerbit Buku Kedokteran: EGC.
- [14] Joly JC, Carvalho AM, da Silva RC, Ciotti DL, Cury PR. Root coverage in isolated gingival recessions using autograft versus allograft: a pilot study. Journal of periodontology. 2007 Jun;78(6):1017-22.

# Mucogingival surgery with SureDerm application for gingival recession treatment in periodontics clinic University of Airlangga in 2022

## ORIGINALITY REPORT

15%

SIMILARITY INDEX

11%

INTERNET SOURCES

12%

PUBLICATIONS

0%

STUDENT PAPERS

## PRIMARY SOURCES

1	Vivian W. Y Ng, Vincent Y. T Cheung. "Successful Control of Heavy Menstrual Bleeding Using High-Intensity Focused Ultrasound Ablation of Fibroid Uterus in a Woman With Eisenmenger Syndrome", <i>Cureus</i> , 2022 Publication	1%
2	<a href="https://scopedatabase.com">scopedatabase.com</a> Internet Source	1%
3	<a href="http://www.apsperio.org">www.apsperio.org</a> Internet Source	1%
4	<a href="http://digilib.unhas.ac.id">digilib.unhas.ac.id</a> Internet Source	1%
5	<a href="http://innspub.net">innspub.net</a> Internet Source	1%
6	<a href="http://hqlo.biomedcentral.com">hqlo.biomedcentral.com</a> Internet Source	1%

7	Alexandrina L. Dumitrescu. "Guided Tissue Regeneration Barriers", Chemicals in Surgical Periodontal Therapy, 2011 Publication	1 %
8	Thomas J. Balshi, Glenn J. Wolfinger, Robert Pellecchia, William Reiger et al. "9 - year follow up on maxillofacial implant - supported framework designed to accommodate childhood growth", Journal of Prosthodontics, 2022 Publication	1 %
9	<a href="http://jurnal.unissula.ac.id">jurnal.unissula.ac.id</a> Internet Source	1 %
10	<a href="http://japid.tbzmed.ac.ir">japid.tbzmed.ac.ir</a> Internet Source	1 %
11	<a href="http://www.ncbi.nlm.nih.gov">www.ncbi.nlm.nih.gov</a> Internet Source	1 %
12	G. Zucchelli, I. Mounssif, M. Stefanini, M. Mele, L. Montebugnoli, N.M. Sforza. "Hand and Ultrasonic Instrumentation in Combination With Root-Coverage Surgery: A Comparative Controlled Randomized Clinical Trial", Journal of Periodontology, 2009 Publication	1 %
13	"Poster abstracts", Journal Of Clinical Periodontology, 06/2009 Publication	<1 %



14 Arthur Belém Novaes, Daniela Bazan Palioto. "Experimental and clinical studies on plastic periodontal procedures", Periodontology 2000, 2019  
Publication <1 %

---

15 [benthamscience.com](http://benthamscience.com)  
Internet Source <1 %

---

16 [ir.library.louisville.edu](http://ir.library.louisville.edu)  
Internet Source <1 %

---

17 [synapse.koreamed.org](http://synapse.koreamed.org)  
Internet Source <1 %

---

18 [www.its-jds.in](http://www.its-jds.in)  
Internet Source <1 %

---

19 [www.science.gov](http://www.science.gov)  
Internet Source <1 %

---

20 [www.scilit.net](http://www.scilit.net)  
Internet Source <1 %

---

21 Sean K. Vreeburg, Garth R. Griffiths, Jeffrey A. Rossmann. "A Comparative Study of Root Coverage using OrACELL™ Versus Subepithelial Connective Tissue Graft: A Randomized Controlled Trial", The Open Dentistry Journal, 2018  
Publication <1 %

---

22 Pierpaolo Cortellini. "Coronally advanced flap and combination therapy for root coverage." <1 %

# Clinical strategies based on scientific evidence and clinical experience : Coronally advanced flap and combination therapy for root coverage", Periodontology 2000, 06/2012

Publication

---

---

Exclude quotes      Off

Exclude matches      Off

Exclude bibliography      On

# Mucogingival surgery with SureDerm application for gingival recession treatment in periodontics clinic University of Airlangga in 2022

---

## GRADEMARK REPORT

---

FINAL GRADE

**/0**

GENERAL COMMENTS

**Instructor**

---

PAGE 1

---

PAGE 2

---

PAGE 3

---

PAGE 4

---

PAGE 5

---