



[Submit your article](#) ↗

[Guide for authors](#) ↗

☰ Menu

🔍 Search in this journal

## Volume 72

Pages 1-650 (2020)

[< Previous vol/issue](#)

[Next vol/issue >](#)

Receive an update when the latest issues in this journal are published

 [Sign in to set up alerts](#)

● [Open access](#)

Editorial Board

Page i

[Download PDF](#)

Case report ● [Open access](#)

Primary hepatic neuroendocrine tumor: A case report and literature review

Adriano C. Costa, Fernando Santa-Cruz, Henrique Guimarães, Alexandre R. Paz, ... Álvaro A.B. Ferraz

Pages 1-4

[Download PDF](#) [Article preview](#) ▾

Case report ● [Open access](#)

Bowel perforation after liposuction in abdominal contouring surgery: Case report

Caterina Gardener, Laura Pandis, Martina Grigatti, Vincenzo Vindigni, ... Tito Brambullo

Pages 5-9

[Download PDF](#) [Article preview](#) ▾

Case report ● [Open access](#)

Characteristic radiological findings indicating the possible involvement of the hepatic hilar lymph nodes in patients with colorectal liver metastasis:

Case report

Yota Kawasaki, Satoshi Iino, Tetsuya Idichi, Shinichi Ueno, Shoji Natsugoe

Pages 10-16

[Download PDF](#) [Article preview](#) ▾

Case report ● [Open access](#)

Secondary aorto-duodenal fistula successfully treated with a novel surgical method: A case report

Takao Tsuneki, Yasuhiro Yuasa, Mizuki Fukuta, Hidenori Maki, ... Takashi Otani

Pages 17-21

[Download PDF](#) [Article preview](#) ▾

Case report ● [Open access](#)

### Photographic smile tracking: Evidence of asymmetric crying faces over time improvement: Case report

Maamouri Sabrine, Marouen Ben Rejeb, Karima Zitouni, Issam Zairi  
Pages 22-26

[Download PDF](#) Article preview 

Case report ● [Open access](#)

### Correction of a postpneumonectomy syndrome with congenital pectus excavatum using Ravitch's procedure and silicone breast implants. Report of a case

Weam Essaleh, Franz Stanzel, Stefan Welter  
Pages 27-31

[Download PDF](#) Article preview 

Case report ● [Open access](#)

### Combined cardiac anomalies in Noonan syndrome: A case report

Natraj Setty H.S., Shankar S., Rahul Patil, Santosh Jadhav, ... C.N. Manjunath  
Pages 32-36

[Download PDF](#) Article preview 

Case report ● [Open access](#)

### Secondary cervical elongatio due to large Gartner cyst: A rare case

Surahman Hakim, Yulia Margareta Sari, Achmad Kemal Harzif  
Pages 37-40

[Download PDF](#) Article preview 

Case report ● [Open access](#)

### Rectal foreign body of a shattered glass bottle; Case report of unexpected late post-operative hemorrhage managed transanally

Elliot Klein, Moshe Bressler, Shmuel Nadler, Michelle Shayowitz, Seth Lapin  
Pages 41-44

[Download PDF](#) Article preview 

Short communication ● [Open access](#)

### Clinical outcome in Giant cell tumor of cervico-thoracic spine: Our experience with three cases

Jagdeep Singh, Raj Bahadur, Sorabh Garg, Karan Rajpal, Karan Chopra  
Pages 45-51

[Download PDF](#) Article preview 

Case report ● [Open access](#)

### Ileo-ileal intussusception caused by small bowel leiomyosarcoma: A rare case report

Erica Mazzotta, Sara Lauricella, Filippo Carannante, Gianluca Mascianà, ... Gabriella T. Capolupo  
Pages 52-55

[Download PDF](#) Article preview 

Case report ● [Open access](#)

### Malignant adenomyoepithelioma of the breast: A case report

Eisa A. Lari, Ali A. Lari, Talal Alsaeed  
Pages 56-58

[Download PDF](#) Article preview 

Case report ● [Open access](#)

### Lower gastrointestinal bleeding due to colonic fistula caused by a gossypiboma: Case report and literature review

María José Gómez-Jurado, Anna Curell, Rocío Martín, Amador García Ruiz de Gordejuela, Manel Armengol  
Pages 59-62

[Download PDF](#) Article preview 

Case report ● [Open access](#)

### A clinically silent tumour of adrenal myelolipoma: A case report

Nornazirah Azizan, Ohnmar Myint, Aye Aye Wynn, Tin Tin Thein, ... Nik Amin Sahid Nik Lah  
Pages 63-65

[Download PDF](#) Article preview 

Case report ● [Open access](#)

### Ectopic adrenal gland in an adult inguinal hernial sac: A case report

Mersad Alimoradi, Etienne El-Helou, Hassan Sabra, Rawan Azaki, ... Nazem Matta  
Pages 66-68

[Download PDF](#) Article preview 

Case report ● [Open access](#)

### Hepatectomy and intrahepatic hepaticocutaneous jejunostomy for bilateral primary hepatolithiasis: Case report

André Luís Conde Watanabe, Alexandre Coutinho Teixeira de Freitas, Lucinei Stadnik, Júlio Cezar Uili Coelho  
Pages 69-71

[Download PDF](#) Article preview 

Case report ● [Open access](#)

### Salvage multivisceral abdominal surgery after caustic ingestion: Case report

Cristina Maggioni, Luca Voltolini, Stefano Bongiolatti, Fabio Cianchi, Francesco Coratti  
Pages 72-74

[Download PDF](#) Article preview 

Case report ● [Open access](#)

### The surprise pathology—Primary squamous cell carcinoma of the colon—A case report

Aysha Hassan Ali Husain, Kiran B. Kaundinya, Faizal Hammed, Abdul Rahim Al Sayed  
Pages 75-78

[Download PDF](#) Article preview 

Case report ● [Open access](#)

### Usefulness of laparoscopy in the management of incidentally discovered retroperitoneal liposarcoma mimicking inguinal hernia: A case report and literature review

Takashi Matsumoto, Kosuke Mima, Asuka Ono, Nobutomo Miyanari, ... Hideo Baba  
Pages 79-84

[Download PDF](#) Article preview 

Case report ● [Open access](#)

### Localized asymptomatic cerebellar abscess after penetrating brain injury by wooden foreign object with adequate antibiotics administration: A case report

Quri Meihaerani Savitri, Corinne Prawira Putri, Kevin Jonathan Gunawan, Dini Lukita Hapsari, ... Pandu Wicaksono  
Pages 85-90

[Download PDF](#) Article preview 

Case report ● [Open access](#)

### Well-differentiated liposarcoma disguised as a recurrent lipoma of the forearm flexor compartment: A case report

Wahyu Widodo, Wildan Latief, Dina Aprilya  
Pages 91-95

[Download PDF](#) Article preview 

Case report ● [Open access](#)

Pilonidal sinus of the perianal region: Difficult to diagnose

Ozlem Zeliha Sert  
Pages 96-98

[Download PDF](#) [Article preview](#) 

Case report  [Open access](#)

Efficacy of panniculectomy-combined surgery in superobese patients with endometrial cancer: A case report and literature review

Masayo Okawa, Hiroaki Komatsu, Daiken Osaku, Mayumi Sawada, ... Tasuku Harada  
Pages 99-103

[Download PDF](#) [Article preview](#) 

Case report  [Open access](#)

Superior vena cava replacement combined with venovenous shunt for thymic carcinoma

Soichi Oka, Kenji Ono, Yoshio Arai, Kenta Kajiyama, ... Takehiko Manabe  
Pages 104-107

[Download PDF](#) [Article preview](#) 

Case report  [Open access](#)

Perforated sigmoid colon cancer presenting as an incarcerated inguinal hernia: A case report

Hassan Sabra, Mersad Alimoradi, Etienne El-Helou, Rawan Azaki, ... Tony Kfoury  
Pages 108-111

[Download PDF](#) [Article preview](#) 

Case report  [Open access](#)

Mucus-filled lesion of a distal viable remnant tip of an appendix that developed 23 years after appendectomy

Hidenori Tomida, Shinichi Hashimoto, Masahiro Hayashi, Masamichi Koyama  
Pages 112-116

[Download PDF](#) [Article preview](#) 

Case report  [Open access](#)

Complete pathological response of high grade appendicular neoplasm induced Pseudomyxoma Peritonei (PMP) after neoadjuvant intra-peritoneal chemotherapy: A case report

Naveen Padmanabhan, Haruaki Ishibashi, Kazurou Nishihara, Shouzou Sako, ... Yutaka Yonemura  
Pages 117-121

[Download PDF](#) [Article preview](#) 

Case report  [Open access](#)

Open abdomen management for massive intestinal infarction due to acute splanchnic venous thrombosis in a patient with protein S deficiency. A case report

Annamaria Di Bella, Alessandro Bruscano, Giovanni Alemanno, Carlo Bergamini, Paolo Prospero  
Pages 122-126

[Download PDF](#) [Article preview](#) 

Case report  [Open access](#)

A pathological complete response after neoadjuvant triplet chemotherapy for locally advanced transverse colon cancer

Tetsuro Tominaga, Takashi Nonaka, Kazuhiro Tabata, Terumitsu Sawai, Takeshi Nagayasu  
Pages 127-132

[Download PDF](#) [Article preview](#) 

Case report  [Open access](#)

Hypnosis and superficial cervical anesthesia for total thyroidectomy in a high-risk patient – A case report

P. Makovac, A. Potié, A. Roukain, L. Pucci, ... M. Matter  
Pages 133-136

[Download PDF](#) Article preview 

Case report ● [Open access](#)

### Full-endoscopic transpedicular discectomy (FETD) for lumbar herniations: Case report and review of the literature

Enrico Giordan, Jacopo Del Verme, Flaminia Coluzzi, Giuseppe Canova, Domenico Billeci  
Pages 137-141

[Download PDF](#) Article preview 

Case report ● [Open access](#)

### Infected intradural dermoid cyst without dermal sinus tract mimicking brain abscess: A case report

Anh Hoang Pham, Tam Duc Le, Hung Thanh Chu, Tuan Anh Le, ... He Van Dong  
Pages 142-146

[Download PDF](#) Article preview 

Short communication ● [Open access](#)

### Recto-vaginal fistulas: A case series

Imad Ziouziou, Safaa Ammouri, Mohammed Ouazni, Harrison Sumba, ... Ahmed Iben Attya Andaloussi  
Pages 147-152

[Download PDF](#) Article preview 

Case report ● [Open access](#)

### Graft preservation with multi-stage surgical repair of an aortoesophageal fistula after thoracic endovascular aortic repair – A case report

Matthias Buerger, Jan Paul Frese, Sebastian Kapahnke, Andreas Greiner  
Pages 153-155

[Download PDF](#) Article preview 

Case report ● [Open access](#)

### A case in which laparoscopic right salpingo-oophorectomy was performed in a patient with a lumboperitoneal shunt

Mio Nakagawa, Tomomi Egawa-Takata, Yuri Kamino, Ayuko Otoshi, ... Yukihiro Nishio  
Pages 156-159

[Download PDF](#) Article preview 

Case report ● [Open access](#)

### Minimally invasive surgical repair of accessory mitral valve tissue: A case report

Dinh Nguyen, Anh Vo, Chuong Pham, Trang Nguyen, ... Bac Nguyen  
Pages 160-162

[Download PDF](#) Article preview 

Case report ● [Open access](#)

### Endovascular repair of infected carotid pseudoaneurysm: A case report

Mohsen Bannazadeh, Ali Reza Sattari, Edvard Skripochnik, Gergios Tzavellas, Apostolos Tassiopoulos  
Pages 163-165

[Download PDF](#) Article preview 

Case report ● [Open access](#)

### Super-late pulmonary recurrence after radical esophagectomy for esophageal squamous cell carcinoma

Akira Umemura, Yuji Akiyama, Takeshi Iwaya, Keisuke Koeda, ... Akira Sasaki  
Pages 166-171

[Download PDF](#) Article preview 

Case report ● [Open access](#)

### Post-thyroidectomy tracheocutaneous fistula; A case report with literature review

Abdulwahid M. Salih, Fahmi H. Kakamad, Imad J. Habibullah, Karzan Mohammed, ... Dahat A. Hussein

Pages 172-174

[Download PDF](#) [Article preview](#) 

Case report  [Open access](#)

### Hartmann pouch herniation in Calot's triangle: A case report

Tariq Alrnaizel, Tawfiq Alnawafleh, Ra'ed Al-Jarrah, Abdulhamid M. Al-Abadi, ... Eman A. Al-Oudat

Pages 175-177

[Download PDF](#) [Article preview](#) 

Case report  [Open access](#)

### Differential diagnosis and laparoscopic resection of an adrenal pseudocyst: A case report

Yuichiro Yokoyama, Yusuke Tajima, Izuru Matsuda, Kentaro Kamada, ... Masahiro Ishimaru

Pages 178-182

[Download PDF](#) [Article preview](#) 

Case report  [Open access](#)

### A diagnostic dilemma: Pedunculated mesenteric lipodystrophy mimicking Meckel's diverticulum. A case report and literature review

Alessandra Mirabile, Marco Moschetta, Nicola Lucarelli, Michele Telegrafo, ... Amato Antonio Stabile Ianora

Pages 183-187

[Download PDF](#) [Article preview](#) 

Case report  [Open access](#)

### Reconstruction of osteosarcoma of the proximal tibia using bone on polyethylene hemiarthroplasty knee joint system: A case report

Yogi Prabowo, Muhammad Rizqi Adhi Primaputra, Evelina Kodrat

Pages 188-196

[Download PDF](#) [Article preview](#) 

Case report  [Open access](#)

### The importance of wearing a seatbelt correctly – A case report of blunt trauma causing complete shearing transection of the gastroduodenal junction

Matheesha Herath, Peter Bautz, Dominic Parker, Christopher Dobbins

Pages 197-201

[Download PDF](#) [Article preview](#) 

Case report  [Open access](#)

### Blue rubber bleb nevus syndrome in a Malay girl: A case report and literature review

Fatimah Mat Johar, Wan Azman Wan Sulaiman, Arman Zaharil Mat Saad, Normala Basiron, Nik Amin Sahid

Pages 202-206

[Download PDF](#) [Article preview](#) 

Case report  [Open access](#)

### Case report: Evisceration of abdomen after blunt trauma

Arwa H. Ibrahim, Adel J. Osman, Mosab A. Alarfaj, Areej M. Alzamil, ... Hanan Alghamdi

Pages 207-211

[Download PDF](#) [Article preview](#) 

Case report  [Open access](#)

### Mimicry of surgical site infection – Case report

H. Bretschneider, S. Helbig, C. Kleber, K. de With, M. Stiehler

Pages 212-214

[Download PDF](#) [Article preview](#) 

Case report  [Open access](#)

### Case of inflammatory granuloma in inguinal hernia sac after hysterosalpingography with oily contrast medium

Yoshiko Miyazaki, Tetsu Yamamoto, Ryoji Hyakudomi, Takahito Taniura, ... Yoshitsugu Tajima  
Pages 215-218

[Download PDF](#) [Article preview](#) 

Case report  [Open access](#)

### Hepatic subcapsular hematoma post-ERCP: Case report and literature review

Luca Giovanni Antonio Pivetta, Caroline Petersen da Costa Ferreira, João Paulo Venancio de Carvalho, Renata Yumi Lima Konichi, ... Mauricio Alves Ribeiro  
Pages 219-228

[Download PDF](#) [Article preview](#) 

Short communication  [Open access](#)

### Stereotactic aspiration of spontaneous intracerebral hematoma: Case series

Achmad Fahmi, Heri Subianto, Nur Setiawan Suroto, Budi Utomo, ... Abdul Hafid Bajamal  
Pages 229-232

[Download PDF](#) [Article preview](#) 

Case report  [Open access](#)

### A large sublingual epidermoid cyst with parapharyngeal space extension: A case report

Hanpon Klibngern, Chanisa Pornchaisakuldee  
Pages 233-236

[Download PDF](#) [Article preview](#) 

Case report  [Open access](#)

### Traumatic diaphragmatic rupture successfully managed in 4-year-old patient: Case report and literature review

Adel Elkbuli, Evander Meneses, Aaron Shepherd, Mark McKenney, Dessy Boneva  
Pages 237-240

[Download PDF](#) [Article preview](#) 

Case report  [Open access](#)

### Anatomic reconstruction for major tissue loss following abdominoplasty: A case report

Vladislav Pavlovich Zhitny, Noama Iftekhar, Barry Zide, Frank Stile  
Pages 241-244

[Download PDF](#) [Article preview](#) 

Case report  [Open access](#)

### Posteriorly displaced salter halter fracture-dislocation at the sternoclavicular joint with associated thoracic outlet syndrome: A case report

Timothy McAleese, Mark Curtin, Denis Collins  
Pages 245-250

[Download PDF](#) [Article preview](#) 

Case report  [Open access](#)

### Esophageal atresia type C with overlapping long upper pouch: A rare variant

Samuel Negash, Hiwote Girma, Hanna Getachew Woldelesassie  
Pages 251-254

[Download PDF](#) [Article preview](#) 

Case report  [Open access](#)

### Adult axillary lymphangioma removal using indocyanine green fluorescence imaging system: A case report

Osamu Kubota, Takashi Uchiyama, Koichi Nakamura, Yoshiro Hayashi, ... Satoshi Baba  
Pages 255-259

[Download PDF](#) [Article preview](#) 

Case report  [Open access](#)

## Total knee arthroplasty for Ochronosis induced knee arthropathy. Case report

Mohamed Al Ateeq Al Dosari, Aissam Elmhiregh, Safa Abulhail, Elhadi Babikir, Shamsi Abdul Hameed  
Pages 260-265

[Download PDF](#) [Article preview](#) 

Case report  [Open access](#)

## Splenic metastases – hematogenous disease or invasive peritoneal implants? Case reports of two patients

Paul H. Sugarbaker, Ebony R. Hoskins  
Pages 266-270

[Download PDF](#) [Article preview](#) 

Case report  [Open access](#)

## Minimally invasive technique for the abscess drainage in lumbosacral tuberculosis using arthroscopy sheath: A case report

Singkat Dohar Apul Lumban Tobing, Dody Kurniawan  
Pages 271-276

[Download PDF](#) [Article preview](#) 

Case report  [Open access](#)

## Laparoscopic retrieval of sharp foreign body: An innovative approach

P.O. Igwe, N.E. Brownson, S.L. Harcourt, N. Ejindu  
Pages 277-280

[Download PDF](#) [Article preview](#) 

Case report  [Open access](#)

## Septic arthritis of the hip, an unreported complication of perforated appendicitis: A case report

Mahnour Zia, Nima Maghami  
Pages 281-284

[Download PDF](#) [Article preview](#) 

Case report  [Open access](#)

## Advantage of laparoscopic peritoneal toileting in acute peritonitis with unclear etiology: A case report with inspiring outcome (with video)

Md. Sumon Rahman, Hasan Ul Banna, Md. Nazmul Hasan, Mohammad Jumman  
Pages 285-289

[Download PDF](#) [Article preview](#) 

Case report  [Open access](#)

## Reconstruction of an anterior chest wall defect in a child using a latissimus dorsi muscle-thoraco-lumbar fascia composite flap – A case report

Mohammad M. Al-Qattan, Waseem M. Hajjar  
Pages 290-293

[Download PDF](#) [Article preview](#) 

Case report  [Open access](#)

## Zenker's diverticulum perforation due to transoesophageal echocardiography: Case report of the management of an extremely rare life-threatening iatrogenic complication

F.-X. Terry, P. Stangherlin, B. Mansvelt  
Pages 294-297

[Download PDF](#) [Article preview](#) 

Case report  [Open access](#)

## Laparoscopic total extraperitoneal (TEP) mesh repair for femoral hernia in a patient of child B liver cirrhosis with ascites. A case report

Aditya Kumar, Manjunath Maruti Pol  
Pages 298-300

[Download PDF](#) [Article preview](#) 



Case report [● Open access](#)

### Vertebroplasty with posterior spinal fusion for osteoporotic vertebral fracture using computer-assisted rod contouring system: A new minimally invasive technique

Haruki Funao, Norihiro Isogai, Yutaka Sasao, Makoto Nishiyama, Ken Ishii

Pages 301-305

[Download PDF](#) [Article preview](#) 

Case report [● Open access](#)

### Intrauterine device migration into the lumen of large bowel: A case report

Vygintas Aliukonis, Marius Lasinskas, Algirdas Pilvelis, Audrius Gradauskas

Pages 306-308

[Download PDF](#) [Article preview](#) 

Case report [● Open access](#)

### Reconstruction of severe burn contractures of the upper lip in males using a pedicled superficial temporal artery hair-bearing flap. Two case reports

Mohammad M. Al-Qattan, Musa H. AlMutairi

Pages 309-312

[Download PDF](#) [Article preview](#) 

Case report [● Open access](#)

### Bilateral congenital absence of the anterior cruciate ligament associated with bilateral knee and hip osteoarthritis: Case report

Kwang-kyoun Kim, Tae-hyeong Kim, Dae-young Kim, Jae-kyu Choi

Pages 313-317

[Download PDF](#) [Article preview](#) 

Case report [● Open access](#)

### Local recurrence of breast cancer caused by core needle biopsy: Case report and review of the literature

Kimiyasu Yoneyama, Motohito Nakagawa, Asuka Hara

Pages 318-321

[Download PDF](#) [Article preview](#) 

Case report [● Open access](#)

### Papillary thyroid carcinoma presenting as miliary nodules on chest roentgenogram in the paediatric setting: A case report

Nandi Viljoen, Marc Hendricks, Eugenio Panieri, Alessandro Pietro Aldera

Pages 322-325

[Download PDF](#) [Article preview](#) 

Case report [● Open access](#)

### Tuberculous peritonitis; The effectiveness of diagnostic laparoscopy and the perioperative infectious prevention: A case report

Leo Yamada, Motonobu Saito, Tetsuro Aita, AungKyitThar Min, ... Koji Kono

Pages 326-329

[Download PDF](#) [Article preview](#) 

Case report [● Open access](#)

### Radial artery-second dorsal metacarpal vein arteriovenous fistula in the first interdigital space for hemodialysis: Utilization of the most peripheral site and autologous vein in the upper limb – A case report

Tsuyoshi Takashima, Yui Nakashima, Atsuhiko Suenaga, Masato Mizuta, ... Yuji Ikeda

Pages 330-334

[Download PDF](#) [Article preview](#) 

Case report [● Open access](#)

### Subtotal laparoscopic cholecystectomy for gangrenous gallbladder during recovery from COVID-19 pneumonia

Andrea Lovece, Emanuele Asti, Barbara Bruni, Luigi Bonavina

Pages 335-338

[Download PDF](#) [Article preview](#) 

Case report  [Open access](#)

### Proteus Syndrome, a rare case with an unusual presentation: Case report

N. Amer, J. Al Helal, M. Al Hajji, A. Al Abduljabbar, ... A. Awadallah

Pages 339-342

[Download PDF](#) [Article preview](#) 

Case report  [Open access](#)

### A rare presentation of hepatolithiasis in an adolescent patient: A case report

Jonathan Freise, Jorge Mena, Kwun Wah Wen, Marshall Stoller, ... Carlos Corvera

Pages 343-345

[Download PDF](#) [Article preview](#) 

Case report  [Open access](#)

### Amputation in crush syndrome: A case report

María Camila Arango-Granados, Diego Fernando Cruz Mendoza, Alexander Ernesto Salcedo Cadavid, Alberto Federico García Marín

Pages 346-350

[Download PDF](#) [Article preview](#) 

Case report  [Open access](#)

### Pyriiform sinus perforation during nasotracheal intubation: a case report

Mohammed Elrabie Ahmed, Bahaa Mohammed Refaie, Farghali Abdelrahman, Abdul-Rahman Abdul-Majeed Ragab

Pages 351-354

[Download PDF](#) [Article preview](#) 

Case report  [Open access](#)

### Massive pericardial effusion causing cardiac tamponade accompanied by elevated CA-125 and thoracic lymphadenopathy in sarcoidosis: a case report

Taalaipek Kudaiberdiev, Elmira Tukusheva, Zhanybek Gaiblydaev, Gulnaz Tursunbekova, ... Emil Muraliev

Pages 355-360

[Download PDF](#) [Article preview](#) 

Case report  [Open access](#)

### Elective robotic hysterectomy for placenta accreta spectrum in the second trimester: Case report

Amro Elfeky, Mary Ann Son, Camila Paiva, Ioannis Alagkiozidis

Pages 361-364

[Download PDF](#) [Article preview](#) 

Case report  [Open access](#)

### Abdominoplasty for treatment of abdominal gun-shot wound sequelae – A case report

Vladislav Pavlovich Zhitny, Noama Iftekhar, Shannon Moreno, Frank Stile

Pages 365-368

[Download PDF](#) [Article preview](#) 

Case report  [Open access](#)

### Case reports on a gastric mass presenting with regional lymphadenopathy: A differential diagnosis is gastric schwannoma

Arnav Wadhawan, Maureen Brady, Charles LeVe, Steven Hochwald, Moshim Kukar

Pages 369-372

[Download PDF](#) [Article preview](#) 

Case report  [Open access](#)

### Bilateral petrous apex cephaloceles: Is surgical intervention indicated?

Ali Alkhaibary, Fahd Musawnaq, Makki Almuntashri, Abdulaziz Alarifi  
Pages 373-376

[Download PDF](#) [Article preview](#) 

Case report  [Open access](#)

A simultaneous bilateral asymmetric hip fracture in an elderly patient: A case report and review of the literature

Kristian Efremov, Alessandro Caterini, Fernando De Maio, Pasquale Farsetti  
Pages 377-380

[Download PDF](#) [Article preview](#) 

Case report  [Open access](#)

Acute intrathoracic gastric volvulus with retrograde gastric intussusception: A case report of a rare surgical emergency with review of the literature

Giovambattista Caruso, Sebastiano Caramma, Angelo Zappalà, Domenico Zerbo, ... Giuseppe Angelo Reina  
Pages 381-385

[Download PDF](#) [Article preview](#) 

Case report  [Open access](#)

Bicycle handlebar injury in a child resulting in complex liver laceration with massive bleeding and bile leakage: A case report

Jan Grosek, Žan Čebren, Jurij Janež, Aleš Tomažič  
Pages 386-390

[Download PDF](#) [Article preview](#) 

Case report  [Open access](#)

Reconstruction of Gustilo type IIIC tibial open fracture caused by shotgun injury using combination Masquelet technique and cross-leg pedicle flap

Chun-Yen Chen, Yung-Cheng Chiu, Cheng-En Hsu  
Pages 391-396

[Download PDF](#) [Article preview](#) 

Case report  [Open access](#)

Liver metastasectomy-cytoreductive surgery- hyperthermic intraperitoneal chemotherapy and ileal pouch-anal anastomosis: A case report

Leonidas Chardalias, Antonios Gklavas, Ira Sotirova, Erasmia Vlachou, ... Ioannis Papaconstantinou  
Pages 397-401

[Download PDF](#) [Article preview](#) 

Case report  [Open access](#)

Delayed enterocutaneous fistula formation secondary to an inverted non-absorbable suture post midline laparotomy closure

Danylo Yershov, Paul Murphy, Henry Ferguson  
Pages 402-405

[Download PDF](#) [Article preview](#) 

Case report  [Open access](#)

Cholecystitis on gallbladder duplication: A case report and literature review

Mabrouka Boukoucha, Fatma Dhieb, Raoudha Ben Khelifa, Hakim Znaidi, ... Alifa Daghfous  
Pages 406-410

[Download PDF](#) [Article preview](#) 

Short communication  [Open access](#)

Colorectal neuroendocrine tumors: A case series

Warsinggih, Liliyanto, Prihantono, Gusti Deasy Wilda Ariani, Muhammad Faruk  
Pages 411-417

[Download PDF](#) [Article preview](#) 

Case report  [Open access](#)

## Dedifferentiated liposarcoma of the spermatic cord: Case report and review of literature

Youssef Shaban, Adel Elkbuli, David Kim, Alia Abdulla, ... Jason Wolf

Pages 418-422

[Download PDF](#) [Article preview](#) 

Case report  [Open access](#)

## Spontaneous expulsion of an intrabronchial sharp metallic foreign body and migration to the gastrointestinal tract at Muhimbili National Hospital: Case report and literature review

Zephania Saitabau Abraham, Aveline Aloyce Kahinga, Kassim Babu Mapondella, Enica Richard Massawe, Daudi Ntunaguzi

Pages 423-425

[Download PDF](#) [Article preview](#) 

Case report  [Open access](#)

## A rare presentation of soft tissue chondroma: A case report

Fahmi H. Kakamad, Abdulwahid M. Salih, Marwan N. hassan, Shvan H. Mohammed, Ari M. Abdullah

Pages 426-428

[Download PDF](#) [Article preview](#) 

Case report  [Open access](#)

## Massive gallstone in an asymptomatic Indigenous Canadian male: Case report and literature review

Angela W. Chan, Rathi M. Sabaratnam, Yagan Pillay

Pages 429-432

[Download PDF](#) [Article preview](#) 

Case report  [Open access](#)

## Multifocal early gastric cancer in a patient with atrophic gastritis and pernicious anemia

Tommaso Zurleni, Michele Altomare, Giovanni Serio, Filippo Catalano

Pages 433-437

[Download PDF](#) [Article preview](#) 

Case report  [Open access](#)

## Gallbladder wall perforation secondary to empyema in Mirizzi's syndrome: An unseen complication. A case report

Awadh Alqahtani, Qurrat Al Ain Atif

Pages 438-442

[Download PDF](#) [Article preview](#) 

Case report  [Open access](#)

## Successful outcome in acute gastric volvulus in a low resource hospital setting in Bangladesh: A case report

Bappy Basak, M. Tasdik Hasan, Jessica Stauber, Amit Sen Gupta, ... S.M. Quamrul Akther

Pages 443-447

[Download PDF](#) [Article preview](#) 

Case report  [Open access](#)

## A rare case of huge maxillary ameloblastoma in a 3.5 years old girl

Mohamed El Sayed, Mohamed Touny, Nesreen Ibrahim, Zainab Al-Azzawi

Pages 448-453

[Download PDF](#) [Article preview](#) 



ELSEVIER



# International Journal of Surgery Case Reports

## Editor-in-Chief

Professor David Rosin, Barbados, West Indies

## Managing and Executive Editor

Dr Riaz Agha, London, UK

## Assistant Managing Editor

Maliha Agha, London, UK

Jo Hodgkison, London, UK

## Senior Editors

Professor Hasan Alam, Michigan, USA

Professor Raafat Afifi, Cairo, Egypt

Dr Juan Barret, Barcelona, Spain

Mr Ben Challacombe, London, UK

Dr Xiaio-ping Chen, Wuhan, China

Dr Burcin Ekser, Indianapolis, USA

Professor Joseph W Y Lau, Shatin, Hong Kong

Dr Oliver Muensterer, New York, USA

Dr Selwyn Rogers, Galveston, Texas

Professor Jamsheer Talati, Karachi, Pakistan

Dr Mangesh Thorat, London, UK

Professor Fu Chan Wei, Tapei, Taiwan

Professor Rudy Leon De Wilde, Oldenburg, Germany

## Associate Editors

Professor Roberto Coppola, Rome, Italy

Dr Veerappan Kasivisvanathan, London, UK

Dr Richard Keijzer, Winnipeg, Canada, USA

Dr Boris Kirshtein, Beer Sheva, Israel

Professor James McCaul, London, UK

Miss Emma McGlone, London, UK

Dr Dattatraya Muzumdar, Mumbai, India

Professor Andy Petroianu, Minas Gerais, Brazil

Mr Shahzad Raja, London, UK

Dr Kandiah Raveedran, Ipoh, Malaysia

Dr Daniel Yeh, Boston, USA

## Assistant Editors

Dr Rafid Al-Mahfoudh, Oxford, UK

Dr Hussein Atta, Boston, USA

Dr Mohammad Bashashati, Texas, USA

Professor Somprakus Basu, Varanasi, India

Mr Andrew Beamish, Cardiff, UK

Dr Anthony Charles, North Carolina, USA

Dr Amitava Das, Hyderabad, India

Dr Brian Davis, Texas, USA

Dr Susana Adriana Esquivel, Córdoba, Mexico

Professor Sheng Feng, Shanghai, China

Dr Juan Gomez Rivas, Madrid, Spain

Dr Haytham Kaafarani, Massachusetts, USA

Dr Yogeesh Kamat, Karnataka, India

Mr Omar Khan, London, UK

Prof. Tsuyoshi Konishi, Osaka, Japan

Dr Vito A Mannacio, Naples, Italy

Dr Todd Manning, Oxford, UK

Dr Zubing Mei, Shanghai, China

Dr Umesh Metkar, Beth, Israel

Dr Indraneil Mukherjee, Staten Island, USA

Dr Enyi Ofo, Adelaide, South Australia

Professor Prathamesh S Pai, Mumbai, India

Dr Alfredas Smailys, Kaunas, Lithuania

Prof. Peter Hyunsuk Suh, Seoul, South Korea

Dr Dieter Weber, Perth, Australia

Dr John Wee, Boston, USA

Dr Honggyi Zhu, Shanghai, China

## Statistical Editors

Dr Derek Cooper, London, UK

Professor Nora Donaldson, Colombia, South America

Professor Mary W Gray, Washington DC, USA

## Society Representative

Deniz Balci, Representative of the International Society of Liver Surgeons

Rhiannon Harries, President, Association of Surgeons in Training

Gene F. Coppa, President of the New York Surgical Society

Xiao-ping Chen, President of the Chinese Chapter of International

Hepato-Pancreato-Biliary Association

## Social Media Editor

Dr Riaz Agha, London, UK

## Assistant Commissioning Editors

Ahmed Al-Jabir, London, UK

Zaid Alsafi, London, UK

Michelle Griffin, Stanford, USA

Christos Iosifides, London, UK

Ahmed Kerwan, London, UK

Mehdi Khan, London, UK

Ginimol Matthew, London, UK

Maria Nicola, London, UK

Niamh O'Neill, London, UK

Catrin Sohrabi, London, UK

## Executive Committee

Professor David Albala, New York, USA

Sir Graeme Catto, London, UK

Professor David Cooper, Pittsburgh, USA

Lord Ara Darzi, London, UK

Professor Harold Ellis, London, UK

Ather Enam, Karachi, Pakistan

Sir Barry Jackson, London, UK

Professor Arthur Li Kwok-Cheung, Wanchai, Hong Kong

Professor C H Leong, Central, Hong Kong

Lord Ian McColl, London, UK

John Norcini, Philadelphia, USA

Professor Susan Standing, London, UK

Lord Robert Winston, London, UK

Sir Magdi Yacoub, London, UK

Sir Norman Williams, London, UK

## Editorial Board

**Raj Badwe**

*Mumbai, India*

**Michael Boscoe**

*Middlesex, UK*

**Rapheal Bueno**

*Boston, USA*

**Kris Chatamra**

*Bangkok, Thailand*

**Paul Coulthard**

*Manchester, UK*

**Anil d'Cruz**

*Mumbai, India*

**Mahesh Desai**

*Mumbai, India*

**Juan Gomez Rivas**

*Spain, Madrid*

**David W. Green**

*London, UK*

**Iraj Harirchi**

*Tehran, Iran*

**Doris Henne-Bruns**

*Ulm, Germany*

**Delawir Kahn**

*Cape Town, South Africa*

**Xiaoxi Lin**

*Shanghai, China*

**Ashok Mahapatra**

*New Delhi, India*

**Todd Manning**

*Melbourne, Australia*

**Indraneel Mitra**

*Mumbai, India*

**Vijay Naraynsingh**

*West Indies*

**Fabio Nicoli**

*London, UK*

**Anibal R. Núñez De Pierro**

*Buenos Aires, Argentina*

**Reuben Orda**

*Tel Aviv, Israel*

**Vladimir Semiglazov**

*St. Petersburg, Russia*

**Tejinder Singh**

*Ludhiana, India*

**Barbara L. Smith**

*Boston, USA*

**James Tatum**

*California, USA*

**Tehemton Udwardia**

*Mumbai, India*

**Martin R. Weiser**

*New York, USA*

**Yixin Zhang**

*Shanghai, China*

**Jun Zhong**

*Shanghai, China*

**Zhao-Fan Xia**

*Shanghai, China*

## Elsevier

### Executive Publisher

Ash Allan, Oxford, UK

### Administrative Editor

Josie Hutchins, Oxford, UK

### Marketing Manager

Jayne Dawkins, Philadelphia, USA

### Journal Manager

Tamsyn Hopkins, Exeter, UK

### Senior Business Development Executive (Reprints)

Emma Steel, London, UK

### Advertising Sales Manager


Robert Bayliss, London, UK

### Account Manager (Supplements)

Evelina Euren, Amsterdam, the Netherlands

### Project Manager Supplements & E-business

Mónica Hernández-Sesma, Amsterdam, the Netherlands



## Case Series

# Stereotactic aspiration of spontaneous intracerebral hematoma: Case series



Achmad Fahmi<sup>a,b,\*</sup>, Heri Subianto<sup>b</sup>, Nur Setiawan Suroto<sup>b</sup>, Budi Utomo<sup>c</sup>,  
Riyanarto Sarno<sup>d</sup>, Agus Turchan<sup>b</sup>, Abdul Hafid Bajamal<sup>b</sup>

<sup>a</sup> Post Graduate Doctoral Program, Faculty of Medicine, Universitas Airlangga, Indonesia

<sup>b</sup> Department of Neurosurgery, Faculty of Medicine, Universitas Airlangga, Indonesia

<sup>c</sup> Department of Public Health and Preventive Medicine, Faculty of Medicine, Universitas Airlangga, Indonesia

<sup>d</sup> Department of Informatics, Institute Teknologi Sepuluh Nopember, Indonesia

## ARTICLE INFO

## Article history:

Received 13 April 2020

Received in revised form 2 June 2020

Accepted 2 June 2020

Available online 11 June 2020

## Keywords:

Spontaneous intracerebral hematoma

Stereotactic aspiration

Safety

## ABSTRACT

**INTRODUCTION:** Minimally invasive techniques such as stereotactic aspiration of spontaneous intracerebral hematoma (SICH) evacuation can minimize brain tissue damage due to surgery. We share our experience of adopting stereotactic aspiration of SICH in our center without compromising safety.

**PRESENTATION OF CASES:** Three stereotactic aspiration procedures for SICH immediately after 24 h of onset are reported. All cases showed good results. Level of consciousness of all the patient returned to normal. Two patients could carry out routine activities independently. One patient has left hemiparesis.

**DISCUSSION:** Stereotactic aspiration of SICH has been newly implemented at our center with acceptable results achieved. Patient selection has an important role in determining the choice of technique. The procedures were done without anticoagulant agent. Stereotactic aspiration of SICH is associated with limited brain tissue damage, shorter duration of surgery, reduced length of stay, faster postoperative healing, and better functional improvement.

**CONCLUSION:** Stereotactic aspiration of SICH is a minimally invasive defined strategy for hematoma evacuation without compromising safety.

© 2020 The Authors. Published by Elsevier Ltd on behalf of IJS Publishing Group Ltd. This is an open access article under the CC BY license (<http://creativecommons.org/licenses/by/4.0/>).

## 1. Introduction

Spontaneous intracerebral hemorrhage (SICH) has a high mortality and morbidity rate. It places a significant economic burden on hospitals and health care services. The incidence of spontaneous supratentorial ICH was 20 cases per 100,000 populations, and more than 70 percent of patients died. Spontaneous ICH causes 10–15 percent of first-ever strokes with a 30-day mortality rate of 35–52 percent, and half of them die within two days after the event [1,2].

Open craniotomy techniques have a mortality rate of 25 percent within three months, and 58.9 percent of patients undergoing surgery have an unfavorable outcome [1]. Currently, minimally invasive techniques such as stereotactic aspiration and endoscopy surgery of ICH evacuation can minimize brain tissue damage due to surgery, shorter duration of surgery, and allow local use of anesthesia. Stereotactic aspiration was our new guideline since 2013. We

share our experience stereotactic aspiration of SICH in the center with newly adopted this technique without compromising safety using Leksell stereotactic hematoma evacuator in general anesthesia without any anticoagulant agent. This work has been reported in line with the PROCESS guideline [3].

## 2. Presentation of cases

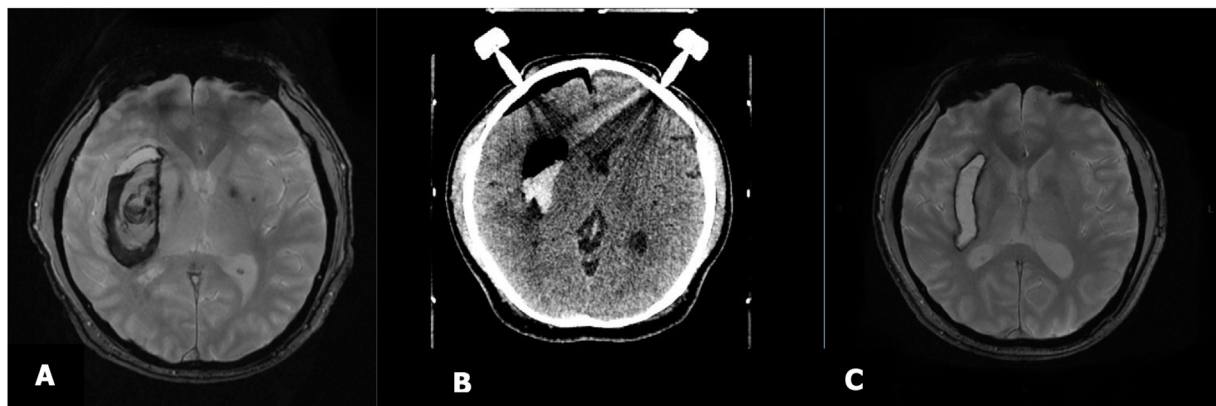
### 2.1. Case 1

A 45-year-old man presented to the emergency room 30 min after developing left hemiparesis and SICH was diagnosed. He refused the treatment on admission. Seven hours later, the patient was brought back to the hospital with diminished level of consciousness and left hemiparesis. The Glasgow Coma Scale (GCS) was E3V3M5.

Head MRI showed acute ICH in the right basal ganglia with volume 55 cc. The perifocal edema displaced the right lateral and third ventricles, causing midline shifting as much as 5 mm to the other side. The patient consented to undergo stereotactic aspiration surgery without anticoagulant for evacuating the clot.

\* Corresponding author at: Sekretariat bedah saraf, GDC lantai 5, Dr. Soetomo General Academic Hospital, Surabaya, 60286, Indonesia.

E-mail address: [achmad.fahmi-13@fk.unair.ac.id](mailto:achmad.fahmi-13@fk.unair.ac.id) (A. Fahmi).



**Fig. 1.** A. MRI image performed a few hour after onset, B. Post-operative CT Scan after stereotactic surgery immediately, and C. MRI image 2 months after surgery.

Stereotactic aspiration of ICH was performed under general anesthesia 10 h after admission. Ten cc of residual hematoma was detected on repeat CT scan and decision was made to manage it conservatively. The patient was treated for 23 days with a satisfactory result. GCS improved to E4V5M6 with residual left hemiparesis. [Fig. 1](#) shows MRI scan two months after surgery.

## 2.2. Case 2

A 52-year-old woman was admitted to the hospital 15 min after developing a decline in level of consciousness. The GCS was E4V2M5 and no hemiparesis. Head MRI showed hyperacute ICH in left temporal lobe (left external capsule and left corona radiata) with volume of 25.6 cc. The perifocal edema pushed the left lateral ventricle, causing midline structure deviation to the right side as much as 6 mm.

We performed stereotactic surgery without anticoagulant for ICH evacuation 6 h after the onset of symptoms. [Fig. 2](#) presents the postoperative head CT scan showing 80 percent reduction in the amount of hemorrhage. The patient was treated for 11 days. She had GCS E4V5M6 and was able to do routine activities independently before discharge.

## 2.3. Case 3

A 27-year-old girl arrived in the emergency room with diminished consciousness 30 min after the onset of symptoms. The GCS was E3V2M5 with no hemiparesis. A head CT scan revealed ICH on the frontal and parietal regions with a volume of 35 cc causing midline shift to the right side as far as 4 mm. There was non-communicating hydrocephalus, intraventricular hemorrhage, and brain edema.

Stereotactic aspiration surgery for evacuating the hemorrhage and external ventricular drainage was done without any anticoagulant. The post procedure CT scan showed 90 percent reduction in the amount of hemorrhage. A week later another CT scan was repeated. We found that the ICH in left subcortical frontal lobe (left basal ganglia) had significantly reduced ([Fig. 3](#)). The patient was treated for 16 days. Her level of consciousness was E4V5M6 with no neurological deficits, and she was able to take on routine activities independently.

## 3. Discussion

Several studies indicate that patients who receive minimally invasive therapies such as stereotactic aspiration and

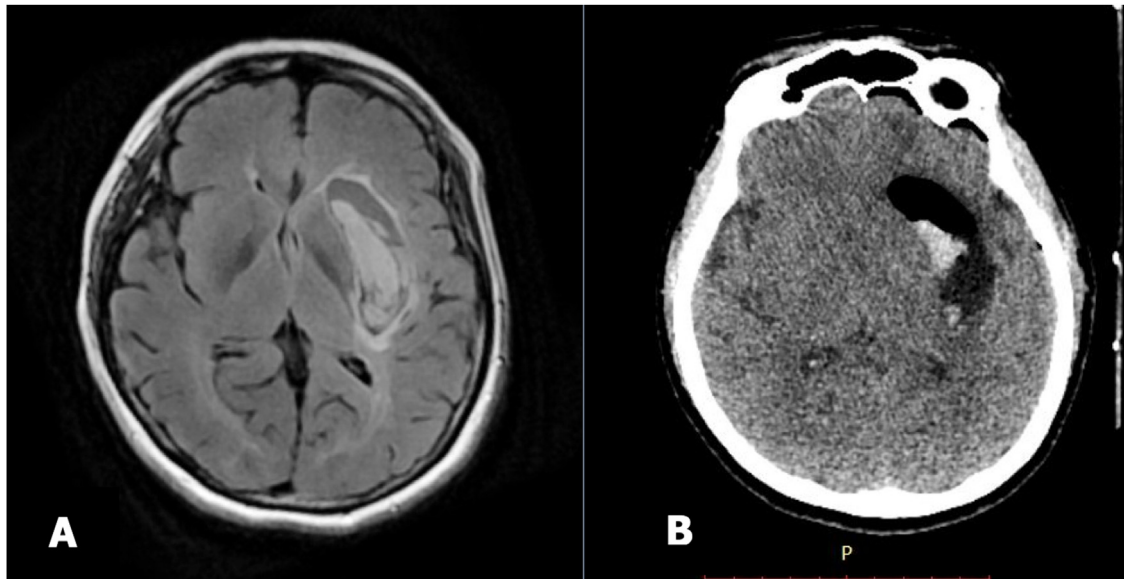
endoscopic surgery have improved outcomes in the form of minimal tissue damage, less blood loss, reduced brain swelling or edema, reduced operative time, shortened length of stay, faster postoperative healing, and better functional improvement [4].

A meta-analysis study compared stereotactic aspiration with medical therapy for 740 patients with spontaneous ICH. The results showed that mortality due to the ICH was most common in patients who received medication therapy compared with the stereotactic aspiration of hematoma evacuation [1]. Li et al. conducted a research about the comparison between the open craniotomy, stereotactic aspiration, and endoscopic surgery in the management of ICH and found that a number of surgical procedures for evacuating clot such as open craniotomy turned out to be more disadvantageous because of brain tissue damage. They also analyzed and compared the safety and efficacy of stereotactic aspiration, endoscopic surgery, and craniotomy for the treatment of spontaneous supratentorial lobar ICH [4].

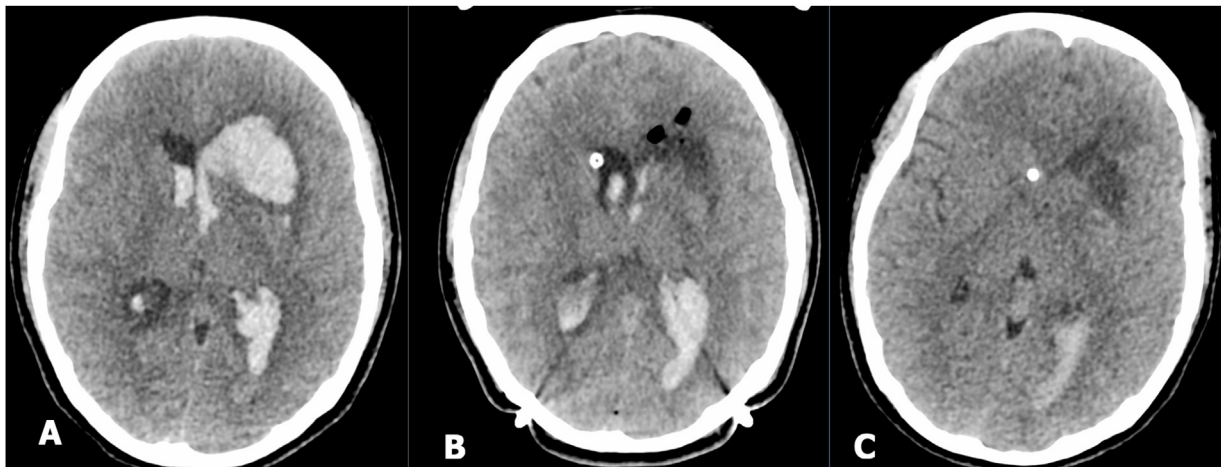
According to a meta-analysis of randomized controlled trials comparing stereotactic aspiration versus craniotomy for primary ICH, stereotactic aspiration has several benefits, including: (1) Significantly decreased odds of death or dependency in patients with primary ICH. (2) No significant difference in the total risk of complications between the groups with either stereotactic aspiration or craniotomy treatment. (3) Significantly reduced risk of re-bleeding with stereotactic aspiration in comparison with craniotomy. (4) Significantly reduced risk of death/dependence, death, and GI hemorrhage compared to conventional open craniotomy. (5) Significantly decreased risk of re-bleeding compared to key-hole craniotomy [5].

The prognosis of ICH depends on the location of the bleeding (supratentorial or infratentorial), size of the hematoma, level of consciousness, age, and general condition of the patient. Death after 30 days of ICH ranged from 35 to 52 percent; half of them happened in the first two days of onset [6]. In our cases, the patients experienced a fairly good improvement after performing stereotactic aspiration surgery. Even two of them are able to carry out the physical activity normally without any neurological deficits, while one patient still has weakness in half of the body. This is similar to the research which was conducted by Kim, et al., who examined the functional outcome of spontaneous ICH patients with hematoma volume less than 30 ml and level of consciousness more than 13 who underwent stereotactic aspiration. The results showed that there was an increase in functional outcomes and improvement in functional recovery to perform daily life activities [7].





**Fig. 2.** A. Pre-operative MRI a few hour after onset, and B. Post-operative CT scan after stereotactic surgery immediately.



**Fig. 3.** A. Head CT scan a few hour after onset, B. Head CT scan image after stereotactic aspiration immediately, and C. Head CT scan image taken a week after surgery.

#### 4. Conclusions

Stereotactic aspiration of SICH technique without anticoagulant agent provides surgeons with a defined strategy for hematoma evacuation without compromising safety. Patient's selection still has an important role in deciding open craniotomy or stereotactic aspiration or other techniques. Stereotactic aspiration of hematoma evacuation can minimize brain tissue damage due to surgery, shortens duration of surgery, reduces length of stay, enhances post-operative healing, and improves functional outcome.

#### Declaration of Competing Interest

None.

#### Sources of funding

None.

#### Ethical approval

All of the procedures performed in this study involving human participants were in accordance with the ethical standards of the institutional research committee.

#### Consent

All of the patient had sign informed consent for the surgery. Patient identity doesn't seen in this case report.

#### Author contribution

Achmad Fahmi, MD, Ph.D: study concept or design, data collection, data analysis or interpretation, writing the paper.  
 Heri Subianto, MD: study concept or design, writing paper.  
 Nur Setiawan Suroto, MD: study concept or design.  
 Budi Utomo, MD, PhD: study concept and critical revised article.  
 Prof. Riyanarto Sarno: study concept and critical revised article.  
 Agus Turchan, MD, PhD: study concept, critical revised article and supervising.



Prof. Abdul Hafid Bajamal: study concept, critical revised article and supervising.

### Registration of research studies

Name of the registry: <http://www.researchregistry.com>.

Unique identifying number or registration ID: researchregistry5506.

Hyperlink to your specific registration (must be publicly accessible and will be checked): N/A.

### Guarantor

Achmad Fahmi, MD, Ph.D

Post Graduate Doctoral Program, Faculty of Medicine, Universitas Airlangga, Indonesia.

### Provenance and peer review

Not commissioned, externally peer-reviewed.

### Acknowledgments

Our acknowledgments to Dr. Soetomo General Academic Hospital and National Hospital, Surabaya, Indonesia, where the surgeries were performed.

### References

- [1] T. Akhigbe, U. Okafor, T. Sattar, D. Rawluk, T. Fahey, Stereotactic-guided evacuation of spontaneous supratentorial intracerebral hemorrhage: systematic review and meta-analysis, *World Neurosurg.* 84 (2) (2015) 451–460.
- [2] Y.S. Choo, J. Chung, J. Joo, Y.B. Kim, C. Hong, Borderline basal ganglia hemorrhage volume: patient selection for good clinical outcome after stereotactic catheter drainage, *J. Neurosurg.* 125 (5) (2016) 1242–1248.
- [3] R.A. Agha, M.R. Borrelli, R. Farwana, K. Koshy, A.J. Fowler, D.P. Orgill, SCARE Group, The PROCESS 2018 statement: updating consensus Preferred Reporting of CasE Series in Surgery (PROCESS) guidelines, *Int. J. Surg.* 60 (2018) 279–282.
- [4] Y. Li, R. Yang, Z. Li, Y. Yang, B. Tian, X. Zhang, B. Wang, D. Lu, S. Guo, M. Man, Y. Yang, T. Luo, G. Gao, L. Li, Surgical evacuation of spontaneous supratentorial lobar intracerebral hemorrhage: comparison of safety and efficacy of stereotactic aspiration, endoscopic surgery, and craniotomy, *World Neurosurg.* 105 (2017) 332–340.
- [5] W. Wang, N. Zhou, C. Wang, Minimally invasive surgery for patients with hypertensive intracerebral hemorrhage with large hematoma volume: a retrospective study, *World Neurosurg.* 105 (2017) 348–358.
- [6] J. Broderick, S. Connolly, E. Feldmann, D. Hanley, C. Kase, M. Mayberg, L. Morgenstern, C.S. Ogilvy, P. Vespa, M. Zuccarello, American Heart Association, American Stroke Association Stroke Council, High Blood Pressure Research Council, Quality of Care and Outcomes in Research Interdisciplinary Working Group, Guidelines for the management of spontaneous intracerebral hemorrhage in adults: 2007 update: a guideline from the American Heart Association/American Stroke Association Stroke Council, High Blood Pressure Research Council, and the Quality of Care and Outcomes in Research Interdisciplinary Working Group, *Stroke* 38 (6) (2007) 2001–2023.
- [7] Y.Z. Kim, K.H. Kim, Even in patients with a small hemorrhagic volume, stereotactic-guided evacuation of spontaneous intracerebral hemorrhage improves functional, *J. Korean Neurosurg. Soc.* 46 (2) (2009) 109–115.

### Open Access

This article is published Open Access at [sciencedirect.com](https://www.sciencedirect.com). It is distributed under the [IJSCR Supplemental terms and conditions](#), which permits unrestricted non commercial use, distribution, and reproduction in any medium, provided the original authors and source are credited.