



Submit your article ↗

Guide for authors ↗

Menu

Search in this journal

Volume 77

Pages 1-946 (2020)

< Previous vol/issue

Next vol/issue >

Receive an update when the latest issues in this journal are published

 Sign in to set up alerts

Case report ● Open access

Adrenal hemangioma: A rare presentation of bleeding incidentaloma: Case report

Alaa Kansoun, Etienne El-Helou, Houssam Bashir Mazraani, Ali Nassif, ... Houssam Alam

Pages 442-445

 [Download PDF](#) Article preview 

Case report ● Open access

A rare case report of recurrent metastatic breast cancer mimicking primary pancreatic cancer

Prajwala S Prakash, James Wai Kit Lee, Siau Wei Tang, Philip Tsau Choong lau

Pages 446-449

 [Download PDF](#) Article preview 

Case report ● Open access

A case of Type 2 appendiceal diverticulum perforated and a review of the literature

Michele Fiordaliso, Antonia Flavia De Marco, Raffaele Costantini

Pages 450-453

 [Download PDF](#) Article preview 

Case report ● [Open access](#)

Acute arterial occlusion of the lower limb as the main clinical manifestation in a patient with Covid-19 – Case Report

Víctor de Oliveira Costa, Guilherme Bicalho Civinelli de Almeida, Eveline Montessi Nicolini, Guilherme de Abreu Rodrigues, ... Davi Pinto Colen

Pages 454-458

[Download PDF](#) Article preview 

Case report ● [Open access](#)

Diagnostic and surgical dilemma of cholecystitis that mimics cancer – A case report of xanthogranulomatous cholecystitis

Alex Lee, Catherine L. Forse, Cynthia Walsh, Kimberly Bertens, Fady Balaa

Pages 459-462

[Download PDF](#) Article preview 

Case report ● [Open access](#)

Sodium-glucose cotransporter-2 (SGLT2) inhibitor-induced euglycemic diabetic ketoacidosis complicating the perioperative management of a patient with type 2 diabetes mellitus (T2DM) and Fournier's gangrene: A case report

Patrick J. Lindsay, Lauren E. Gibson, Edward A. Bittner, Sheri Berg, Marvin G. Chang

Pages 463-466

[Download PDF](#) Article preview 

Case report ● [Open access](#)

Breakdown of spontaneous fused bilateral hip with heterotopic ossification to staged bilateral total hip arthroplasty through a direct lateral approach: A case report

Osama R. Aldhafian, Bashir R. Alenazi, Abdulrhman M. Mohammed, Hussam E. Khairi, Naif Bin Nwihadh

Pages 467-471

[Download PDF](#) Article preview 

Case report ● [Open access](#)

Management of septic non union and discrepancy of humerus in a child: A case report

Mohseni Ahmed Amine, Boussetta Rim, Zairi Mohamed, Saied Walid, ... Mohamed Nabil Nessib

Pages 472-475

[Download PDF](#) Article preview 

Mini review ● [Open access](#)

Colo-ovarian Fistula complicating acute diverticulitis: Two cases and literature review

Catarina Quintela, Cláudia Santos, Ana Catarina Silva, Eva Barbosa, ... Artur Silva

Pages 476-482

[Download PDF](#) Article preview 

Case report ● [Open access](#)

A case report of prostate cancer presenting as a symptomatic pelvic mass mimicking lymphoma

Zied Mahjoubi, Mokhtar Bibi, Housseem Hedhli, Yassine Ouanes, ... Noura Yassine

Pages 483-485

[Download PDF](#) Article preview 

Case report ● [Open access](#)

Giant recurrent liposarcoma of the retroperitoneum – A surgical challenge: A case report

Zied Mahjoubi, Walid Zakhama, Aymen Sakly, Manel Njima, ... Yassine Binous

Pages 486-489

[Download PDF](#) Article preview 

Case report ● [Open access](#)

Newborn with complete double penis and two separate scrotums: A case report

Ahmed Maher, Tarek Abdelazeem Sabra, Hussein Ibrahim, Mahmoud Mostafa

Pages 490-497

[Download PDF](#) Article preview 

Case report ● [Open access](#)

A case report of diffuse hyperplastic gastropathy with multiple polypoid formations in a patient with pernicious anemia, *Helicobacter pylori* infection, hypergastrinemia and hypoalbuminaemia: Do not forget of Ménétrier's disease

Daniel Reis Waisberg, Evandro Sobroza de Mello, Francisco Tustumi, Daniel José Szor, ... André Roncon Dias

Pages 498-502

[Download PDF](#) Article preview 

Case report ● [Open access](#)

What surgeons should know about emergency operation for COVID-19 confirmed patients: A case report

Dongkyu Oh, Yu Min Kang, Jin Yong Choi, Wang Jun Lee

Pages 503-506

[Download PDF](#) Article preview 

Case report ● [Open access](#)

A case report of appendicitis within an Amyand's hernia: A surprising finding in diagnostic laparoscopy

Majid Samsami, Shahram Sayadi, Shohra Qaderi, Javad Zebarjadi Bagherpour

Pages 507-509

[Download PDF](#) Article preview 

Case report ● [Open access](#)

Successful treatment of valgus knee osteoarthritis involving external tibial torsion with a double level osteotomy: A case report

Shohei Murata, Hidetomo Saito, Kimio Saito, Toshiaki Yamamura, ... Yoichi Shimada

Pages 510-514

[Download PDF](#) Article preview 

Case report  *Open access*

Intravesical foreign object: A case report of autoerotism

Albert Ivan Simangunsong, Sawkar Vijay Pramod

Pages 515-518

[Download PDF](#) Article preview 

Case report  *Open access*

Stent-graft placement for delayed extrahepatic portal hemorrhage after surgical treatment for perihilar cholangiocarcinoma: A case report

Tadashi Tsukamoto, Chihoko Nobori, Tsuyoshi Nishiyama, Tomohiro Kunimoto, ... Yukio Nishiguchi

Pages 519-522

[Download PDF](#) Article preview 

Case report  *Open access*

Head and tail pancreatic duct stones mimicking duplex staghorn renal calculi: A rare case

Adeodatus Yuda Handaya, Nurbudiono, Aditya Rifqi Fauzi, Joshua Andrew, ... Azriel Farrel Krisna Aditya

Pages 523-526

[Download PDF](#) Article preview 

Case report  *Open access*

Hemorrhagic synovial cyst: An unexpected cause of acute cervical spinal cord compression. Case report

Khaled Radhouane, Hadhemi Dridi, Nada Mansouri, Mohamed Dehmani Yedeas, ... Ridha Chkili

Pages 527-530

[Download PDF](#) Article preview 

Case report  *Open access*

Superficial Acral Fibromyxoma: A case report

Mürüvvet Akçay Çelik, Havva Erdem, Nurten Turhan Haktanır

Pages 531-533

[Download PDF](#) Article preview 

Case report  *Open access*

Bezold's abscess: An extremely rare complication of suppurative mastoiditis: Case report and literature review

Hicham Lyoubi, Omar Berrada, Adil Lekhbal, Reda Allah Abada, Mohammed Mahtar

Pages 534-537

[Download PDF](#) Article preview 

Case report  *Open access*

A giant hand lipoma as a rare cause of secondary carpal tunnel syndrome - A case report

Mariana Barreira, Nuno Marques, Vicente Campos, Guilherme Marques, ... Sandra Stefanova Alves

Pages 538-542

[Download PDF](#) Article preview 

Case report ● [Open access](#)

Management of complex pelvic fracture and sacral fracture Denis type 2 using spanning unilateral fixation of L5 to S2AI screw

Yudha Mathan Sakti, Akbar Mafaza, Zikrina Abyanti Lanodiyu, Galih Prasetya Sakadewa, Rahadyan Magetsari

Pages 543-548

[Download PDF](#) Article preview 

Case report ● [Open access](#)

Mirizzi syndrome in a patient with partial gastrectomy with Billroth II anastomosis: A case report

Giacomo E.M. Rizzo, Giovanni Di Carlo, Giovanna Rizzo, Giuseppina Ferro, ... Carmelo Sciumè

Pages 549-553

[Download PDF](#) Article preview 

Case report ● [Open access](#)

Laparotomy-assisted transcatheter variceal embolization for bleeding jejunal varices formed at the site of choledochojejunostomy: Report of a case and review of the literature

Masaki Wakasugi, Masanori Tsujie, Seiichi Goda, Kohsaku Ohnishi, ... Junichi Hasegawa

Pages 554-559

[Download PDF](#) Article preview 

Case report ● [Open access](#)

Giant cell tumor of bone at the proximal epiphysis of humerus in a skeletally immature patient: A case report

Manuel A. Ramírez-González, Gerardo Olivella, Norman Ramírez, Antonio Soler-Salas, ... Christian Foy-Parilla

Pages 560-564

[Download PDF](#) Article preview 

Case report ● [Open access](#)

Suprasellar epidermoid cyst in an adult female, presenting as amnesia and somnolence: A rare case report

Habib Ahmad Esmat

Pages 565-569

[Download PDF](#) Article preview 

Case report ● [Open access](#)

Uterus inguinal hernia accompaniment didelphys uterus: A case report

Yang Deng, Yuan Wang, Bo Wang, Langsong Hao

Pages 570-572

[Download PDF](#) Article preview 

Mini review ● *Open access*

Vim line technique thalamotomy for Parkinson tremor: Case series

Achmad Fahmi, Heri Subianto, Priya Nugraha, Muhammad Hamdan, ... Abdul Hafid Bajamal
Pages 573-575

[Download PDF](#) Article preview 

Case report ● *Open access*

Complete resolution of recurrent piriformis syndrome after piriformis resection with 3 years' follow up: A case report

Achmad Fahmi, Mustaqim Apriyansa Rahmadhan, Dirga Rachmad Aprianto, Heri Subianto, Agus Turchan
Pages 576-579

[Download PDF](#) Article preview 

Case report ● *Open access*

Lumbar artery aneurysm complicated by a fistula between the aneurysm and the duodenum in a patient with Leriche syndrome: A case report

Toru Imagami, Masaki Sakamoto, Hisanori Kani, Masao Tadakoshi
Pages 580-583

[Download PDF](#) Article preview 

Case report ● *Open access*

Congenital pseudarthrosis of the forearm treated with induced membrane technique: A case report

Ahmed Amine Mohseni, Rim Boussetta, Walid Saied, Mohamed Zairi, ... Mohamed Nabil Nessib
Pages 584-590

[Download PDF](#) Article preview 

Case report ● *Open access*

Pembrolizumab and tavokinogene telseplasmid electroporation in metastatic melanoma

Yonatan Dollin, Jason Rubin, Richard D. Carvajal, Helene Rached, James R. Nitzkowski
Pages 591-594

[Download PDF](#) Article preview 

Case report ● *Open access*

Hybrid management of thoracic aortic aneurysm in a patient with massive hemoptysis: A case report

Ali Sadeghpour Tabaei, Amirhosein Jalali, Sanaz Asadian, Omid Shafe, ... Yaser Toloueitabar
Pages 595-598

[Download PDF](#) Article preview 

Case report ● *Open access*

Orbital emphysema post laparoscopic Nissen fundoplication in an adult with ventriculoperitoneal shunt. Case report

Iuliana M. Lupu, Mona Momeni, Pierre Geradon, Yannik Deswysen, Cristina B. Robu
Pages 599-601

[Download PDF](#) Article preview 

Case report ● *Open access*

Segmental renal artery and popliteal artery embolism in an adult patient with rheumatic heart disease and atrial fibrillation: A case report

Purushottam Parajuli, Bhoj Raj Luitel, Suman Chapagain, Manish Man Pradhan, ... Uttam Kumar Sharma

Pages 602-604

[Download PDF](#) Article preview 

Case report ● *Open access*

Trousseau's syndrome associated with rapidly emerging pancreatic adenocarcinoma soon after esophagectomy: A case report

Sang-Woong Lee, Ryo Tanaka, Yoshiro Imai, Hiroko Kuwabara, ... Kazuhisa Uchiyama

Pages 605-609

[Download PDF](#) Article preview 

Case report ● *Open access*

Improvised vacuum assisted closure dressing for enterocutaneous fistula, a case report

Masawa K. Nyamuryekunge, Biswalo Yango, Ally Mwanga, Athar Ali

Pages 610-613

[Download PDF](#) Article preview 

Case report ● *Open access*

The efficacy of intraoperative indocyanine green fluorescence angiography in gastric cancer operation after living donor liver transplantation: A case report

Wei Zhou, Kengo Kanetaka, Akira Yoneda, Shinichiro Kobayashi, ... Susumu Eguchi

Pages 614-617

[Download PDF](#) Article preview 

Case report ● *Open access*

Malignant peripheral nerve sheath tumour – A long story: Case report

Y.M. Fazil Marickar, Betty Abraham

Pages 618-623

[Download PDF](#) Article preview 

Case report ● *Open access*

Surgical treatment for mediastinitis after endobronchial ultrasound-guided transbronchial needle aspiration: 2 case reports

Sung Joon Han, Yooyoung Chong, Man-shik Shim, Woosik Han, ... Jae Hyeon Yu

Pages 624-627

[Download PDF](#) Article preview 

Case report ● *Open access*

Synchronous primary adenocarcinoma of the appendix and colon: Case report and literature review

Mohammad K.M. Al-Wiswasy, Hamzeh Al-Balas, Raith A.S. Al-Saffar, Mahmoud Al-Balas

Pages 628-633

[Download PDF](#) Article preview 

Case report ● *Open access*

An unusual presentation of pleomorphic adenoma in a patient with thalassemia: A case report

Abdelrahman R. Alsaleh, Adham A. Aljariri, Baraa A. Wazwaz, Hasan A. Haider, ... Abdulqadir J. Nashwan

Pages 634-637

[Download PDF](#) Article preview 

Case report ● *Open access*

A giant mesenteric fibromatosis adherent to the appendix and colonic wall, case report

Etienne El-Helou, Mersad Alimoradi, Hassan Sabra, Jessica Naccour, ... Henri Bitar

Pages 638-642

[Download PDF](#) Article preview 

Case report ● *Open access*

Management of large and surrounding tissue infiltrative anal fistula cancer: Two case reports

Sang Hyun An, Ik Yong Kim

Pages 643-646

[Download PDF](#) Article preview 

Case report ● *Open access*

Cardiac metastasizing leiomyoma: A case report

Raquel Reis Soares, Leonardo Ferber Drumond, Daniel Soares da Mata, Luiza Miraglia Firpe, ... Matheus Ferber Drumond

Pages 647-650

[Download PDF](#) Article preview 

Mini review ● *Open access*

Treatment and evaluation of recurrence for antrochoanal polyps by endoscopic large middle meatal antrostomy, clinical case series of 25 patients

Yassir Hammouda, Omar Berrada, Sami Rouadi, Redallah Larbi Abada, Mohamed Mahtar

Pages 651-655

[Download PDF](#) Article preview 

Case report ● *Open access*

Warfarin-induced major unilateral breast necrosis in a patient with antiphospholipid syndrome: A case report

Abdullh AlQhtani, Abdulrahman AlSahabi, Ahmad Ashammery

Pages 656-659

[Download PDF](#) Article preview 

Case report ● *Open access*

Breast adenomyoepithelioma, a case report

Etienne El-Helou, Jad J. Terro, Alaa Kansoun, Georges Robert Neaime, ... Houssam Alam
Pages 660-663

[Download PDF](#) Article preview 

Case report ● *Open access*

Spleen in the thorax: A case report on traumatic diaphragmatic rupture

S. Dahal, R. Koju, B. Shrestha, T. Karki, S. Bade
Pages 664-667

[Download PDF](#) Article preview 

Case report ● *Open access*

Endoscopic-guided percutaneous nephrolithotomy (EPNL) with prone split-leg position for complex kidney stone: A case report

Soefiannagoya Soedarman, Nur Rasyid, Ponco Birowo, Widi Atmoko
Pages 668-672

[Download PDF](#) Article preview 

Case report ● *Open access*

The strategy for Mirizzi syndrome type II with laparoscopic surgery: A case report

Hirofumi Sato, Masatsugu Hiraki, Atsushi Miyoshi, Shota Ikeda, ... Kenji Kitahara
Pages 673-676

[Download PDF](#) Article preview 

Case report ● *Open access*

Necrotizing soft tissue infection after liposculpture; Case report

Raul Cuevas Bustos, Oscar Cervantes Gutierrez, Felix Alejandro Perez Tristan, Alejandro Acuña Macouzet, ... Marcos Jaffif Cojab
Pages 677-681

[Download PDF](#) Article preview 

Case report ● *Open access*

Intramuscular haemangioma of abductor hallucis muscle – A rare case report

Dimas Radithya Boedijono, Andi Praja Wira Yudha Luthfi, Erlina
Pages 682-685

[Download PDF](#) Article preview 

Case report ● *Open access*

Case report: Neonatal pancreatitis, chromosomal abnormality and duodenal stenosis in a newborn. A new syndrome?

Oluwaseun Ladipo-Ajayi, George Ihediwa, Andrea O. Akinjo, Nicholas A. Awolola, ... Adesoji E. Ademuyiwa
Pages 686-691

[Download PDF](#) Article preview 

Case report  *Open access*

Fournier's gangrene under SGLT-2 inhibitor therapy: A literature review and case report

Lisa Ellegård, Mattias Prytz
Pages 692-694

[Download PDF](#) Article preview 

Case report  *Open access*

Combined injury of femoral artery and femoral nerve after blunt trauma to the proximal femur: A case report

Abdulaziz AlKheraiji, Abdulaziz AlHakbani
Pages 695-697

[Download PDF](#) Article preview 

Case report  *Open access*

Unilateral *Exserohilum* Allergic Fungal Sinusitis in a Pediatric Host: Case Report

Arwa A. Al Muslat, Basmah M. Alghmdi, Abdullah J. AlShehri, Rakan A. Alhaidey, ... Naif H. Alotaibi
Pages 698-700

[Download PDF](#) Article preview 

Case report  *Open access*

Invasive ductal carcinoma arising in borderline phyllode tumor: A potential role of PIK3CA mutation

Sarah Bouri, Philippe Simon, Nicky D'Haene, Xavier Catteau, Jean-Christophe Noël
Pages 701-703

[Download PDF](#) Article preview 

Case report  *Open access*

Co-existence of oral intra-muscular lipoma and lobular capillary hemangioma: A rare case report

Yogesh Kini, Anish Kamat, Komal Navalkha, Swapna Nayan, ... Damini Gupta
Pages 704-707

[Download PDF](#) Article preview 

Case report  *Open access*

Localised amyloidosis of the bladder: A rare mimic of urinary tract malignancy (case report and literature review)

N. Mayor, A.S.J. Coppola, Harry Knights, T. Nazar, ... H. Mostafid
Pages 708-710

[Download PDF](#) Article preview 

Case report ● *Open access*

Destructive Osteonecrosis of the Femoral Head After a Single Intra-Articular Corticosteroid Injection: A Report of Two Cases

Abdulaziz F. Ahmed, Mohammed Hammad, Motasem Salameh, Ghalib O. Ahmed

Pages 711-715

[Download PDF](#) Article preview 

Case report ● *Open access*

Traumatic pseudoaneurysm of the brachiocephalic artery obstructing the airways

Bader M. Tahlawi, Amirah Hassan, Mohamed Regal

Pages 716-718

[Download PDF](#) Article preview 

Case report ● *Open access*

SARS-COV-2 infection in the perioperative of pulmonary lobectomy. About a case

Ricardo Taipe, Mardonio Euscatigue, Fernando Valdivia, Brenner Belloso, Irene Huaroto

Pages 719-725

[Download PDF](#) Article preview 

Case report ● *Open access*

Retrorectal tumors: Case report and review of literature

Giorgio La Greca, Giovanni Trombatore, Guido Basile, Pietro Conti

Pages 726-729

[Download PDF](#) Article preview 

Case report ● *Open access*

Nutcracker syndrome due to aorto-mesenteric compression in adults: Case report and literature review

Khalid Elhattabi, Abdelilah Elbakouri, Mohamed Ouchane, Mounir Bouali, ... Abdelaziz Fadil

Pages 730-732

[Download PDF](#) Article preview 

Mini review ● *Open access*

Minimally invasive perineal redo surgery for rectovesical and rectovaginal fistulae: A case series

A.A.J. Grüter, S.E. Van Oostendorp, L.J.H. Smits, M. Kusters, ... J.B. Tuynman

Pages 733-738

[Download PDF](#) Article preview 

Case report ● *Open access*

Hip transposition procedure due to osteosarcoma metastasis of the ilium in a patient with preexisting rotationplasty leads to satisfactory functional result: A case report

Jan Puetzler, Niklas Deventer, Georg Gosheger, Thomas Goesling, ... Tymoteusz Budny

Pages 739-742

[Download PDF](#) Article preview 

Case report  *Open access*

A patient with superior mesenteric artery lymph node metastasis after laparoscopic gastrectomy for gastric cancer with Adachi type VI vascular anomaly: A case report

Kenjiro Hirai, Taro Aoyama, Wataru Hirata, Hiroshi Okabe, Akira Mitsuyoshi

Pages 743-747

[Download PDF](#) Article preview 

Case report  *Open access*

Management of a transverse vaginal septum complicated with hematocolpos in an adolescent girl: Case report

El Moussaoui Kamal, Amina Lakhdar, Aziz Baidada

Pages 748-752

[Download PDF](#) Article preview 

Case report  *Open access*

First-in-man craniectomy and asportation of solitary cerebellar metastasis in COVID-19 patient: A case report

Pierfrancesco Lapolla, Pietro Familiari, Placido Bruzzaniti, Roberto Arcese, ... Antonio Santoro

Pages 753-758

[Download PDF](#) Article preview 

Case report  *Open access*

Morel-Lavallée lesion as an unusual cause of hemorrhagic shock: Case report and review of literature

Mohamed Aziz Daghmouri, Imen Ben Ismail, Maroua Ouesleti, Mohamed Amine Tarhouni, ... Lotfi Rebai

Pages 759-761

[Download PDF](#) Article preview 

Case report  *Open access*

A rare case of colon obstruction due to gastrointestinal basidiobolomycosis in a 36-year-old woman

Alaa Eid Aljohani, Bandar Alshemesi, Abdullatif Alshubaisheri, Abdulmajeed Alkraidis, ... Rami Sairafi

Pages 762-765

[Download PDF](#) Article preview 

Case report  *Open access*

Radicular cysts and Chin implants; An unexpected complication prompting explantation – Case report

Mohamed A. Mrad, Qutaiba N.M. Shah Mardan, Nehal A. Mahabbat

Pages 766-768

[Download PDF](#) Article preview 

Case report  *Open access*

Unusual presentations of urogenital tuberculosis

Rayen Lahouar, Badreddine Ben Khalifa, Najib Ebbey Baba, Wael Gazzah, ... Rafik El Kamel
Pages 769-772

[Download PDF](#) Article preview 

Case report ● *Open access*

Single lung resection: The limits of the possible. Clinical report

Dmitry B. Giller, Jens C. Rückert, Boris B. Giller, Oleg Sh. Kesaev, ... Galina V. Scherbakova
Pages 773-777

[Download PDF](#) Article preview 

Case report ● *Open access*

Hypofertility in a persistence of mullerian duct syndrome: Case report

Issam Jandou, Tarik Mhanna, Mehdi Chennoufi, Mohamed Aynaou, ... Ali Barki
Pages 778-781

[Download PDF](#) Article preview 

Case report ● *Open access*

Complex anal fistula: A case report

Hui Wang, BingYuan Fei, HongYong Jin
Pages 782-786

[Download PDF](#) Article preview 

Case report ● *Open access*

Case report: Hybrid approach in the management of a complete persistent sciatic artery aneurysm

Andrew Yang, Ammar Hashmi, Anton Androsov, Gregory Salzler, Evan Ryer
Pages 787-790

[Download PDF](#) Article preview 

Case report ● *Open access*

Metastatic Papillary Renal Cell Carcinoma in a 13-Year Old Girl: A Case Report and Review of the Literature Mainly Focusing on Treatment and Prognosis

James J. Yahaya, Nicholas Bartholomew, Alex Mremi
Pages 791-794

[Download PDF](#) Article preview 

Case report ● *Open access*

Cervical necrotizing fasciitis by dental abscess treated with negative pressure wound therapy: Case report

Veronica L. Campana, Federico M. Braun, Carina Giuliani
Pages 795-798

[Download PDF](#) Article preview 

Case report ● *Open access*

Chylous ascites: Case report of a rare presentation of blunt abdominal trauma

Vânia Fernandes, Jacinta Queirós, Carlos Soares

Pages 799-802

[Download PDF](#) Article preview 

Case report ● *Open access*

Multiple intestinal perforations due to primary mediastinal B-cell lymphoma: A case with an infrequent extra-nodal presentation

René M. Palacios Huatuco, Diana A. Pantoja Pachajoa, Agustín E. Pinsak, Mario L. Salvano, ... Facundo I. Mandojana

Pages 803-808

[Download PDF](#) Article preview 

Case report ● *Open access*

Giant diverticulum of the transverse colon mimicking gastrocolic fistula: A case report

Imam Sofii, Amal Fathullah Pua Upa, Gunadi

Pages 809-812

[Download PDF](#) Article preview 

Case report ● *Open access*

Triorchidism; an incidental finding at inguinal hernia repair: A case report

Badhaasaa B. Bayissa, Dhugasa Tesfaye

Pages 813-815

[Download PDF](#) Article preview 

Mini review ● *Open access*

Tumor response and the quality of life after isolated hypoxic pelvic perfusion for advanced G3 cervical cancer: A case series

Karl R. Aigner, Youri Lavinski, Sabine Gailhofer

Pages 816-821

[Download PDF](#) Article preview 

Case report ● *Open access*

Pediatric bronchiectasis: An orphan disease ending in pneumonectomy: A case report

Esubalew Taddese Mindaye, Goytom Knfe Tesfay, Maru Gama Erge

Pages 822-825

[Download PDF](#) Article preview 

Case report ● *Open access*

Soft palate resection and secondary healing not to impair the velopharyngeal function? – Diagnosis and treatment of an intraoral schwannoma: A case report

Lukas Sebastian Fiedler

Pages 826-829

[Download PDF](#) Article preview 

Case report ● *Open access*

Pneumomediastinum and ECG changes during laparoscopic Nissen fundoplication in a child; Case report

Wafa Alshahrani, Jamila Almaary

Pages 830-833

[Download PDF](#) Article preview 

Case report ● *Open access*

Axillary Hibernoma in woman with Lobular breast cancer and MEN1 syndrome: A case report

Giulia Deguidi, Sara Mirandola, Alessia Nottesgar, Vassilena Tsvetkova, ... Francesca Pellini

Pages 834-838

[Download PDF](#) Article preview 

Case report ● *Open access*

Paratubal endosalpingiosis: a case report

Fatemeh Sadat Mahdavi, Mehdi Tavallaei, Arsh Haj Mohamad Ebrahim Ketabforoush, Mahsa Bahadorinia

Pages 839-842

[Download PDF](#) Article preview 

Case report ● *Open access*

Relapsed hip stiffness after recovery of range of motion in a hip treated for developmental dysplasia of the hip?
Think again: A case report

Hasan Alanazi, Faisal Almalik, Naif Alanazi, Thamer Alhussainan

Pages 843-847

[Download PDF](#) Article preview 

Case report ● *Open access*

Alveolar rhabdomyosarcoma of the mandible in an adult invading the parotid gland: A rare case report

Hammouda Yassir, Hicham Ngham, Mouna Lyoubi, Reda Allah Abada, ... Mohammed Mahtar

Pages 848-852

[Download PDF](#) Article preview 

Case report ● *Open access*

Bilateral inguinoscrotal hernia with gastric contents and subsequent perforation: Lessons in operative management

Joseph Heylen, Daniel Campioni-Norman

Pages 853-856

[Download PDF](#) Article preview 

Case report ● *Open access*

The ectopic vesical pheochromocytoma a diagnostic and therapeutic challenge case report and literature review

Issam Jandou, Amine Moataz, Mohammed Hicham Mouqtassid, Mohammed Dakir, ... Rachid Aboutaieb

Pages 857-861

[Download PDF](#) Article preview 

Case report  [Open access](#)

Non operative management of proximal posterior gastric injury in a trauma patient: A case report

Norah Alsubaie, Bushr Mrad, Abdullah Albdah, Nadia Aljomah, Thamer Nouh

Pages 862-865

[Download PDF](#) Article preview 

Case report  [Open access](#)

Large leiomyomatosis peritonealis disseminata after laparoscopic myomectomy: A case report with literature review

Yasunori Yoshino, Naoyuki Yoshiki, Reiko Nakamura, Yuki Iwahara, ... Naoyuki Miyasaka

Pages 866-869

[Download PDF](#) Article preview 

Mini review  [Open access](#)

Emergency orthopaedic surgery in the pandemic era: A case series at Cipto Mangunkusumo national tertiary hospital in Jakarta, Indonesia

Achmad Fauzi Kamal, Wahyu Widodo, Mohamad Walid Kuncoro, I. Wayan Arya Mahendra Karda, ... Anita Happy Rahayu Sitanggang

Pages 870-874

[Download PDF](#) Article preview 

Case report  [Open access](#)

Sigmoid volvulus in a teenager, successfully managed with endoscopic detorsion: An unusual case report and review of the literature

Habib Ahmad Esmat

Pages 875-879

[Download PDF](#) Article preview 



ELSEVIER



International Journal of Surgery Case Reports

Editor-in-Chief

Professor David Rosin, Barbados, West Indies

Managing and Executive Editor

Dr Riaz Agha, London, UK

Assistant Managing Editor

Maliha Agha, London, UK

Senior Editors

Professor Hasan Alam, Michigan, USA
Professor Raafat Afifi, Cairo, Egypt
Dr Juan Barret, Barcelona, Spain
Mr Ben Challacombe, London, UK
Dr Xiaio-ping Chen, Wuhan, China

Dr Burcin Ekser, Indianapolis, USA
Professor Joseph W Y Lau, Shatin, Hong Kong
Dr Oliver Muensterer, New York, USA
Dr Selwyn Rogers, Galveston, Texas
Professor Jamsheer Talati, Karachi, Pakistan

Dr Mangesh Thorat, London, UK
Professor Fu Chan Wei, Tapei, Taiwan
Professor Rudy Leon De Wilde, Oldenburg, Germany

Associate Editors

Professor Roberto Coppola, Rome, Italy
Dr Veerappan Kasivisvanathan, London, UK
Dr Richard Keijzer, Winnipeg, Canada, USA
Dr Boris Kirshtein, Beer Sheva, Israel

Professor James McCaul, London, UK
Miss Emma McGlone, London, UK
Dr Dattatraya Muzumdar, Mumbai, India
Professor Andy Petroianu, Minas Gerais, Brazil

Mr Shahzad Raja, London, UK
Dr Kandiah Raveedran, Ipoh, Malaysia
Dr Daniel Yeh, Boston, USA

Assistant Editors

Dr Rafid Al-Mahfoudh, Oxford, UK
Dr Hussein Atta, Boston, USA
Dr Mohammad Bashashati, Texas, USA
Professor Somprakus Basu, Varanasi, India
Mr Andrew Beamish, Cardiff, UK
Dr Anthony Charles, North Carolina, USA
Dr Amitava Das, Hyderabad, India
Dr Brian Davis, Texas, USA
Dr Susana Adriana Esquivel, Córdoba, Mexico
Professor Sheng Feng, Shanghai, China

Dr Juan Gomez Rivas, Madrid, Spain
Dr Satoshi Ieiri, Kagoshima City, Japan
Dr Haytham Kaafarani, Massachusetts, USA
Dr Yogeesh Kamat, Karnataka, India
Mr Omar Khan, London, UK
Prof. Tsuyoshi Konishi, Osaka, Japan
Dr Vito A Mannacio, Naples, Italy
Dr Todd Manning, Oxford, UK
Dr Zubing Mei, Shanghai, China
Dr Umesh Metkar, Beth, Israel

Dr Indraneel Mukherjee, Staten Island, USA
Dr Enyi Ofo, Adelaide, South Australia
Dr Lena Perger, Albuquerque, USA
Professor Prathamesh S Pai, Mumbai, India
Dr Alfredas Smailys, Kaunas, Lithuania
Prof. Peter Hyunsuk Suh, Seoul, South Korea
Dr Dieter Weber, Perth, Australia
Dr John Wee, Boston, USA
Dr Honggyi Zhu, Shanghai, China

Statistical Editors

Dr Derek Cooper, London, UK
Professor Nora Donaldson, Colombia, South America
Professor Mary W Gray, Washington DC, USA

Society Representative

Deniz Balci, Representative of the International Society of Liver Surgeons
Rhiannon Harries, President, Association of Surgeons in Training
Gene F. Coppa, President of the New York Surgical Society
Xiao-ping Chen, President of the Chinese Chapter of International Hepato-Pancreato-Biliary Association

Social Media Editor

Dr Riaz Agha, London, UK

Assistant Commissioning Editors

Ahmed Al-Jabir, London, UK
Zaid Alsafi, London, UK
Thomas Franchi, Sheffield, UK
Christos Iosifides, London, UK

Ahmed Kerwan, London, UK
Mehdi Khan, London, UK
Ginimol Matthew, London, UK
Maria Nicola, London, UK

Niamh O'Neill, London, UK
Catrin Sohrabi, London, UK

Executive Committee

Professor David Albala, New York, USA
Sir Graeme Catto, London, UK
Professor David Cooper, Pittsburgh, USA
Lord Ara Darzi, London, UK
Professor Harold Ellis, London, UK
Ather Enam, Karachi, Pakistan

Sir Barry Jackson, London, UK
Professor Arthur Li Kwok-Cheung, Wanchai, Hong Kong
Professor C H Leong, Central, Hong Kong
Lord Ian McColl, London, UK

John Norcini, Philadelphia, USA
Professor Susan Standing, London, UK
Lord Robert Winston, London, UK
Sir Magdi Yacoub, London, UK

Editorial Board

Raj Badwe
Mumbai, India
Michael Boscoe
Middlesex, UK
Rapheal Bueno
Boston, USA
Kris Chatamra
Bangkok, Thailand
Paul Coulthard
Manchester, UK
Anil d' Cruz
Mumbai, India
Mahesh Desai
Mumbai, India
Juan Gomez Rivas
Spain, Madrid

David W. Green
London, UK
Iraj Harirchi
Tehran, Iran
Doris Henne-Bruns
Ulm, Germany
Delawir Kahn
Cape Town, South Africa
Xiaoxi Lin
Shanghai, China
Ashok Mahapatra
New Delhi, India
Todd Manning
Melbourne, Australia
Indraneel Mittra
Mumbai, India

Vijay Naraynsingh
West Indies
Fabio Nicoli
London, UK
Anibal R. Núñez De Pierro
Buenos Aires, Argentina
Reuben Orda
Tel Aviv, Israel
Vladimir Semiglazov
St. Petersburg, Russia
Tejinder Singh
Ludhiana, India
Barbara L. Smith
Boston, USA
James Tatum
California, USA

Tehemton Udwadia
Mumbai, India
Martin R. Weiser
New York, USA
Yixin Zhang
Shanghai, China
Jun Zhong
Shanghai, China
Zhao-Fan Xia
Shanghai, China

Elsevier

Executive Publisher
Ash Allan, Oxford, UK
Administrative Editor
Josie Hutchins, Oxford, UK
Marketing Manager
Jayne Dawkins, Philadelphia, USA

Journal Manager
Tamsyn Hopkins, Exeter, UK
Senior Business Development Executive (Reprints)
Emma Steel, London, UK
Advertising Sales Manager
Robert Bayliss, London, UK

Account Manager (Supplements)
Evelina Euren, Amsterdam, the Netherlands
Project Manager Supplements & E-business
Mónica Hernández-Sesma, Amsterdam, the Netherlands



Case Series

Vim line technique thalamotomy for Parkinson tremor: Case series

Achmad Fahmi^{a,*}, Heri Subianto^b, Priya Nugraha^c, Muhammad Hamdan^c, Asra Al Fauzi^b,
 Anggraini Dwi Sensusiaty^d, Budi Utomo^e, Riyanarto Sarno^f, Agus Turchan^b,
 Mohammad Hasan Macfoed^c, Takaomi Taira^g, Abdul Hafid Bajamal^b

^a Post Graduate Doctoral Program, Faculty of Medicine, Universitas Airlangga, Surabaya, Indonesia

^b Department of Neurosurgery, Faculty of Medicine, Universitas Airlangga, Surabaya, Indonesia

^c Department of Neurology, Faculty of Medicine, Universitas Airlangga, Surabaya, Indonesia

^d Department of Radiology, Faculty of Medicine, Universitas Airlangga, Surabaya, Indonesia

^e Department of Public Health and Preventive Medicine, Faculty of Medicine, Universitas Airlangga, Surabaya, Indonesia

^f Department of Informatics, Institut Teknologi Sepuluh Nopember, Surabaya, Indonesia

^g Department of Neurosurgery, Tokyo Women's Medical University Hospital, Tokyo, Japan



ARTICLE INFO

Article history:

Received 30 October 2020

Received in revised form

16 November 2020

Accepted 16 November 2020

Available online 20 November 2020

Keywords:

Parkinson tremor

Thalamotomy

Vim line technique

ABSTRACT

INTRODUCTION: The ventral intermediate (Vim) nucleus of the thalamus is difficult to identify even with 3 T magnetic resonance imaging. Stereotactic Vim thalamotomy is a usual procedure to control Parkinson tremor. Successful relieving of the tremor depends on the accuracy of defining the Vim location.

PRESENTATION OF CASES: Three patients with Parkinson tremor were subjected to stereotactic thalamotomy using the Vim line technique (VLT) so as to precisely determine the Vim location. All patients showed good results, with improved tremors, as indicated by the UPDRS score, without any complications.

DISCUSSION: The precise targeting of the Vim nucleus is crucial importance for the successful Vim thalamotomy. Various method has been developed to determine Vim location. Atlas based and Guiot's technique routinely used by neurosurgeon. VLT is a new technique that has been developed to determine the Vim location on MRI.

CONCLUSION: VLT is useful for the determination of the Vim location. However, further research is warranted to prove its effectiveness.

© 2020 The Authors. Published by Elsevier Ltd on behalf of IJS Publishing Group Ltd. This is an open access article under the CC BY license (<http://creativecommons.org/licenses/by/4.0/>).

1. Introduction

Ventral intermediate (Vim) nucleus of the thalamus is reputed to be 'invisible' on the routinely available imaging techniques. Currently, there exists several hypotheses related to the estimation of the Vim location [6]. The use of magnetic resonance imaging (MRI) to identify critical structures near the stereotactic targets is crucial. The optic tract, internal segment of the globus pallidus, border between the Vim nucleus of the thalamus and the internal capsule must be evaluated precisely before some serious surgeries [5].

Several different surgical procedures have been proposed for the treatment of essential tremor, including deep brain stimulation (DBS), radiofrequency thalamotomy, gamma knife radio surgical thalamotomy and focused ultrasound thalamotomy [1]. Stereo-

tactic lesioning surgeries such as thalamotomy and pallidotomy have been performed to control movement disorders. The thalamic Vim nucleus is a usual target for controlling the tremor. Tremor-dominant hemi-Parkinson's disease (PD) is a good indication of Vim thalamotomy, especially when tremor is a major complaint [5]. Some techniques have been developed to define the Vim location. For instance, the Guiot's technique uses 3/12 or 4/12 anterior from posterior commissure (PC) in anterior commissure-PC (AC-PC) line [6]. The coordinate base uses the brain atlas to define the Vim location [2]. New techniques are hence required to develop variation of the brain anatomy. Improvement after Vim thalamotomy in the control of tremor ranges between 74% and 90% [1]. VLT did not interfered by this variation. VLT can be used by neurosurgeons to determined the Vim location, including in different anatomical variation of the brain. Using VLT to determine Vim location should increase the outcome that can be measured by Unified PD Rating Scale (UPDRS) score. However, there is insufficient evidence to support or refute efficacy superiority of DBS or thalamotomy for treating essential tremor [7]. All of the procedures performed by the authors in this study involving human

* Corresponding author at: Post Graduate Doctoral Program, Faculty of Medicine Universitas Airlangga, Dr. Soetomo General Academic Hospital, Jalan Mayjend Prof. Dr. Moestopo No. 6 - 8, Surabaya, 60286, Indonesia.

E-mail address: achmad.fahmi-13@fk.unair.ac.id (A. Fahmi).

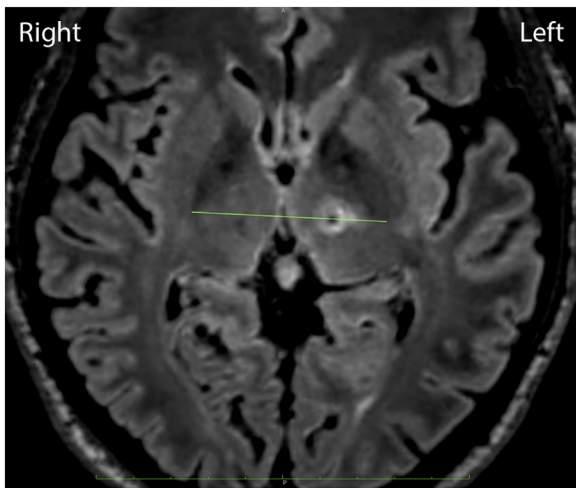


Fig. 1. Left side thalamotomy in the Vim line connecting the posterior tips of both the external globus pallidus in the AC-PC plane, 1.5-mm medial from the cerebrospinal tract border.

participants were in accordance with the ethical standards of the institutional research committee. This work has been reported in line with the PROCESS guideline [8]. This work has been registered at <http://www.researchregistry.com> (researchregistry6183).

1.1. Presentation of cases

1.1.1. Case 1

A 30-year-old man presented with tremor in his right hand and a stiffness at his right side of the body. He was diagnosed with PD since the past 5 years and was receiving oral medication (L-dopa, trihexyphenidyl, pramipexole and ropinirole), but the tremor continued to recur.

The MRI and computerized tomography (CT) of the head is performed before conducting stereotactic surgery. The patient's UPDRS before surgery was ON 6 and OFF 33. The patient consented to undergo left Vim thalamotomy by the Vim line technique (VLT) using the *Cosman G4* radiofrequency system (electrode active tip 4 mm, diameter 1.1 mm, 70 °C for 30 s) (Fig. 1). Evaluation after surgery revealed that tremor in the right hand and the stiffness of the right side of the body had improved. The patient's UPDRS score after surgery was ON 0 and OFF 7.

1.1.2. Case 2

A 59-year-old woman presented with a tremor at her left and right sides of the body. The left side tremor was dominant since past 15 years and the right side tremor since past 3 years. She also complained of rigidity and bradykinesia. Patient had ON-OFF response to oral medications (L-dopa, trihexyphenidyl, pramipexole and ropinirole).

The patient's head MRI and CT scan were performed before the stereotactic surgery. Her UPDRS score before the surgery was ON 15 and OFF 41. The patient consented to undergo the right Vim thalamotomy with VLT using the *Cosman G4* radiofrequency system (electrode active tip 4 mm, diameter 1.1 mm, 70 °C for 30 s) (Fig. 2). Her evaluation after the surgery revealed that the tremor in the left side of the body had improved. Her UPDRS score after the surgery was ON 0 and OFF 7.

1.1.3. Case 3

A 57-year-old man presented with tremor in the left hand since the past 2 years. He had undergone left Vim thalamotomy 4 years ago for his right-side tremor. His head MRI and CT scan were performed before the stereotactic surgery. His UPDRS score

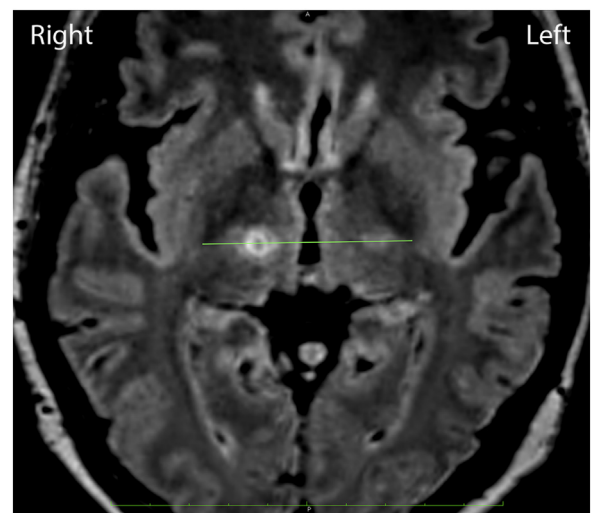


Fig. 2. Right-side thalamotomy in the Vim line connecting the posterior tips of both the external globus pallidus in the AC-PC plane, 1.5-mm medial from the cerebrospinal tract border.

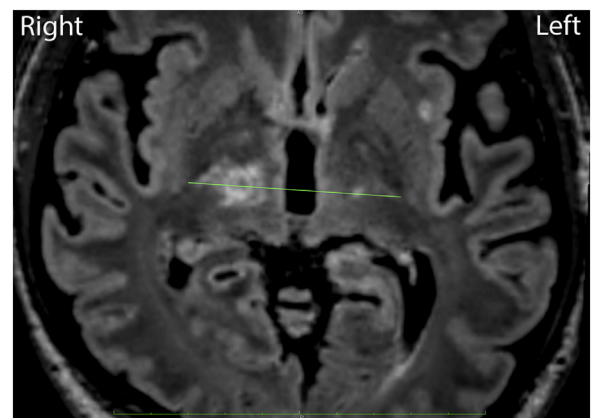


Fig. 3. Left-side thalamotomy in the Vim line connecting the posterior tips of both the external globus pallidus in the AC-PC plane, 1.5-mm medial from the cerebrospinal tract border.

before the surgery was ON 13 and OFF 42 with oral medications (L-dopa, trihexyphenidyl, pramipexole and ropinirole). He consented to undergo right Vim thalamotomy with VLT using the *Cosman G4* radiofrequency system (electrode active tip 4 mm, diameter 1.1 mm, 70 °C for 30 s) (Fig. 3). His evaluation after the surgery revealed that the tremor in the left hand had improved. His UPDRS score after the surgery was ON 4 and OFF 23.

2. Discussion

Thalamic stimulation and thalamotomy are equally effective in reducing drug resistant tremor, and stimulation has only a few adverse effects. The efficacy of stimulation ranges from 71% to 94% in PD patients and from 74% to 90% for essential tremor [1,4]. In patients with bilateral tremor, thalamic stimulation in the dominant hemisphere can be combined with thalamotomy for the non-dominant hemisphere; however, morbidity associated with thalamotomy probably outweighs any advantage of this approach [3].

The precise targeting of the Vim nucleus is crucial importance for the successful Vim thalamotomy. Targeting is usually conducted by using stereotactic coordinates that are specified in relation to a point on the AC-PC line based on the brain atlas or intraoper-

active stimulation techniques, although these methods sometimes need modification based on the anatomical brain variation. Since the identification of the thalamic nuclei on conventional imaging modalities is difficult, recently, MRI tractography was successfully used to investigate the dentatorubrothalamic tract that crosses the Vim nucleus [2]. Some of the stereotactic planning software available presently do not have the tractography facility.

VLT is a new technique that has been developed to determine the Vim location on MRI. This technique is suitable for any brain anatomical variation. This technique is performed by drawing a line that connects both the external globus pallidus posterior tips in the AC-PC plane. The Vim location is defined in 1.5-mm medial area from the cerebrospinal tract area border. Vim thalamotomy done with VLT using the *Cosman* G4 radiofrequency system (electrode active tip 4 mm, diameter 1.1 mm, 70 °C for 30 s).

A past study has reported improvement in the UPDRS scores in the long-term evaluation after Vim thalamotomy [4]. We noted symptom improvement in our cases as depicted by their UPDRS scores. Sixth months follow up of UPDRS were examined by same neurologist at the same hospital with constant score.

3. Conclusion

Our results depict that stereotactic thalamotomy using VLT can be used to determine the Vim location as a useful approach to reduce or control tremor in PD patients. However, further research is warranted to prove the effectiveness of the proposed approach.

Declaration of Competing Interest

The authors report no declarations of interest.

Sources of funding

None.

Ethical approval

This research had ethical clearance from Dr. Soetomo General Academic Hospital Ethical Committee (No.1619/KEPK/XI/2019).

Consent

Written informed consent was obtained from the patient for publication of this case report and accompanying images. A copy of the written consent is available for review by the Editor-in-Chief of this journal on request.

Author contribution

Achmad Fahmi, MD, PhD: study concept or design, data collection, writing the paper.

Heri Subianto, MD: data collection.

Priya Nugraha, MD: data analysis.

Muhammad Hamdan, MD, PhD: Supervising.

Asra Al Fauzi MD, PhD: study concept.

Anggraini Dwi Sensusiaty MD, PhD: critical revised article.

Budi Utomo MD, PhD: data analysis or interpretation.

Prof. Riyanarto Sarno: critical revised article.

Prof Takaomi Taira: supervising.

Agus Turchan MD, PhD: supervising.

Prof. Mohammad Hasan Macfoed: supervising.

Prof. Abdul Hafid Bajamal: supervising.

Registration of research studies

1. Name of the registry: <http://www.researchregistry.com>
2. Unique identifying number or registration ID: researchregistry6183
3. Hyperlink to your specific registration (must be publicly accessible and will be checked): n/a

Guarantor

Achmad Fahmi, MD, Ph.D.

Post Graduate Doctoral Program, Faculty of Medicine, Universitas Airlangga, Indonesia.

Agus Turchan, MD, PhD.

Head of Neurosurgery Department, Faculty of Medicine, Universitas Airlangga, Indonesia.

Provenance and peer-reviewed

Not commissioned, externally peer-reviewed.

Acknowledgments

Our acknowledgments to Dr. Soetomo General Academic Hospital and National Hospital, Surabaya, Indonesia, where the surgeries were performed.

References

- [1] R.F. Dallapiazza, D.J. Lee, P. De Vloo, A. Fomenko, C. Hamani, M. Hodaie, S.K. Kalia, A. Fasano, A.M. Lozano, Outcomes from stereotactic surgery for essential tremor, *J. Neurosurg. Neurosurg. Psychiatry* 90 (4) (2019) 474–482.
- [2] Z.T. Kincses, N. Szabó, I. Valálik, Z. Kopniczky, L. Dézsi, P. Klivényi, M. Jenkinson, A. Király, M. Babos, E. Vörös, P. Barzó, L. Vécsei, Target identification for stereotactic thalamotomy using diffusion tractography, *PLoS One* 7 (1) (2012), e29969.
- [3] P.R. Schuurman, D.A. Bosch, P.M. Bossuyt, G.J. Bonsel, E.J. van Someren, R.M. de Bie, M.P. Merkus, J.D. Speelman, A comparison of continuous thalamic stimulation and thalamotomy for suppression of severe tremor, *N. Engl. J. Med.* 342 (7) (2000) 461–468.
- [4] P.R. Schuurman, D.A. Bosch, M.P. Merkus, J.D. Speelman, Long-term follow-up of thalamic stimulation versus thalamotomy for tremor suppression, *Mov. Disord.* 23 (8) (2008) 1146–1153.
- [5] T. Taira, S. Horisawa, N. Takeda, P. Ghate, Stereotactic radiofrequency lesioning for movement disorders, *Prog. Neurol. Surg.* 33 (2018) 107–119.
- [6] F. Vassal, J. Coste, P. Derost, V. Mendes, J. Gabrillargues, C. Nuti, F. Durif, J.J. Lemaire, Direct stereotactic targeting of the ventrointermediate nucleus of the thalamus based on anatomic 1.5-T MRI mapping with a white matter attenuated inversion recovery (WAIR) sequence, *Brain Stimul.* 5 (4) (2012) 625–633.
- [7] T.A. Zesiewicz, R.J. Elble, E.D. Louis, G.S. Gronseth, W.G. Ondo, R.B. Dewey Jr., M.S. Okun, K.L. Sullivan, W.J. Weiner, Evidence-based guideline update: treatment of essential tremor: report of the Quality Standards Subcommittee of the American Academy of Neurology, *Neurology* 77 (19) (2011) 1752–1755.
- [8] R.A. Agha, M.R. Borrelli, R. Farwana, K. Koshy, A.J. Fowler, D.P. Orgill, SCARE Group, The PROCESS 2018 statement: updating consensus Preferred Reporting Of Case Series in Surgery (PROCESS) guidelines, *Int. J. Surg.* 60 (2018) 279–282.

Open Access

This article is published Open Access at [sciencedirect.com](https://www.sciencedirect.com). It is distributed under the [IJSCR Supplemental terms and conditions](#), which permits unrestricted non commercial use, distribution, and reproduction in any medium, provided the original authors and source are credited.