

Article submitted

External

Inbox



Polish Journal of Veterinary Sciences noreply <pjvs@uwm.edu.pl>

Jul 16,
2021,
8:47 PM

to me



Dear Dr. M.Sc. DVM Epy Muhammad Luqman (epy),

Thank you for submitting your manuscript entitled "Effect of kebar grass extract (Biophytum petersianum klotzch) on histopathological of mice offspring liver (Mus musculus) from the parent exposed to carbofuran during lactation periode " to Polish Journal of Veterinary Sciences. Your assigned manuscript number is 1505-pjvs-2021.

We will now begin processing your manuscript and may contact you if we require any further information. You can also check the status of your manuscript by logging into your account at <http://spjvs.uwm.edu.pl/index/login>.

Thank you for submitting your manuscript to PJVS.

Kind regards,
Editors Polish Journal Of Veterinary Sciences

Remember:

If You want to log in always use the username: "epy".

Link: <http://spjvs.uwm.edu.pl/index/login>

If You don't remeber password you can change it here: <http://spjvs.uwm.edu.pl/index/remindpassword>

© Polish Journal of Veterinary Sciences and University of Warmia and Mazury in Olsztyn - 2021

Article needs to be improved

External

Inbox



Polish Journal of Veterinary Sciences noreply <pjvs@uwm.edu.pl>

Nov 7,
2021,
1:51 AM

to me



You received a review of your articles [Effect of kebar grass extract \(Biophytum petersianum klotzch\) on histopathological of mice offspring liver \(Mus musculus\) from the parent exposed to carbofuran during lactation periode](#). Log in to your account to view full review

Review:

- no comments -

Comment:

Dear Author, Thank you for submitting your manuscript to Polish Journal of Veterinary Sciences. The review of your paper indicates that this manuscript requires a major revision. We invite you to submit a revised version of the manuscript that addresses all the points raised by the Reviewers. We encourage you to submit your revision within twenty days (or even faster) of the date of this decision. Do not submit a revised manuscript as a new submission. Please include all the required corrections (by logging on your profile and clicking "CORRECT" button in the panel "ARTICLES"). To replace the particular file you have to delete from the system the old version of the file (by clicking DELETE near by the particular file) and then upload the improved version of the file. Replace ONLY files that have been changed. Before uploading improved files, you should proofread your manuscript very closely for mistakes and grammatical errors. Additionally, you have to write a response for EACH review (by clicking "YOU HAVE TO WRITE RESPONSE TO A REVIEW" in the panel "ARTICLES"). Subsequently, please send back your improved version of the article by clicking button "SEND BACK TO OFFICE" in the panel "ARTICLES". Then YOU HAVE to click "SUBMIT YOUR ARTICLE" in the pop-up window of the optional comments. Sincerely, Michal Zalecki PJVS Associate Editor

Remember:

If You want to log in always use the username: "epy".

Link: <http://spjvs.uwm.edu.pl/index/login>

If You don't remeber password you can change it here: <http://spjvs.uwm.edu.pl/index/remindpassword>

© Polish Journal of Veterinary Sciences and University of Warmia and Mazury in Olsztyn - 2021

The screenshot shows the author's dashboard for the Polish Journal of Veterinary Sciences. At the top, there is a navigation bar with the journal logo and user options like 'LOG ME OUT' and 'EDIT PROFILE'. The main content area is titled 'LIST OF ALL ARTICLES' and includes a search bar. Below this, there is a table of articles with the following columns: STATUS, REVIEWERS, ACTIONS, and ID. Two articles are listed:

STATUS	REVIEWERS	ACTIONS	ID
Rejected	See review Rejected by reviewer	Comments (1/2) Details	1505-pjvs-2021
Archived	no review yet or reviews in archive	Comments (3/3) Details	1505-pjvs-2021

The dashboard also includes a 'Back to article list' button and a copyright notice at the bottom: © 2021 Polish Journal of Veterinary Sciences and University of Warmia and Mazury in Olsztyn.

Other authors:

- DVM Nonik Ayu Yulitasari (N.Ayu Yulitasari)
- Prof. Dr. DVM, MSc Sri Hidayati (S.Hidayati)
- Prof. Dr. DVM, MSc Widjati Widjati (W.Widjati)
- MSc, DVM Viski Fitri Hendrawan (V.Fitri Hendrawan)
- Dr. M.Sc. DVM Epy Muhammad Luqman (epy)

Categories: Preclinical Sciences

Dolączone pliki

LOGS:

13 December 2021 (Monday)

- 00:52 Article was sent to the editor.
- 00:32 Editor sent article to author

7 December 2021 (Tuesday)

- 06:46 Article translation corrected by author.
- 06:44 You modified the article .

6 December 2021 (Monday)

- 13:33 You modified the article .

5 December 2021 (Sunday)

- 08:52 You modified the article .
- 07:00 You modified the article .
- 06:56 You modified the article .
- 06:53 You modified the article .

4 December 2021 (Saturday)

- 13:31 You modified the article .
- 13:18 You modified the article .
- 01:11 You modified the article .
- 01:01 You modified the article .
- 00:57 You modified the article .
- 00:45 You modified the article .
- 00:44 You modified the article .
- 00:32 You modified the article .
- 00:30 You modified the article .
- 00:24 You modified the article .
- 00:21 You modified the article .

Can you suggest changes or brief additions (word, phrases) that will increase the value of this paper for an international audience? See comments

COMMENTS

Dear Authors, In my opinion, this work needs many corrections: - the Titel: ... on histological changes of mice offsprings or histological status of mice offsprings..... - maybe in the title: A preliminary study.? - klotzsch or Klotzsch? - seven groups of mice, but how many mice in groups? - we no need the list of all equipment (....scalpels, surgical scissors..), - in the description for figure 3 please change Arteria instead Arteri - please change the title in position 3 of references: Semin Cell Dev Biol instead Seminars in Cell & Developmental Biology. - please change the title in position 7 of references: J Toxicol Environ Health instead Journal of Toxicology and Environmental Health - please write the title of the journal for position 8 in the list of references (In my opinion, Oxidative Medicine?). - the sixth line from the end line in the manuscript: Tochoferol or Tocopherol? I think that the conclusions are not adequate for results - only on histopathological view. More attractive would be an additional demonstration of the biochemical status of the liver (blood biochemistry and the liver enzymes levels). Regards SD

© 2021 Polish Journal of Veterinary Sciences and University of Warmia and Mazury in Olsztyn.

Rebuttal Letter

Surabaya Indonesia, Nopember 7, 2021
 Polish Journal of Veterinary Sciences
 Editorial Office

I am submitting a revision of manuscript entitled "Effect of kebar grass extract (*Biophytum petersianum Klotzsch*) on histopathological changes of mice offspring liver (*Mus musculus*) from

the parent exposed to carbofuran during lactation period” (manuscript number is 1505-pjvs-2021). I had corrected manuscript according the reviewer comment (red color text):

1. I have changed the title to “Effect of kebar grass extract (*Biophytum petersianum* Klotzsch) on histopathological changes of mice offspring liver (*Mus musculus*) from the parent exposed to carbofuran during lactation period” (page 1)
2. I have changed the word *klotzsch* to *Klotzsch* (all words in the manuscript).
3. I have added in the abstract and method section: the number of mice in each group (six mice per group)
4. I have removed all the equipment used in the research (....scalpels, surgical scissors..)
5. I have changed the description figure 3: Arteria to Arteri
6. I have changed the title in position 3 of references: Seminars in Cell & Developmental Biology to Semin Cell Dev Biol.
7. I have changed the title in position 7 of references: Journal of Toxicology and Environmental Health to J Toxicol Environ Health
8. I have added the title of the journal for position 8 (ISRN Oxidative Medicine)
9. I have changed Tochoferol to Tocopherol (the sixth line from the end line)
10. I have changed the conclusion according to the research results.
11. I welcome the good advice of adding the biochemical status of the liver (blood biochemistry and the liver enzymes levels) in future research.

Yours Sincerely,

Dr. Epy Muhammad Luqmqn, M.Sc., DVM
Department of Veterinary Science,
Faculty of Veterinary Medicine,
Kampus C Universitas Airlangga,
Jl. Mulyorejo Surabaya 60115, Indonesia.
Tel.: +62315992785; Fax: +62315993015
Email: epy-m-l@fkh.unair.ac.id

2021-11-16 14:05:59

Dear Author, The second review of your paper indicates that this manuscript requires a revision. We invite you to submit a revised version of the manuscript that addresses all the points raised by the Reviewers. We encourage you to submit your revision within twenty days (or even faster) of the date of this decision. Do not submit a revised manuscript as a new submission. Please include all the required corrections (by logging on your profile and clicking “CORRECT” button in the panel “ARTICLES”). To replace the particular file you have to delete from the system the old version of the file (by clicking DELETE near by the particular file) and then upload the improved version of the file. Replace ONLY files that have been changed. Before uploading improved files, you should proofread your manuscript very closely for mistakes and grammatical errors. Additionally, you have to write a response for EACH review (by clicking “YOU HAVE TO WRITE RESPONSE TO A REVIEW” in the panel “ARTICLES”). Subsequently, please send back your improved version of the article by clicking button “SEND BACK TO OFFICE” in the panel “ARTICLES”. Then YOU HAVE to click “SUBMIT YOUR ARTICLE” in the pop-up window of the optional comments. Sincerely, Michal Zalecki PJVS Associate Editor

2021-11-17 12:02:27

Your article will be published in the Vol. 24 No. 4 (December 2021) of PJVS. PLEASE SEND US DATA NECESSARY TO PREPARE THE INVOICE (SEND IT VIA EMAIL TO barbara.manka@uwm.edu.pl). THE EMAIL HAS TO BE subjected as: INVOICE DATA XXX-PJVS-2021 – VOL 24-4 (XXX = Number of Your Article) AND SHOULD INCLUDE: 1. the number of your manuscript (XXX-PJVS-2021); 2. Volume 24/4 3. the title of the manuscript; 4. the name of the first author; 5. exact name of your institution; 6. exact address; 7. VAT EU number (full, including letters) of your institution (for European countries). In the next step (within a few weeks) you will receive INVOICE via return email from barbara.manka@uwm.edu.pl specifying the publication fee (according to <http://www.uwm.edu.pl/pjvsci/ifa.html>). Remember, that your contribution will appear in upcoming issue of the Polish Journal of Veterinary Sciences PROVIDING the Editorial Office RECEIVES A CONFIRMATION OF THE INFLOW OF THE PUBLICATION FEE to the journal bank account. THE BANK TRANSFER IS THE ONLY PAYMENT OPTION! Please note that the transfer/manipulation fees are also to be covered by the authors. Kind regards, Michal Zalecki, PJVS Associate Editor

Surabaya Indonesia, Nopember 17, 2021

Polish Journal of Veterinary Sciences

Editorial Office

I am submitting a revision of manuscript entitled "**Effect of kebar grass extract (*Biophytum petersianum* Klotzsch) on histopathological changes of mice offspring liver (*Mus musculus*) from the parent exposed to carbofuran during lactation period**" (manuscript number is 1505-pjvs-2021). I had corrected the manuscript:

1. I have changed whole text (including reference list) be written in DOUBLE SPACED Times New Roman 12 pts fonts.
2. I have checked carefully the journal title abbreviations used in "References" were consistent with those used by popular scientific data bases, e.g. PubMed.
3. Saya telah mengikuti dengan ketat (setiap titik atau koma) instruksi untuk penulis yang tersedia di www.uwm.edu.pl/pjvsci/ifa.html.
4. I have visited your Open Access platform (<http://journals.pan.pl/pjvs/128347>) to download an article and use it as a pattern.

Yours Sincerely,

Dr. Epy Muhammad Luqmqn, M.Sc., DVM

Department of Veterinary Science,

Faculty of Veterinary Medicine,

Kampus C Universitas Airlangga,

Jl. Mulyorejo Surabaya 60115, Indonesia.

Tel.: +62315992785; Fax: +62315993015

Email: epy-m-l@fkh.unair.ac.id

2021-12-07 06:46:44

Surabaya Indonesia, December 4, 2021 Polish Journal of Veterinary Sciences Editorial Office I am submitting a revision of manuscript entitled "**Effect of kebar grass extract (*Biophytum petersianum* Klotzsch) on histopathological changes in liver of mice offspring from the parent exposed to carbofuran during lactation period**" (manuscript number is 1505-pjvs-2021). I had corrected the manuscript (red text): 1. I have changed the title to "Effect of kebar grass extract (*Biophytum*

petersianum Klotzsch) on histopathological changes in liver of mice offspring from the parent exposed to carbofuran during lactation period". 2. I have added full address, street name, city and post code. 3. I have changed the punctuation in the sentence, citation according to the PJVS writing guidelines. 4. I've changed and added the word the reviewer suggested (due to exposure to..coming from, manufacture to making, is quite a lot (multicompound) to contains compounds, ability to activity, more effective to higher, participating in to interfering with, stabilize to bind etc. 5. I added a histology scale with 400X magnification. 6. I have checked carefully whether journal title abbreviations used in "References" are consistent with those used by popular scientific databases, e.g. PubMed. 7. I have paid Eur 322 as Article Processing Charges (APC) on November 22, 2021 and I have informed to Barbara Mańka.

Rebuttal Letter

Surabaya Indonesia, December 4, 2021
Polish Journal of Veterinary Sciences
Editorial Office

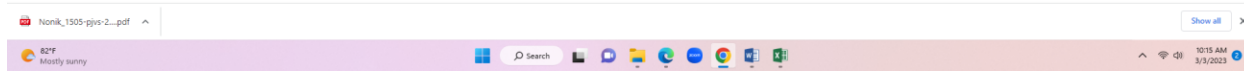
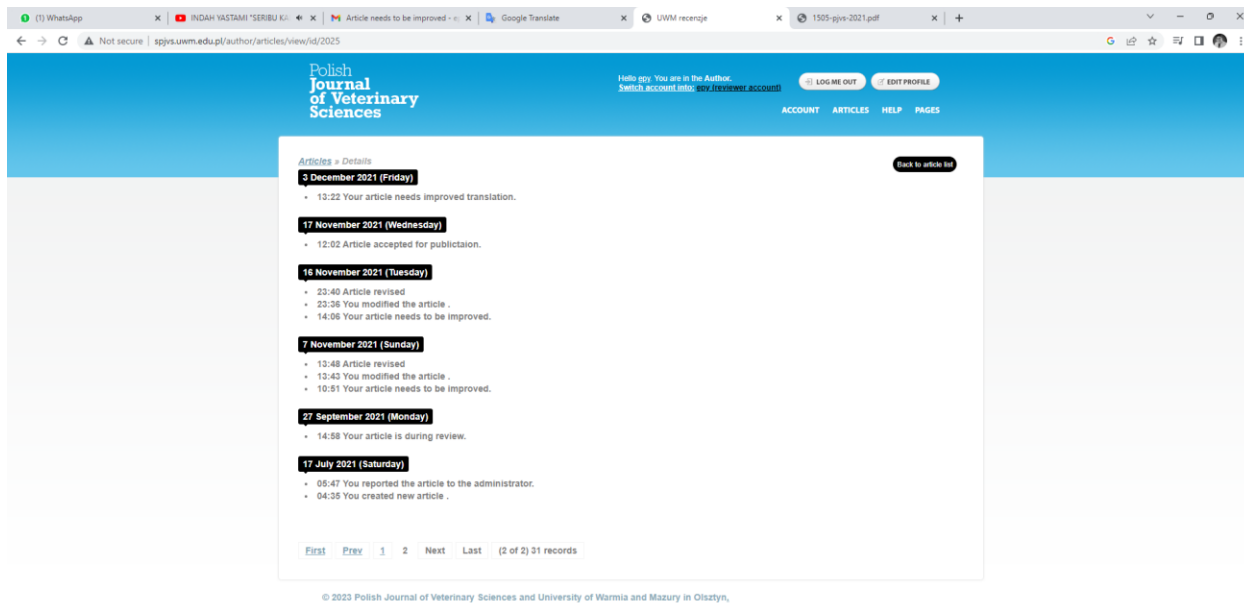
I am submitting a revision of manuscript entitled "**Effect of kebar grass extract (*Biophytum petersianum Klotzsch*) on histopathological changes in liver of mice offspring from the parent exposed to carbofuran during lactation period**" (manuscript number is 1505-pjvs-2021).

I had corrected the manuscript (red text):

1. I have changed the title to "Effect of kebar grass extract (*Biophytum petersianum Klotzsch*) on histopathological changes in liver of mice offspring from the parent exposed to carbofuran during lactation period".
2. I have added full address, street name, city and post code.
3. I have changed the punctuation in the sentence, citation according to the PJVS writing guidelines.
4. I've changed and added the word the reviewer suggested (due to exposure to..coming from, manufacture to making, is quite a lot (multicompound) to contains compounds, ability to activity, more effective to higher, participating in to interfering with, stabilize to bind etc.
5. I added a histology scale with 400X magnification.
6. I have checked carefully whether journal title abbreviations used in "References" are consistent with those used by popular scientific databases, e.g. PubMed.
7. I have paid Eur 322 as Article Processing Charges (APC) on November 22, 2021 and I have informed to Barbara Mańka.

Yours Sincerely,

Dr. Epy Muhammad Luqman, M.Sc., DVM
Department of Veterinary Science,
Faculty of Veterinary Medicine,
Kampus C Universitas Airlangga,
Jl. Mulyorejo Surabaya 60115, Indonesia.
Tel.: +62315992785; Fax: +62315993015
Email: epy-m-l@fkh.unair.ac.id



Article needs to be improved

External

Inbox



Polish Journal of Veterinary Sciences noreply <pjvs@uwm.edu.pl> Tue, Nov 16, 2021, 5:06 AM

to me



You received a review of your articles [Effect of kebar grass extract \(Biophytum petersianum Klotzsch\) on histopathological changes of mice offspring liver \(Mus musculus\) from the parent exposed to carbofuran during lactation period](#). Log in to your account to view full review

Review:

- no comments -

Comment:

Dear Author, The second review of your paper indicates that this manuscript requires a revision. We invite you to submit a revised version of the manuscript that addresses all the points raised by the Reviewers. We encourage you to submit your revision within twenty days (or even faster) of the date of this decision. Do not submit a revised manuscript as a new submission. Please include all the required corrections (by logging on your profile and clicking "CORRECT" button in the panel "ARTICLES"). To replace the particular file you have to delete from the system the old version of the file (by clicking DELETE near by the particular file) and then upload the improved version of the file. Replace ONLY files that have been changed. Before uploading improved files, you should proofread your manuscript very closely for mistakes and grammatical errors. Additionally, you have to write a response for EACH review (by

clicking "YOU HAVE TO WRITE RESPONSE TO A REVIEW" in the panel "ARTICLES"). Subsequently, please send back your improved version of the article by clicking button "SEND BACK TO OFFICE" in the panel "ARTICLES". Then YOU HAVE to click "SUBMIT YOUR ARTICLE" in the pop-up window of the optional comments. Sincerely,
Michal Zalecki PJVS Associate Editor

Remember:

If You want to log in always use the username: "epy".

Link: <http://spjvs.uwm.edu.pl/index/login>

If You don't remember password you can change it here: <http://spjvs.uwm.edu.pl/index/remindpassword>

© Polish Journal of Veterinary Sciences and University of Warmia and Mazury in Olsztyn – 2021

Original article

Effect of kebar grass extract (*Biophytum petersianum Klotzsch*) on histopathological changes in liver of mice offspring from the parent exposed to carbofuran during lactation period

N. A. Yulitasari¹, S. Hidanah¹, Widjiati¹, V. F. Hendrawan², E. M. Luqman¹

¹Department of Veterinary Science Faculty of Veterinary Medicine Universitas Airlangga
Kampus C Unair, Jalan Mulyorejo Surabaya 60115 Indonesia,

²Department of Animal Reproduction Faculty of Veterinary Medicine, Universitas Brawijaya,
Jl. MT. Haryono No.169, Ketawanggede, Lowokwaru, Kota Malang, 65144 Indonesia

Correspondence to: E. M. Luqman, email: epy-m-l@fkh.unair.ac.id

Abstract

This study aims to determine the potential of Kebar grass extract in reducing the impact of liver damage in mice offspring (*Mus musculus*) from parent exposed to carbofuran during lactation period. 42 lactation mice (*Mus musculus*) used in the study were divided into seven groups, each group consisting of six mice. Carbofuran, Kebar grass extract, and vitamin C are administered orally on days 1 to 14 after birth. This group consisted of K (aquadest), P1 (carbofuran 1/4 LD₅₀ 0.0125 mg/day), P2 (carbofuran 1/8 LD₅₀ 0.00625 mg/day), P3 (Kebar grass extract 3.375 mg (0.2 ml) + carbofuran 1/4 LD₅₀), P4 (Kebar grass extract 3.375 mg (0.2 ml) + carbofuran 1/8 LD₅₀), P5 (vitamin C 5 mg (0.2 ml) + carbofuran 1/4 LD₅₀), and P6 (vitamin C 5 mg (0.2 ml) + carbofuran 1/8 LD₅₀). On the 15th day after birth, mice were sacrificed and their liver taken for microscopic examination with *hematoxilin and eosin* staining. The scoring data were analyzed using Kruskal-Wallis and Mann-Whitney test. The result showed significant different (p<0.05) among the treatment groups. Mean of P4 in degeneration is (1.13), necrosis (1.13) and inflammation (0.73), while the mean of P6 in degeneration is (2.20), necrosis (2.73) and inflammation (1.93). The conclusion of this research is giving Kebar grass extract is more effective in reducing degeneration, necrosis and inflammatory cell's infiltration than vitamin C in mice offspring (*Mus musculus*) from parent exposed to carbofuran during lactation period.

Key words: Pesticide stress, carbofuran, Kebar grass extract, lactation period, liver

Introduction

Carbofuran (2,3-dihidro-2, 2-dimethyl, -7benzofuranyl methyl carbamate) is an insecticide from the carbamate group. Carbofuran is most often used and causes many poisoning incidents in humans and animals (Deepak et al. 2011). Otieno et al. (2010) reported that the intensive use of carbofuran can leave residues, contamination, and poison the environment thereby reducing the population of various useful animals.

Oral administration of carbofuran has been shown to stimulate *Reactive Oxygen Species* (ROS) (Luqman et al. 2019). Cell damage by carbofuran is associated with the formation of ROS or free radicals in the body (Jaiswal et al. 2013). Target organ damaged due to the effects of carbofuran is the brain, liver, muscles, and heart (Gupta et al. 1994, Kaur et al. 2006, Rai et al. 2009).

The liver is the largest gland and is a vital organ for humans and animals. The liver is an organ that plays a role in the process of detoxifying the waste products of the metabolism of food substances, drugs, and toxic substances that enter the body (Gibson, 2003). The presence of toxic substances carried in the portal vein bloodstream can cause the liver cells around the portal vessels to experience the most cell damage. The impact of ROS triggers congestion, infiltration of inflammatory cell (inflammation) and necrosis of the liver (Gbadegesin et al. 2013).

The lactation period is a critical period for the development of postpartum individuals because the function and organ systems are still developing so they are more susceptible to disease (Chin et al. 2017). Metabolites in milk coming from insecticides in lactating mothers allow the transmission of toxic substances to children (Keegan et al. 2009). Milk that passes through the digestive system will undergo a process of absorption and will be distributed to all organs of the body including the liver. Therefore toxic substances in milk are thought to cause liver cell damage.

Kebar grass contains flavonoids (Unitly and Inara 2011) and phenolic compounds (Trisetiyono et al. 2019) which function as antioxidants. Phenolic compounds as antioxidants have mechanisms as reducers, free radical scavengers, metal binders, and prevent the formation of singlet oxygen (Sayuti and Rina 2015).

Materials and Methods

The research procedure was conducted according to the permit by testing the code of ethics committee of experimental animals with the number 1.KE.107.06.2019 at the Faculty of Veterinary Medicine, Universitas Airlangga. The research design used was a completely randomized design (CRD) with seven groups. The experimental animals used were mother and mice offspring (*Mus musculus*) Balb/C at the lactation period, aged 0-14 days. The treatment group consisted of seven groups: P0, P1, P2, P3, P4, P5, P6

Materials

The tools used in this study were plastic cages and wire mesh for experimental animal cages, drinking containers, sonde needles, test tubes, and 3 ml syringes. Equipment for the making manufacture of liver histopathological preparations includes object glasses, cover glasses, automatic tissue processor, water bath, hot plate, microtome, and blade. Histology of the liver was assessed using a camera and an Olympus® CX-4 microscope.

The materials used in this study were female mice (*Mus musculus*), Kebar grass (*Biophytum petersianum Klotzsch*) in dry form obtained from the district of Kebar, Papua and the extraction was carried out in the Testing Service Unit of the Faculty of Pharmacy, Universitas Airlangga. Carbofuran (2,3-dihydro -2,2-dimethyl-7-benzofuranol N-methylcarbamate 98%) was obtained from Aldrich Chemistry with Bellstain Registry number 1428746 (Product of USA). Pellet feed for mice, aquadest as a solvent for carbofuran, carbofuran, and vitamin C, drinking water, husks as cage mats, ether, 10% formalin, and alcohol.

Methods

Mice were divided into seven groups, each group consisting of six mice that were: group consisted of K (aquadest), P1 (carbofuran 1/4 LD₅₀ 0.0125 mg/day), P2 (carbofuran 1/8 LD₅₀ 0.00625 mg/day), P3 (Kebar grass extract 3.375 mg (0.2 ml) + carbofuran 1/4 LD₅₀), P4 (Kebar

grass extract 3.375 mg (0.2 ml) + carbofuran 1/8 LD₅₀), P5 (vitamin C 5 mg (0.2 ml) + carbofuran 1/4 LD₅₀), and P6 (vitamin C 5 mg (0.2 ml) + carbofuran 1/8 LD₅₀). On the 15th day after birth, mice offspring were sacrificed and their liver taken for microscopic examination with hematoxilin and eosin staining.

Histopathological preparations

Counting the number of hepatocyte damaged for each treatment group was done in five different fields of view in each histopathological preparation. Microscopic observation of hepatocytes in histopathological preparations was done using a 400X magnification of Olympus® CX-23 microscope. Observations were made by counting the number of degenerations, necrosis and infiltration of inflammatory cells. Calculation of each field of view in one preparation is summed, then averaged, then statistically analyzed.

Data Analysis

The data that has been collected were then analyzed using the SPSS 22 (Statistical Product and Service Solutions) program, namely the Kruskal-Wallis test with the Mann-Whitney posttest.

Results

Microscopic observation of the histology of the liver of the mice offspring from lactating mothers exposed to carbofuran given Kebar grass extract which was compared with mice offspring from lactating mothers who were given carbofuran and vitamin C. The scoring results of the liver of the mice offspring showed degeneration, necrosis, and infiltration of inflammatory cells.

The presence of degeneration is marked by the size of the enlarged cell cytoplasm and cloudy cytoplasm due to the presence of vacuoles (Fig. 1). Observation of necrosis was seen in the presence of cell nuclei that had picnosis, cariorexis, and karyolysis (Fig. 2). Observation infiltration of inflammatory cell (inflammation) was seen in the Kiernan triangle area (Table 1 and Fig. 3).

Table 1. Average score of hepatic degeneration, necrosis and inflammatory cell's infiltration of mice offspring from mothers given the extract of Kebar grass (*Biophytum petersianum Klotzsch*) and vitamin C exposed to carbofuran

Treatments	Score Degeneration (Mean ± SD)	Score Necrosis (Mean ± SD)	Score infiltration of inflammatory cell (Mean ± SD)
K (control)	0.00±0.00 ^a	0.00±0.00 ^a	0.00±0.00 ^a
P1 (carbofuran 1/4 LD ₅₀)	4.73±0.23 ^g	4.60±0.00 ^f	4.33±0.23 ^g
P2 (carbofuran 1/8 LD ₅₀)	4.06±0.23 ^f	3.93±0.23 ^e	3.80±0.00 ^f
P3 (Kebar grass extract 3.375 mg + carbofuran 1/4 LD ₅₀)	1.67±0.23 ^c	2.06±0.23 ^c	1.40±0.00 ^c
P4 (Kebar grass extract 3.375 mg + carbofuran 1/8 LD ₅₀)	1.13±0.11 ^b	1.13±0.11 ^b	0.73±0.11 ^b
P5 (vitamin C + carbofuran 1/4 LD ₅₀)	3.00±0.40 ^e	3.13±0.46 ^d	3.13±0.46 ^e
P6 (vitamin C + carbofuran 1/8 LD ₅₀)	2.20±0.00 ^d	2.73±0.23 ^d	1.93±0.23 ^d

Note: The different notations a, b, c, d, e, f and g (superscript) in the same column indicate a significant difference ($p < 0.05$)

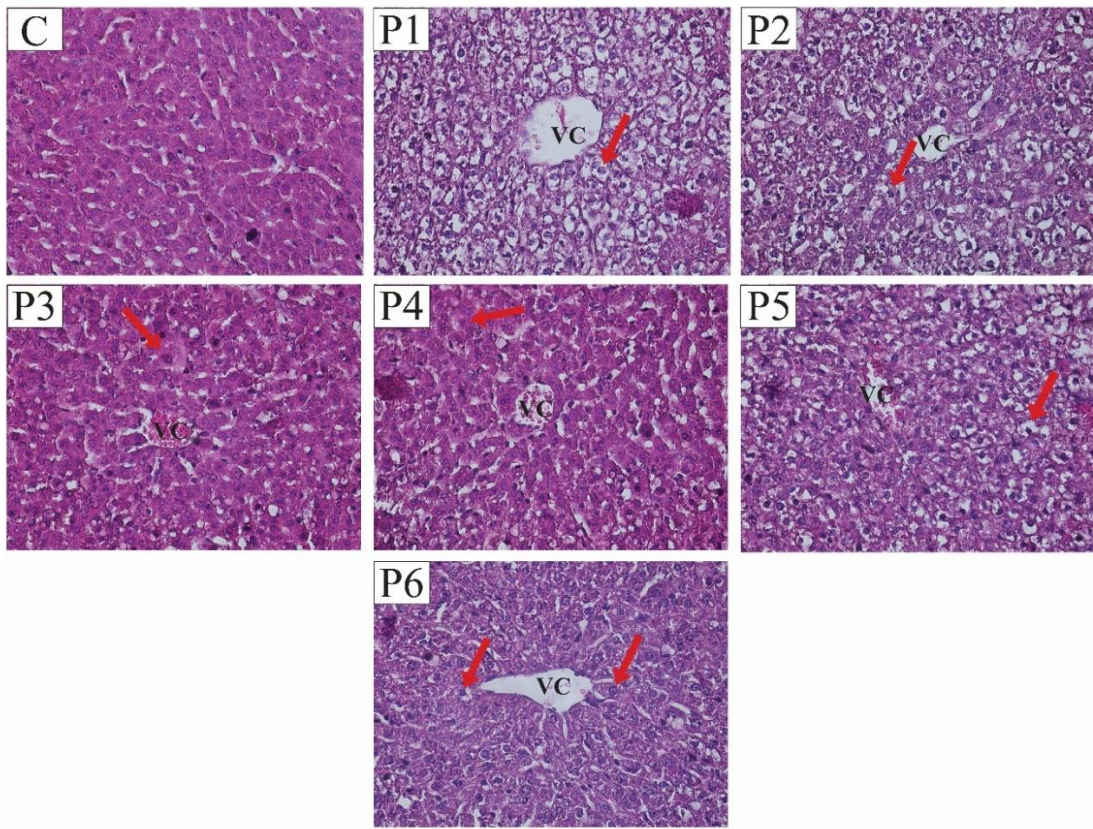


Fig. 1. Comparison of the microscopic picture of hepatocyte degeneration in mice offspring with H&E staining, magnification 400x. The arrows indicate cell degeneration (➡), VC (Vena Centralis). K (aquadest), P1 (carbofuran 1/4 LD₅₀ 0.0125 mg/day), P2 (carbofuran 1/8 LD₅₀ 0.00625 mg/day), P3 (Kebar grass extract 3.375 mg (0.2 ml) + carbofuran 1/4 LD₅₀), P4 (Kebar grass extract 3.375 mg (0.2 ml) + carbofuran 1/8 LD₅₀), P5 (vitamin C 5 mg (0.2 ml) + carbofuran 1/4 LD₅₀), and P6 (vitamin C 5 mg (0.2 ml) + carbofuran 1/8 LD₅₀). **400X magnification.**

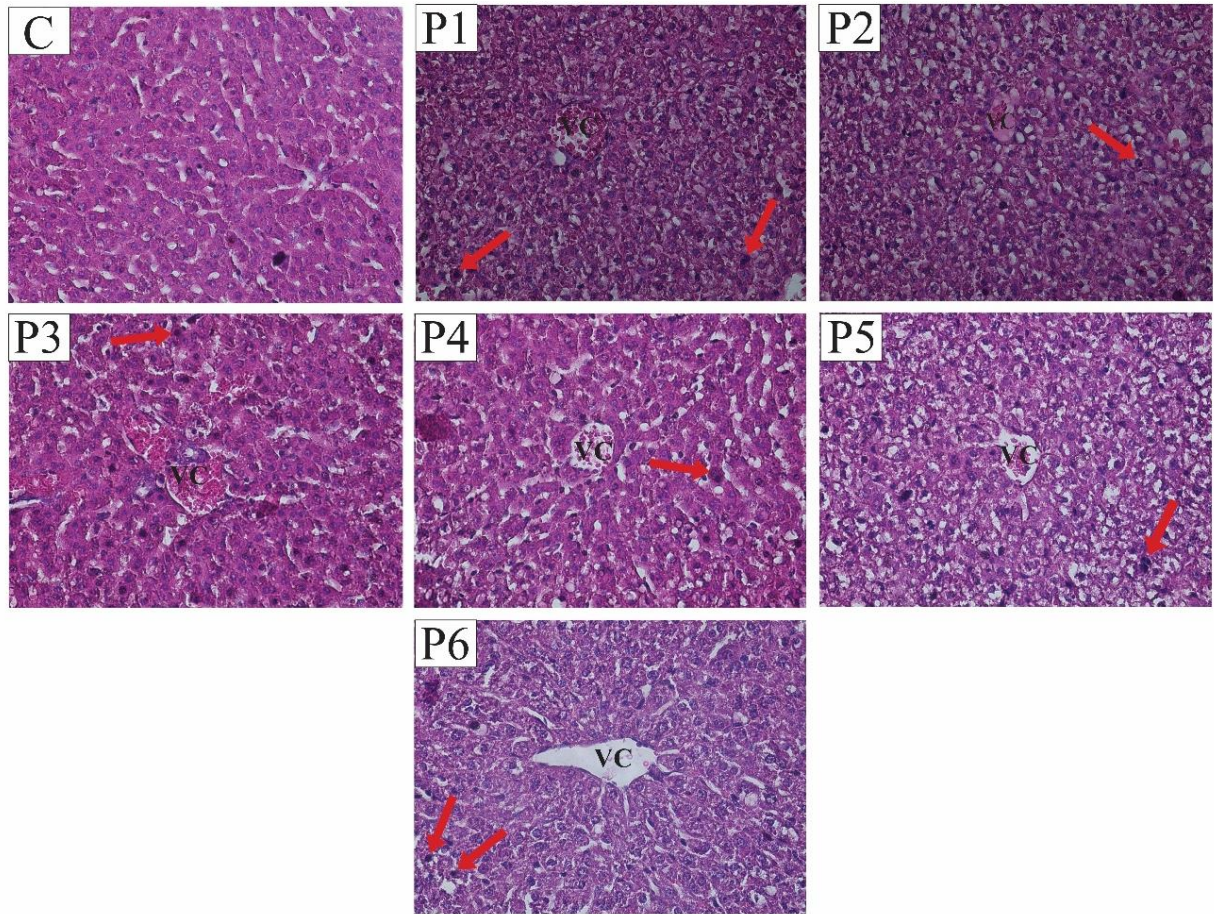


Fig. 2. Comparison of the microscopic appearance of hepatocyte necrosis in mice offspring with H&E staining, magnification 400x. Arrows indicate cell necrosis (➡), VC (Vena Centralis). K (aquadest), P1 (carbofuran 1/4 LD₅₀ 0.0125 mg/day), P2 (carbofuran 1/8 LD₅₀ 0.00625 mg/day), P3 (Kebar grass extract 3.375 mg (0.2 ml) + carbofuran 1/4 LD₅₀), P4 (Kebar grass extract 3.375 mg (0.2 ml) + carbofuran 1/8 LD₅₀), P5 (vitamin C 5 mg (0.2 ml) + carbofuran 1/4 LD₅₀), and P6 (vitamin C 5 mg (0.2 ml) + carbofuran 1/8 LD₅₀). **400X magnification.**

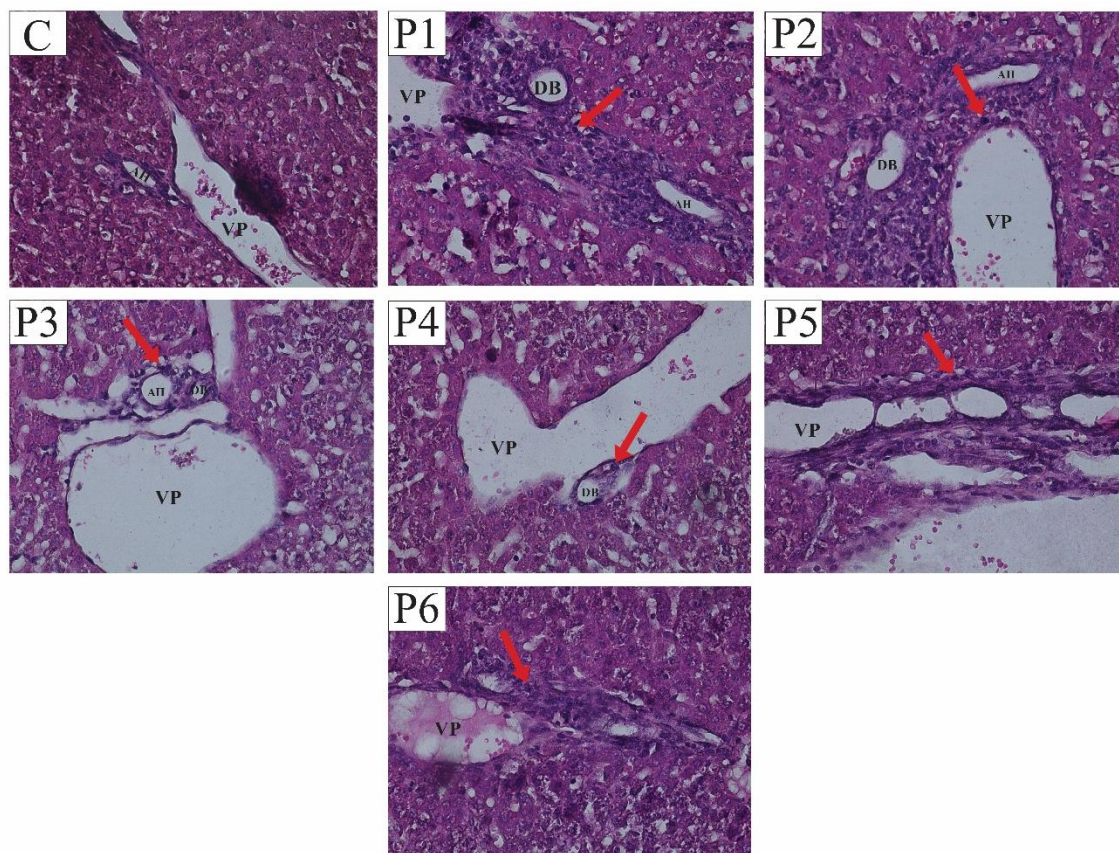


Fig. 3. Comparison of the microscopic appearance of infiltration of inflammatory cells in mice offspring hepatositis (*Mus musculus*) with H&E staining, magnification 400x. Arrows indicate infiltration of inflammatory cells (➔), PV (Portal Vein), DB (Ductus Billiverus), AH (Arteria Hepatica). K (aquadest), P1 (carbofuran 1/4 LD₅₀ 0.0125 mg/day), P2 (carbofuran 1/8 LD₅₀ 0.00625 mg/day), P3 (Kebar grass extract 3.375 mg (0.2 ml) + carbofuran 1/4 LD₅₀), P4 (Kebar grass extract 3.375 mg (0.2 ml) + carbofuran 1/8 LD₅₀), P5 (vitamin C 5 mg (0.2 ml) + carbofuran 1/4 LD₅₀), and P6 (vitamin C 5 mg (0.2 ml) + carbofuran 1/8 LD₅₀). **400X magnification.**

Discussion

Degeneration, necrosis and infiltration of inflammatory cell are manifestations of injury. Degeneration is a reaction to a lesion that is reversible, meaning that the cell can return to normal if it is able to overcome the injury, but if the cell is unable to overcome the injury, it will continue to the point of no return where the cell experiences death or necrosis which is irreversible (Arimbi et al. 2015). The results of this study indicate that giving Kebar grass extract as an antioxidant is better in reducing the level of degeneration, necrosis, and infiltration of inflammatory cell in mice hepatocytes compared to giving vitamin C. This is related to the antioxidant content of Kebar grass which **contains compounds** such as flavonoids, vitamin A and vitamin E. Antioxidants can work more effectively if given in combination (Addor 2017). The combination of primary antioxidants (flavonoids) and phenolic antioxidants (vitamins A and E) is able to provide maximum results in overcoming oxidative stress (Sayuti and Rina 2015). The antioxidant ability **activity** of flavonoids is **higher** than vitamin C (Prior and Cao 2000). Giving **solely** vitamin C causes this antioxidant not to work optimally. Flavonoids are

antioxidants that are included in primary antioxidants. Flavonoids can increase endogenous antioxidant function by **interfering with** free radical-producing systems. One of the mechanisms of flavonoids as anti-oxidants is directly cleaning radicals so that they can prevent cell damage. caused by free radicals. Direct **scavenging of flavonoids results in** stable substances, because the activity of the flavonoid group is high so that it can **bind** reactive oxygen species (Panche et al. 2016). The mechanism of vitamin A **activity** as an antioxidant is by reacting with free radicals and causing them to become stable. Tocopherol or vitamin E is the first line of defense against the peroxidation process of polyunsaturated fatty acids (General Adaptation Syndrome, GAS) and acts as a chain-breaking antioxidant in membranes (Maslachah et al. 2008). Based on the results of **our** research, it can be concluded that giving the extract of Kebar grass (*Biophytum petersianum Klotzsch*) is more effective in reducing degeneration, necrosis and inflammatory cell's infiltration than vitamin C in mice offspring (*Mus musculus*) from parent exposed to carbofuran during lactation period.

Acknowledgements

The authors express sincere thanks to the Ministry of Research, Technology and Higher Education of the Republic of Indonesia for funding the research, and the Dean of Faculty of Veterinary Medicine, Universitas Airlangga for providing all necessary facilities and funds in conducting this research work.

References

- Addor FA (2017) Antioxidants in dermatology. *An Bras Dermatol* 92: 356–362.
- Arimbi A, Azmijah, Darsono R, Plumerriastuti H, Widiyatno TV, Legowo D (2015) Veterinary general pathology textbook. 2nd ed., Airlangga University Press, Surabaya.
- Chin AM, Hill DR, Aurora M, Spence JR (2017) Morphogenesis and maturation of embryonic and postnatal intestine. *Semin Cell Dev Biol* 66: 81-93.
- Chandra D, Tripathi UN, Srivastava S, Amit Swaroop A (2011) Carbofuran induced biochemical toxicity in mice; Protective role of *Momordica charantia*. *Eur J Exp Biol* 1: 106-112.
- Gbadegesin MA, Owumi SE, Akinseye V, Odunola OA (2013) Evaluation of hepatotoxicity and clastogenicity of carbofuran in male Wistar rats. *Food Chem Toxicol* 5: 115-119
- Gibson J (2003) Modern physiology and anatomy for nurses. 2nd Ed. Jakarta. EGC Press
- Gupta RC (1994) Carbofuran Toxicity. *J Toxicol Environ Health* 43: 383-418.
- Jaiswal SK, Siddiqi NJ, Sharma B (2013) Carbofuran induced oxidative stress in rat heart: Ameliorative effect of vitamin C. *ISRN Oxid Med*: 11: 1-10.
- Kaur M, Sandhir R (2006) Comparative effects of acute and chronic carbofuran exposure on oxidative stress and drug-metabolizing enzymes in liver. *Drug Chem Toxicol* 29: 415-421.
- Keegan J, Whelan M, Danaher M, Crooks S, Sayers R, Anastasio A, Elliott C, Brandon D, Furey A, O'Kennedy R (2009) Bensimidazole carbamate residues in milk: Detection by Surface Plasmon Resonance-biosensor, using a modified QuEChERS (Quick, Easy, Cheap, Effective, Rugged and Safe) method for extraction. *Anal Chim Acta* 654: 111-119.
- Luqman EM, Sudiana, IK, Darmanto W, Achmad AB, Widjiati (2019) Mouse (*Mus musculus*) embryonic cerebral cortex cell death caused by carbofuran insecticide exposure. *J Vet Res* 63: 413–421.
- Maslachah L, Sugihartuti R, Kurniasanti R (2008) The inhibition of vitamin E (α -tocopherol) antioxidant to superoxide radical reactive oxygen species ($O_2^{\cdot-}$) production on the white rat (*Rattus norvegicus*) stressed by an electric shock. *Vet J* 24: 22- 26.

- Otieno PO, Lalah JO, Virani M, Jondiko IO, Schram KW (2010) Carbofuran and its toxic metabolites provide forensic evidence for furadan exposure in vultures (*Gyps africanus*) In Kenya. Bull Environ Contam Toxicol 84: 536-544
- Panche AN, Diwan AD, Chandra SR (2016) Flavonoids: an overview. J Nutr Sci 5: 1-15.
- Prior RL, Cao G (2000) Antioxidant phytochemicals in fruits and vegetables; diet and health implications. Hort Sci 35: 588-592.
- Rai DK, Rai PK, Rizvi SI, Watal G, Sharma B (2009) Carbofuran-induced toxicity in rats: protective role of vitamin C. Exp Toxicol Pathol 61: 531-535.
- Sayuti K, Rina Y (2015) Natural and synthetic antioxidants, 1st ed., Andalas University Press, Padang.
- Trisetiyono Y, Pramono N, Hidayat ST, Widjiati (2019) The differences of malondialdehyde serum level, expression of tumor necrosis factor alpha and vascular endothelial growth factor, and the area of endometriotic implants in administration of Kebar grass extract (*Biophytum petersianum*) and green tea extract (*Camelia sinensis*) to mice. Trad Med J 24: 169-177
- Unitly AJA, Inara C (2011) Potential of kebar grass (*Biophytum Petersianum Klotzsch*) in improving reproductive performance. Proceedings of the National Seminar Universitas Patimura, Ambon, Indonesia. pp.329-333

PJVS - Article Accepted

External



Polish Journal of Veterinary Sciences noreply <pjvs@uwm.edu.pl>

Wed, Nov
17, 2021,
3:02 AM

to me



Dear Dr. M.Sc. DVM Epy Muhammad Luqman (epy), We are pleased to inform you that your manuscript, "Effect of kebar grass extract (*Biophytum petersianum* Klotzsch) on histopathological changes of mice offspring liver (*Mus musculus*) from the parent exposed to carbofuran during lactation period " has been accepted for publication in Polish Journal of Veterinary Sciences. The article will be directed to the next stages of editing. Please wait patiently for the future information. Best regards, The Editorial Office Polish Journal of Veterinary Sciences

Comment:

Your article will be published in the Vol. 24 No. 4 (December 2021) of PJVS. PLEASE SEND US DATA NECESSARY TO PREPARE THE INVOICE (SEND IT VIA EMAIL TO barbara.manka@uwm.edu.pl). THE EMAIL HAS TO BE subjected as: INVOICE DATA XXX-PJVS-2021 – VOL 24-4 (XXX = Number of Your Article) AND SHOULD INCLUDE: 1. the number of your manuscript (XXX-PJVS-2021); 2. Volume 24/4 3. the title of the manuscript; 4. the name of the first author; 5. exact name of your institution; 6. exact address; 7. VAT EU number (full, including letters) of your institution (for European countries). In the next step (within a few weeks) you will receive INVOICE via return email from barbara.manka@uwm.edu.pl specifying the publication fee (according to <http://www.uwm.edu.pl/pjvsci/ifa.html>). Remember, that your contribution will appear in upcoming issue of the Polish Journal of Veterinary Sciences PROVIDING the Editorial Office RECEIVES A CONFIRMATION OF THE INFLOW OF THE PUBLICATION FEE to the journal bank account. THE BANK TRANSFER IS THE ONLY

PAYMENT OPTION! Please note that the transfer/manipulation fees are also to be covered by the authors. Kind regards, Michal Zalecki, PJVS Associate Editor

Remember:

If You want to log in always use the username: "epy".

Link: <http://spjvs.uwm.edu.pl/index/login>

If You don't remember password you can change it here: <http://spjvs.uwm.edu.pl/index/remindpassword>

© Polish Journal of Veterinary Sciences and University of Warmia and Mazury in Olsztyn - 2021

PJVS - PUBLICATION INVOICE for article

External

Inbox

B

Barbara Manka <barbara.manka@uwm.edu.pl>

Fri, Nov 19,
2021,
1:56 AM

to me

Dear Author,

Please find attached the invoice for publication in PJVS. The data of the bank account, seller and amount are included in the invoice.

Please send us back the scan of your payment via email

to: barbara.manka@uwm.edu.pl

The email should include the number of the article, the title of the manuscript and the name of the first author.

Your contribution will appear in upcoming issue of the Polish Journal of Veterinary Sciences PROVIDING the Editorial Office RECEIVES A CONFIRMATION OF THE INFLOW OF THE PUBLICATION FEE (based upon the attached invoice) to the journal bank account. Please note that the transfer/manipulation fees are also to be covered by the authors.

Kind regards,
PJVS Secretary

Article needs improved translation

External

Inbox



Polish Journal of Veterinary Sciences noreply <pjvs@uwm.edu.pl>

Fri, Dec 3,
2021,
4:22 AM

to me

Article Effect of kebar grass extract (*Biophytum petersianum* Klotzsch) on histopathological changes of mice offspring liver (*Mus musculus*) from the parent exposed to carbofuran during lactation period needs improved translation

Comment:

Dear Author, We are pleased to inform you that your paper is nearing publication. The translator's page proofs are available in attached PDF file (button "PAGE PROOFS – PDF FILE" In the panel "ARTICLES"). Please include all the required corrections enclosed in the PDF file into your files (eg. manuscript, tables etc. if necessary) and replace them in the system (by logging on your profile and clicking "EDIT" button in the panel "ARTICLES"). To replace the particular files you have to delete from the system the old version of the file (by clicking DELETE near by the particular file) and then you have to upload the new version of file. Replace ONLY files that have been changed. Before uploading improved files, you should proofread your manuscript very closely for mistakes and grammatical errors. PLEASE REMOVE LINE NUMBERS and INCLUDE TRACK CHANGES (if any)! Please remove all the inconsistencies regarding the literature cited throughout the manuscript. Please check carefully whether journal title abbreviations used in "References" are consistent with those used by popular scientific data bases, e.g. PubMed. In general, with regard to the literature, please strictly follow (considering every point or comma) the instructions for authors available at www.uwm.edu.pl/pjvsci. Do not submit a revised manuscript as a new submission! Finally, please send back your improved version of the article by clicking button "SUBMIT TO OFFICE" in the panel "ARTICLES". Then in the pop-up window of the optional comments you HAVE to click "SUBMIT YOUR ARTICLE" button to finally sent back your paper. We encourage you to submit your improvements as soon as possible! The fast revision would allow for publication of your article in the upcoming issue. In the next step the manuscript will be directed to the Typesetter's Office – then you will receive a galley-proof (PDF) of your paper via PJVS Online system. NOTE: In the final step, the published version of the article (hard copy) will be send to you by the post office and the article will be published online with direct access from PubMed website (by clicking article's DOI) and at <http://journals.pan.pl/pjvs>. REMEMBER: ALL THE PAYMENTS AND FINAL CORRECTIONS HAVE TO BE FINISHED TILL 08.12.2021!!! If you do not complete it, your manuscript will NOT be published in the current issue! Sincerely, Michal Zalecki PJVS Associate Editor

Remember:

If You want to log in always use the username: "epy".

Link: <http://spjvs.uwm.edu.pl/index/login>

If You don't remeber password you can change it here: <http://spjvs.uwm.edu.pl/index/remindpassword>

© Polish Journal of Veterinary Sciences and University of Warmia and Mazury in Olsztyn - 2021

Revision from translator (manuscript number is 1505-pjvs-2021)

Dear Michal Zalecki

Thank you for your fast response and very helpful for dealing with server technicalities. Here I send a revision of manuscript entitled "**Effect of kebar grass extract (*Biophytum petersianum* Klotzsch) on histopathological changes in liver of mice offspring from the parent exposed to carbofuran during lactation period**" (manuscript number is 1505-pjvs-2021) from Translator.

I had corrected the manuscript (red text):

1. I have changed the title to "Effect of kebar grass extract (*Biophytum petersianum* Klotzsch) on histopathological changes in liver of mice offspring from the parent exposed to carbofuran during lactation period".
2. I have added full address, street name, city and post code.
3. I have changed the punctuation in the sentence, citation according to the PJVS writing guidelines.

4. I've changed and added the word the reviewer suggested (due to exposure to..coming from, manufacture to making, is quite a lot (multicompound) to contains compounds, ability to activity, more effective to higher, participating in to interfering with, stabilize to bind etc.
5. I added a histology scale with 400X magnification.
6. I have checked carefully whether journal title abbreviations used in "References" are consistent with those used by popular scientific databases, e.g. PubMed.
7. I have paid Eur 322 as Article Processing Charges (APC) on November 22, 2021 and I have informed to Barbara Mańka.

Thank you

Michał Zalecki michal.zalecki@uwm.edu.pl

Editor sent article for acceptance

External

Inbox



Polish Journal of Veterinary Sciences noreply <pjvs@uwm.edu.pl> Sun, Dec 12, 2021, 3:32 PM

to me



Dear Author, We are pleased to inform you that your paper Effect of kebar grass extract (*Biophytum petersianum* Klotzsch) on histopathological changes in liver of mice offspring from the parent exposed to carbofuran during lactation period is nearing publication. The galley-proof of your article is available as a PDF file [PJVS online system (<http://spjvs.uwm.edu.pl/index/login>) > "SHOW EDITORS FILE" in the panel "ARTICLES"]. Please verify your paper thoroughly and decide if the article is suitable for final publication in the present form, or you want to include some corrections (please be aware that only small corrections can be made; larger fragments of the text can be changed or added only in case they have been omitted during preparation of the paper for printing). Include all the required corrections (CLEARLY) on the printed version of the manuscript and scan only the pages with marked amendments. Finally, SEND US BACK the pages with marked corrections by email (email pattern below) to jerzy.kaleczyc@uwm.edu.pl IN CASE you decide that the manuscript is suitable for publication in the present form (without any additional improvements) – SEND BACK the email (email pattern below) to jerzy.kaleczyc@uwm.edu.pl giving such information. THE EMAIL HAS TO BE SUBJECTED AS: "Galley-Proof - Name of the First Author - XXX-PJVS-201X" AND SHOULD INCLUDE: 1. the title of the manuscript 2. the name of the first author; 3. the number of your manuscript (XXX-PJVS-201X); ; TO AVOID A DELAY in publication of your article, please complete your proof review and SEND BACK your "Galley-Proof" email in the next 72 hours. If you are unable to meet this deadline, you encounter any problems or have further questions, please contact our co-editor, Jerzy Kaleczyc (jerzy.kaleczyc@uwm.edu.pl). Best regards, Editorial Office Polish Journal of Veterinary Sciences

Remember:

If You want to log in always use the username: "epy".

Link: <http://spjvs.uwm.edu.pl/index/login>

If You don't remeber password you can change it here: <http://spjvs.uwm.edu.pl/index/remindpassword>

© Polish Journal of Veterinary Sciences and University of Warmia and Mazury in Olsztyn - 2021