



UNIVERSITAS AIRLANGGA
Excellence with Morality

p-ISSN: 1907-3623

e-ISSN: 2684-9453



August 2022, Vol. XIII No. 2



Editorial Team



Prof. Viskasari Pintoko Kalanjati, dr., M.Kes., PA(K), Ph.D.

Editor in Chief

Department of Anatomy, Histology and Pharmacology, Faculty of Medicine, Universitas Airlangga, Surabaya, Indonesia



 0000-0002-7005-0025 [Google Scholar](#) 54388384000  5975075



Prof. Muhammad Miftahussurur, dr., M.Kes., Sp.PD-KGEH., Ph.D., FINASIM

Associate Editor

Division of Gastroentero-hepatothology, Department of Internal Medicine, Faculty of Medicine, Universitas Airlangga, Surabaya, Indonesia

 0000-0003-1415-6033 [Google Scholar](#) 56323903000  6031037



Dr. Purwo Sri Rejeki, dr., M.Kes.

Associate Editor

Department of Physiology, Faculty of Medicine, Universitas Airlangga, Surabaya, Indonesia

 0000-0002-6285-4058 [Google Scholar](#) 57208052652  6067303



Prof. Gustaaf Albert Dekker, MD., Ph.D., FDCOG., FRANZCOG

Editorial Board Member

Pediatrics and Reproductive Health, The University of Adelaide, Adelaide, Australia

 - [Google Scholar](#) 57203258819  -




Prof. Togas Tulandi, MD., MHCM., FRCSC., FACOG

Editorial Board Member

Department of Obstetrics and Gynecology, McGill University, Montreal, Canada

 0000-0002-5253-2565 [Google Scholar](#) 7102237805  -



Prof. Liang-Yo Yang, DVM., Ph.D.

Editorial Board Member

Department of Physiology, China Medical University, Taiwan, China

 0000-0002-0886-1679 [Google Scholar](#) 8893236100  -





Prof. Dr. Ari Fahrial Syam, dr., Sp.PD-KGEH., MMB, FINASIM, FACP, FAGG

Editorial Board Member

Department of Internal Medicine, Faculty of Medicine, Universitas Indonesia, Jakarta, Indonesia

 0000-0003-0041-3553 [Google Scholar](#) 8443384400  6025740



Prof. Dr. Wachyu Hadisaputra, dr., Sp.OG-KFER

Editorial Board Member

Department of Obstetrics and Gynecology Clinic, Faculty of Medicine, Universitas Indonesia, Jakarta, Indonesia

 0000-0002-2575-8323 [Google Scholar](#) 6602393903  6043440



Dr. Fauzi Yusuf, dr., Sp.PD., K-GEH, FINASIM, FAGG

Editorial Board Member

Division of Gastroentero-hepatothology, Department of Internal Medicine, Faculty of Medicine, Universitas Syiah Kuala, Banda Aceh, Indonesia

 0000-0002-5822-300X [Google Scholar](#) 57192179254  6678934



Fadhil Ahsan, dr., M.Sc., Ph.D.

Editorial Board Member

Universitätsklinikum Würzburg, Bavaria, Germany

 0000-0002-9302-3804 [Google Scholar](#) 57190570149  6718475



Prof. Dr. Muhammad Fidel Ganis Siregar, dr., M. Ked(OG), Sp.OG(K)-Fer

Editorial Board Member

Department of Obstetrics and Gynecology, Faculty of Medicine, Universitas Sumatera Utara, Medan, Indonesia

 0000-0002-2702-4091 [Google Scholar](#) 56237331100  5990297



Dr. Wahjoe Djatisoesanto, dr., Sp.U(K)

Editorial Board Member

Department of Urology, Faculty of Medicine, Universitas Airlangga, Surabaya, Indonesia



 0000-0002-7579-5608 [Google Scholar](#) 56786304700  6052131



Prof. Dr. Sri Herawati Juniati Prasetyo Boestan, dr., Sp.T.H.T.K.L(K), FICS

Editorial Board Member

Department of Otolaryngology-Head and Neck Surgery, Faculty of Medicine, Universitas Airlangga, Surabaya, Indonesia

 0000-0002-8672-6085 [Google Scholar](#) 57201312026  6045



Anggie Kusumawardhani, S.KM.

Assistant Editor

Universitas Airlangga, Surabaya, Indonesia

 0000-0002-7998-8589

[Google Scholar](#)

-



-



Cindy Belinda Ramadhanty, S.Hum., M.Hum.

Assistant Editor

Universitas Airlangga, Surabaya, Indonesia

 0000-0003-0255-8684

[Google Scholar](#)

-



-

Login

Username *

Password *

[Forgot your password?](#)

Keep me logged in

[Login](#)

[Register](#)

[Make a Submission](#)

[Focus and Scope](#)

[Publication Ethics](#)

[Article Processing Charge](#)

[Peer Reviewers](#)

[Peer Review Process](#)

[Open Access Statement](#)

[Archiving](#)

[Plagiarism](#)

[Copyright](#)

[Repository Policy](#)

[ORCID ID Policy](#)

[License Term](#)

DAFTAR ISI

JUXTA:): Jurnal Ilmiah Mahasiswa Kedokteran Universitas Airlangga

Vol. 13 No. 2 (2022): Jurnal Ilmiah Mahasiswa Kedokteran Universitas Airlangga
Published: 2022-08-10

Decubitus Ulcer Patients Profile in Department of Plastic Surgery Dr. Soetomo General Hospital Surabaya from January to December 2018
Azmil Permatasari ⁽¹⁾, Magda Rosalina Hutagalung ⁽²⁾, Nuniek Nugraheni Sulistiawaty ⁽³⁾, Agus Susanto Budi ⁽⁴⁾

Page : 46-50, DOI : 10.20473/juxta.V13I22022.46-50

In Vitro Antimicrobial Activity Evaluation of Ginger (*Zingiber officinale*) Absolute Ethanol Extract against Uropathogenic *Escherichia coli* (UPEC)
Angeline Felicia ⁽¹⁾, Kartuti Debora ⁽²⁾, Ramadhani Ramadhani ⁽³⁾

Page: 51-56, DOI : 10.20473/juxta.V13I22022.51-56

Sedentary Lifestyle and Overweight in Relation to the Risk of Polycystic Ovary Syndrome in Senior High School Students in Surabaya
Shafira Noorania Putri ⁽¹⁾, Budi Santoso ⁽²⁾, Budiono Budiono ⁽³⁾

PAGE: 57-61, DOI : 10.20473/juxta.V13I22022.57-61

Incidence of Respiratory Tract Infection in Children with Cyanotic and Acyanotic Congenital Heart Disease: A Comparative Study
Syafira Yasmine ⁽¹⁾, I Ketut Alit Utamayasa ⁽²⁾, Bambang Herwanto ⁽³⁾

Page: 62-66, DOI : 10.20473/juxta.V13I22022.62-66

Effectiveness of Medication, Surgery, and Combination Therapy to Decrease Intraocular Pressure on Glaucoma Outpatient at Outpatient Ophthalmic Clinic Dr. Soetomo General Hospital Surabaya in January – December 2017
Muhammad Bagas Pratista ⁽¹⁾, Nurwasis Nurwasis ⁽²⁾, Kusuma Eko Purwantari ⁽³⁾, Indri Wahyuni ⁽⁴⁾

Page: 67-72, DOI : 10.20473/juxta.V13I22022.67-72

Therapeutic Communications of Doctors and Hypertensive Patients' Satisfaction

Reka Elvia Dirda Prasasta ⁽¹⁾, Linda Dewanti ⁽²⁾, Dominicus Husada ⁽³⁾, Lilik Djuari ⁽⁴⁾

Page: 73-78, DOI : 10.20473/juxta.V13I22022.73-78

Wound Pattern Profile in Deceased Victims of Traffic Accidents in Raden Said Sukanto

Bhayangkara Hospital Jakarta from January 2017 until December 2018

Evan Boedi Dewanto ⁽¹⁾, Ahmad Yudianto ⁽²⁾, Magda Rosalina Hutagalung ⁽³⁾

Page: 79-82, DOI : 10.20473/juxta.V13I22022.79-82

Bone Age Measurement in Pediatric Patients of Universitas Airlangga Hospital from January 2018 to December 2019

Dinda Chandra Yuliantari ⁽¹⁾, Anggraini Dwi Sensusiati ⁽²⁾, Ahmad Suryawan ⁽³⁾, Muhammad Faizi ⁽⁴⁾

Page: 83-87, DOI : 10.20473/juxta.V13I22022.83-87

Effect of Carrots (*Daucus carota* L.) on Gastric Histopathology of Piroxicam-Induced Mice as a Peptic Ulcer Prevention

Jennifer Susanto ⁽¹⁾, Danti Nur Indiasuti ⁽²⁾, Gondo Mastutik ⁽³⁾

Page: 88-92, DOI : 10.20473/juxta.V13I22022.88-92

In-Silico Study: Potential Inhibitor of Cyclin-Dependent Kinase 6 (CDK6) from Natural Plant Compounds for Melanoma Treatment

Putri Aliya Ahadini ⁽¹⁾, Adhyatma Ismu Reihan ⁽²⁾, Muhamad Bagus Wira Utama ⁽³⁾, Siti Khaerunnisa ⁽⁴⁾, Fadilah Fadilah ⁽⁵⁾

Page: 93-99, DOI : 10.20473/juxta.V13I22022.93-99

Effect of Carrots (*Daucus carota L.*) on Gastric Histopathology of Piroxicam-Induced Mice as a Peptic Ulcer Prevention

Jennifer Susanto¹ , Danti Nur Indiasuti^{2*} , Gondo Mastutik³ 

¹Faculty of Medicine, Universitas Airlangga, Surabaya, Indonesia.

²Department of Anatomy, Histology, and Pharmacology, Faculty of Medicine, Universitas Airlangga, Surabaya, Indonesia.

³Department of Anatomical Pathology, Faculty of Medicine, Universitas Airlangga, Surabaya, Indonesia.

ABSTRACT

Introduction: Non-steroidal anti-inflammatory drugs (NSAIDs) consumption contributes significantly to gastrointestinal morbidity, including peptic ulcers. NSAIDs cause gastric mucosal damage by inhibiting PGE2 and PGI2 secretion, increasing HCl secretion, and also causing local irritation and neutrophil adhesion. Flavonoids and chlorogenic acid are gastroprotective agents found in carrots (*Daucus carota L.*). Therefore, this study aimed to validate the effect of carrots on gastric histopathology of piroxicam-induced mice.

Methods: This was an experimental study using a post-test-only control group design. 35 mice were divided into 5 groups and were allowed to adapt for 1 week. The negative control group received 0.25 mL aqua dest, while the positive control group received 0.104 mg famotidine. Group A, B, and C received carrot extract with each dosage was 200 mg/kgBW, 300 mg/kgBW, and 400 mg/kgBW. The mice were induced 2 hours later with 0.052 mg piroxicam. The treatments lasted 14 days. Each stomach was taken and examined on the 15th day. Afterward, histopathological preparations were made.

Results: The results of the histopathological signs of inflammation using the Kruskal-Wallis method showed $p = 0.000$, indicating that there was an effect of the carrot extract in preventing inflammation on the gastric histopathology ($p < 0.05$).

Conclusion: In conclusion, this study confirmed that carrot extract is more effective in avoiding peptic ulcers due to NSAID consumption.

ARTICLE INFO

Article history:

Received 2 June 2022

Received in revised form
28 June 2022

Accepted 27 July 2022

Available online 10 August 2022

Keywords:

Carrot,
Famotidine,
Health risk,
Peptic ulcer,
Piroxicam.

* Correspondence: danti-n-i@fk.unair.ac.id

JUXTA: Jurnal Ilmiah Mahasiswa Kedokteran Universitas Airlangga

p-ISSN: 1907-3623; e-ISSN: 2684-9453

DOI: 10.20473/juxta.V13I12022.88-92

Open access under Creative Commons Attribution-ShareAlike 4.0 International License
(CC-BY-SA)

Introduction

Non-steroidal anti-inflammatory drugs (NSAID) have common side effects that damage the digestive tract mucosa through inhibition of cyclooxygenase-1 (COX-1) enzyme which can reduce the secretion of gastric mucosal cytoprotective materials, especially PGE2 and PGI2, through local irritation due to direct contact with gastric mucosa,¹ through inhibition of cyclooxygenase-2 (COX-2) enzyme which can increase neutrophil adhesion,² through reactive oxygen species (ROS) production,^{3,4} and also through its prominent acidic nature.⁴ Based on 2013 Basic Health Research in Indonesia, there were 24,496 NSAIDs stored by 20,516 households purchased without a prescription. One of them is piroxicam which has side effects of peptic ulcers and gastrointestinal bleeding up to 9.5 times higher than others.^{5,6}

Peptic ulcers are ulceration of the gastric or duodenum mucosa.⁷ The best therapy is proton pump inhibitor (PPI). However, PPI is an acid-labile drug and only works after being absorbed in the intestine,⁵ thus the H2 receptor antagonist (H2RA) was the drug used in this study because it directly inhibits the H2 receptor. Famotidine, for example, was effective in preventing peptic ulcers in indomethacin-induced rats by reduction of gastric degenerative changes, gastric acidity, and ROS production.⁸ However, PPI and H2RA have side effects such as diarrhea and headache.⁵ Therefore, carrots (*Daucus carota L.*) which contain anti-inflammatory substances, known as phenolic substances, can be used as an alternative to prevent peptic ulcers.⁸ The most dominant phenolic compound in carrots is chlorogenic acid which can reduce the release of inflammatory mediators, especially TNF- α .^{9,10} Carrots also contain flavonoids that inhibit acid secretion, reduce pepsin level and activity, and also increase gastric mucous and bicarbonate secretion. Flavonoids also have antioxidative, anti-inflammatory, and cytoprotective effect.^{11,12} Therefore, this study aimed to prove the effect of carrot extract as a peptic ulcer prevention on piroxicam-induced mice using histopathological signs of inflammation as the measurement.

Methods

This study used an experimental method with a post-test-only control group design that randomized mice into groups consisting of 2 control groups and 3 experimental groups.

Drugs

The dosage of the piroxicam used in this study was 20 mg x 0.0026 = 0.052 mg/treatment/mice (2 tablets of piroxicam were crushed). 25.48 mg of piroxicam were taken and dissolved in 122.5 ml aqua dest. The dosage of the famotidine used in this study was 40 mg x 0.026 = 0.052 mg/treatment/mice (1 tablet of famotidine was crushed). 10.192 mg of famotidine were taken and dissolved in 24.5 ml aqua dest. 0.0026 was the constant surface-area ratio from man to mouse.¹³

Carrot Extract

Fresh carrots were pureed with methanol using a blender. Then the juice was put in a place to be macerated for 3 days. Afterward, the juice was filtered to separate the pulp and the filtrate. The filtrate was evaporated using a rotary evaporator to evaporate the methanol. Carrot extract was dissolved in aqua dest.

Animals

The sample population of this study was male mice (*Mus musculus*) with an average weight of 25 grams, aged 2-3 months, and healthy. Samples that died during the trial period were excluded. The animals were provided by Department of Anatomy, Histology, and Pharmacology Faculty of Medicine Universitas Airlangga Surabaya. The animals were housed in standard cages and supplemented with food and water ad libitum. After 7 days of adaptation, the mice were randomly divided into 5 groups and were treated as follows: (negative control) aqua dest 0.25 ml; (positive control) famotidine 0.104 mg; (A) 200 mg/kg BW carrot extract; (B) 300 mg/kg BW carrot extract; and (C) 400 mg/kg BW carrot extract. 2 hours later, all mice received 0.052 mg piroxicam. All treatments were administered orally. The treatments were given for 14 days. On the 15th day, the mice were examined and the stomachs were removed. All procedures were approved by the ethics committee of Faculty of Medicine Universitas Airlangga Surabaya

Histology Preparation

The stomach was opened along the greater curvature. Then, the part that had rugae (corpus to antrum) was given 10% formalin solution, dehydrated through increasing the grades of alcohol, printed into a paraffin block, and stored in the refrigerator. Paraffin blocks were cut to a thickness of 5 μ m. The pieces floated in warm water with a temperature of 60°C for 24 hours. The preparation was then removed and stained with hematoxylin-eosin (HE) solution.

Determination of Histopathological Signs of Inflammation

Each preparation was viewed in 3 fields per specimen (400x).

Score 0: normal gastric mucosa

Score 1: signs of inflammation of the gastric mucosa, such as hyperemia and edema, accompanied by neutrophils on the basement membrane, but the epithelial surface was still intact and there were no lymphocytes or plasma cells in the lamina propria

Score 2: erosion or bleeding on the mucosal surface

Score 3: erosions that penetrate the mucosa or transmural bleeding

Score 4: necrotic tissue in the basal lamina formed by granulation tissue¹⁴

Statistical Analysis

For histopathology the inflammatory sign, this study used the Kruskal-Wallis method because the data measurement scale was an ordinal. The results were displayed in tables.

Results

Table 1. Mean value and the Kruskal-Wallis test result of histopathological score

Group	Histopathological Score	Asymp. sig. (p)
Negative Control	1.95 ± 0.26	0.000
Positive Control	1.67 ± 0.29	
A	0.84 ± 0.07	
B	0.50 ± 0.14	
C	0.39 ± 0.10	

Table 1 shows that the severity of the inflammation decreased as the dosage increasing. There was an effect of treatment given on the histopathological score of inflammation signs. Similarly, this study used post hoc Mann-Whitney test to know which groups were significantly different. The results showed that group A and group B were not significantly different, the same with group B and group C.

Below are some pictures from the histopathological score of inflammation signs measurement:

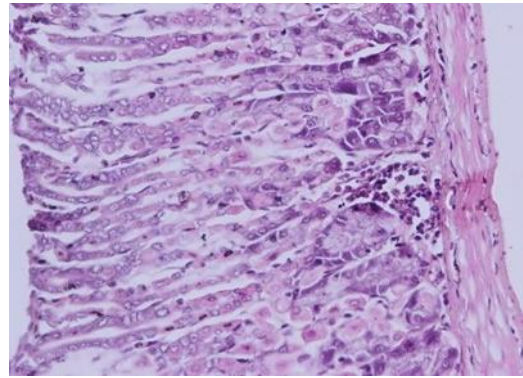


Figure 3. Group A (Score 1)

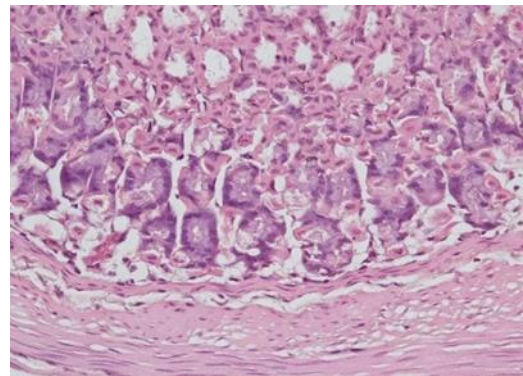


Figure 4. Group B (Score 1)

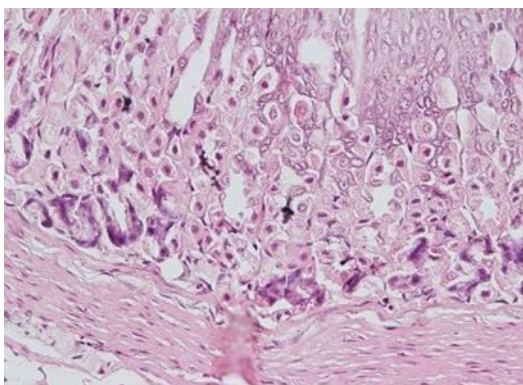


Figure 5. Group C (Score 0)

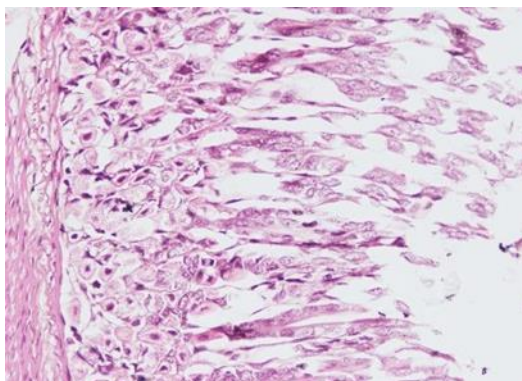


Figure 1. Negative Control (Score 3)

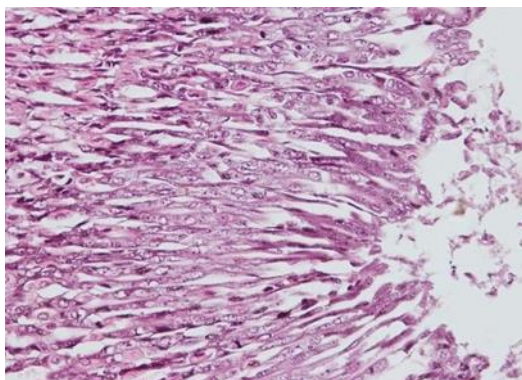


Figure 2. Positive Control (Score 2)

Discussion

On the histopathological signs of inflammation, all doses of carrot extract were more effective than famotidine. However, the difference in histopathological scores between group A and B and group B and C was less significant because of the close difference in dosage. The dosage used in the previous study were 150 mg/kg BW and 300 mg/kg BW, the results showed that ulcer index and

curative ratio percentage were significantly different.¹⁵ Therefore, carrot extract is more effective at preventing peptic ulcers than famotidine. This is caused by the antioxidant and gastroprotection compounds found in carrots such as flavonoids and chlorogenic acid.^{8,16}

Flavonoids can increase gastric prostaglandins, reduce H⁺ secretion, reduce free radicals, and regulate both pro and anti-inflammatory cytokines.^{12,16,17} One of the flavonoids in carrots is flavonols. There are several substances that are included in the flavonol class, one of which is quercetin. Quercetin can inhibit gastric acid secretion and lipid peroxidation. It also can increase mucous bicarbonate secretion.¹⁸

On the other hand, chlorogenic acid can also reduce gastric tissue lesions through several ways. First, it can decrease neutrophil migration and infiltration to the lesion area. Neutrophils are the first leukocytes to enter the area of inflammation and secrete chemicals to destroy the damaging agent. Thus, it can damage the host tissue.^{10,19} Second, it can decrease local secretion of pro-inflammatory mediators by modulating the key transcription factors.^{10,20} Lastly, it can decrease free radicals production. It can restore enzyme function and glutathione levels that can be reduced during inflammation.¹⁰

In comparison to carrot extract, famotidine is the most potent H₂RA. In previous studies, famotidine could reduce the side effect of NSAID consumption.^{5,8} However, the results showed that it was not as effective as carrot extract due to its only mechanism of action that reduce aggressive factors but does not increase defensive factors.^{8,21} If the use of NSAIDs should be continued, then PPI is a better choice than H₂RA.⁶

Conclusion

Carrot extract at a dose of 200 mg/kg, 300 mg/kg, and 400 mg/kg of body weight can prevent inflammation better than famotidine 0.104 mg for the histopathological signs of inflammation. In conclusion, carrot extract is more effective in preventing peptic ulcers due to NSAIDs consumption than famotidine.

Acknowledgments

The authors are extremely thankful to all staff in Department of Anatomy, Histology, and Pharmacology and Department of Pathology Anatomy Faculty of Medicine Universitas Airlangga for the help in this study.

Conflict of Interest

The authors declared there is no conflict of interest.

References

- Grosser T, Smyth E, FitzGerald GA. Anti-inflammatory, Antipyretic, and Analgesic Agents; Pharmacotherapy of Gout. In: Brunton LL, Chabner BA, Knollmann BC (eds) *Goodman & Gilman's: The Pharmacological Basis of Therapeutics*, 12e. New York, NY: McGraw-Hill Education, <http://accessmedicine.mhmedical.com/content.aspx?aid=1127868620> (2015).
- Habeeb A, Tiwari SK, Bardia A, et al. Peptic Ulcer Disease: Descriptive Epidemiology, Risk Factors, Management and Prevention. *SMGroup*, <http://www.smgebooks.com/peptic-ulcer-disease/chapters/PUD-16-06.pdf> (2016).
- Firdaus SB, Ghosh D, Chattopadhyay A, et al. Protective Effect of Antioxidant Rich Aqueous Curry Leaf (*Murraya koenigii*) Extract Against Gastro-Toxic Effects of Piroxicam in Male Wistar Rats. *Toxicol Reports* 2014; 1: 987–1003. [PubMed] [CrossRef]
- Nabil M, El Raey MA, Abdo W, et al. Gastro-Protective Effects of Albizia anthelmintica Leaf Extract on Indomethacin-Induced Gastric Ulcer in Wistar Rats: In Silico and In Vivo Studies. *Antioxidants* 2021; 10: 176. [PubMed] [CrossRef]
- Soleha M, Isnawati A, Fitri N, et al. Profil Penggunaan Obat Antiinflamasi Nonstereoid di Indonesia. *J Kefarmasian Indones* 2018; 109–117. [CrossRef]
- Katzung BG, Masters SB, Trevor AJ. *Farmakologi Dasar & Klinik*. 12th ed. Jakarta: EGC, 2012.
- Chan F, Lau J. *Peptic Ulcer Disease*. 10th ed. Philadelphia: Elsevier Saunders, 2016.
- Leja M, Kamińska I, Kramer M, et al. The Content of Phenolic Compounds and Radical Scavenging Activity Varies with Carrot Origin and Root Color. *Plant Foods Hum Nutr* 2013; 68: 163–170. [PubMed] [CrossRef]
- Arscott SA, Tanumihardjo SA. Carrots of Many Colors Provide Basic Nutrition and Bioavailable Phytochemicals Acting as a Functional Food. *Compr Rev Food Sci Food Saf* 2010; 9: 223–239. [CrossRef]
- López-Gómez G, Elez-Martínez P, Martín-Belloso O, et al. Applying Pulsed Electric Fields to Whole Carrots Enhances the Bioaccessibility of Carotenoid and Phenolic Compounds in Derived Products. *Foods* 2021; 10: 1321. [PubMed] [CrossRef]
- Shimoyama AT, Santin JR, Machado ID, et al. Antiulcerogenic Activity of Chlorogenic Acid in Different Models of Gastric Ulcer. *Naunyn Schmiedeberg's Arch Pharmacol* 2013; 386: 5–14. [PubMed] [CrossRef]
- Zhang W, Lian Y, Li Q, et al. Preventative and Therapeutic Potential of Flavonoids in Peptic Ulcers. *Molecules* 2020; 25: 4626. [PubMed] [CrossRef]
- Paget G, Barnes J. *Evaluation of Drug Activities: Pharmacometrics*. London: Academic Press, 1964.
- Kumar V, Abbas A, Aster J. *Robbins Basic Pathology*. Philadelphia: Elsevier Saunders, 2013.
- Wehbe K, Mroueh M, Daher CF. The Potential Role of *Daucus carota* Aqueous and Methanolic Extracts on Inflammation and Gastric Ulcers in Rats. *J Complement Integr Med*; 6. Epub ahead of print 16 January 2009. [CrossRef]
- da Silva Dias JC. Nutritional and Health Benefits of Carrots and Their Seed Extracts. *Food Nutr Sci* 2014; 05: 2147–2156. [CrossRef]
- Serafim C, Araruna ME, Júnior EA, et al. A Review of the Role of Flavonoids in Peptic Ulcer (2010–2020). *Molecules* 2020; 25: 5431. [PubMed] [CrossRef]
- Anand David A, Arulmoli R, Parasuraman S. Overviews of Biological Importance of Quercetin: A

- Bioactive Flavonoid. *Pharmacogn Rev* 2016; 10: 84. [PubMed]
19. Zatorski H, Sałaga M, Zielińska M, *et al.* Experimental Colitis in Mice is Attenuated by Topical Administration of Chlorogenic Acid. *Naunyn Schmiedebergs Arch Pharmacol* 2015; 388: 643–651. [PubMed] [CrossRef]
20. Liang N, Kitts D. Role of Chlorogenic Acids in Controlling Oxidative and Inflammatory Stress Conditions. *Nutrients* 2015; 8: 16. [PubMed] [CrossRef]
21. Tjokropawiro A. *Buku ajar ilmu penyakit dalam. Ed.2: Fakultas Kedokteran Universitas Airlangga Rumah Sakit Pendidikan Dr. Soetomo Surabaya.* Surabaya: Airlangga University Press, 2015.



JUXTA: JURNAL ILMIAH MAHASISWA KEDOKTERAN UNIVERSITAS AIRLANGGA

 [UNIVERSITAS AIRLANGGA](#)

✦ P-ISSN : 19073623 <> E-ISSN : 26849453



0.48

Impact Factor



110

Google Citations



Sinta 3

Current Accreditation

 [Google Scholar](#)  [Garuda](#)  [Website](#)  [Editor URL](#)

History Accreditation

2019

2020

2021

2022

2023

2024

[Garuda](#) [Google Scholar](#)

[Sleep Duration Determines Excess Body Mass Index among Young Adults in Surabaya](#)

Faculty of Medicine Universitas Airlangga  [JUXTA: Jurnal Ilmiah Mahasiswa Kedokteran Universitas Airlangga Vol. 13 No. 1 \(2022\): Jurnal Ilmiah Mahasiswa Kedokteran Universitas Airlangga 18-21](#)

 2022  DOI: [10.20473/juxta.V13I12022.18-21](#)  Accred : [Sinta 3](#)

[Back Matter Vol 13 No 1, 2021](#)

Faculty of Medicine Universitas Airlangga  [JUXTA: Jurnal Ilmiah Mahasiswa Kedokteran Universitas Airlangga Vol. 13 No. 1 \(2022\): Jurnal Ilmiah Mahasiswa Kedokteran Universitas Airlangga](#)

 2022  DOI: [10.20473/juxta.V13I12022.%p](#)  Accred : [Sinta 3](#)

[Early- and Late-Onset Preeclampsia at a Tertiary Hospital in 2016](#)

Faculty of Medicine Universitas Airlangga  [JUXTA: Jurnal Ilmiah Mahasiswa Kedokteran Universitas Airlangga Vol. 13 No. 1 \(2022\): Jurnal Ilmiah Mahasiswa Kedokteran Universitas Airlangga 6-8](#)

 2022  DOI: [10.20473/juxta.V13I12022.6-8](#)  Accred : [Sinta 3](#)

[Pre- and Post-Operative Intraocular Pressure of Pediatric Cataract Surgery](#)

Faculty of Medicine Universitas Airlangga  [JUXTA: Jurnal Ilmiah Mahasiswa Kedokteran Universitas Airlangga Vol. 13 No. 1 \(2022\): Jurnal Ilmiah Mahasiswa Kedokteran Universitas Airlangga 22-26](#)

 2022  DOI: [10.20473/juxta.V13I12022.22-26](#)  Accred : [Sinta 3](#)



**KOMITE ETIK PENELITIAN KESEHATAN
FAKULTAS KEDOKTERAN UNIVERSITAS AIRLANGGA
SURABAYA**

**KETERANGAN KELAIKAN ETIK
(“ETHICAL CLEARANCE”)**

No. 268/EC/KEPK/FKUA/2019

KOMITE ETIK PENELITIAN KESEHATAN FAKULTAS KEDOKTERAN UNIVERSITAS AIRLANGGA SURABAYA, TELAH MEMPELAJARI SECARA SEKSAMA RANCANGAN PENELITIAN YANG DIUSULKAN, MAKA DENGAN INI MENYATAKAN BAHWA PENELITIAN BERJUDUL :

Pengaruh Ekstrak Wortel (*Daucus carota L.*) sebagai Antiulserogenik pada Mencit yang Diinduksi Piroksikam

PENELITI UTAMA :
Jennifer Susanto

PEMBIMBING :
Danti Nur Indiasuti, dr., M.Ked.
Dr. Gondo Mastutik, drh., M.Kes.

UNIT / LEMBAGA / TEMPAT PENELITIAN :
Laboratorium Farmakologi Fakultas Kedokteran Universitas Airlangga, Laboratorium Histologi Fakultas Kedokteran Universitas Airlangga, Laboratorium Patologi Anatomi Fakultas Kedokteran Universitas Airlangga

DINYATAKAN LAIK ETIK.

Surabaya, 25 November 2019



Prof. Dr. H. Eddy Bagus Wasito, dr, MS., Sp.MK (K)